

# Herpes Zoster Ophthalmicus and Delayed Contralateral Hemiparesis Caused by Cerebral Angiitis: Diagnosis and Management Approaches

Dana C. Hilt, MD, David Buchholz, MD, Allan Krumholz, MD, Howard Weiss, MD,  
and Jerry S. Wolinsky, MD\*

Four patients with herpes zoster ophthalmicus and delayed contralateral hemiparesis are described, and their findings are compared with those in patients previously reported in the English language literature. The current patients evidenced multifocal ipsilateral cerebral angiitis by angiography and multifocal infarcts in the distribution of the ipsilateral middle cerebral artery by computed tomographic scanning. Cerebrospinal fluid showed mononuclear pleocytosis, positive oligoclonal bands, and an elevated immunoglobulin G index. Two patients were treated with corticosteroids and acyclovir, and 1 with corticosteroids alone, all without apparent response. Necrotizing angiitis ipsilateral to the herpes zoster ophthalmicus was demonstrated postmortem in 1 patient with multifocal cerebral infarction and progressive leukoencephalopathy. Neither herpes varicella zoster immunocytochemical reactivity nor viral inclusions were seen. The leukoencephalopathy associated with herpes varicella zoster either may be caused by cerebral angiitis or, as previously reported, may be a temporally remote manifestation of persistent herpes varicella zoster infection. The cerebral angiitis associated with herpes varicella zoster is histologically similar to granulomatous angiitis, and both may be related to herpes varicella zoster infection of the cerebral vasculature.

Hilt DC, Buchholz D, Krumholz A, Weiss H, Wolinsky JS: Herpes zoster ophthalmicus and delayed contralateral hemiparesis caused by cerebral angiitis: diagnosis and management approaches. *Ann Neurol* 14:543-553, 1983

Nervous system syndromes associated with herpes varicella zoster virus (HVZ) infections include varicella myositis [43], zoster radiculopathy [23, 38, 60], zoster myelitis [23, 25, 36, 38], cranial neuropathy including Ramsay-Hunt syndrome [13, 29, 47], zoster meningoenzephalitis [3, 6, 38, 39, 44, 52, 59], and a temporally remote leukoencephalitis [26]. A distinctive central nervous system syndrome associated with HVZ is that of herpes zoster ophthalmicus (HZO) followed by ipsilateral cerebral angiitis and consequent contralateral hemiparesis. Only 25 cases have appeared in the English language literature since the original description by Baudouin and Lantuejoul [5] after Dumary in 1919 [1, 2, 11, 15, 19, 22, 24, 28, 31-33, 35, 37, 44, 46, 49, 53, 55, 61-63]. Some cases may escape recognition because of the temporal dissociation of the acute vesicular rash and the subsequent hemiparesis. Pathogenetic mechanisms are unknown, but the finding of focal cerebral angiitis within the sensory field of the trigeminal

nerve suggests active HVZ infection by direct extension via the trigeminal nerve. An immune-mediated angiitis triggered by the HVZ infection is a possible alternate mechanism. This report describes four patients with HZO with contralateral hemiparesis seen consecutively over one year and compares their clinical features, diagnostic evaluations, and, in 2 cases, neuropathological findings with examples previously reported in the English language literature.

## Case Reports

### *Patient 1*

An 82-year-old right-handed woman was in excellent health until she developed left HZO, without corneal involvement, which healed completely. Twenty days after onset of the rash, she was noted to be "depressed." At 30 days she was lethargic but showed no other abnormalities on clinical examination. The cerebrospinal fluid (CSF) contained 136 white blood cells (WBC) per cubic millimeter, of which 97% were mono-

From the Department of Neurology, The Johns Hopkins University, Baltimore, MD 21205.

\*Present address: University of Texas Health Science Center at Houston, Department of Neurology, 6431 Fannin, Rm 7.044, PO Box 20708, Houston, TX 77025.

Received Jan 28, 1983, and in revised form Mar 28, 1983. Accepted for publication Apr 1, 1983.

Address reprint requests to Dr Wolinsky at his present address.

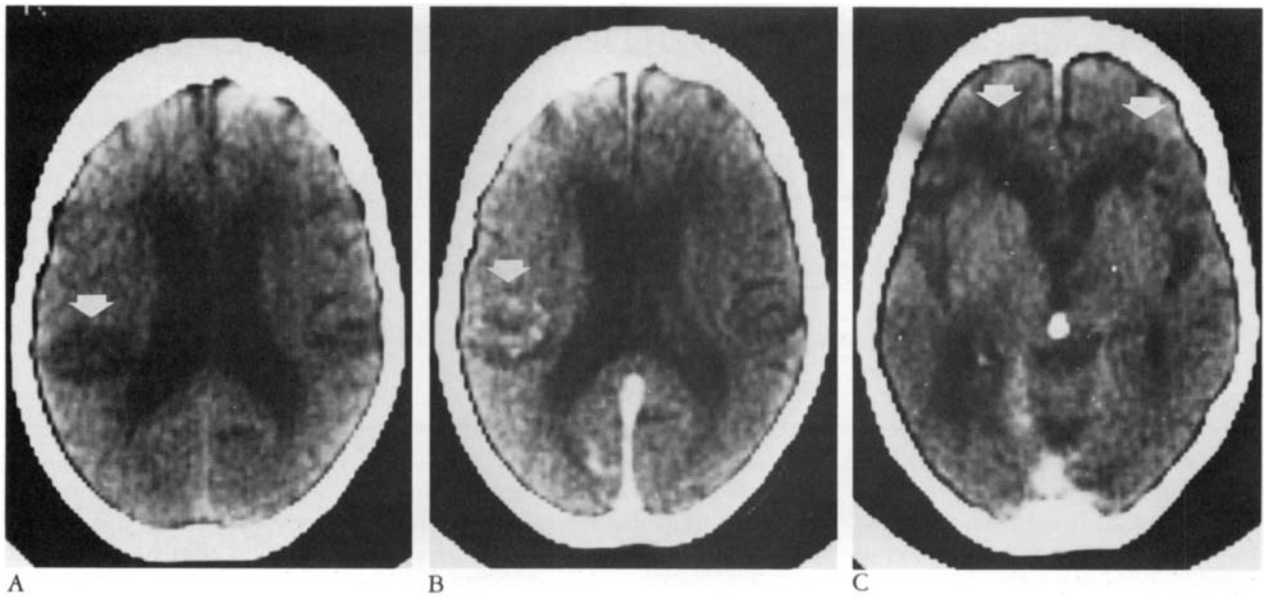


Fig 1. (Patient 1.) (A) Noncontrast computed tomographic (CT) scan at day 70, demonstrating a left parietal infarct (arrow). (B) Contrast CT scan at day 70, showing enhancement of the left parietal infarct (arrow). (C) Contrast CT scan at day 84, showing bifrontal periventricular white matter lucencies (arrows).

nuclear cells. The CSF glucose level was 58 mg/dl and CSF protein level was 125 mg/dl, of which 39% was immunoglobulin (normal, up to 12%). All cultures were negative. An electroencephalogram (EEG) was diffusely slow, and a computed tomographic (CT) scan showed mild ventriculomegaly compatible with age. The encephalopathy did not change greatly over the next three weeks, and the CSF pleocytosis persisted. On transfer to The Johns Hopkins Hospital 70 days into the illness, the patient was lethargic and aphasic, with a right spastic hemiparesis and left gaze preference. Repeat CSF analysis showed 34 mononuclear cells, a glucose level of 56 mg/dl, and a protein level of 53 mg/dl. Viral, bacterial, mycobacterial, and fungal cultures and CSF VDRL and cryptococcal antigen tests were negative, and cytology showed no abnormalities. The CSF myelin basic protein level was 15 ng/ml (normal, up to 6 ng/ml). Agarose gel electrophoresis of CSF showed four oligoclonal bands, and the immunoglobulin G index was elevated to 1.3 (normal, up to 0.6). CT scans showed an enhancing left parietal infarction and bifrontal periventricular white matter lucencies (Fig 1). The EEG was diffusely slow with periodic (0.5 to 1.5 Hz) high-voltage sharp waves, right greater than left. Cerebral angiography showed segmental narrowing of the proximal M<sub>1</sub> portion of the left middle cerebral artery and A<sub>1</sub> portion of the left anterior cerebral artery, as well as distal irregularities including segmental beading with pseudoaneurysm formation, all compatible with cerebral angiitis (Fig 2). Evaluation for systemic vasculitis, endocarditis, cardiac emboli, and malignancy showed no abnormalities. Methyl prednisolone was begun at a daily dose of 80 mg administered intravenously, and the dosage was tapered over six weeks, and acyclovir, 750 mg every 8 hours, was given intravenously for 10 days. Progressive obtundation ensued, however. Following acyclovir treatment, the CSF contained 10 mononuclear cells and normal glucose and protein levels; myelin basic protein level and oligoclonal bands were unchanged. The patient died 120 days after onset of HZO.

At postmortem examination, areas of focal infarction were

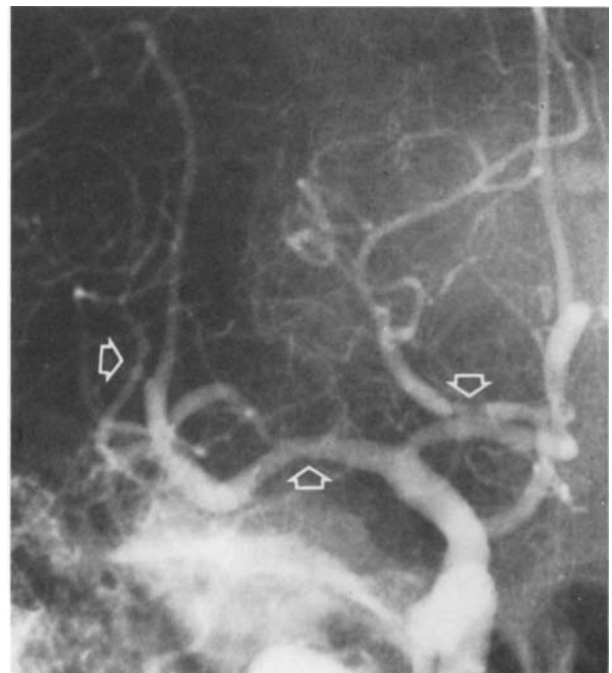
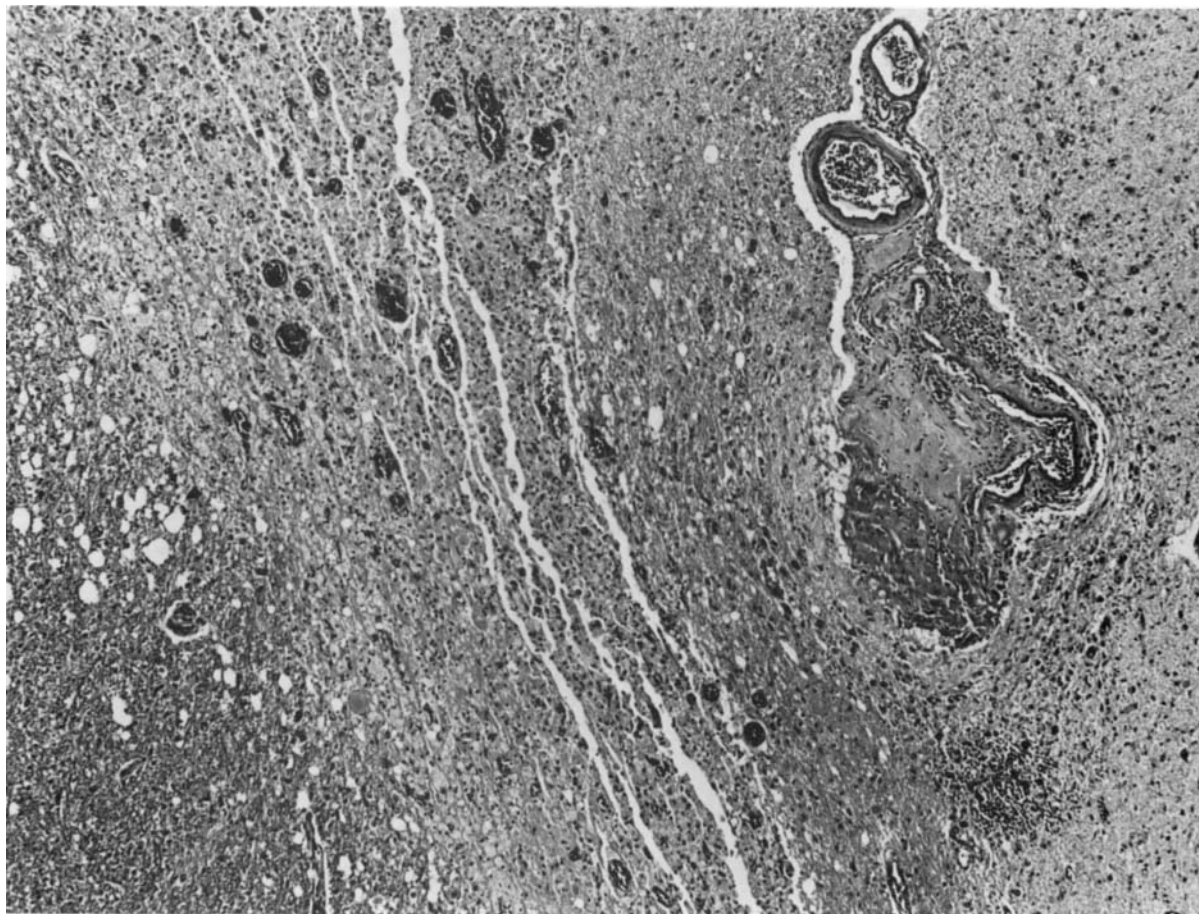
Fig 2. (Patient 1.) Left internal carotid angiogram (anteroposterior view), showing narrowing of the M<sub>1</sub> portion of the left middle cerebral artery and the A<sub>1</sub> portion of the left anterior cerebral artery and distal irregularities including segmental beading (arrows).



*Fig 3. (Patient 1.) Photomicrograph showing necrotizing histiocytic angiitis. An involved vessel and infarcted tissue are seen on the right; a small area of relatively normal white matter is seen in the lower left. (H&E;  $\times 160$ .)*

widespread in white and gray matter of both cerebral hemispheres, cerebellum, and brainstem. The histological appearance was compatible with infarcts several months old. Vessels in these regions showed evidence of necrotizing angiitis with infiltration of the vessel wall by histiocytes and occasional giant cells (Fig 3). No inclusion-bearing cells were seen.

Viral antigens were sought in deparaffinized tissues using the unlabeled peroxidase-antiperoxidase immunocytochemical procedure of Sternberger [58]. Prebleed or postimmunization sera were obtained from rabbits that received a series of inoculations of purified HVZ virions in complete and incomplete Freund's adjuvant [69]. The virions were prepared from the clarified supernatant of infected BSC-1 cells disrupted by sonication and then further purified by gradient centrifugation in sucrose [20]. Immunoglobulin fractions of these rabbit sera were used as primary immunocytochemical reagents [68]. Appropriate dilutions of the immunoglobulins were selected, using as targets comparably processed uninfected and HVZ-infected cells. These were prepared from mock- or HVZ-infected BSC-1 monolayers fixed in buffered 4% formalin; then the cells were scraped and collected by

filtration on millipore filters and the cell-containing filters were embedded in paraffin. Both infected and uninfected paraffin-embedded cell pellets served as concurrent positive and negative controls for the tissue sections from patient 1. Viral antigens could not be detected in any tissue sections examined by this method.

#### *Patient 2*

A 60-year-old right-handed man had a one-year history of myasthenia gravis, which was treated by resection of an invasive thymoma, mediastinal irradiation, pyridostigmine, and oral prednisone, 35 mg every other day. He developed right HZO with corneal involvement, and the prednisone dosage was briefly increased to 30 mg daily. The rash healed well, but at day 28 he became confused and ataxic and developed marked left hemiparesis with hyperreflexia. The CSF contained 96 WBC per cubic millimeter (92% mononuclear cells), with a glucose level of 52 mg/dl and a protein level of 96 mg/dl. Viral, bacterial, mycobacterial, and fungal cultures and CSF VDRL and cryptococcal antigen tests were negative, and there were no cellular abnormalities. The EEG was diffusely slow, especially over the right frontal area. Multiple right pericaudate lucencies that enhanced with contrast were seen on CT scan. Cerebral angiography showed narrowing of the right intracranial carotid artery, marked irregularity of the  $A_1$  segment of the right anterior cerebral artery, and focal dilatation of a branch of the right middle cerebral artery, all

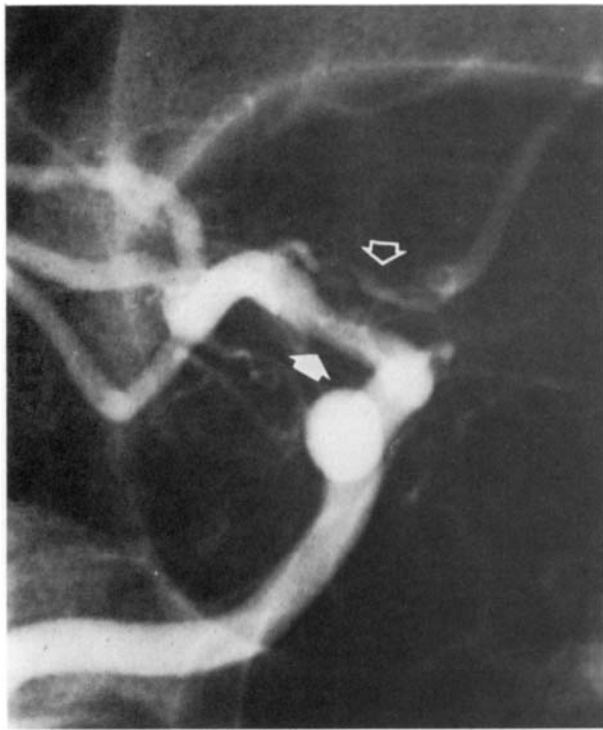


Fig 4. (Patient 2.) Right internal carotid angiogram (oblique view), showing narrowing of the right intracranial carotid artery (filled arrow) and irregular narrowing of the A<sub>1</sub> portion of the right anterior cerebral artery (open arrow).

compatible with cerebral angiitis (Fig 4). The patient was treated with acyclovir, 945 mg intravenously for 6 days, and his oral prednisone dosage was again increased to 30 mg daily. His neurological status initially stabilized, but on day 35 he became more lethargic and the left hemiparesis worsened. Acyclovir was stopped because of mild renal insufficiency, and the prednisone was increased to 50 mg twice a day. Repeat CSF analysis showed 8 mononuclear cells, normal glucose and protein levels, four oligoclonal bands, and immunoglobulin 25% of total protein. The patient's mental status and hemiparesis were improving by day 40. Prednisone dosage was tapered, and he was discharged to home with a residual left hemiparesis that subsequently resolved.

#### Patient 3

A 62-year-old right-handed woman with a remote history of bilateral resected breast carcinoma, migraine headaches, and mild angina pectoris developed right HZO with corneal involvement. This was treated with oral prednisone, 60 mg a day. On day 10 of therapy she was noted to be "depressed." Disorientation and hallucinations ensued, and she was treated with haloperidol. The neurological findings were otherwise normal. The CSF contained 100 WBC per cubic millimeter (97% mononuclear cells), with a glucose level of 60 mg/dl and a protein level of 62 mg/dl. The CSF IgG was 16% of total protein. Bacterial and fungal cultures and CSF VDRL and cryptococcal antigen tests were negative, and no cellular abnormalities were found. The EEG at day 28 was diffusely slow. The encephalopathy deepened, and repeat CSF analysis

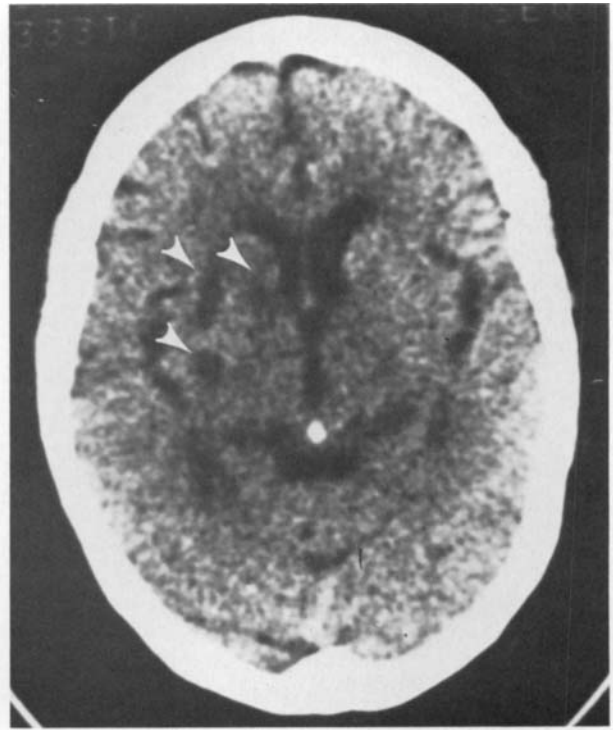


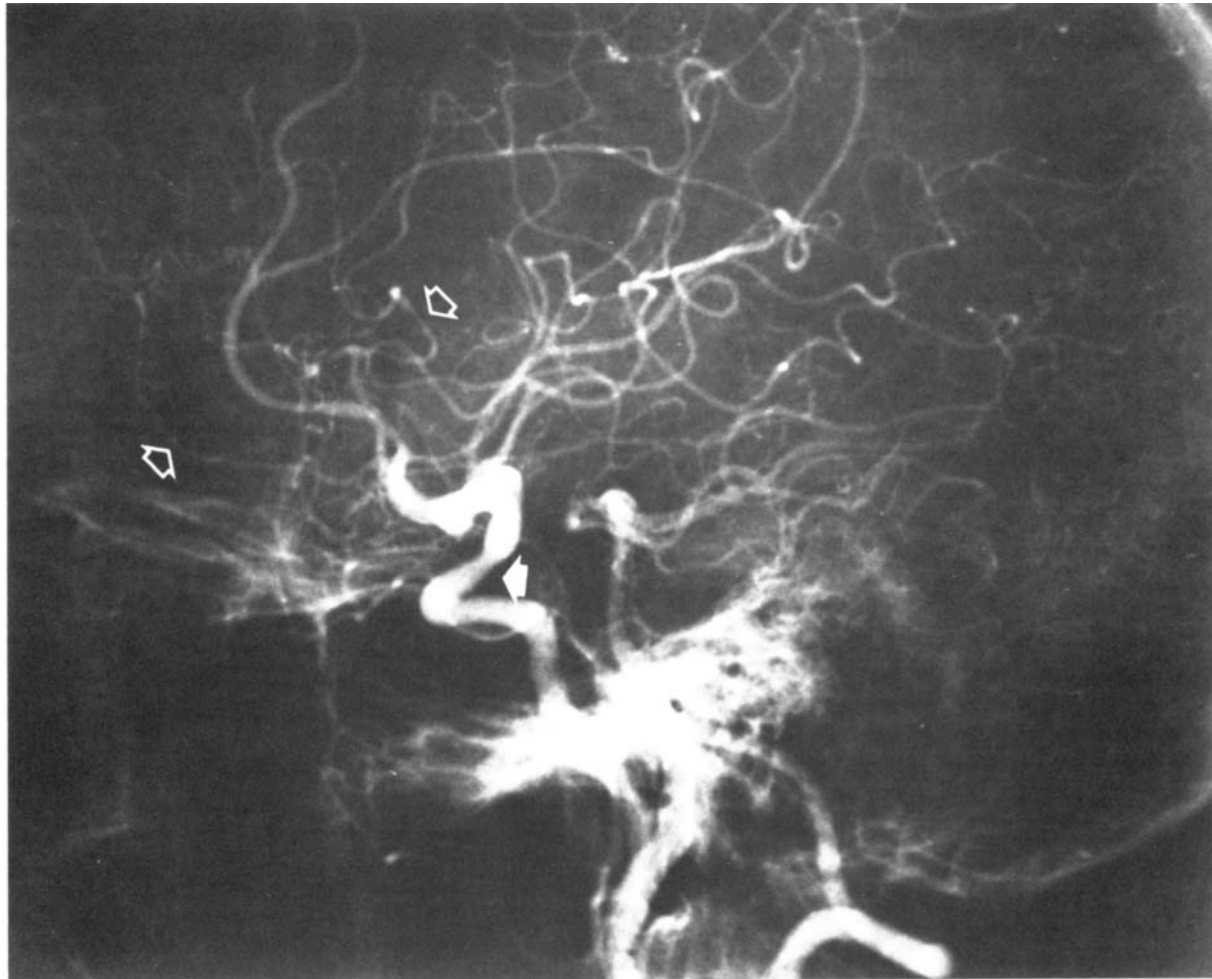
Fig 5. (Patient 3.) Noncontrast computed tomographic scan at day 40, showing multiple right basal ganglia and deep white matter infarcts (arrowheads).

at day 35 revealed no changes. Left hemiparesis and hemihypoesthesia were first noted on day 40. A CT scan showed multiple right basal ganglia and deep white matter lucencies (Fig 5), which enhanced with contrast, and an old, small, right parieto-occipital infarct. Cerebral angiography demonstrated right intracranial carotid artery narrowing and abnormalities of the distal right anterior and middle cerebral artery branches, all compatible with cerebral angiitis (Fig 6). The right carotid bifurcation was normal. Evaluation for systemic vasculitis, endocarditis, and metastatic malignancy showed no abnormalities. Oral dexamethasone, 20 mg daily, was started, and over the next two weeks the patient's disorientation and left hemiparesis gradually improved.

The patient did well following discharge from the hospital, and the dexamethasone dosage was tapered. At day 60, however, she suffered an acute intracranial hemorrhage, and she died several days later. Postmortem findings included right uncus herniation syndrome and right caudate hemorrhage with extensive tissue destruction. No aneurysm or other source of the hemorrhage was found. A limited histological evaluation documented old and new infarctions. No evidence of cerebral angiitis or inclusion-bearing cells was noted.

#### Patient 4

A 62-year-old right-handed man with severe rheumatoid arthritis and rheumatoid lung disease developed left HZO with corneal involvement. On day 10 he was febrile and was admitted to the hospital for treatment of possible sepsis. The initial neurological findings were normal. The serum HVZ



*Fig 6. (Patient 3.) Right retrograde brachial cerebral angiogram (lateral view), showing narrowing of the right intracranial carotid artery (filled arrow) and distal irregularities (open arrows).*

reciprocal titer was 256. He gradually became afebrile, antibiotics were discontinued, and the HZO was healing. On day 21 he became lethargic, and neurological examination showed mild disorientation, mild right central facial weakness, pronation and drift of the right arm, and subtle right leg weakness. The EEG was diffusely slow. Results of a radionuclide brain scan were normal, but a CT scan showed a new small left basal ganglia lucency. The CSF contained 56 mononuclear cells, a normal glucose level, and a protein level of 49 mg/dl, of which 40% was immunoglobulin. The IgG index was elevated to 1.8. Bacterial, mycobacterial, and fungal cultures and CSF VDRL and cryptococcal antigen tests were negative, and cytology showed no abnormalities. The CSF HVZ reciprocal titer rose from 4 to 16. Over the next two weeks the hemiparesis and confusion gradually improved without specific treatment. At day 35 the patient again became confused and combative, and the mild right hemiparesis worsened. A repeat CT scan showed no changes. An

atraumatic cervical puncture showed bloody, xanthochromic CSF with a disproportionate mononuclear pleocytosis and a protein level of 365 mg/dl. The clinical impression was possible cerebral angiitis with subarachnoid hemorrhage. Angiography was refused, and the patient made an uneventful and complete recovery over the next month without specific treatment.

### Discussion

The Table summarizes pertinent clinical and laboratory data in the English language literature on 25 previously reported patients with HZO and contralateral hemiparesis, to which the current cases are added. Including the current 4 patients, the mean age is 57 years, with a range from 7 to 96 years. Nineteen of 29 patients were age 60 or older, a finding consistent with a selective decline in cellular immune response to HVZ and increasing incidence of dermatomal zoster with aging [41]. Some patients had systemic malignancies or were otherwise immunocompromised. The latter group had a well-documented increased susceptibility to HVZ infections, manifested by dermatomal or disseminated zoster [14, 53, 64, 65]. Fourteen of the patients were

*Findings in 25 Patients with Herpes Zoster Ophthalmicus and Contralateral Hemiparesis*

| Reference                   | Age, Sex | Interval <sup>a</sup> | CNS Symptoms   | CSF (per mm <sup>3</sup> )   |
|-----------------------------|----------|-----------------------|--|--|
| Gordon and Tucker [22]      | 26, M    | 4 wk                  | Right HP, aphasia  | 4 wk <sup>c</sup> : WBC 3, pro N, xanthochromia<br>6 wk: WBC 38 (95% M), pro 70  |
| Hughes [28]                 | 70, F    | 4 wk                  | Left HP  | 4 wk: WBC 51, RBC 4, pro 34<br>8 wk: WBC 59, RBC 72, pro 100                     |
| Cope and Jones [11]         | 54, F    | 5 wk                  | Left HP  | 6 wk: WBC 48, pro 50   |
| Anastasopoulos et al [2]    | 29, M    | 5 wk                  | Right HP, aphasia  | 5 wk: WBC 4, pro 44  |
| Laws [33]                   | 65, F    | 4 mo                  | Right HP, aphasia  | ...  |
| Acers [1]                   | 32, M    | 3 wk                  | Right HP   | 3 wk: N  |
|                             | 61, M    | 4 wk                  | Right HP   | 4 wk: WBC 3, pro N   |
| Pandi and Romanes [46]      | 55, F    | 2 wk                  | Left HP  | 2 wk: WBC 90 (M > P), RBC 7, pro 200   |
| Kolodny et al [31]          | 96, F    | 4 wk                  | Left HP  | 1 wk: WBC 80 (62% M), pro 200<br>2-4 wk: WBC 110 (98% M), pro 445                |
| Norris et al [44]           | 72, F    | 6 mo                  | Disorientation, ataxia, right HP                           | ...  |
| Rosenblum and Hadfield [53] | 64, M    | 6 wk                  | Delirium, left HP  | 2 wk: WBC 65 (M > P), pro elevated<br>6 wk: WBC 7, RBC 7, pro 315, xanthochromia |
| Walker et al [63]           | 7, M     | 6 mo                  | Right HP, aphasia  | 6 mo: WBC 1, RBC 13  |
| Gilbert [19]                | 73, M    | 0                     | Left HP, right amaurosis fugax                             | 3 wk: N  |
| Victor and Green [62]       | 58, M    | 5 wk                  | Delirium, left HP and hemianopsia, right Horner's syndrome | 5 wk: WBC 55 (98% M), RBC 27, pro 52, IgG 15%                                    |
| Pratesi et al [49]          | 48, M    | 10 wk                 | Delirium, left HP  | 4 wk: no cells, pro 116<br>12 wk: no cells, pro 79                               |
| Gursoy et al [24]           | 24, F    | 1 wk                  | Right HP   | 1 wk: WBC 1200 (P > M) pro 100, glu 30<br>3 wk: N                                |
| Ruppenthal [55]             | 72, F    | 2 wk                  | Left HP  | ...  |
| Kuroiwa and Furukawa [32]   | 67, M    | 6 wk                  | Right HP   | 6 wk: WBC 21 (86% M), pro 32, elevated IgG                                       |
| MacKenzie et al [35]        | 34, F    | 4.5 mo                | Right HP, aphasia  | 4.5 mo: N  |
|                             | 70, M    | 7 wk                  | Left HP  | ...  |
|                             | 67, F    | 6 wk                  | Right HP, aphasia, memory deficit                          | 10 wk: N   |
|                             | 60, M    | 12 wk                 | Confusion, right HP, aphasia                               | 8 wk: WBC 14 (50% M), pro 63<br>12 wk: WBC 38, RBC 2091, pro 78                  |
| Doyle et al [15]            | 69, F    | 2 wk                  | Right HP   | ...  |
| Vecht [61]                  | 66, M    | 3 wk                  | Right HP and hemianopsia, aphasia                          | 4 wk: WBC 87 (92% M), RBC 6, pro 48, elevated IgG                                |
| McComas and Gutmann [37]    | 69, F    | 8 wk                  | Stupor, right HP, aphasia                                  | 8 wk: WBC 14, pro 55   |

<sup>a</sup>Approximate time from onset of herpes zoster ophthalmicus to onset of contralateral hemiparesis.

<sup>b</sup>Estimate based on available information.

<sup>c</sup>Approximate time since onset of herpes zoster ophthalmicus.

CNS = central nervous system; CSF = cerebrospinal fluid; CT = computed tomographic; EEG = electroencephalogram; HP = hemiparesis; WBC = white blood cell count; RBC = red blood cell count; pro = protein; N = normal; M = mononuclear cells; P = polymorphonuclear cells; glu = glucose; MCA = middle cerebral artery; ACA = anterior cerebral artery; PCA = posterior cerebral artery; R = radionuclide; ICA = internal carotid artery.

| Angiography  | Radionuclide or CT Scan                                    | EEG                                    | Course/Outcome <sup>b</sup>   |
|--|--|--|---|
| ...  | ...  | ...                                    | Moderate disability   |
| ...  | ...  | ...                                    | Severe disability   |
| ...  | ...  | ...                                    | Moderate disability   |
| ...  | ...  | ...                                    | Mild disability   |
| ...  | ...  | ...                                    | Anticoagulants; moderate disability   |
| ...  | ...  | ...                                    | Mild disability   |
| ...  | ...  | ...                                    | Severe disability   |
| ...  | ...  | Right slowing                          | Good recovery   |
| ...  | ...  | Diffuse, high-voltage slowing          | Death at 5 wk; diffuse angiitis with multiple recent infarcts   |
| Multiple right MCA branch occlusions   | (R) Increased parietal uptake                              | Diffuse 1–2 Hz<br>Right delta          | Prednisone; good recovery<br>Death at 6 wk; reticulum cell sarcoma; giant cell angiitis with multiple right cerebral infarcts |
| Segmental narrowing of left proximal ACA and MCA branches  | (R) Increased left frontoparietal uptake                   | Left delta                             | Some recovery   |
| Segmental narrowing of right carotid siphon  | ...  | Right temporal delta                   | Anticoagulants and steroids; mild disability  |
| ...  | (CT) N<br>(R) #1, N; #2, increased right occipital uptake  | ...                                    | Right temporal artery biopsy: mononuclear cell infiltrate; some recovery  |
| 10 wk: right PCA narrowing<br>16 wk: bilateral proximal MCA narrowing; occlusion of right ACA and PCA  | (R) N  | Right slowing                          | Prednisone; severe disability   |
| 2 wk: elevation of left MCA  | (R) Increased left temporal uptake                         | Left anterior sharp waves              | Ligation of aneurysm; mild disability   |
| 5 wk: left intrapetrosal carotid aneurysm  | ...  | ...                                    | Death at 2 wk; multifocal demyelination; ependymitis; mononuclear perivascular infiltrate                                     |
| ...  | ...  | ...                                    | Mild disability   |
| Segmental narrowing of left proximal MCA   | (CT) 6 wk: N<br>7 wk: multiple left MCA territory infarcts | Left slowing                           | Mild disability   |
| Stenosis of left M <sub>1</sub><br>Narrowing of right M <sub>1</sub> and A <sub>2</sub><br>Segmental narrowing of left M <sub>1</sub> and A <sub>2</sub> | (CT) Left internal capsule infarct<br>(CT) N<br>(CT) N     | Left temporal delta<br>N<br>Left delta | Anticoagulants; good recovery<br>Anticoagulants; good recovery<br>Prednisone; some recovery                                   |
| Stenosis of left A <sub>2</sub> and two MCA segments   | (CT) Meningiomas   | Left temporal delta                    | Prednisone; death   |
| ...  | ...  | ...                                    | Steroids; death at 10 wk; angiitis, massive left ICA thrombosis and left cerebral infarct; herpes virions in left MCA         |
| ...  | (CT) Left internal capsule infarct<br>(R) N                | Left temporal and diffuse slowing      | Unknown   |
| ...  | (CT) Bilateral basal ganglia and right frontal infarcts    | ...                                    | Left temporal and meningeal biopsies N; severe disability   |



women and 15 were men; 17 had left and 12 right HZO. The mean delay from onset of HZO to first manifestation of contralateral hemiparesis was seven weeks, with a range from no delay to six months.

The typical clinical history is gradual resolution of cutaneous HZO followed by the acute onset of contralateral hemiparesis, hemisensory symptoms, or aphasia. The temporal dissociation of HZO and neurological symptoms may obscure the diagnosis of HZO-associated cerebral angiitis. The neurological manifestations are usually monophasic, but some patients have recurrent ischemic episodes in the distribution of the ipsilateral middle cerebral artery. Prognosis is guarded, and there is a mortality of approximately 25%. Eleven of 29 patients had mild residual disability or made a good recovery, 10 had moderate or severe disability, 7 died, and the outcome of 1 is unknown.

Early alteration of mental status was noted in all of the current patients. In 2 patients psychological depression was diagnosed until progressive focal deficits became evident. An acute confusional state or delirium was also noted in several previously reported patients. This encephalopathy probably indicates generalized bihemispherical involvement, an impression supported by diffuse EEG abnormalities in all the present cases. Focal delta slowing over the involved hemisphere is the most common EEG abnormality reported in previous patients, however. The periodic sharp waves seen in patient 1 have not been described previously in any patient with HZO-associated cerebral angiitis. This type of abnormality is similar to that seen in herpes simplex encephalitis, Creutzfeldt-Jakob disease, and subacute sclerosing panencephalitis [42].

The CSF was abnormal in 17 of the 24 patients from whom it was obtained. The most common finding was a mononuclear pleocytosis of up to 1,200, but usually less than 100, WBC per cubic millimeter. The finding of normal CSF in 7 patients may reflect the timing of samples. As evidenced in patient 1, during the acute phase there often is a mononuclear pleocytosis that then slowly resolves. Patients with either dermatomal zoster or HZO may have a mononuclear CSF pleocytosis. By itself, the CSF pleocytosis does not distinguish patients with uncomplicated HZO from those who develop a neurological syndrome secondary to cerebral angiitis.

Bieger and colleagues [6] showed elevated CSF HVZ antibody titers in patients with probable HVZ meningoencephalitis. In both their patients the serum titer was much higher than the concurrent CSF titer. Gershon and associates [18] demonstrated the usefulness of an indirect immunofluorescence assay for HVZ antibody in CSF of patients with HVZ-associated neurological syndromes. Serial CSF and serum titers were obtained only in patient 4 of the current series. During the acute HZO episode the serum titer was

256 and the CSF titer was 4. As serum titers subsequently decreased, the CSF titer increased to 16. Serial determinations of paired serum and CSF titers may aid the diagnosis of HVZ involvement of the nervous system.

All the current patients had elevated CSF immunoglobulins or IgG indices. These findings presumably reflect increased intrathecal immunoglobulin synthesis. Oligoclonal bands were present in the 2 patients in which they were sought. As stated by Hosein and Johnson in a recent review [27], oligoclonal bands are present in a wide variety of central nervous system infections and inflammatory processes but have not been reported previously in patients with HVZ-associated cerebral angiitis.

Cerebral angiography was performed in 10 previously reported patients. MacKenzie and colleagues [35] emphasized segmental narrowing of the proximal middle and anterior cerebral arteries in the M<sub>1</sub>, A<sub>1</sub>, and A<sub>2</sub> segments in their patients. Small distal vessels may also be involved. Less frequently noted abnormalities include aneurysm of the intracavernous internal carotid artery [24], intracranial carotid artery stenosis at the level of the siphon [19], and total occlusion of the internal carotid artery from the level of the carotid bifurcation [15]. Three patients in the present series had cerebral angiography with adequate visualization of the carotid bifurcation, and atherosclerotic lesions were not seen. Changes compatible with cerebral angiitis were found at varied sites.

CT scans have been reported in 12 patients and showed abnormalities in 8. Lesions generally appeared in the deep gray matter or internal capsule and were consistent with infarcts in the distribution of the appropriate middle cerebral artery and its branches. One previously reported patient had bilateral basal ganglia infarcts [37]. All 4 current patients had infarcts of the basal ganglia, internal capsule, or pericaudate regions ipsilateral to the HZO. Patient 1 had progressive periventricular white matter lucencies documented by CT scan. Three of the patients had initial CT scan findings that did not satisfactorily explain their clinical presentations, and abnormalities were documented in the appropriate vascular distribution only on follow-up scans. This delayed development of CT scan abnormalities is typical of small, deep infarcts [50]. The location of the infarcts, together with the angiographic findings, suggests deep penetrating branch occlusion secondary to angiitis. This concept is further supported by available pathological findings.

CSF myelin basic protein concentration was determined in only patient 1 and was markedly abnormal, indicating active myelin destruction [9, 10]. This finding was supported further by the presence of progressive periventricular white matter lucencies on CT scans (see Fig 1C). Leukoencephalopathy has not been



reported previously in close association with HZO, although a syndrome of progressive leukoencephalitis temporally remote from HVZ infection was recently described by Horten and co-workers [26]. They reported 2 immunosuppressed patients with systemic malignancies who had truncal dermatomal zoster nine and ten months, respectively, prior to the onset of a progressive white matter process immunocytochemically directly related to HVZ. Angiitis was not seen in these patients. In both patients CT scans showed progressive white matter degeneration. Ruppenthal [55] reported a patient with HZO and delayed contralateral hemiparesis who showed multifocal demyelination postmortem with mononuclear perivascular inflammation and ependymitis without viral inclusions. It therefore appears that two pathogenetic mechanisms may be involved in patients with delayed or progressive white matter degeneration after HVZ infection. One process, temporally remote, as reported by Horten and colleagues [26], involves ongoing central nervous system viral infection in an immunocompromised host and must be distinguished from progressive multifocal leukoencephalopathy. The other mechanism is exemplified by our patient 1, in whom leukoencephalopathy appears to be a manifestation of progressive angiitis involving both gray and white matter.

Although neither viral inclusions nor HVZ immunoreactivity could be demonstrated in patient 1, there are reports of viral particles within involved vasculature in a patient with HZO and hemiparesis [15]. Failure to show HVZ antigens in pathological material from the current patient may reflect: (1) prior treatment with acyclovir, (2) inactive angiitis at the time of death, or (3) angiitis triggered by HVZ infection of the cerebral vasculature but possibly not requiring active infection once initiated.

At present, herpes simplex virus infection of the central nervous system is the only treatable viral encephalitis [66, 67]. Both adenine arabinoside and, more recently, acyclovir have been effective in patients with nonneural HVZ infections [8, 17, 30, 56, 57, 64, 65]. Some previously reported patients with HZO-associated hemiparesis have been treated with corticosteroids or warfarin sodium without apparent benefit [15, 19, 33, 35, 44, 49]. Because the likely pathogenesis of HZO-associated hemiparesis includes HVZ infection of cerebral vasculature and consequent cerebral angiitis, 2 of the current patients were treated with both high-dose corticosteroids and parenteral acyclovir. One other patient received only corticosteroids. Treatment did not noticeably alter their clinical courses. Optimal therapy, including the utility of antiviral agents, remains to be defined.

Since its recognition by Cravioto and Feigin [12], granulomatous angiitis of the central nervous system has remained a rare entity characterized by cerebral

angiitis with few if any systemic manifestations [7, 45]. In their review Kolodny and colleagues [31] included a patient with HZO, contralateral hemiparesis, and white matter infarcts. Although the pathogenesis of granulomatous angiitis is unexplained, Rosenblum and Hadfield [53] and Rosenblum and colleagues [54] suggested that in their 2 patients with systemic malignancy, an association existed between HVZ and the pathologically proven granulomatous angiitis. Reyes and co-workers [51] reported a patient with granulomatous angiitis and primarily white matter infarcts in whom viral particles in involved vasculature were demonstrated by electron microscopy. Linnemann and colleagues [34] reported an additional patient with HZO and a rapidly progressive multifocal encephalopathy who showed fulminant vasculitis postmortem with viral particles in vascular smooth muscle cells demonstrated by electron microscopy. Most recently, Doyle and associates [15] reported viral particles within giant cells in the inflamed middle cerebral artery of a patient with HZO and contralateral hemiparesis. This mounting body of evidence suggests viral infection of vascular structures in both HZO-associated hemiparesis and some cases of granulomatous angiitis.

The ability of HVZ to infect human brain cells and trigeminal ganglion cells in tissue culture, the recovery of virus from affected neurons postmortem, and the immunofluorescent demonstration of HVZ antigen in the CSF of patients with HVZ infection and neurological symptoms are all well documented [4, 6, 16, 21, 48, 55]. The trigeminal nerve is known to provide sensory innervation to the proximal middle cerebral artery [40], and it has been proposed that HZO-associated angiitis is the result of spread of virus along the trigeminal nerve. This may not, however, be the sole mechanism of viral spread. Although the infection may be initiated in branches of the trigeminal nerve innervating the middle cerebral artery, in some patients there is widespread bilateral involvement that includes posterior vascular structures not known to be innervated by trigeminal nerve branches. Additionally, some patients with HVZ-associated cerebral angiitis have had truncal rather than trigeminal zoster eruptions. In such patients either hematogenous or contiguous dissemination via CSF pathways must be invoked.

---

Supported in part by Public Health Service Grant NS15721 from the National Institutes of Health (National Institute of Neurological and Communicative Disorders and Stroke). J. S. W. is the recipient of Public Health Service Research Career Development Award NS00443.

The authors are grateful to Dr Donald H. Gilden for providing the hyperimmune sera, to Linda Kelly for manuscript preparation, and to Susan Sim for technical assistance.

---

## References

1. Acers TE: Herpes zoster ophthalmicus with contralateral hemiplegia. *Arch Ophthalmol* 71:371-376, 1964
2. Anastasopoulos G, Routsonis K, Ierodiakonou CS: Ophthalmic herpes zoster with contralateral hemiplegia. *J Neurol Neurosurg Psychiatry* 21:210-212, 1958
3. Appelbaum E, Kreps SI, Sunshine A: Herpes zoster encephalitis. *Am J Med* 32:25-31, 1962
4. Bastian FO, Rabson AS, Yee CL, Tralka S: Herpesvirus varicellae: isolated from human dorsal root ganglia. *Arch Pathol* 97:331-332, 1974
5. Baudouin E, Lantuejoul P: Les troubles dans le zona. *Gazzetta Degli Ospedali e Delle Cliniche* 92:1293-1295, 1919
6. Bieger RC, Van Scoy RE, Smith TF: Antibodies to varicella zoster in cerebrospinal fluid. *Arch Neurol* 34:489-491, 1977
7. Burger PC, Burch JG, Vogel FS: Granulomatous angiitis: an unusual etiology of stroke. *Stroke* 8:29-35, 1977
8. Burns WH, Saral R, Santos GW, Laskin OL, Leitman PS: Isolation and characterization of resistant herpes simplex virus after acyclovir therapy. *Lancet* 1:421-423, 1982
9. Cohen SR, Brooks BR, Herndon RM, Jubelt B, McKhann GM: A diagnostic index of active demyelination: myelin basic protein in cerebrospinal fluid. *Ann Neurol* 8:25-31, 1980
10. Cohen SR, Herndon RM, McKhann GM: Radioimmunoassay of myelin basic protein in spinal fluid: an index of active demyelination. *N Engl J Med* 295:1455-1457, 1976
11. Cope S, Jones AT: Hemiplegia complicating ophthalmic zoster. *Lancet* 2:898-899, 1954
12. Cravioto H, Feigin I: Noninfectious granulomatous angiitis with a predilection for the nervous system. *Neurology (Minneapolis)* 9:599-607, 1959
13. Denny-Brown P, Adams RD, Fitzgerald PJ: Pathologic features of herpes zoster. *Arch Neurol Psychiatry* 51:216-231, 1944
14. Dolin R: Herpes zoster-varicella infections in immunosuppressed patients. *Ann Intern Med* 89:375-388, 1978
15. Doyle PW, Gibson G, Dolman CL: Herpes zoster ophthalmicus with contralateral hemiplegia: identification of cause. *Ann Neurol* 14:84-85, 1983
16. Esiri MM, Tomlinson AH: Herpes zoster: demonstration of virus in trigeminal nerve and ganglion by immunofluorescence and electron microscopy. *J Neurol Sci* 15:35-48, 1972
17. Esmann V, Ipsen J, Peterslund NA, Seyer-Hansen K, Schonheyder H, Juhl H: Therapy of acute herpes zoster with acyclovir in the nonimmunocompromised host. *Am J Med* 73:[Suppl] 320-325, 1982
18. Gershon A, Steinberg S, Greenberg S, Taber L: Varicella-zoster-associated encephalitis: detection of specific antibody in cerebrospinal fluid. *J Clin Microbiol* 12:764-767, 1980
19. Gilbert GJ: Herpes zoster ophthalmicus and delayed contralateral hemiparesis. *JAMA* 229:302-304, 1974
20. Gilden DH, Shtram Y, Friedmann A, Wellish M, Devlin M, Fraser N, Becker Y: The internal organization of the varicella zoster genome. *J Gen Virol* 60:371-374, 1982
21. Gilden DH, Wroblewska Z, Kindt V, Warren KG, Wolinsky JS: Varicella-zoster virus infection of human brain cells and ganglion cells in tissue culture. *Arch Virol* 56:105-117, 1978
22. Gordon IRS, Tucker JF: Lesions of the central nervous system in herpes zoster. *J Neurol Neurosurg Psychiatry* 8:40-46, 1945
23. Griffith JF, Salam MV, Adams RD: The nervous system disease associated with varicella. *Acta Neurol Scand* 46:279-300, 1970
24. Gursoy G, Aktin E, Bahar S, Tolun R, Ozden B: Post-herpetic aneurysm in the intrapetrous portion of the internal carotid artery. *Neuroradiology* 19:279-282, 1980
25. Hogan EL, Krigman MR: Herpes zoster myelitis: evidence for viral invasion of spinal cord. *Arch Neurol* 29:309-313, 1973
26. Horten B, Price RW, Jimenez D: Multifocal varicella-zoster virus leukoencephalitis temporally remote from herpes zoster. *Ann Neurol* 9:251-266, 1981
27. Hosein ZZ, Johnson KP: Isoelectric focusing of cerebrospinal fluid proteins in the diagnosis of multiple sclerosis. *Neurology (NY)* 31:70-76, 1981
28. Hughes WN: Herpes zoster of the right trigeminal nerve with left hemiplegia. *Neurology (Minneapolis)* 1:167-169, 1951
29. Hunt JR: On herpetic inflammation of the geniculate ganglion. *J Nerv Ment Dis* 34:73-96, 1907
30. Johnson MT, Luby JP, Buchanan RA: Treatment of varicella-zoster virus infections with adenine arabinoside. *J Infect Dis* 131:225-229, 1975
31. Kolodny EH, Rebeiz JJ, Caviness VS, Richardson EP: Granulomatous angiitis of the central nervous system. *Arch Neurol* 19:510-524, 1968
32. Kuroiwa Y, Furukawa T: Hemispheric infarction after herpes zoster ophthalmicus: computed tomography and angiography. *Neurology (NY)* 31:1030-1032, 1981
33. Laws HW: Herpes zoster ophthalmicus complicated by contralateral hemiplegia. *Arch Ophthalmol* 63:273-280, 1960
34. Linnemann CC, Alvira MM: Pathogenesis of varicella-zoster angiitis in the CNS. *Arch Neurol* 37:239-240, 1980
35. MacKenzie RA, Forbes GS, Karnes WE: Angiographic findings in herpes zoster arteritis. *Ann Neurol* 10:458-464, 1981
36. McCarthy JT, Amer J: Postvaricella acute transverse myelitis: a case presentation and review of the literature. *Pediatrics* 62:202-204, 1978
37. McComas CF, Gutmann L: Hemispheric infarction after herpes zoster ophthalmicus. *Neurology (NY)* 32:914-915, 1982
38. McKendall RR, Klawans HL: Nervous system complications of varicella-zoster virus. In Vinken PJ, Bruyn GW (eds): *Handbook of Clinical Neurology*, Vol 34. Amsterdam, North Holland, 1978
39. McKormick WF, Rodnitzky RL, Schochet SS, McKee AP: Varicella-zoster encephalomyelitis: a morphologic and virologic study. *Arch Neurol* 21:559-570, 1969
40. Mayberg M, Langer RS, Zervas NT, Moskowitz MA: Perivascular meningeal projections from cat trigeminal ganglia: possible pathway for vascular headaches in man. *Science* 213:228-230, 1981
41. Miller AE: Selective decline in cellular immune response to varicella-zoster in the elderly. *Neurology (NY)* 30:582-587, 1980
42. Niedermeyer E, Lopes da Silva F: *Electroencephalography*. Baltimore/Munich: Urban and Schwarzenberg, 1982
43. Norris FH, Dramov B, Calder CD, Johnson SG: Virus-like particles in myositis accompanying herpes zoster. *Arch Neurol* 21:25-31, 1969
44. Norris FH, Leonards R, Calanchini PR, Calder CD: Herpes zoster meningoencephalitis. *J Infect Dis* 122:335-338, 1970
45. Nurick S, Blackwood W, Mair WGP: Giant cell granulomatous angiitis of the central nervous system. *Brain* 95:133-142, 1972
46. Pandi DN, Romanes GJ: Ophthalmological herpes zoster complicated by hemiplegia. *Br J Ophthalmol* 50:610-611, 1966
47. Parker WJC: Multiple cranial nerve involvement with herpes zoster. *Med J Aust* 2:1179-1180, 1971
48. Peters A, Versteeg J, Bots G, Lindeman J, Smeets R: Nervous system complications of herpes zoster: immunofluorescent demonstration of varicella-zoster antigen in CSF cells. *J Neurol Neurosurg Psychiatry* 42:452-457, 1979
49. Pratesi R, Freemon FR, Lowry JL: Herpes zoster ophthalmicus with contralateral hemiplegia. *Arch Neurol* 34:640-641, 1977
50. Pullicino P, Nelson RF, Kendall BE, Marshall J: Small deep infarcts diagnosed on computed tomography. *Neurology (NY)* 30:1090-1096, 1980
51. Reyes MG, Fresco R, Chokroverty S, Salud EQ: Virus like parti-

- cles in granulomatous angiitis of the central nervous system. *Neurology (Minneapolis)* 26:797-799, 1976
52. Rose FC, Brett EM, Burston J: Zoster encephalomyelitis. *Arch Neurol* 11:155-172, 1964
  53. Rosenblum WI, Hadfield MG: Granulomatous angiitis of the nervous system in cases of herpes zoster and lymphosarcoma. *Neurology (Minneapolis)* 22:348-354, 1972
  54. Rosenblum WI, Hadfield MG, Young HF: Granulomatous angiitis with preceding varicella zoster. *Ann Neurol* 3:374-375, 1978
  55. Ruppenthal M: Changes of the central nervous system in herpes zoster. *Acta Neuropathol* 52:59-68, 1980
  56. Schulthess GK, Sauter C: Acyclovir and herpes zoster. *N Engl J Med* 305:1349, 1981
  57. Selby PJ, Powles RL, Jameson B, Kay H, Watson JG, Thornton R, Morgenstern G, Clink HM, McElwain TJ: Parenteral acyclovir therapy for herpes virus infections in man. *Lancet* 2:1267-1270, 1979
  58. Sternberger LA: *Immunocytochemistry*. Second edition. New York: Wiley, 1979
  59. Takashima S, Becker LE: Neuropathology of fatal varicella. *Arch Pathol Lab Med* 103:209-213, 1979
  60. Thomas JE, Howard FM: Segmental zoster paresis: a disease profile. *Neurology (Minneapolis)* 22:459-466, 1972
  61. Vecht J: Hemispheric infarction after herpes zoster ophthalmicus. *Neurology (NY)* 32:914, 1982
  62. Victor DI, Green WR: Temporal artery biopsy in herpes zoster ophthalmicus with delayed arteritis. *Am J Ophthalmol* 82:628-630, 1976
  63. Walker RJ, Gammal TE, Allen MB: Cranial arteritis associated with herpes zoster. *Radiology* 107:109-110, 1973
  64. Whitley RJ, Ch'ien LT, Dolin R, Galasso GJ, Alford CA: Adenine arabinoside therapy of herpes zoster in the immunosuppressed. *N Engl J Med* 294:1193-1199, 1976
  65. Whitley RJ, Soong SJ, Dolin R, Betts R, Linnemann C, Alford CA: Early vidarabine therapy to control the complications of herpes zoster in immunosuppressed patients. *N Engl J Med* 307:971-975, 1982
  66. Whitley RJ, Soong SJ, Dolin R, Galasso CJ, Ch'ien LT, Alford CA: Adenine arabinoside therapy of biopsy-proved herpes simplex encephalitis. *New Engl J Med* 297:289-294, 1977
  67. Wolinsky JS: Clinical conferences at the Johns Hopkins Hospital: herpes simplex encephalitis. *Johns Hopkins Med J* 147:157-163, 1980
  68. Wolinsky JS, Hatzidimitriou G, Waxham MN, Burke S: Immunocytochemical localization of mumps virus antigens in vivo by light and electron microscopy. In Bishop DHL, Compans RW (eds): *The Replication of Negative Strand Viruses*. New York: Elsevier-North Holland, 1981
  69. Wroblewska Z, Devlin M, Reilly K, van Trieste H, Wellish M, Gilden DH: The production of varicella zoster virus antiserum in laboratory animals. *Arch Virol* 74:233-238, 1982