

Herpes zoster ophthalmicus with contralateral hemiplegia and normal pressure hydrocephalus

N. Inoue¹, S. Shiraishi¹, T. Tsuda¹, T. Yamato¹, Y. Murai¹, Y. Tsukamoto², and H. Nakata²

¹ Departments of Neurology and ² Radiology
University of Occupational and Environmental Health, Japan, Kitakyushu, Japan

Summary. A case of herpes zoster ophthalmicus complicated by contralateral hemiplegia and normal pressure hydrocephalus is presented. The hydrocephalus is considered to be caused by recurrent haemorrhage from extensive cerebral arteritis.

Key words: Herpes zoster ophthalmicus – Hemiplegia normal pressure hydrocephalus – Computed tomography – Arteritis

Zusammenfassung. Es wird über einen Fall von Herpes Zoster ophthalmicus berichtet, welcher durch eine kontralaterale Hemiplegie und einen aresorptiven Hydrocephalus kompliziert wurde. Es wird angenommen, daß letzterer durch rezidivierende Blutungen aufgrund der ausgedehnten Arteriitis cerebraler Gefäße verursacht wurde.

Herpes zoster ophthalmicus (HZO) with delayed contralateral hemiplegia is a rare but well-defined syndrome [1, 2], and more than 30 cases have been reported in the world literature. Some histopathological studies [3–5] have shown that the hemiplegia in this syndrome results from cerebral infarction caused by granulomatous angiitis.

Normal pressure hydrocephalus (NPH) has not previously been reported with HZO and delayed hemiplegia.

Case report

A 69-year-old man was admitted to our University Hospital on 7 June 1982, because of a vesicular rash on the left forehead and a lethargic episode. In June 1981, he had been diagnosed as suffering from Parkinson's disease and had been treated with levodopa. At that time CT was normal. On 11 May 1982, he developed a gnawing pain in his left eye. In a few days this was accompanied by an erythematous papulovesicular eruption over the left side of his forehead. One week later the skin lesion began to resolve. On 25 May he became lethargic.

On admission, he had a temperature of 38°C and was somnolent. Discrete areas of hyperpigmentation and scarring were noted in the distribution of the ophthalmic division of the left trigeminal nerve. The pupils were round, but larger on the left. Light reflexes were absent on the left side. There was no evidence of the involvement in any of the other cranial nerves.

Resting tremor of the right hand and marked rigidity on the neck and four limbs were recognized. Voluntary movements of all limbs were fully maintained, and muscle strength was intact. The deep tendon reflexes were normal with flexor plantar reflexes. Normal studies included complete blood cell count, urinalysis, hepatic and renal functions, serum electrolytes, serum protein, electrocardiograph, and X-ray examinations of the chest and skull. VDRL and PPD skin tests were negative. Varicella complement fixation titre alone was 1:256 in serum. Cerebrospinal fluid (CSF) was clear with a pressure of 90 mm H₂O and contained 33 lymphocytes/mm³. CSF protein content was 110 mg/100 ml. Glucose and chloride were normal. Varicella complement fixation titre was also high (1:64) in CSF.

Following admission various doses of anti-parkinsonian medications including levodopa were employed without definite improvement. On 2 July his voluntary movement of the right limbs decreased. In a few days he developed a definite right hemiplegia with exaggerated deep reflexes. Babinski and Chaddock signs became positive on the right. The CSF on 7 July revealed normal pressure (105 mm H₂O), xanthochromia, pleocytosis (16/mm³) and increased protein content (72 mg/100 ml). CSF varicella complement fixation rose to 1:256, serum titre also being high (1:256). These titres of serum and CSF gradually decreased thereafter. An electroencephalogram on 12 July showed diffuse delta waves over the left hemisphere. On 21 July 10 weeks after HZO, CT of the brain demonstrated mildly dilated symmetrical ventricles with periventricular lucency. There were oval hypodense zones in both basal ganglia, larger on the left. A high density area showing fluid level was also observed in the posterior horns of both lateral ventricles, consistent with intraventricular haemorrhage. Contrast enhancement was not evident. At about the middle of August, voluntary movement of his right limbs reappeared, and muscle strength became almost normal in the next month. Hyperreflexia and pathological reflexes were still present. On 14 September the follow-up CT showed the progression of the dilatation of the lateral ventricles, which appeared to compress the low-density lesions in the basal ganglia. A new hypodense area was recognized in the posterior portion of the left temporal lobe. There was mild cerebral atrophy in the frontal lobes. CSF on 27 September showed normal pressure and marked xanthochromia. The left carotid angiograms (Fig. 1) performed on 16 September showed definite segmental narrowing of the horizontal and pericallosal parts of the anterior cerebral artery. These vascular changes were also present in the knee of the middle cerebral artery. The posterior temporal artery, the precentral artery and the central artery were completely obstruct-

Offprint requests to: Dr. N. Inoue, Department of Neurology, University of Occupational and Environmental Health, Japan, Yahatanishiku, Kitakyushu, 807, Japan

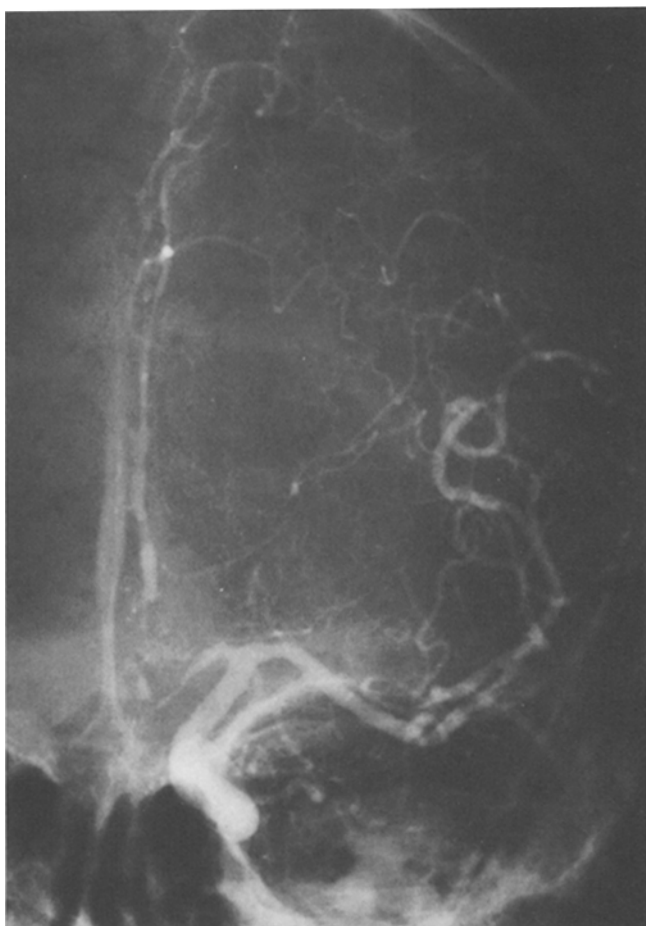

Fig. 1. Left carotid angiography (AP view) shows a marked segmental narrowing of the anterior and middle cerebral arteries with partial visualization of lenticulo-striate arteries

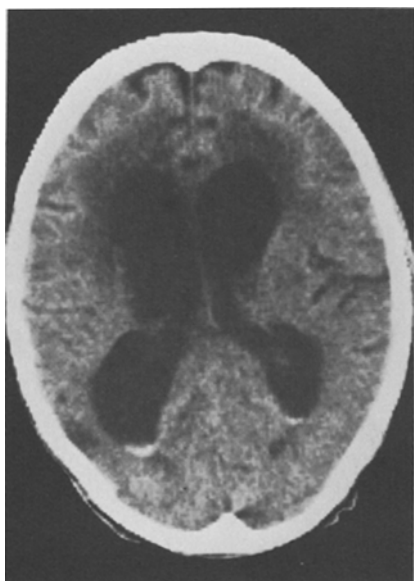


Fig. 2. CT (5 months after HZO) shows overt hydrocephalus and intraventricular haemorrhage

ed, while retrograde fillings were noted on the serial films. The lenticulostriate arteries were partially visualized. Scintiscintigraphy using ^{111}In -DTPA performed on 9 October revealed persistent filling of the enlarged lateral ventricles for more

than 48 h with failure of the radioactivity to ascend over the subarachnoid spaces of the convexity.

Five months after HZO (on 12 October), CT (Fig. 2) demonstrated overt hydrocephalus and intraventricular haemorrhage. The cerebral atrophy in the frontal lobes became less conspicuous. CSF at that time showed normal pressure and xanthochromia. On 13 October, right carotid angiography and vertebral angiography were carried out. Segmental narrowing was found in the proximal portions of the anterior and middle cerebral arteries. Similar but milder changes were recognized in both posterior cerebral arteries. Hydrocephalus with no evidence of prominent cortical atrophy on CT was still observed on 2 November and on 22 December respectively.

Neurological examination on 31 January 1983, revealed stupor, hyper-reflexia on the right limbs, and marked rigidity on the neck and four limbs.

Discussion

The diagnosis of HZO with a delayed contralateral hemiplegia was supported by high varicella complement fixation titres of serum and CSF.

Onoda and Takahashi [6] first reported a case with a well-defined low-density lesion on CT affecting the posterior limb of the internal capsule on the side ipsilateral to ophthalmic herpes. Since then such unilateral hypodense lesions on CT have been recognized by several authors [7–11]. These CT abnormalities were localized exclusively in the internal capsule or its vicinity on the ipsilateral side to HZO. However, CT in our case showed oval low-density lesions in both basal ganglia, followed by a newer low-density area in the left posterior temporal lobe. Only one other case with multiple bilateral lesions has been reported, by McComas and Gutman in 1982 [12].

Cerebral angiography has been carried out to define the nature and extent of vasculitis in cases with this syndrome [1, 6–8, 11, 13–16]. The main lesions observed have been in the territory on the carotid artery on the ipsilateral side to HZO. The characteristic angiographic appearance consists of single or multiple smooth tapered segmental narrowings in either the proximal pericallosal artery beneath the genu of the corpus callosum or the horizontal segment of the middle cerebral artery, or both [8]. However, our patient showed more widespread angiographic findings: proximal segmental narrowings in the anterior and middle cerebral arteries on both sides, and also in both posterior cerebral arteries to a lesser degree.

Another interesting aspect of our patient is the insidious occurrence of hydrocephalus which became prominent 5 months after HZO. To our knowledge, this is the first case of NPH associated with this syndrome and herpes zoster infection. However, the occurrence of this complication is not surprising. In this syndrome, milder enlargement of ventricular system has been recognized by means of pneumoencephalography [13] and CT [6]. Kolodny et al. [3] described some ventricular enlargement in an autopsy case with granulomatous angiitis. Also, in varicella zoster encephalomyelitis, McCormick et al. [17] observed a moderate enlargement of the lateral and third ventricles in an autopsy case.

Interestingly our patient had ventricular haemorrhage in repeat CT examinations. Such a CT finding has not been previously reported in this syndrome. In our case, CSF showed xanthochromia whenever ventricular haemorrhage was recognized on CT. According to a review by Kuroiwa and Furukawa

[7], 5 of 16 patients in whom CSF was examined showed xanthochromia. This is well explainable by the fact that haemorrhagic lesions have been observed in the autopsy material of cases with herpes zoster encephalomyelitis [17] or encephalitis [18].

Thus the cause of NPH in our case was thought to be based on the recurrent bleeding from the extensive cerebral arteritis.

Acknowledgement. The authors are grateful to Miss Reiheki Kaku and Miss Tomoko Kitagawa for secretarial assistance.

References

1. Pratesi R, Freeman FR, Lowry JL (1977) Herpes zoster ophthalmicus with contralateral hemiplegia. *Arch Neurol* 34: 640-641
2. Gilbert GJ (1977) Evidence of viral cause in granulomatous angiitis. *Neurology (Minneapolis)* 27: 100-101
3. Kolodny EH, Rebeiz JJ, Caviness VS, Richardson EP (1968) Granulomatous angiitis of the central nervous system. *Arch Neurol* 19: 510-524
4. Rosenblum WI, Hadfield MG (1972) Granulomatous angiitis of the nervous system in cases of herpes zoster and lymphosarcoma. *Neurology (Minneapolis)* 22: 348-354
5. Victor DI, Green W (1976) Temporal artery biopsy in herpes zoster ophthalmicus with delayed arteritis. *Am J Ophthalmol* 82: 628-638
6. Onoda M, Takahashi A (1979) Herpes zoster ophthalmicus followed by contralateral hemiparesis. *Clin Neurol* 19: 496-503
7. Kuroiwa Y, Furukawa T (1981) Hemispheric infarction after herpes zoster ophthalmicus: computed tomography and angiography. *Neurology (NY)* 31: 1030-1032
8. MacKenzie RA, Forbes GS, Karnes WE (1981) Angiographic findings in herpes zoster arteritis. *Ann Neurol* 10: 458-464
9. Vecht CJ, v d Sande JJ (1982) Hemispheric infarction after herpes zoster ophthalmicus. *Neurology (NY)* 32: 914
10. Menkes DB, Bishara S, Corbett AJ (1983) Hemispheric infarction after herpes zoster ophthalmicus. *J Neurol Neurosurg Psychiatry* 46: 786-788
11. Doyle PW, Gibson G, Dolman CL (1983) Herpes zoster ophthalmicus with contralateral hemiplegia: identification of cause. *Ann Neurol* 14: 84-85
12. McComas CF, Gutmann L (1982) Hemispheric infarction after herpes zoster ophthalmicus. *Neurology (NY)* 32: 914-915
13. Sato M, Nabeyama T, Ikeda H (1971) A case of herpes zoster encephalitis complicated by sensory aphasia and contralateral hemiparesis. *Clin Neurol* 11: 365-372
14. Walker RJ, El Gammal T, Allen MB (1973) Cranial arteritis associated with herpes zoster. *Radiology* 107: 109-110
15. Nishimaru K, Kamei H (1976) Herpes zoster ophthalmicus with contralateral hemiplegia. *Clin Neurol* 16: 649-653
16. Gilbert GJ (1974) Herpes zoster ophthalmicus and delayed contralateral hemiparesis. Relationship of the syndrome to central nervous system granulomatous angiitis. *JAMA* 229: 302-304
17. McCormick WF, Rodwitzky RL, Schochet SS, McKee AP (1969) Varicella-zoster encephalomyelitis. A morphologic and virologic study. *Arch Neurol* 21: 559
18. Nicolaides NV (1957) Fatal systemic varicella: a report of three cases. *Med J Aust* 2: 88-91

Received August 24, 1983