

Transient Neurologic Disturbances, Brain Tumors, and Normal Computed Tomography Scans

RUSSELL WALKER, MD,* ABRAHAM N. LIEBERMAN, MD,* RICHARD PINTO, MD,† AJAX GEORGE, MD,† JOSEPH RANSOHOFF, MD,‡ MAX TRUBEK, MD,§ AND ARLENE WISE, MA‡

During a 4-year period, four patients presented with transient disturbances in neurologic function that were diagnosed as seizures in two and transient ischemic attacks in the other two. Computed tomography (CT scan), both with and without contrast, was normal in all four patients. Isotopic brain scans (3 patients), cerebral angiograms (4 patients), and lumbar punctures (4 patients) were normal. Electroencephalograms (EEG) were normal in two patients and abnormal in two patients (consisting of focal slowing). Within 4.5 months, all patients developed symptoms and signs of a brain tumor, and in all four, CT scan now revealed a large mass lesion which at surgery was shown to be a malignant astrocytoma. These four patients constituted 4% of the total number of patients with malignant astrocytomas that were seen at the NYU Medical Center during this same time period. It is stressed that the CT scan may be normal early in the course of patients with brain tumors, particularly if they present with a transient disturbance in neurologic function. The first evidence of the tumor in such patients may be a slow-wave abnormality on the EEG. Patients who are suspected of having a brain tumor should, if the initial CT scan is normal, have the scan repeated later.

Cancer 52:1502-1506, 1983.

CONTRAST-ENHANCED computed tomography (CT scan) is the best method of diagnosing brain tumors. It is not generally appreciated, however, that the CT scan may be normal early in the course of a patient with a brain tumor, especially when the initial presentation of the tumor is that of transient neurologic disturbance (a seizure and/or a transient ischemic attack). This article reports our experience with four such patients.

Methods

Four patients, during a 4-year period of time (1977 to 1980), were referred to the New York University Medical Center (NYUMC) for evaluation of a transient neurologic disturbance. The initial CT scans in all four of these patients were normal, while repeat CT scans a few months later revealed large mass lesions that histologically were shown to be malignant astrocytomas.

From the Department of Neurology,* the Department of Radiology,† the Department of Neurosurgery,‡ and the Department of Medicine,§ New York University School of Medicine, New York, New York.

Address for reprints: Abraham N. Lieberman, MD, Professor of Neurology, NYU Medical Center, 530 First Avenue, Suite 5A, New York, NY 10016.

The authors thank the following individuals for their cooperation: Sun Hoo Foo, MD, Irvin Kricheff, MD, Joseph Lin, MD, Peter Pasternack, MD, Michael Ruoff, MD, and Edwin Weiss, MD; and Ms. K. Faridazar for help in preparing the manuscript.

Accepted for publication July 9, 1982.

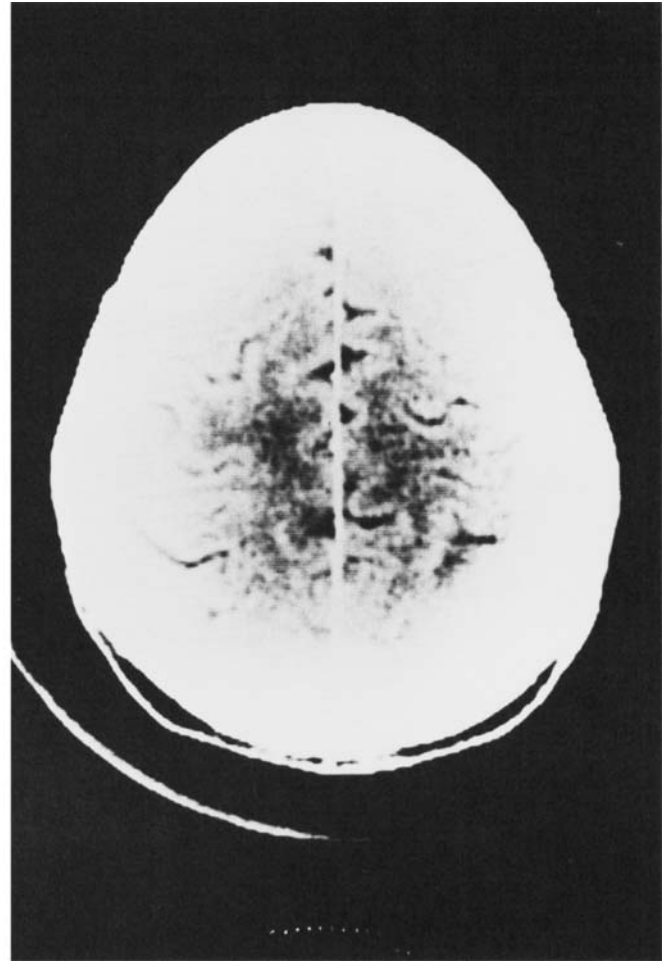
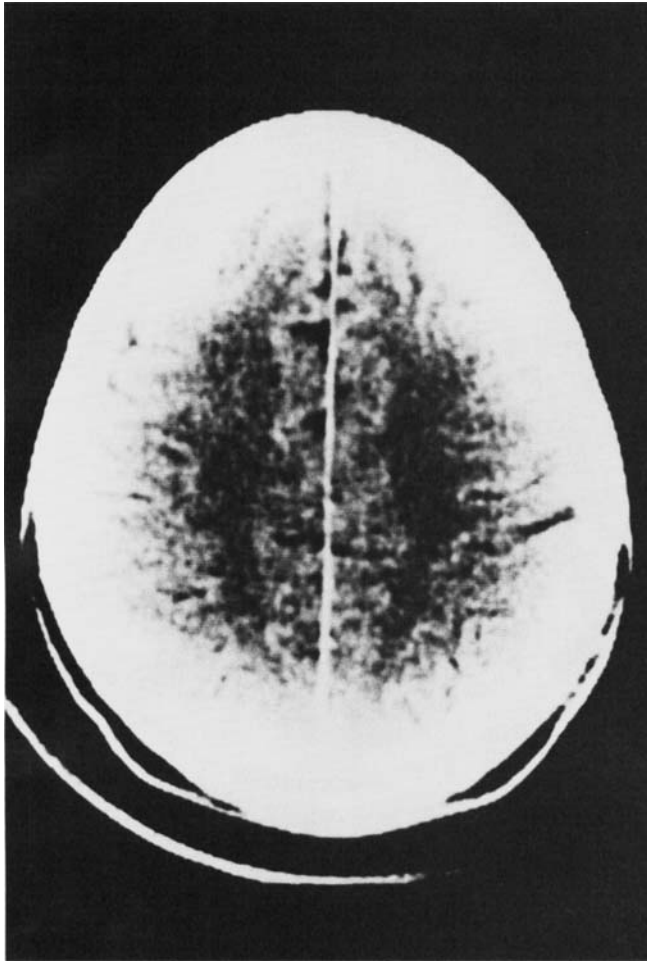
During the four years in which these patients were seen, a total of 162 patients with malignant astrocytomas were seen at the NYUMC. Thus, the four patients in this report constituted 4% of the total number of patients with malignant astrocytomas that were seen at the NYUMC.

Assessment consisted of a detailed physical, neurologic, and laboratory examination including a hemogram, random and fasting blood sugars, calcium, phosphorous, blood urea nitrogen (BUN), and serum creatinine. CT scans with and without a single dose of iodinated contrast were performed on an EMI head scanner Model #5005 (Cases 1, 3, and 4) or a General Electric CT/T scanner Model #8800 (Case 2). These scans were independently interpreted by two neuroradiologists (R.P.; A.G.). Electroencephalograms (EEGs) were performed on all patients and records were obtained with the patient awake, drowsy and asleep, and during hyperventilation and photic stimulation. Three patients had isotope (technetium-99m) brain scans, three patients had cerebral angiograms, and all four patients had lumbar punctures.

Case Reports

Case 1

A 38-year-old, right-handed man in previously good health and on no medication, suffered six generalized seizures within

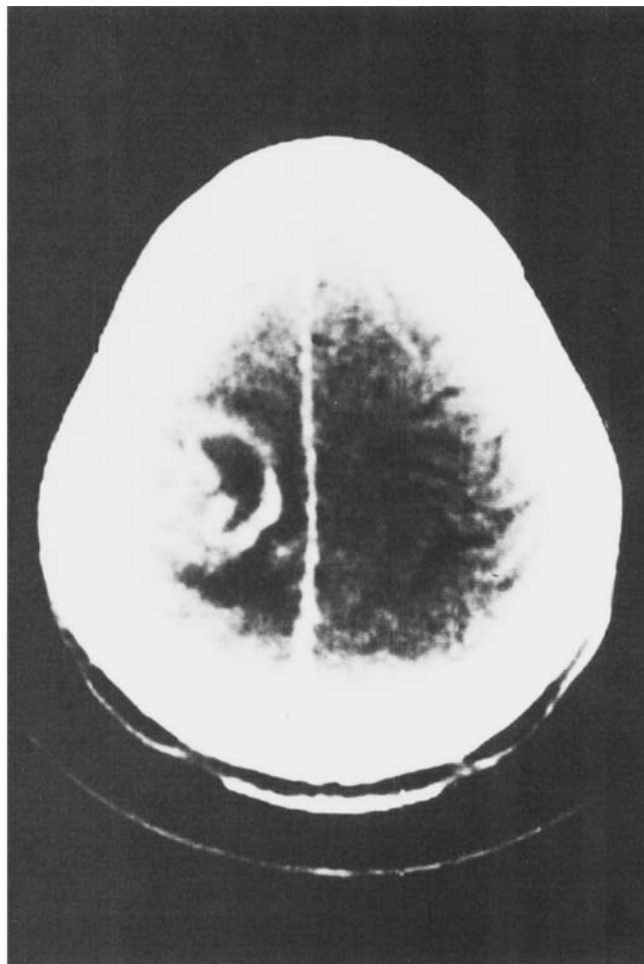
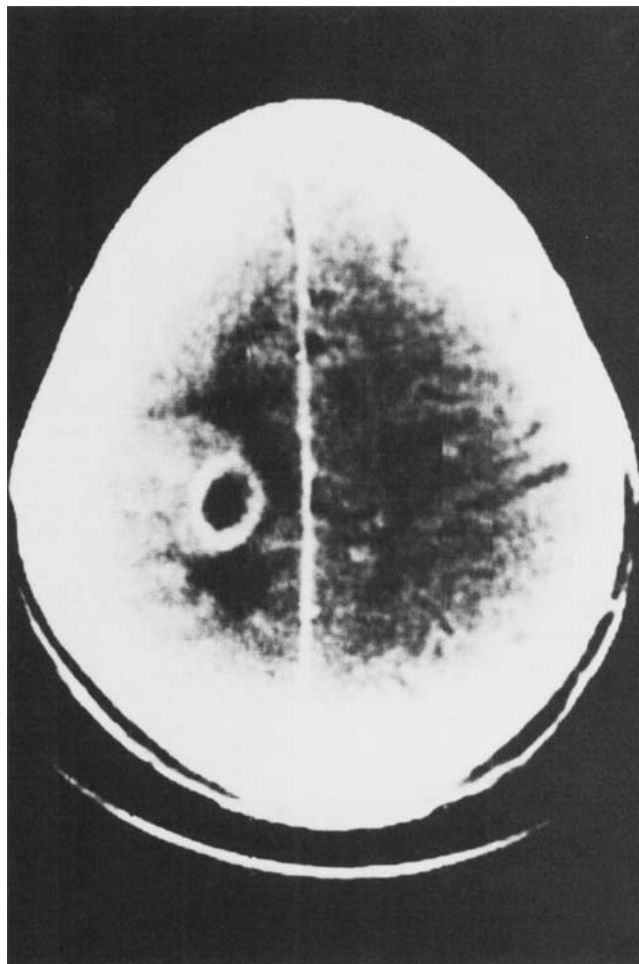


FIGS. 1A AND 1B. Upper cerebral convexity tomographic images utilizing a high-resolution GE CT/T scanner, Model #8800, after a single dose of iodinated contrast (Patient 2) reveals normal grey-white matter discrimination without distortion, effacement or obliteration of the cortical sulci.

24 hours and was admitted to the NYUMC. Physical and neurologic examination immediately after the last seizure revealed only postictal lethargy and confusion. CT scan with and without contrast, cerebral angiography and lumbar puncture were normal. An EEG, performed 24 hours later, revealed paroxysmal bursts of 2 to 4 hertz (Hz) slow waves, on the right. The patient was placed on phenytoin. Because of the occurrence of generalized seizures in a previously healthy adult and the presence of focal slowing on the EEG, the patient was regarded as a brain tumor suspect. Four months later, he returned complaining of headaches. Neurologic examination revealed a left facial weakness, increased left-sided deep tendon reflexes and papilledema. A CT scan now showed a large, non-uniformly enhancing mass lesion involving the right frontal lobe with a shift of midline structures. The mass at craniotomy (done by J.R.) was removed *in toto* and was shown to be an astrocytoma with marked anaplasia. The patient was treated with whole brain irradiation (6000 rads) and chemotherapy (nitrosoureas). The tumor recurred after 3 months and the patient again underwent a gross total removal of the tumor (done by J.R.). The tumor recurred again in 3 months, and the patient died shortly afterwards.

Case 2

A 61-year-old, right-handed man developed several episodes of tingling that began in his left hand and then spread to his left leg. The patient was admitted to a local hospital where neurologic examination, CT scan with and without contrast, EEG and isotope brain scan were normal. A diagnosis of a focal seizure disorder was made and the patient was placed on anticonvulsant medication. The patient was re-admitted to the hospital because of more episodes that included clonic movements of the left arm and leg. Repeat CT scan with and without contrast and isotope brain scan were normal. Adjustments were made in the patient's anticonvulsant medications and he was discharged. Despite adequate serum anticonvulsant levels, the patient continued to have left side of body focal motor seizures, and one month later he was re-admitted to the hospital. CT scan with and without contrast (Figs. 1A and 1B), isotope brain scan, lumbar puncture and cerebral angiography were normal. An EEG revealed intermittent 2 to 6 Hz slow waves over the right hemisphere. Further adjustments were made in the patient's anticonvulsant medications, but he continued to have left-sided focal seizures. Four months later, over a 2-week period of time,



FIGS. 2A AND 2B. Upper convexity tomographic images utilizing a high-resolution GE CT/T scanner after a single dose of iodinated contrast (Patient 2) reveals a large nonuniformly enhancing mass lesion with a necrotic center and surrounding edema.

he developed a left hemiparesis and was admitted to NYUMC. Computed tomography now revealed a moderate sized mass lesion with enhancing borders and a necrotic center involving the right frontoparietal region (Figs. 2A and 2B). One day later, the patient abruptly deteriorated and CT scan revealed hemorrhage into the tumor. At surgery (done by J.R.), the tumor was found to be a malignant astrocytoma with marked anaplasia. The patient was treated with whole brain irradiation and chemotherapy (nitrosoureas). The patient died 10 months later of recurrent tumor.

Case 3

A 75-year-old, right-handed woman was admitted to the NYUMC because of a loss of consciousness. On the day of admission, the patient noted that, while talking on the telephone, her speech was slurred. She then felt the ground spinning beneath her and lost consciousness. She was found on the floor 1 hour later by her husband who immediately brought her to the hospital, where she was noted to be awake, alert, rational, and coherent. There was a slight drift of the left arm, and nystagmus on both right and left lateral gaze. The re-

mainder of the examination was normal and the neurological deficit cleared within 24 hours. The patient was nondiabetic and nonhypertensive. Computed tomography with and without contrast, isotope brain scan, EEG, lumbar puncture, 24-hour Holter monitor and echocardiogram, were normal. A diagnosis of vertebrobasilar insufficiency was made and the patient was discharged. Four months later, while walking in the street, she again lost consciousness. Computed tomography at this time revealed a large nonuniformly enhancing mass lesion involving the right frontal lobe that was removed in toto at surgery, and was shown to be an astrocytoma with marked anaplasia. The patient was treated with whole brain irradiation (6000 rad) and nitrosoureas. The patient died of recurrent tumor in 6 months.

Case 4

A 54-year-old, right-handed woman presented with a 2-month history of episodic difficulty in speaking, each episode lasting a few minutes. The patient also complained of episodic difficulty in reading, each episode also lasting a few minutes. Examination at the time of admission to NYUMC revealed

only that the patient had subtle difficulty in word finding. Complete examination, including echocardiogram, 24-hour Holter monitor, skull series, EEG, lumbar puncture and CT scan both with and without contrast were normal. Cerebral angiography was normal. A diagnosis of cerebrovascular disease was made and the patient was placed on anti-platelet therapy. Six months later, the patient re-entered the hospital because of increasing difficulty with speech. Computed tomography now revealed a large irregularly enhancing mass lesion involving the left parietooccipital region that, at craniotomy (done by J.R.), was shown to be an astrocytoma with marked anaplasia. The patient was treated with whole brain irradiation (6000 rad) and nitrosoureas. The patient died of recurrent tumor 6 months later.

Neurologic Findings

Mean age of the four patients was 57 years (range, 38–75 years). The transient disturbances in neurologic function that were the presentation of the tumor in the first two patients were seizures. In the first patient, the seizures were generalized, but were associated with focal (right hemispheric) slowing on the EEG. In the second patient, the seizures were focal. Because of the occurrence of focal seizures (Case 2) or seizures associated with a focally abnormal EEG (Case 1) in previously healthy adults, both patients were regarded as brain tumor suspects. The disturbances in neurologic function that were the presentation of the tumor in the last two patients were initially diagnosed as transient ischemic attacks, although both of them lacked any of the major risk factors for stroke: diabetes, hypertension or heart disease. Indeed cerebral angiography carried out in one of them (Case 4) was free of extracranial or intracranial vascular disease. An alternative explanation is that the episodic disturbances in neurologic function in the last two patients may have been partial complex seizures rather than transient ischemic attacks.

All four patients had CT scans within 24 hours of their initial episode, and in all, the scans, even in retrospect, were normal. One patient (Case 2) had three separate normal-appearing scans. All four patients had EEGs shortly after their CT scans and the EEGs were abnormal in two patients (Cases 1 and 2) at what was later shown to be the site of the tumor. Three of the patients (Cases 1, 2, and 4) underwent cerebral angiography. The angiograms were normal in all three patients without evidence of extracranial or intracranial vascular disease. Isotope brain scans were performed in three patients (Cases 1, 2, and 4) and were normal. The mean time from the initial CT scan to the one showing the tumor was 4.5 months (range, 4–6 months). The CT scans showing the tumors were typical for malignant astrocytomas, consisting of moderate to large nonuniformly enhancing mass lesions with necrotic centers.¹

Two of the patients (Cases 1 and 4) developed progressive neurologic dysfunction after their initial transient disturbance in function: one patient (Case 3) had repeated transient disturbances in function, and one patient (Case 2) had repeated transient disturbances in function and then developed a progressive neurologic deficit. The location of the tumor was right frontal or frontoparietal in three patients (Cases 1, 2, and 3), and left parietooccipital in one patient (Case 4). The tumors were all malignant astrocytomas with moderate to marked anaplasia. Despite surgery, whole brain irradiation (6000 rad) and chemotherapy all four patients died within 10 months of the time the tumor was diagnosed.

Discussion

This study demonstrates that the CT scan may be normal early in the course of patients with brain tumors, particularly when the patients present with a transient disturbance in neurologic function, a seizure or an ischemic attack.² One explanation for this may be that only a few malignant cells are required to produce a seizure or a transient ischemic attack either by altering the metabolism or the blood supply of the surrounding brain tissue. Although the number of tumor cells may be too small to be detected by the CT scan, the metabolic or vascular alteration they produce may be detected by the EEG. Another explanation as to why the tumor might not be seen initially on the CT scan, is that in the beginning the tumor cells may be isodense with the surrounding brain tissue.

Several articles have appeared on the accuracy of the CT scanner in diagnosing intracranial tumors. Ambrose *et al.*³ reported being able to detect 96% of malignant gliomas without contrast administration, and 100% of these tumors with contrast administration; while Kendall *et al.*⁴ were able to detect 98% of malignant gliomas. The accuracy of the CT scanner in diagnosing malignant brain tumors is not in question, but the timing is of importance.^{2,5} Thus, as documented in this report, the tumor may initially present as a transient neurologic disturbance, may be too small to be seen, and yet a few months later may be highly visible. Such a scenario seems reasonable given the known facts about the rapid growth of malignant gliomas in man. Thus, the cell cycle time of malignant gliomas has been calculated by Hoshino and Wilson⁶ as approximately 7 hours and the time for the tumor to repopulate itself as 53 to 78 days. Furthermore, prior to the advent of high-voltage whole-brain irradiation and chemotherapy, it had been well known that a malignant glioma (Kernohan grade 3 or 4) removed *in toto* at surgery was likely to regrow to its original size within a 4- to 6-month period of time.^{7,8} Thus, the presence of a large mass lesion on a CT scan

4.5 months after the original normal scan is not surprising. Indeed in one of our patients (Case 1) after gross total removal of the tumor, the tumor grew back to its original size within 3 months despite irradiation and chemotherapy.

The first question that arises is: when a transient disturbance in neurologic function occurs and the CT is normal, when, if at all, should the CT scan be repeated: In the first two patients, both of whom were suspected of having a brain tumor, conventional plans based on what were then judged to be reasonable considerations, called for repeating the CT scan in 6 months to 1 year. In retrospect, given our current experience, and based on what is known about the growth rate of malignant gliomas, we would recommend, even in the absence of new symptoms, repeating the CT scan 4 months in patients who are suspected of having a brain tumor; and if the results negative, repeating it periodically thereafter. We emphasize that we do not make such a recommendation for all patients who have suffered a transient disturbance in neurologic function, but only for those who, because they had seizures, are suspected of having a brain tumor. Given the much lower incidence of malignant astrocytomas as compared to cerebrovascular disease, transient ischemic attacks are much more likely to be related to cerebrovascular disease than to malignant astrocytomas.^{9,10} Thus, it would be unreasonable to recommend periodically rescanning every patient who has had a transient ischemic attack on the assumption that a small percentage of these patients might harbor tumors. Nonetheless, among patients who are having repeated ischemic episodes (Case 4) and who are without risk factors for vascular disease, the suspicion should be entertained that the patient could have a tumor.¹¹

It should be emphasized that, at the time of this investigation, all of our patients were scanned after a single dose of iodinated contrast; three were scanned on the EMI head scanner, while one was scanned on the new high-resolution General Electric CT/T scanner. It is thus conceivable, although we think not likely, that a small lesion that was not detected on the EMI scanner, might have been detected on the high resolution scanner, especially after a double dose of iodinated contrast. Parenthetically, we should add that only in patients who are strongly suspected of having a brain tumor do we recommend a double dose of iodinated contrast.

It may be pertinent to ask what value there is in making an early diagnosis of malignant glioma given the limitations of the treatment that is currently available.¹² We would answer this question by pointing out the rapid strides that are being made in the treatment of many systemic malignancies where early diagnosis is important in influencing outcome. We would fully expect that the same principles will apply to malignant gliomas.

The final question that arises is: At what point does a patient who suffers a transient neurologic disturbance, has a normal CT scan and is suspected of having a brain tumor cease being a tumor suspect? This question cannot be answered from the current study. However, given our current knowledge on the growth of malignant brain tumors, it would appear reasonable, in the absence of new symptoms, to obtain CT scans periodically on such patients for up to 2 years.

ADDENDUM

Since this article was accepted an article making similar points has appeared. Wulff JD, Proffitt PQ, Panszl JG, Ziegler DK. False-negative CT in astrocytoma: The value of repeat scanning. *Neurology (NY)* 1982; 32:766-769.

REFERENCES

1. Butler AR, Horli SC, Kricheff II. Computed tomography in astrocytoma. *Radiology* 1978; 129:433-439.
2. Tentler RL, Palacios E. False-negative computerized tomography in brain tumor. *JAMA* 1977; 238:339-340.
3. Ambrose J, Gooding MR, Richardson AE. An assessment of the accuracy of computerized transverse axial scanning (EMI scanning) in the diagnosis of intracranial tumor. *Brain* 1975; 98:569-582.
4. Kendall BE, Jakubowski J, Pulicino P. Difficulties in diagnosis of supratentorial gliomas by CAT scan. *J Neurol Neurosurg Psychiatr* 1979; 47:485-492.
5. Steinhoff H, Grumme TH, Kazner E. Axial transverse computerized tomography in 73 glioblastomas. *Acta Neurochir (Wien)* 1978; 42:45-56.
6. Hoshino T, Wilson CB. Cell kinetic analysis of human malignant brain tumors (gliomas). *Cancer* 1979; 44:956-962.
7. Frankel SA, German WJ. Glioblastoma multiforme. *J Neurosurg* 1958; 15:489-503.
8. Matuskado Y, MacCarty CS, Kernohan JW. The growth of glioblastoma multiforme (astrocytomas, grades 3 & 4) in neurosurgical practice. *J Neurosurg* 1961; 18:636-644.
9. Dyken ML, Conneally PM, Haerer AF. Cooperative study of hospital frequency and character of transient ischemic attacks. *JAMA* 1977; 237:882-886.
10. Weisberg LA, Nice CN. Intracranial tumors simulating the presentation of cerebrovascular syndromes. *Am J Med* 1977; 63:517-524.
11. Lin JP, Siew FP. Glioblastoma multiforme presenting angiographically as intracranial atherosclerotic vascular disease. *Radiology* 1971; 101:353-354.
12. Lieberman A, Ransohoff J. Treatment of primary brain tumors. *Med Clin North Am* 1979; 63:835-848.