

Pure "aphasic" agraphia due to damage of the left superior parietal lobule.

Paolino E., De Bastiani P., Monetti V.C., Boldrini P., Rosati G.*

Clinica Neurologica Università di Ferrara e Clinica Neurologica Università di Sassari.*

A case of pure agraphia, due to an ischaemic lesion of the left superior parietal lobule, is reported. The neuropsychological analysis of writing performances suggests an aphasic nature of this patient's pure agraphia. The authors discuss the role played by diffuse and/or localized brain lesions in writing function, emphasizing that the left superior parietal lobule in man may be crucial for the sensorimotor linguistic integration needed for writing.

Key-Words: agraphia

Introduction

Pure agraphia, that is a selective disorder of writing which arises without disturbances in oral language, reading, praxis or in graphomotor functions, has rarely been described in the literature. The question of the localization of the brain lesion responsible for it is still under discussion. In the hypothesis advanced by Chedru and Geschwind [5], after an analysis of the published cases, this disorder may be attributed to diffuse brain lesions which may cause confusional states with reduction and/or shifting of attention. On the other hand, some observations suggest that pure agraphia may be the result of isolated focal brain damage which involves different areas of the left hemisphere: the second and third frontal gyri [1, 7, 10, 12], the superior parietal lobe [3, 4], the temporal lobe [11], the region of the caudate nucleus and the anterior crus of the internal capsule [8]. In recent years, the assumption of a specific centre for writing in the second and third frontal convolution ("Exner's writing centre") has been rejected [5, 9]. On the contrary, a considerable role is attributed to the left superior parietal lobule which is supposed to be essential for the sensorimotor

linguistic integration needed for writing [4].

We describe a case of pure agraphia due to an ischaemic lesion involving this area.

Case report

A 66-year-old, right-handed tradesman, with a grade school certificate, was in good general health until one week prior to admission when he began to complain of diffuse headache. Six days afterwards, attempting to invoice the goods ordered by a customer, he realized he was writing scrawls. Further attempts to write correctly failed and the next day he was admitted to the Neurological Clinic of Ferrara University.

On admission, general medical examination showed no abnormality. On mental status assessment, he was alert and fully oriented in time, space and person. Judgement and memory, both for new and old events, were found to be unimpaired. Pupils, visual acuity, and visual fields, as well as fundi and ocular movements were all normal. The other cranial nerves were intact. The remainder of the neurological examination disclosed no abnormality, except for slight

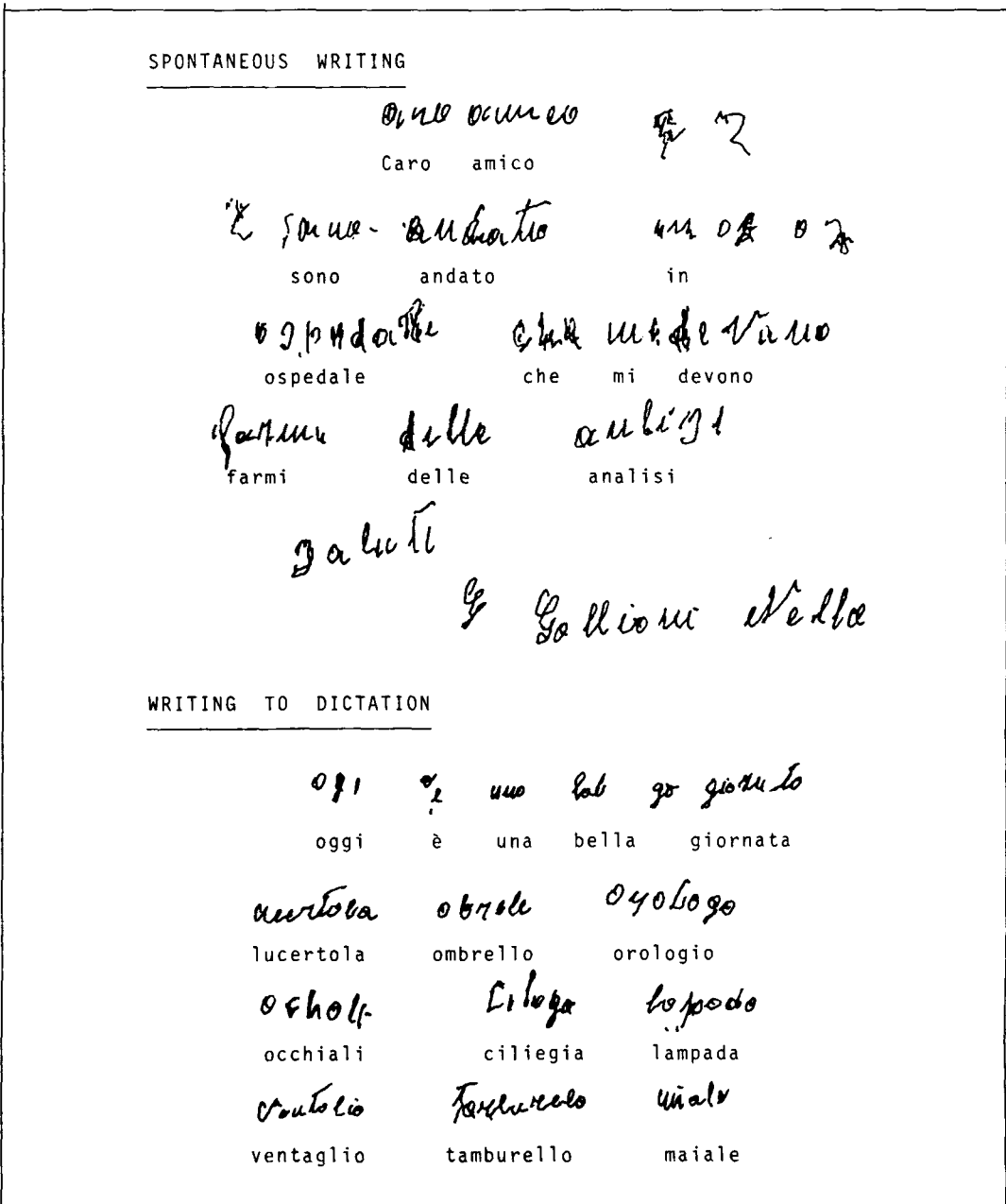


Fig. 1. Examples of spontaneous writing and writing to dictation showing paraphasias and neologisms.

increase of deep reflexes in the right limbs. A neuropsychological examination was carried out the day after admission. Intelligence and reasoning capabilities tested by WAIS were normal according to age educational level (IQv: 89,

IQp: 80 with the low score on Digit Symbol subtest, IQfs: 84), as well memory tested by WMS (MQ: 80). Word fluency was normal and finger naming, right-left orientation, calculation and stereognosis were unaffected. No impair-

ment was found in the tests for the apraxias such as oral (imitation of buccofacial gestures), ideomotor (imitation of intransitive upper limb gestures); constructional (copying geometrical drawings), and use praxis (showing the use of actual objects). On the Token Test the patient scored 29 out of 36. The Language Test (Copyright Association for Development of Neuropsychological Research, Milan 1974) disclosed no abnormalities in spontaneous speech, repetition, comprehension, denomination and reading, while impairment of writing was striking. Examples of spontaneous writing and writing to dictation are shown in Fig. 1. Omissions and substitutions of letters in a word, transposition and repetition of words in a sentence were present. The first or last syllables of a word were often omitted. Occasionally he would omit an entire word. Paragraphias and neologisms occurred in one sentence. In both spontaneous writing and writing to dictation he made mistakes, whereas when he was asked to spell orally the same words he could usually do so correctly. No difference was found in writing concrete and abstract words or in writing short and long letter strings, although an increase in the rate of errors was detected in writing non-words. Ability to write numbers to dictation was preserved as long as they did not exceed three figures; above this level, some minor mistakes were made. Reproduction of a printed text was relatively conserved and not "imitative". Transcription of capital letters into lower case was correct about 70% of the time. Forming words and short sentences with alphabet blocks on command was better than spontaneous writing, although not without errors.

The patient was always aware of his mistakes, which caused reactions of despair.

An electroencephalogram showed a discontinuous focal disturbance in the region of the left parietal lobe and a CT scan a small hypodense lesion in the left superior parietal lobule (Fig. 2 A, B, C). The CT-anatomical correlation was made by using the criteria suggested by Takayoshi et al. [13].

He was discharged after two weeks. In the course of the following months the patient's visits to the Neurological Clinic were frequent and regular. On these occasions, it was consistently observed that no appreciable change occurred in his neuropsychological test scores, although his writing problems did show a slight tendency to improve.

Discussion

In the case reported here, there is clinical evidence of a condition of agraphia without asso-

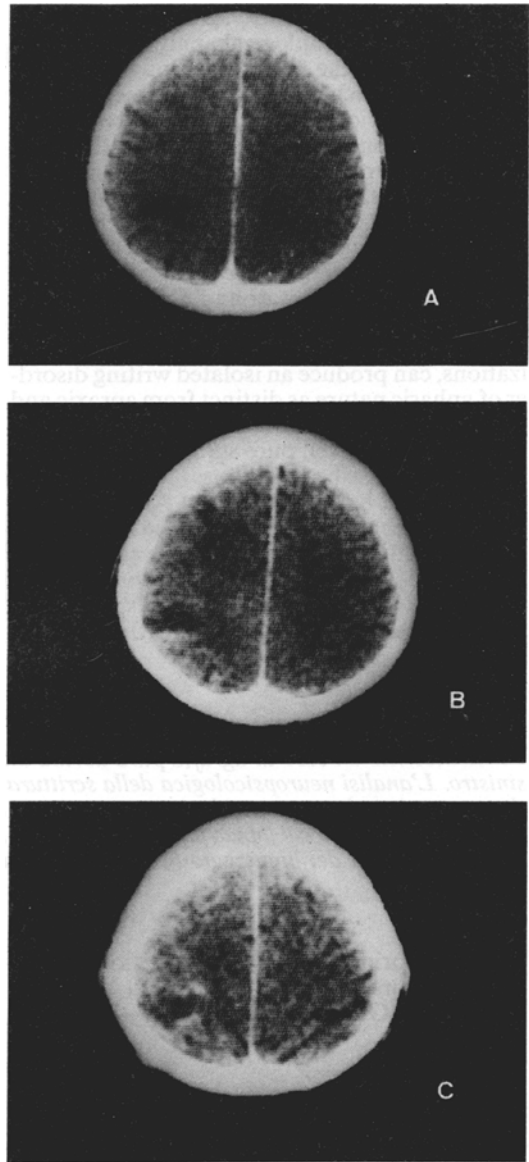


Fig. 2 A, B, C. Three successive computed tomographic scans with contrast enhancement showing a small hypodense lesion in the left superior parietal lobule.

ciated aphasic, apraxic, spatial or graphomotor disorders.

On the basis of the particular writing components which are disturbed, various clinical forms of agraphia have been described [9]. In our patient, initially, the disruption of writing was so serious that he was able to write only scrawls or loops; therefore, the writing disorder might

be classified as "apraxic" agraphia. Nevertheless, the neuropsychological analyses of writing performed over the following days showed linguistic errors such as paraphasias, neologisms, graphemic elisions, and reiterated attempts at correction (*conduites d'approche*), without associated disorders in the visuospatial arrangement of letters, words and lines. These findings, in our opinion, might suggest a selective disorder of the language output and, thus, the aphasic nature of this patient's pure agraphia similar to those reported by Rosati and De Bastiani [11] and Laine and Marttila [8], who have suggested that a focal brain damage, even in various localizations, can produce an isolated writing disorder of aphasic nature as distinct from apraxic and spatial agraphias. In Chedru and Geschwind's opinion [5], however, pure agraphia may be produced by diffuse brain lesions. It would seem to be confirmed by the findings of Assal et al. [2], who have proposed that an isolated writing disorder might be the result of a conjunction between a state of general intellectual impairment and a selective deficiency corresponding to a more localized damage, and furthermore by

Dubois et al. [6], who have emphasized the importance of the decrease in intellectual capabilities present in four out of their six patients.

In our patient, the CT scan demonstrated an ischaemic lesion in the left superior parietal lobule, without any other signs of diffuse brain damage and, furthermore, no impairment of intellectual functioning was disclosed by WAIS and WMS. Basso and co-workers [4] have advanced the hypothesis that the left superior parietal lobule in man may be "crucial for the sensorimotor linguistic integration needed for writing". The present case would seem to confirm that this area plays a role in writing, but, in our view, additional information is needed before drawing conclusions on the nature of this role. In fact, some authors [8, 11] have described cases of pure agraphia, clinically indistinguishable from ours, in which the left superior parietal lobule is spared. Accordingly, although pure agraphia is more often the result of a localized brain lesion, we are led to conclude that it has no localizing value.

Sommario

Viene descritto un caso di agrafia pura dovuta ad una lesione ischemica del lobulo parietale superiore sinistro. L'analisi neuropsicologica della scrittura indica la natura afasica di tale disordine. Gli autori discutono il ruolo rivestito da lesioni cerebrali diffuse e/o localizzate nei processi della scrittura, sottolineando quello del lobulo parietale superiore sinistro, ritenuto un importante punto di integrazione sensorio-motoria del linguaggio necessaria per tale funzione.

Address reprint requests to: Dr. Ezio Paolino
Clinica Neurologica dell'Università,
Corso della Giovecca 203, 44100 — Ferrara

References

- [1] AIMARD G., DEVIC M., TROUILLAS P. and BOISSON D.: *Agraphie pure (dynamique?) d'origine frontale. A propos d'une observation*. Rev. Neurol. (Paris) 131: 505-512, 1975.
- [2] ASSAL G., CHAPUIS G. and ZANDER E.: *Isolated writing disorders in a patient with stenosis of the left internal carotid artery*. Cortex, 6: 241-248, 1970.
- [3] AUERBACH S.H., ALEXANDER M.P.: *Pure agraphia and unilateral optic ataxia associated with a left superior parietal lobule lesion*. Journal of Neurol. Neuros. and Psych. 44: 430-432, 1981.
- [4] BASSO A., TABORELLI A., VIGNOLO L.A.: *Dissociated disorders of speaking and writing in aphasia*. Journal of Neurol., Neuros. and Psych. 41: 556-563, 1978.
- [5] CHEDRU F., GESCHWIND N.: *Writing disturbances in acute confusional states*. Neuropsychologia 10: 343-353, 1972.
- [6] DUBOIS J., HÉCAEN H., and MARCIE P.: *L'agraphie "pure"*. Neuropsychologia 7: 271-286, 1969.
- [7] HEHSCHEN E.S.: *Klinische und anatomische Beiträge zur Pathologie des Gehirnes*. VII. Über motorische Aphasie und Agraphie. E.S. Henschel, Stockholm, 1922.
- [8] LAINE T., MARTTILA R.J.: *Pure agraphia: a case study*. Neuropsychologia 19: 311-316, 1981.
- [9] LEISCHNER A.: *The agraphias*. In Vinken P.J. and Bruyn G.W. (Eds): *Handbook of Clinical Neurology*. North Holland: Amsterdam, 4: 141-180, 1969.
- [10] MAHOUDEAU D., DAVID M., LECOEUR J.: *Un nouveau cas d'agraphie sans aphasie révélatrice d'une tumeur métastatique du pied de la deuxième*

- circonvolution frontale gauche. Rev. Neurol. (Paris) 1: 159-161, 1951.*
- [11] ROSATI G., DE BASTIANI P.: *Pure agraphia: a discrete form of aphasia. Journal of Neurol., Neuros. and Psych. 42: 266-269, 1979.*
- [12] SINICO S.: *Neoplasia della seconda circonvoluzione frontale sinistra: agrafia pura. Gazzetta degli Ospedali e delle Cliniche (Milano) 47: 627-631, 1926.*
- [13] TAKAYOSHI MATSUI et al.: *Anatomical and pathological study of the brain by CT scanner-1: anatomical study of normal brain. Computerized Tomography 1: 3-43, 1977*