

Bilateral TIAs and unilateral seizures due to orthostatic hypotension. A case report.

Landi G.*, Perrone P.**, Guidotti M.*

*Clinica Neurologica II, Università degli Studi di Milano

** Divisione di Neurologia, Ospedale Civile di Busto Arsizio

After a reversible right hemispheric stroke, a patient with bilateral carotid occlusion developed left motor seizures and bilateral TIAs, both triggered by orthostatic hypotension.

A CT-scan showed a right frontal hypodense area.

Hemodynamic factors may cause focal seizures in patients with cortical lesions.

Key-Words: TIA — orthostatic hypotension

Introduction

Although partial seizures are relatively frequent in cerebrovascular patients [1], they are not regarded as TIAs in the absence of other symptoms [2]. Actually, most of these fits are due to the presence of epileptogenic lesions of the brain parenchyma. However, in patients with stenosis or thrombosis of the carotid artery, a hemodynamic [3] or embolic [4] pathogenesis has been suggested. We report the case of a patient with pre-existing cortical lesion that supports this possibility.

Case Report

A 60-year-old man suddenly developed a left hemiparesis which resolved completely within a week. He was hypertensive and was treated with alpha-methyldopa 250 mg bid. Ten months later he began to have focal motor seizures which started from the left hand spreading to the ipsilateral limbs. The seizures occurred several times a month, always when the patient was standing; treatment with diphenylhydantoin did not reduce their frequency, despite a serum level of 14.5 mcg/ml.

After one year the patient began to present also

TIAs, sometimes with aphasia and right hemiparesis, at other times with left hemiparesis. They too developed only when the patient was standing.

On admission, neurological examination was negative. An EEG showed diffuse slowing with rhythmic sharp waves on the right hemisphere.

A CT-scan (Fig. 1.) demonstrated a right frontal hypodense area involving the cortex and the white matter. Cerebral angiography revealed thrombosis of both internal carotid arteries near the origin, a 50% stenosis of the right external and a 30% stenosis of the left common carotid arteries.

Methyldopa and diphenylhydantoin were stopped and aspirin and phenobarbital (200 mg/day) were administered. Blood pressure (BP) ranged from 170/100 to 250/120; however, in the standing position a BP of 90/50 — 100/60 was sometimes reported. During his hospital stay the patient had several episodes both of TIA and of left motor seizures, occurring either when he passed from the recumbent to the standing position, or when he was already standing. During four TIAs and two focal seizures the BP was taken, and it was always lower than 100/70.

Without any hypotensive treatment, the BP pro-

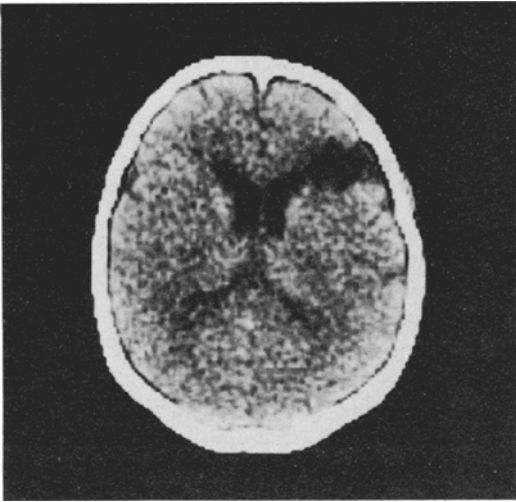


Fig. 1. CT-scan of the right frontal hypodense area.

gressively became normal, and no further hypotensive episodes occurred. Phenobarbital was continued, with a serum level of 22 mcg/ml. During the following year the patient had only

one TIA with left hemiparesis lasting 6 hours. Seizures did not recur.

Comment

In our patient marked decreases of the BP, probably caused by loss of baroreceptor mechanisms and by antihypertensive therapy, triggered both focal seizures and episodes of right and left hemiparesis. His symptoms disappeared as soon as orthostatic hypotension improved. Although focal inhibitory seizures may mimic the clinical appearance of TIAs [5], the occurrence of bilateral attacks of transient neurological dysfunction in a patient with thrombosis of both internal carotid arteries pointed to focal ischemia as the pathogenetic mechanism.

However, focal seizures involved only the left limbs, thus raising the possibility that hypotension was sufficient to cause TIAs, but the additional presence of a structurally abnormal cortical area was necessary to trigger epileptic discharges, as already suggested by other authors [3, 6].

In this case, although both kinds of episodes were due to transient focal ischemia, partial seizures should be distinguished from TIAs which do not require a permanent pathological substratum.

Riassunto

Dopo un attacco ischemico reversibile in emisfero destro, un paziente con occlusione carotidea bilaterale presentò crisi epilettiche focali motorie agli arti di sinistra e TIA bilaterali, entrambi scatenati da ipotensione ortostatica.

Una TAC dimostrò un'area ipodensa frontale destra.

Fattori emodinamici possono provocare crisi epilettiche focali in pazienti con lesioni corticali.

Address reprint requests to: Dr. Gianluca Landi
Clinica Neurologia II Università degli Studi di Milano
Ospedale Policlinico
Via F. Sforza 35 20122 Milano

References

- [1] COCITO L., FAVALE E., RENI L.: *Epileptic seizures in cerebral arterial occlusive disease*. Stroke 13, 189-195, 1982.
- [2] HEYMAN A., LEVITON A., MILLIKAN CH et al: *Transient focal cerebral ischemia. Epidemiological and clinical aspects*. Stroke 5, 277-287, 1974.
- [3] RILEY TL., FRIEDMAN JM.: *Stroke, orthostatic hypotension, and focal seizures*. JAMA 245, 1243-1244, 1981.
- [4] JOYEUX O., AIMARD G., GOUTELLE A., COUVION J., PERRAUDON C.: *Athérome carotidien segmentaire et épilepsie*. Neurochirurgie 17, 217-224, 1971.
- [5] GLOBUS M., LAVI E., FICH A., ABRAMSKY O.: *Ictal hemiparesis*. Eur Neurol 21, 165-168, 1982.
- [6] DODGE P.R., RICHARDSON EP., VICTOR M.: *Recurrent convulsive seizures as a sequel to cerebral infarction: a clinical and pathological study*. Brain 77, 610-638, 1959.