

Repeated Self-induced Syncope and Subsequent Seizures

A Case Report

Chi-Wan Lai, MD, Dewey K. Ziegler, MD

● A patient with an unusual "compulsion" to induce syncope over a period of years by bilateral compression of the carotid arteries subsequently had recurrent seizures. The EEG showed patterns typical of cerebral ischemia during the syncope and epileptogenic foci in both temporal lobes after sleep deprivation. It is difficult to distinguish between seizure and syncope associated with involuntary movements when making a differential diagnosis. We hypothesize that the frequent self-induced ischemic insult to the brain caused a cicatrix to develop, which in turn caused the frequent seizure disorder; and that because this ischemia functioned as a stimulus to the reward site in the limbic system, the patient repeatedly induced it.

(Arch Neurol 1983;40:820-823)

Habitual self-induced syncope by bilateral compression of carotid arteries has never before been reported to our knowledge. We describe a patient who indulged in this practice at extremely frequent intervals over a period of six years. Spontaneous, recurrent typical complex partial seizures and generalized convulsions then developed. The EEG disclosed epileptiform abnormalities in the temporal lobes.

REPORT OF A CASE

A 21-year-old woman was first examined at the age of 20 years because she had experienced a generalized tonic-clonic convulsion with urinary incontinence. Results of physical and neurologic examinations at that time were normal, as were results of blood chemistry tests, VDRL, ECG, CSF examination, and a computed tomographic scan of the head. Routine EEG taken on waking and sleeping was normal, but an EEG with nasopharyngeal leads taken after sleep deprivation revealed frequent paroxysmal focal spikes in the temporal lobes, predominantly on the right side (Fig 1). Phenobarbital sodium (90 mg at bedtime) was prescribed. The patient had more episodes of nocturnal grand mal, probably because of noncompliance with the use of her medication; she was subsequently referred to the Neurology Department

of the University of Kansas Medical Center, Kansas City.

The patient had an unusual history. At age 14 years, she discovered that if she pressed both sides of her neck, she could produce an altered state of consciousness that was pleasurable to her. She had become so "addicted" to this habit that she performed the act several times a day, sometimes up to once every five to ten minutes while she was home. On several occasions she noted that the act would cause kicking movements of her legs or jerking movements of her arms or body, followed by confusion, or rarely, by total blackout. There was no urinary incontinence, focal weakness, or numbness; but after the spell, there was generalized fatigue and sleepiness. The act was usually performed while the patient was sitting. Occasionally, after successive spells occurring within a short period, the woman became extremely confused and then compressed her neck while standing. This sequence ended with her falling to the floor and sustaining physical injury. She had a long history of abuse of alcohol and multiple illegal drugs.

A simultaneous EEG/ECG recording was performed with the patient's consent. Unilateral light massage or compression of

the carotid sinus was performed on either side, but failed to change the EEG or ECG recording. The patient then performed her habitual maneuver. While sitting, she brought her right hand to the anterior neck area, thumb firmly pressing the left side, and the other four fingers simultaneously pressing the right side of the neck. The patient also appeared to be holding her breath and performing Valsalva's maneuver. Within 14.5 s, she began to exhibit twitching facial muscles, blinking eyes, and myoclonic jerks of the arms and a rhythmic falling forward of the head, accompanied by a momentary lapse of consciousness. Her hand dropped and she appeared dazed with a vacant stare, suggesting pained perplexity. Within a few seconds, she regained full consciousness. The EEG showed generalized, high-voltage, 2.5- to 3.0-Hz delta activities within 14.5 s of the compression, which were coincidental with the clinical manifestation of muscle jerking and lapses of consciousness. The EEG slowing lasted for 24 s, with a rapid return to the normal baseline. No ECG change or epileptiform abnormality was noted during or preceding these spells (Fig 2). On two occasions during the recording, the patient clearly performed Valsalva's maneuver for more than

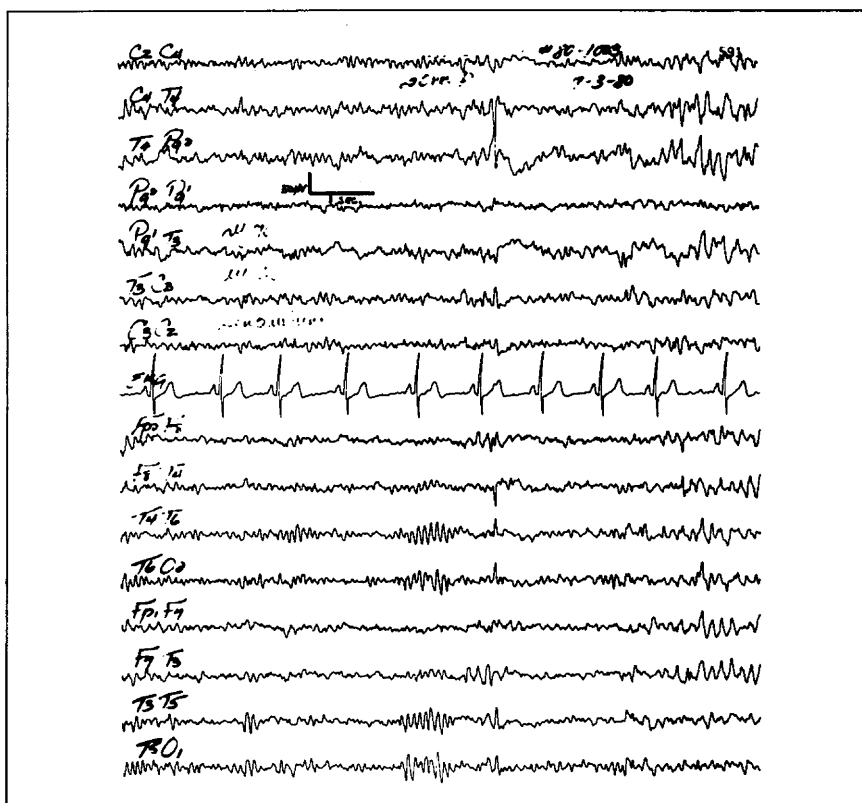


Fig 1.—EEG recording after sleep deprivation shows focal paroxysmal spikes at T₄.

Accepted for publication Dec 28, 1982.

From the Neurology Department, University of Kansas Medical Center, Kansas City.

Reprint requests to Neurology Department, University of Kansas Medical Center, 39th at Rainbow Boulevard, Kansas City, KS 66103 (Dr Lai).

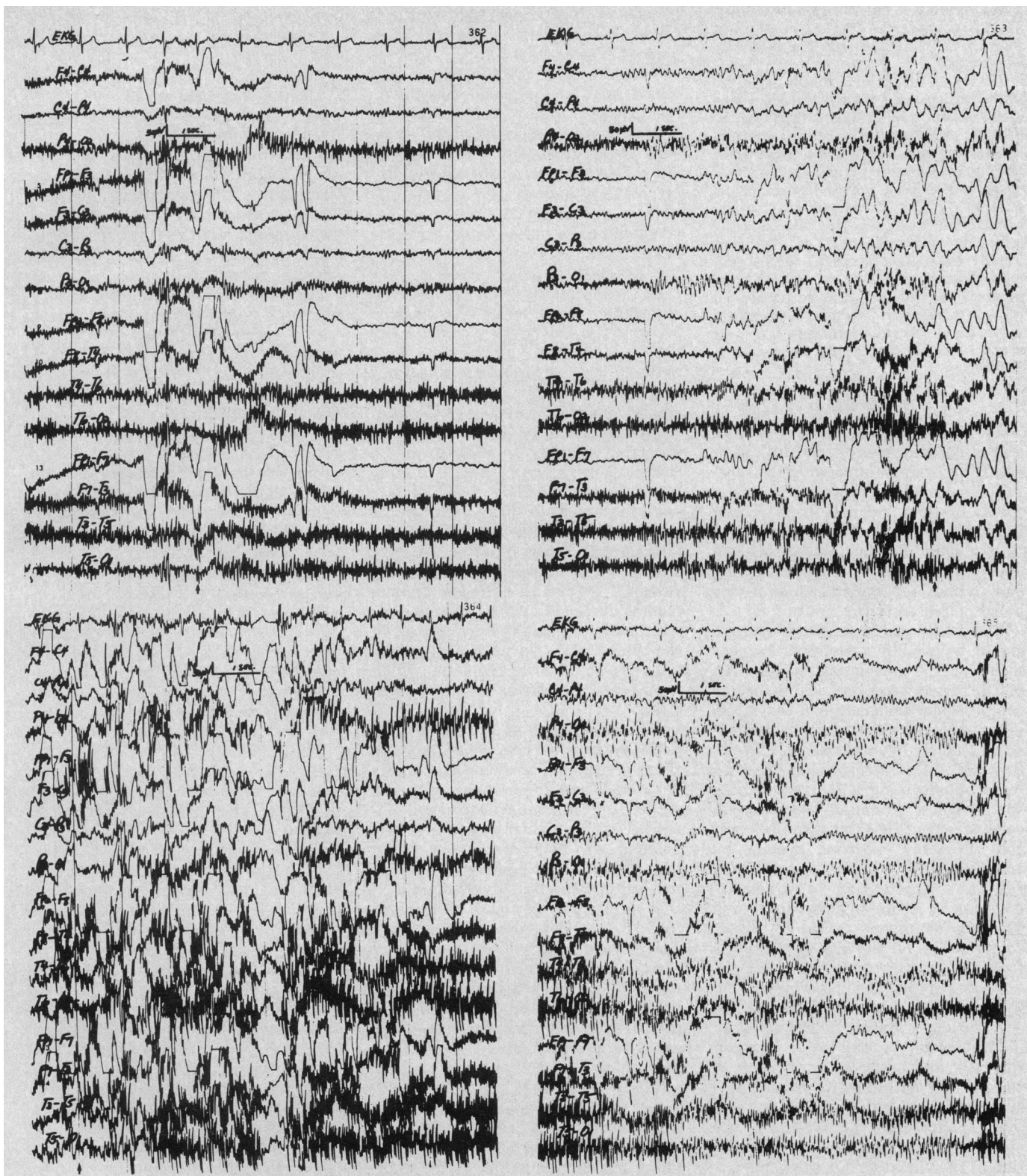


Fig 2.—Continuous ECG/EEG tracings, each lasting for 10 s. Top left, EEG immediately after compression (arrow) shows artifacts of electromyogram and eye blinking without any significant ECG or EEG change. Top right, At arrow, 14.5 s after compression, EEG reveals generalized high-voltage 2.5- to 3.0-Hz delta activities, coincidental with clinical manifestation of muscle jerking and lapse of consciousness. Bottom left, Arrow indicates when patient's hand dropped and she appeared dazed with vacant stare, suggesting pained perplexity. Bottom right, EEG spontaneously recovers to normal alpha rhythm. Throughout tracing, no ECG change was found.

20 s without carotid compression. This act failed to produce the subjective "pleasurable" sensation, the motor phenomenon, and the EEG changes seen during carotid compression.

The risk of this habit was fully explained to the patient, and treatment with a psychotherapist was arranged. The patient initially was reluctant to take an anticonvulsant regularly for seizure prophylaxis. During a follow-up period, she reported episodes of déjà vu, followed by confusion, features typical of complex partial seizures. She also reported experiencing occasional nocturnal grand mal seizures. Finally, the patient consented to take phenobarbital sodium (100 mg at bedtime) regularly, and she has had no seizures in the last six months. She also has stopped indulging in the habit for the last nine months and has had no further syncopal episodes.

COMMENT

Syncope is defined as a transient loss of consciousness of abrupt onset, resulting from an impairment in cerebral metabolism. Such an impairment, in turn, results from a brief interruption of the cerebral circulation or from the shortage of required energy substrates, ie, glucose and oxygen, which are constituents of the blood delivered to the brain.¹

In healthy young subjects, syncope can be induced by a variety of mechanisms: (1) by mechanical stimulation of the vagal receptors, using ocular compression² or massage of the carotid sinus,^{3,4} with resultant reflex cardiac arrest or hypotension; (2) by an increase in the intrathoracic pressure (eg, by performing Valsalva's maneuver), with a secondary decrease in cardiac output^{5,6}; (3) by stimulation of the autonomic nervous system by emotional or painful stimuli, with resultant hypotension or bradycardia⁷; (4) by acute hypoxia in a low-pressure chamber⁸; or (5) by direct compression of the carotid arteries from the surface of the neck.⁹

Interestingly, the experiments by Rosen et al⁹ are closely analogous to our patient's habit. They used an inflatable cuff on the lower third of the neck and produced a pressure of 600 mm Hg within 0.125. After acute arrest of the carotid circulation for 5 to 10 s, they observed fixation of the eyeballs, blurring of vision, constriction of the visual field, and within 6 s, loss of consciousness, and after 8 s, anoxic convulsion. As the subject became unconscious, the pressure cuff was deflated; the subject would then spontaneously recover. The fact that our patient experienced convulsive syncope with the presumed occlusion of only the carotid arteries supports the proposition of Gastaut and Fischer-Williams: that such syncope

is due to the liberation of tonogenic centers of the pontobulbar reticular formation from telencephalic and diencephalic centers.²

The striking involuntary movements that accompanied syncope in our patient are an uncommon, but well-known, manifestation of transient global cerebral ischemia. Duvoisin noted that brief duration, rapidity of recovery, and absence of postictal phenomena are reliable clues for distinguishing syncope from epileptic seizures⁵; yet some epileptic seizures, for example, absence, can be very brief without postictal phenomena. Myoclonic jerks or tonic spasms occurring in this setting occasionally make it difficult to differentiate between syncope and seizure. Gastaut and Fischer-Williams found that generalized clonic convulsions of the typical grand mal type were not seen in syncopal attacks.² In a study of 35 cases of convulsive syncope among blood donors, however, two patients were observed to have only clonic movements for three to five beats, and another two were reported to have tonic spasms followed by clonic convulsions.¹⁰ When an EEG can be performed during clinical symptoms, differentiation is usually easy because of the typical slow waves of diffuse distribution in cerebral ischemia, which were noted as early as 1942 by Foster et al.³

Whether there is a relationship between true seizure disorders and the susceptibility to syncope is highly debated. Whether some or all patients subject to recurrent syncope have other EEG abnormalities as well is also debated. In 1949, Kershman found that 65% of 114 patients with syncope had diffuse cerebral dysrhythmia in the interictal period.¹¹ O'Doherty found, in 1953, paroxysmal slow, sharp wave activity in five cases of tussive syncope, which he thought was an epileptic phenomenon.¹² In 1958, Lloyd-Smith and Tatlow reported a case of syncope that was induced by venipuncture in a patient whose EEG changes and clinical phenomena were strongly suggestive of a seizure.¹³ When pentylentetrazol activation was used to study seizure threshold, the lowest threshold to the drug was found in epileptic subjects, the highest threshold in control subjects, and a threshold close to those with seizure disorders in patients with syncope.¹⁴

The coexistence of syncope and seizure is generally rare. Gastaut¹⁵ found in his three-year study of patients with loss of consciousness, with or without convulsion, 417 cases of syncope, 377 cases of epilepsy, and only three with both syncope and epilepsy.

In these three cases, ocular compression produced syncope and pentylentetrazol did induce seizure, but seizure and syncope never occurred in sequence.¹⁵

Our patient clearly suffered recurrent seizures of complex partial and generalized convulsive type, with interictal epileptiform discharge in the temporal lobes and a favorable response to anticonvulsant therapy. There was no family history of epilepsy, no history of birth injury or febrile convulsion, and no other possible cause of seizure.

Although the patient had a history of abuse of alcohol and other drugs, the seizures were never temporally related to the withdrawal or use of any of these agents. We hypothesize that the genesis of her recurrent seizures with temporal-lobe foci is the extremely frequent self-induced cerebral ischemia over a period of six years. Because the hippocampus is one of the most sensitive areas to anoxic damage, the repeated cerebral ischemia may have resulted in scar formation there. The mechanism of seizure genesis may be comparable to the recurrent seizures that occur secondary to cerebral infarct.¹⁶ If the cause-effect relationship between syncope and seizure is valid, we believe this case demonstrates an important possible complication of syncope and strong indication for careful evaluation and treatment.

The "addiction" this patient had to the habit of carotid compression and subsequent syncope is a striking phenomenon. It is reminiscent of the compulsive induction of minor seizures that are self-induced in some children by moving their hands in front of their eyes to produce a flickering light.¹⁷ The patient admitted that a pleasurable sensation with definite sexual overtones was associated with the habit. We postulate that this sensation resulted from ischemic stimulation of the limbic system, analogous to hallucinatory visual sensations resulting from ischemic stimulation of the occipital cortex that occurs in posterior cerebral artery insufficiency and probably in migraine. Repetitive self-strangulation as a maneuver to induce or enhance sexual excitement is a well-known phenomenon in men and is usually associated with an overt history of a variety of sexual deviations.^{18,19} This phenomenon is probably best known to medicolegal personnel because the practice is occasionally fatal and is usually reported when the bodies (usually nude) are the subject of investigation by coroners. It has been estimated that 50 deaths per year result from this practice, which

interestingly has been reported only rarely in women.²⁰ Whether these persons who abuse themselves in this way primarily induce cerebral ischemia by compression of the carotid arteries or asphyxia by compression of the trachea is of course not known, although Resnik¹⁹ favors the former mechanism. No case of repetitive strangulation, however, has been reported to have a compulsive frequency similar to that of our patient. It is interesting to speculate on why this patient repeatedly indulged in the production of cerebral ischemia. The existence of a reward center in the limbic system is well documented,²¹ and ischemia could have served as a stimulus to this area, thereby producing repetitive behavior such as has been observed in animals.

References

1. Noble RJ: Syncope. *Cardiovasc Clin* 1981; 12:119-130.
2. Gastaut H, Fischer-Williams M: Electroen-

cephalographic study of syncope: Its differentiation from epilepsy. *Lancet* 1957;2:1018-1025.

3. Foster FM, Roseman E, Gibbs FA: Electroencephalogram accompanying hyperactive carotid sinus reflex and orthostatic syncope. *Arch Neurol Psychiatry* 1942;48:957-967.
4. Engel GL, Romano J, McLin TR: Vasodepressor and carotid sinus syncope. *Arch Intern Med* 1944;74:100-119.
5. Duvoisin RC: Convulsive syncope induced by the Weber maneuver. *Arch Neurol* 1962;7:219-226.
6. Klein LJ, Saltzman HA, Heyman A, et al: Syncope induced by the Valsalva maneuver: A study of the effects of arterial blood gas tensions, glucose concentration and blood pressure. *Am J Med* 1964;37:263-268.
7. Braham J, Hertzzeanu H, Yahini JH, et al: Reflex cardiac arrest presenting as epilepsy. *Ann Neurol* 1981;10:277-278.
8. Luft UC, Noell WK: Manifestations of brief instantaneous anoxia in man. *J Appl Physiol* 1956;8:444-454.
9. Rosen LR, Kabat H, Anderson JP: Acute arrest of cerebral circulation in man. *Arch Neurol Psychiatry* 1943;50:510-528.
10. Lin JT-Y, Ziegler DK, Lai CW, et al: Convulsive syncope in blood donor. *Ann Neurol* 1982;11:525-528.
11. Kershman J: Syncope and seizures. *J Neurol Neurosurg Psychiatry* 1949;12:25-33.
12. O'Doherty DS: Tussive syncope and its

relation to epilepsy. *Neurology* 1953;3:16-21.

13. Lloyd-Smith D, Tatlow WFT: Syncope and seizure. *Electroencephalogr Clin Neurophysiol* 1958;10:153-157.
14. Fuglsang-Frederiksen V: Activation of EEG disturbances with Metrazol (Pentazol) in epileptics, normals and patients with syncopal attacks. *Electroencephalogr Clin Neurophysiol* 1952;4:471-480.
15. Gastaut H: Syncope and seizure. *Electroencephalogr Clin Neurophysiol* 1958;10:571-572.
16. Louis S, McDowell F: Epileptic seizures in nonembolic cerebral infarction. *Arch Neurol* 1967;17:414-418.
17. Andermann K, Berman S, Cooke PM, et al: Self-induced epilepsy: A collection of self-induced epilepsy cases compared with some other photoconvulsive cases. *Arch Neurol* 1962;6:49-65.
18. Litman RE, Swearingen C: Bondage and suicide. *Arch Gen Psychiatry* 1972;27:80-85.
19. Resnik HLP: Erotized repetitive hanging: A form of self-destructive behavior. *Am J Psychother* 1972;26:4-21.
20. Sass FA: Sexual asphyxia in the female. *J Forensic Sci* 1975;20:181-185.
21. Milner PM: Self-stimulation and mechanisms of motivation, in *Physiological Psychology*. New York, Holt Rinehart & Winston Inc, 1970, pp 378-412.

Gouty Neuropathy

Peyton Delaney, MD

● A patient with gout had a peripheral neuropathy that improved with the lowering of the serum uric acid level. He had a relapse when hyperuricemia recurred, suggesting that the hyperuricemia of gout may produce a treatable form of peripheral neuropathy.

(*Arch Neurol* 1983;40:823-824)

The neurologic complications of gout are rare, consisting of either peripheral nerve entrapment¹⁻⁶ or spinal cord compression.⁷⁻¹² When a generalized peripheral neuropathy develops in a gouty patient, other causes of neuropathy are sought, since hyperuricemia has not been reported as a causal agent.^{13,14} The following case demonstrates that the hyperuricemia of gout may produce a treatable form of peripheral neuropathy.

REPORT OF A CASE

A 53-year-old man with chronic, tophaceous gout and nephrolithiasis had progressive numbness of his feet and difficul-

ty walking for six months. He denied alcohol abuse, diabetes mellitus, exposure to toxins, or a family history of gout or neuropathy. He took colchicine and allopurinol erratically.

Multiple tophi were present over the extremities. His gait was wide based and Romberg's sign was present. Myotactic reflexes were hypoactive in the arms and absent in the legs. Plantar responses were neutral. There was slightly diminished strength of the anterior tibialis and extensor digitorum brevis muscles. No atrophy was seen. Vibratory and position sense and light touch were markedly reduced distally in all limbs. Signs of a right carpal tunnel syndrome (CTS) were present.

The serum uric acid level was 10.1 mg/dL (normal, 3.5 to 8.5 mg/dL). A complete blood cell count and ESR, the serum calcium level, and results of hepatic and renal function studies were normal. Vitamin B₁₂ and whole blood folate levels, and results of thyroid function tests, a urinary screen for heavy metals, lead, and porphobilinogen, a five-hour glucose tolerance test, serum protein electrophoresis, and antinuclear antibody and rheumatoid factor tests were unremarkable. The CSF was normal. Results of an occult neoplasm workup were negative. Results of nerve conduction studies (NCS) were consistent with an axonal neuropathy and a right carpal tunnel syndrome (Table). The patient refused a nerve biopsy and carpal tunnel release procedure. The dose of allopurinol was increased to 200 mg twice daily.

Six months later, the patient claimed that his walking had improved and that his feet were no longer numb. Many of the tophi had regressed, knee reflexes had returned but were still hypoactive, strength and gait were normal, only minimal distal sensory loss was present, and previous signs of CTS were absent. The serum uric acid level was 6.9 mg/dL. Results of repeated NCS showed much improvement (Table).

Three years later the patient had acute renal colic resulting in a nephrolithotomy. His uric acid level was 9.3 mg/dL. His gait was wide based, myotactic reflexes were absent in the legs, there was diminished strength of the anterior tibialis and extensor digitorum brevis muscles, and vibratory and position sense and light touch were moderately reduced distally in all limbs. Results of a repeat workup for peripheral neuropathy were negative, and included normal phosphoribosyltransferase activity.¹⁵ The NCS had worsened (Table). He had taken no nonprescription drugs, did not abuse alcohol, and had no exposure to toxin. He was given 200 mg of allopurinol daily and follow-up examination revealed a serum uric acid level of 7.5 mg/dL with subjective improvement. Knee reflexes had returned, his strength and gait were normal, and mild distal sensory loss was present. Results of repeat NCS again were improved (Table).

COMMENT

Since the earliest description of

Accepted for publication March 7, 1983.

From the Department of Medicine, Division of Neurology, University of Texas Health Science Center and Medical Service, Neurology Section, Audie L. Murphy VA Hospital, San Antonio, Tex.

Reprint requests to 4499 Medical Dr, Suite 255, San Antonio, TX 78229 (Dr Delaney).