

SPEECH FLUENCY IN CROSSED APHASIA

by VICTOR W. HENDERSON

(From the Department of Neurology, University of Southern California School of Medicine, 1200 North State Street, Los Angeles, California 90033, USA)

SUMMARY

Three strongly right-handed patients developed fluent aphasia after right hemisphere infarction documented by computerized tomography. For these patients and for other reported cases of crossed aphasia suitable for analysis, the correlation between fluency and infarct localization was similar to that of right-handed aphasics with left-sided lesions. Right hemisphere language representation in most crossed aphasics probably mirrors that normally present in the language-dominant left hemisphere.

Two of these patients showed concomitant hemispatial inattention and visuoconstructive impairment. Right hemisphere language dominance therefore does not preclude ipsilateral specialization for visuospatial functions.

INTRODUCTION

Aphasia from a right cerebral hemisphere lesion in right-handers (crossed aphasia) is rare (Roberts, 1951; Gloning *et al.*, 1969; Hécaen *et al.*, 1971). Regardless of lesion site, crossed aphasia (CA) has been characterized as nonfluent, implying that when the right hemisphere is anomalously language-dominant, language organization does not mirror that normally present in the left hemisphere (Angelergues *et al.*, 1962; Brown and Hécaen, 1976; Urbain *et al.*, 1978). This paper describes three patients in whom persistent fluent language disturbances followed right cerebral infarction confirmed by computed tomography. For these three cases and for other reported CA patients, the correlation between fluency and infarct localization was similar to that of right-handed aphasics with left hemisphere lesions. For most right-handed adults, intrahemispheric representation of language functions probably does not depend on the side of language dominance.

CASE SUMMARIES

Case 1

A 51-year-old college educated man had a sudden onset of disturbed speech and difficulty using his left hand. There was no prior history of neurological illness. He spoke only English. He was strongly right handed (laterality quotient of 100 on the Edinburgh Inventory of handedness—Oldfield, 1971), and 7 out of 8 first degree relatives were right handed. Detailed evaluation was made three weeks after onset. By the time of discharge two weeks later he had improved slightly, and similar deficits were apparent when he was later seen as an outpatient.

Visual fields, ocular movements and optokinetic nystagmus, tactile sensation, motor tone and strength, and gait were normal. There was no unilateral visual or tactile neglect. On the left, he showed clumsy fine finger movements, a pronator drift of the outstretched arm, hyperreflexia and Babinski's sign.

He was alert and orientated. Affect was normal. Immediate recall (oral repetition span) was four digits. Each of three previously rehearsed object names was recalled after a five minute delay.

Spontaneous speech was grammatical but hesitant. He showed stuttering on initial syllables, word-finding pauses and a paucity of substantive words. In describing the Boston Diagnostic Aphasia Examination (BDAE) Cookie Theft picture (Goodglass and Kaplan, 1972), he stated 'The sink is overspilling. I don't know what the little girl; she's gesturing something there'. Literal paraphasias, present during spontaneous speech, were more frequent during automatized speech, such as nursery rhyme recitation. Rate of speech, prosody, phrase length and articulation of individual phonemes were normal. Confrontation naming was mildly impaired, but mistakes were often self-corrected. Auditory comprehension was normal except when he followed commands dependent on a knowledge of syntactic relations. Repetition was impaired, particularly for syntactically complex sentences. There were literal paraphasias on phrase repetition and verbal paraphasias on number repetition. Reading aloud was similarly hesitant and paraphasic. He correctly spelled words aloud but failed to name most words spelled aloud to him. His BDAE aphasia severity rating was 4 (on a scale of 0 to 5, with 5 representing the mildest deficits), and his speech profile was that of conduction aphasia (Goodglass and Kaplan, 1972) (fig. 1).

Affective intonation during spontaneous speech and repetition, assessed by the bedside method of Ross (1981), was normal. His spontaneous facial expressions and production of requested emotional expressions on command were normal. With the examiner standing behind him, he could name the affective content of the examiner's speech (Ross, 1981). Melody while singing was good, and he recognized tunes whistled by the examiner.

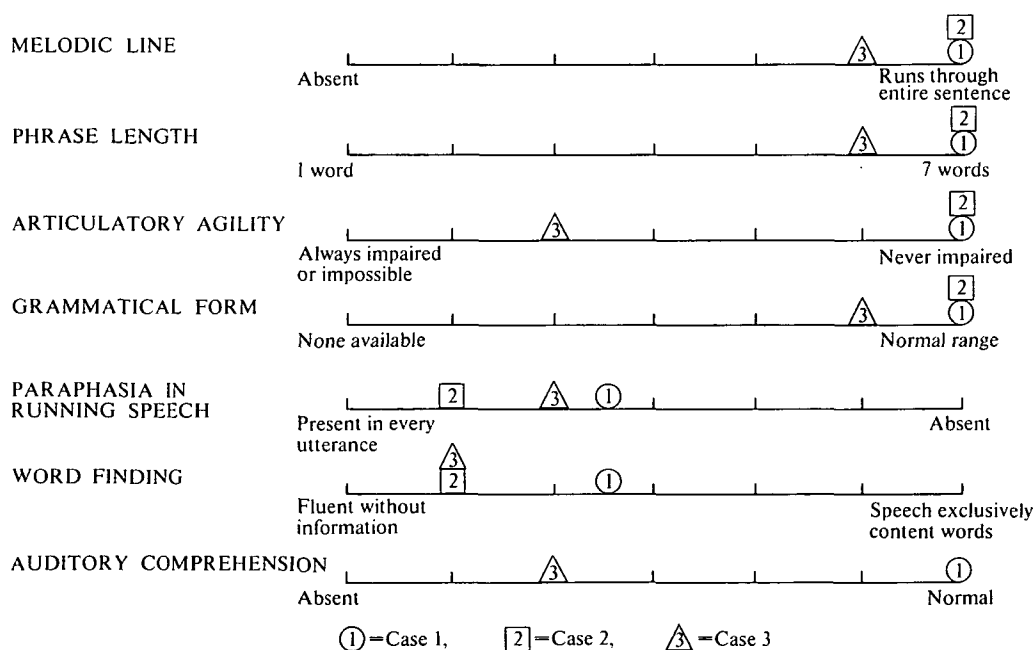


FIG. 1. BDAE speech profiles for Cases 1, 2 and 3.

Orofacial, limb and axial praxis to command and imitation were normal.

Writing posture with the right hand was noninverted (Levy and Reid, 1976). Letters were well formed, but mistakes included paragraphic errors, omissions and reiterations (fig. 2). He made more errors on phrases with few substantives. For example, the dictations *no ifs, ands or buts* and *no apples, pears or string beans* were written 'if no and and buts' and 'no apple, pears and string beans', respectively. He made errors, some due to paraphasic and paragraphic substitutions, on simple problems of oral and written arithmetic. He performed poorly when asked to name fingers or to point to individual fingers named by the examiner. On the examiner but not on himself, he confused left and right sides.

On a line bisection task (Albert, 1973), he worked from left to right, bisecting each line normally. There was no unilateral neglect, but line drawings were oversimplified. Copies were better than drawings without a model (fig. 2). He correctly identified photographs of famous faces. His scaled score on the Block Design subtest of the Wechsler Adult Intelligence Scale (Wechsler, 1955) was 9. (The mean score for the normal reference group is 10.)

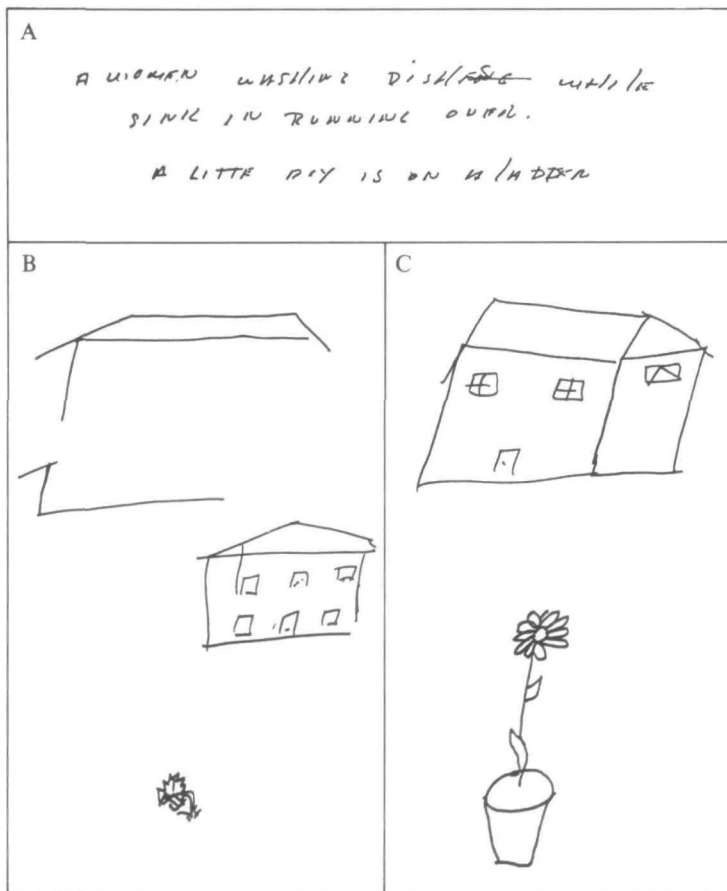


FIG. 2. Case 1. A, description of BDAE Cookie Theft picture. He prints 'A WOMEN WASHING DISHES' (self-corrected to DiSHES) WHILE SINK IN RUNNING OVER. A LITTLE BOY IS ON A IATTER' (self-corrected to LADDER). B and C, drawings of a house and daisy without (B) and with (C) a model. Copies are better than his simplified drawings to command.

An electroencephalogram (EEG) showed right temporoparietal slowing. Computed tomography of the brain (CT) demonstrated two right hemisphere areas of decreased density consistent with infarcts (fig. 3). A circumscribed lesion involving the inferior parietal lobule extended from cortex to the body of the lateral ventricle. There was a smaller lesion of the head of the caudate nucleus and adjacent anterior limb of the internal capsule. The left hemisphere was normal, and CT five months later showed no new abnormality.

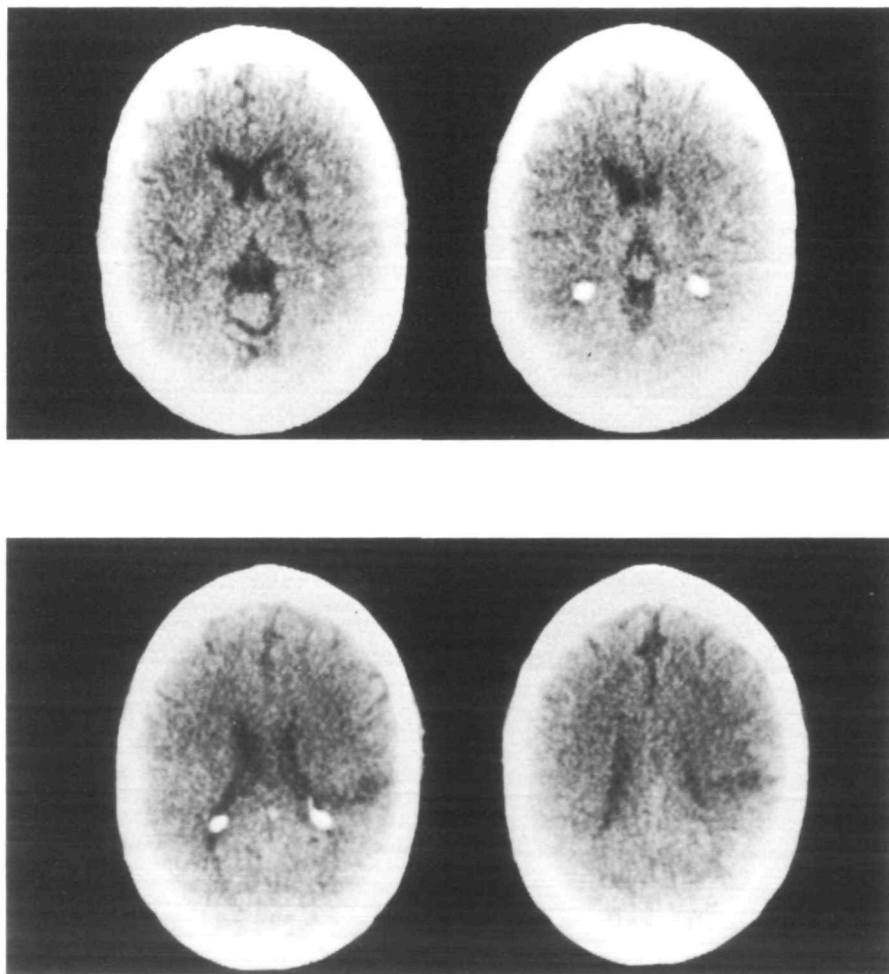
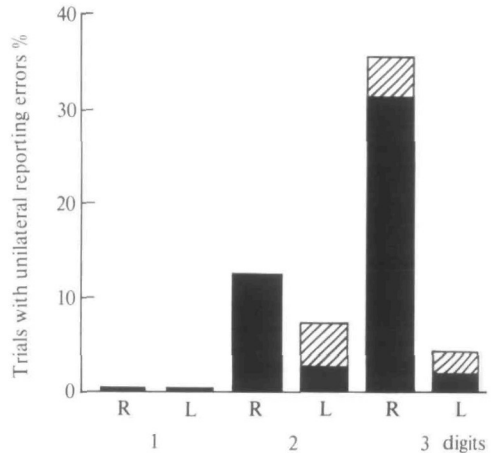


FIG. 3. CT of *Case 1*. The lower two photographs show a low-density lesion of the right inferior parietal lobule extending deeply into subcortical white matter. A smaller lesion of the head of the right caudate nucleus and adjacent anterior limb of the internal capsule is seen in the left upper CT slice.

Audiometry confirmed normal hearing within the speech frequencies. He was evaluated with dichotic pairs of one, two and three digit numbers. By reversing the stereo headphones, each pair appeared twice in reverse ear order. No instructions were given as to the order of report. He correctly named all single digits, but on 88 trials with two or three digit pairs, he made 22 unilateral errors from the right ear and 5 from the left (fig. 4).

By the time of discharge, finger gnosis and left/right discrimination had returned to normal. Rote calculations could be accurately performed, but written arithmetic remained flawed by paragraphic errors, and division was almost impossible. Auditory comprehension was completely normal, whereas speech was persistently halting with some repetition difficulty and occasional paraphasias.

FIG. 4. *Case 1*. Unilateral errors on dichotic listening task with pairs of one, two and three digit numbers. The height of the bars represents unilateral reporting errors, while the solid portion of the bar reflects errors when order of reporting was disregarded for two and three digit numbers.



Case 2

A week before admission, a 60-year-old woman awoke with transient left-sided weakness. At another hospital, she was described as incoherent.

There was a past history of treated hypertension and chemical diabetes but no previous neurological or psychiatric symptoms. She was a high school graduate who spoke only English. She was strongly right handed (laterality quotient of 100 on the Edinburgh Inventory of handedness—Oldfield, 1971). Each of 11 first degree relatives was right handed.

She was alert but agitated and disorientated. Immediate recall was impaired. Confusion resolved gradually during her seven week hospital course. She was assessed neurologically a month after her stroke and in more detail after discharge one month later. Findings were similar, but during the earlier interview attention remained poor, press of speech with augmentation was more evident, and paraphasic errors more frequent.

She perceived hand movement in her left visual field but could not count fingers on that side or detect left-sided movement during simultaneous bilateral movements. Ocular saccades were impaired for an optokinetic target moving from her left to right. The left nasolabial fold was flattened. Strength and tendon reflexes were normal, but the left hand was clumsy. Although tactile sensation was intact, she ignored stimuli on her left limbs during bilateral simultaneous stimulation.

She was alert and orientated. The digit repetition span was five. She correctly recalled names of three items after a five minute delay. During the first interview, she was euphoric and denied any reason for being in hospital. Later, she admitted to having had a stroke but claimed full recovery.

Spontaneous speech was effortless, empty and circumlocutory with word-finding pauses. Rate was increased, and articulation, prosody and phrase length were normal. There were verbal, literal and occasional neologistic paraphasias. When asked if she recognized the name of former President Carter, she said 'That's the next another one I voted. Jorner, Jorna [the target word was *Georgia*], something around Alabama'. Automatized speech was often intact. Visual confrontation naming was impaired for object and body part names. She benefited poorly from contextual or phonetic cues. Examples of

errors were 'microphone' for *magnet*, 'bullet' for *watchband*, 'jaw' for *cheek* and 'middle, that's the middle the tongue, the second hand to the tongue' for *index finger*. Repetition was normal for numbers, single words and short phrases but impaired for longer sentences. *No ifs, ands or buts* was repeated as 'no if, hamma and buts'. Auditory comprehension was intact for simple yes/no questions. Pointing to objects on command was impaired, more so when the item was identified by a functional description rather than by name. She incorrectly answered questions involving complex ideational information.




FIG. 5. Case 2 writing samples. A, dictated as *She parked the car in the garage*. B, she was instructed to describe the weather. Asked what she had written, she said 'The weather is hot'. C, copy showing left-sided neglect. Spelling of *dog* as 'gog' and the extra stroke in *lazy* (arrow) may represent spatial dysgraphia (Hécaen and Marcie, 1974). However, linguistic errors are clearly present in other written productions.

Many oral reading errors were confined to words on the left side of the page and to the initial portion of a word. The sentences *Why did she do it* and *The airplane pilot flew over the German landscape* were read aloud as 'Did she go it?' and 'The airplane pilot went over the country and escaped', respectively. During the second interview, the BDAE aphasia severity rating was 3, and the speech profile was that of Wernicke's aphasia (Goodglass and Kaplan, 1972) (fig. 1).

Affective intonation during spontaneous speech and repetition was normal. She correctly identified affective intonation in the examiner's speech. Spontaneous facial expressions and her production of emotional expressions on command were normal. Melody while singing was good.

Orofacial and axial praxis to command were normal. On tasks of transitive limb praxis to command and imitation, she substituted a body part for intended objects (Goodglass and Kaplan, 1972).

Writing posture with the right hand was noninverted. The left margin was widened, and some lines sloped upward. Even after first correctly reading a sentence aloud, copying was impaired, although less so than writing done spontaneously or to dictation (fig. 5). She distinguished her left and right sides but

not those of the examiner. Rote arithmetic calculations were accurately performed but not more complex problems. She correctly named only the thumb and little finger and consistently reversed the index and middle fingers when pointing to digits named by the examiner.

On a line bisection task, she worked from right to left, marking lines to the right of centre. Drawings to command and copy were strikingly impaired. Her approach was piecemeal (Paterson and Zangwill, 1944), she sometimes drew over the examiner's model, left-sided details were omitted, and individual features often bore little relation to the overall design (fig. 6). She identified photographs of famous faces. Her scaled score on the Block Design test was zero.

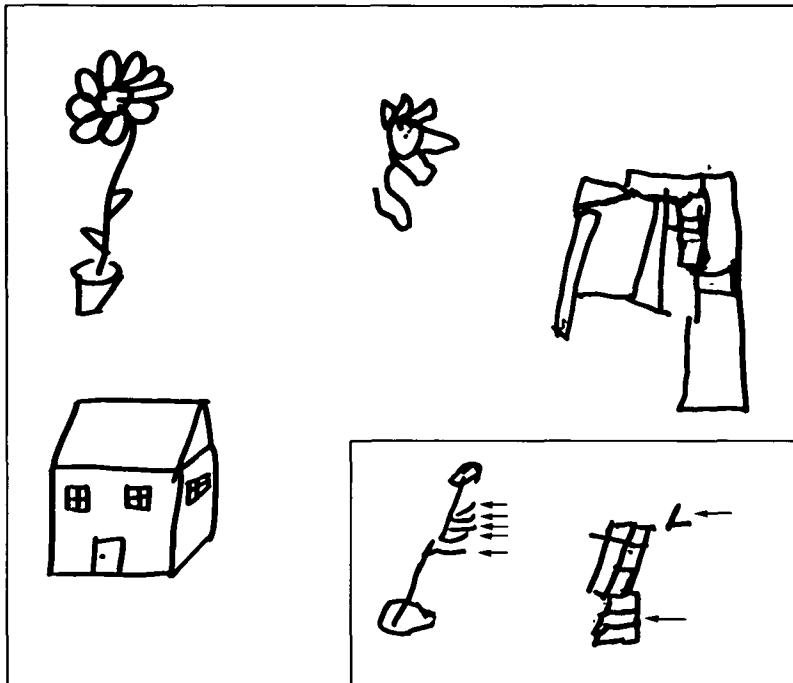


FIG. 6. Case 2. Drawings to command (*inset*) and copy (*models on left*). Left-sided inattention on the daisy and piecemeal approach to the house are evident. Details are placed with little regard for the overall design. Performance is not improved by the model. Arrows point to daisy petals and to the roof and stairs of her house.

Consistent with acute infarction, CT five days after onset of symptoms showed a large area of decreased density with associated mass effect, involving the right temporal, parietal and occipital lobes. Three weeks after her stroke, an EEG showed right temporoparietal delta slowing, and CT now revealed a right temporal-parietal-occipital low-density lesion without mass effect. After contrast injection, there was enhancement within this area (fig. 7).

Case 3

A 61-year-old man was admitted to hospital after the abrupt onset of left-sided weakness and language impairment. He left school in Ireland at the age of 14 but could read and write well. He spoke only English. He had been diabetic for several years. Over the past year, he had noticed a resting hand tremor, but there was no past history of other neurological symptoms. He was strongly right handed

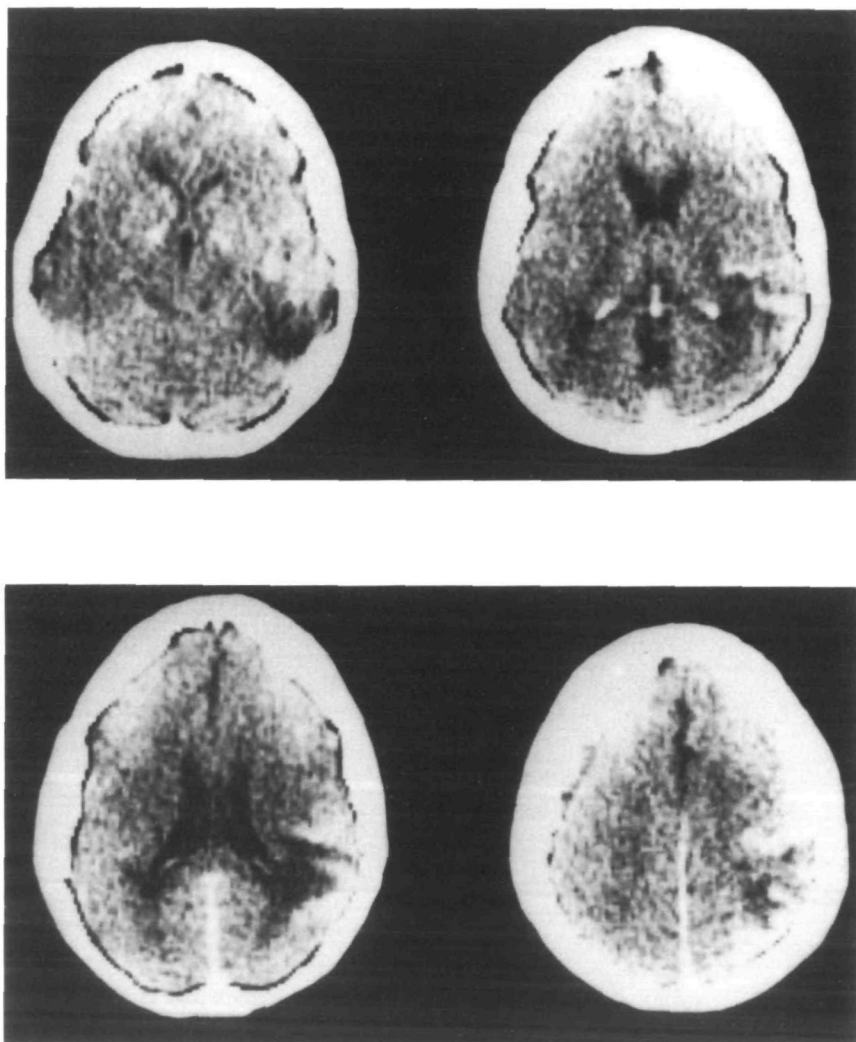


FIG. 7. *Case 2.* CT shows a contrast-enhancing right temporal-parietal-occipital infarct.

(laterality quotient of 100 on the Edinburgh Inventory of handedness—Oldfield, 1971). Each of 3 first degree relatives was right handed.

Neurological deficits were stable during evaluation two to three months after symptom onset. To confrontation there was a dense left homonymous hemianopia. Corneal sensation was depressed on the left, and pin prick was identified as less sharp on the left side of the face. He had a mild spastic left hemiparesis with brisk tendon reflexes on that side. There was an intermittent low amplitude 5 Hz distal upper limb resting tremor. Except for signs of a distal polyneuropathy, limb sensation was normal. Left-sided tactile stimuli were ignored during bilateral simultaneous stimulation.

He was alert and orientated. Affect was normal. Digit repetition span was three. He recalled names of three previously rehearsed object names after a five minute delay.

Speech was hypophonic and mildly dysarthric. Conversational speech was effortless with normal rate, prosody and phrase length. He used a variety of grammatical forms, but there were word finding pauses and he used few substantive words. There were occasional verbal, literal and neologistic paraphasias. When describing a leg injury, he said 'It was fishe o'clock they left. They table, they left the table away. Oh, it was heavy; it was heavy. As much as I could left, and then the foot sore, would, uh, the foot was, uh, feelin' well. And I skinned it and everythin'. And then they, the doctor was away on vacation, and they weren't there or nothin''. Automatized speech was better than spontaneous speech.

Confrontation naming was impaired, more so for objects than body parts. He improved with phonetic but not contextual cues. Examples of errors were 'hand' for *glove*, 'smissor' for *feather*, 'toe' for *tongue*, 'argoni' for *elbow*, 'yellow' for *pink*, and 'like a blue, but it's not' for *purple*. Repetition was often intact at the single word and short phrase level but impaired for more complex sentences. *Shoe* was repeated as 'sugar', *under the bed* as 'under the door', *what of it* as 'what about it' and *the barn swallow captured a plump worm* as 'the barn sollowed a captured a worm'. Often correct for single yes/no questions, auditory comprehension was more consistently impaired when he responded to more complex questions or pointed to objects named by the examiner. Oral reading and his comprehension of written language were impaired. *Circle* was read aloud as 'circulet', *triangle* as 'transition', *fifteen* as 'charifant', *purple* as 'burgandy' and *The spy fled to Greece* as 'They say they to greet'. The BDAE aphasia severity rating was 2, and his speech profile was that of Wernicke's aphasia (Goodglass and Kaplan, 1972) (fig. 1).

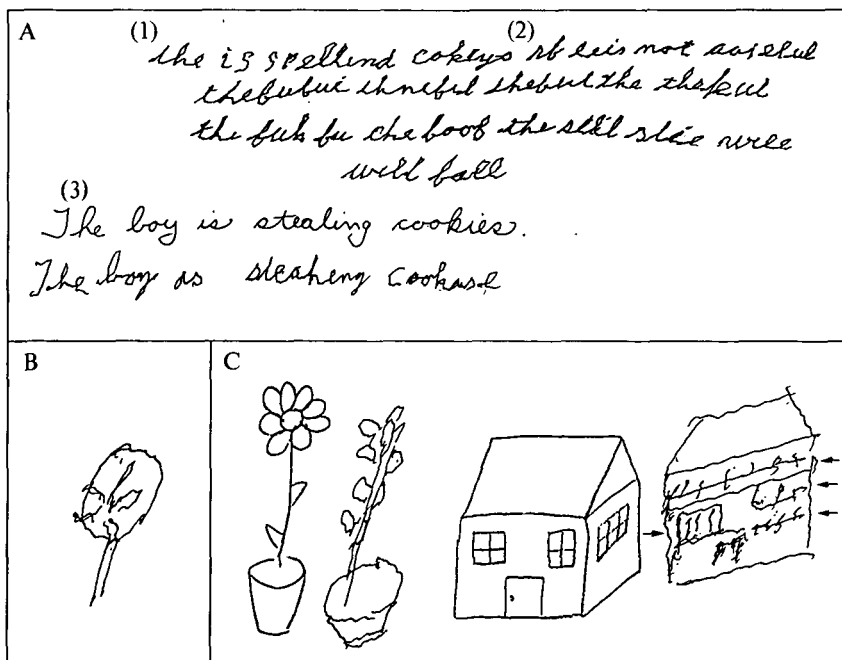


FIG. 8. Case 3. A, writing samples. Two separately dictated sentences were (1) *The boy is stealing cookies* and (2) *If he is not careful, the stool will fall*. Particular difficulty is seen with substantive words: *boy* is omitted, *stealing cookies* is misspelled as 'seellind cokeys', and *stool* induces striking iteration. At one point, the paraphasia 'book' is written for *stool*. (3) Performance is much better when copying. B, petals of the daisy drawn to command are placed within the flower head. He would not attempt to draw a house without a model. C, copy of a daisy shows petals which extend down the stem rather than radiating from the centre. Extra windows in his copy of the house are indicated by arrows.

Affective intonation during spontaneous speech and repetition, and his ability to identify the affective content of the examiner's speech were normal, as was melody while singing. Spontaneous facial expressions, his production on command of emotional expressions and his recognition of the affective content expressed by the examiner's expressions were normal.

Orofacial and axial praxis were normal. Mild limb apraxia to command, with loss of extension and the substitution of a body part for the intended object (Goodglass and Kaplan, 1972), improved on imitation.

Writing posture of the right hand was noninverted. Handwriting was marred by tremor, and perseveration, neologisms and misspellings were common (fig. 8). He distinguished left and right sides on himself but not on the examiner. He could name only his thumb and 'wee' finger and correctly identified only the same two digits when asked to point to fingers named by the examiner. He was unable to perform simple problems of oral or written arithmetic.

On a line bisection task, he neglected lines on the left side of the page and bisected other lines to the right of centre. Line drawings to command and copy were impaired. He placed individual details without regard to the overall configuration, and the left side of some drawings was incomplete (fig. 8). He identified photographs of famous faces. His scaled score on the Block Design test was zero.

EEG showed the absence of right hemisphere alpha activity, right-sided theta slowing and occasional sharp waves from right-sided leads. CT the day of admission was normal, but one month later CT showed a nonenhancing low-density lesion involving the right inferior parietal lobule and the posterior part of the superior temporal lobe (fig. 9).

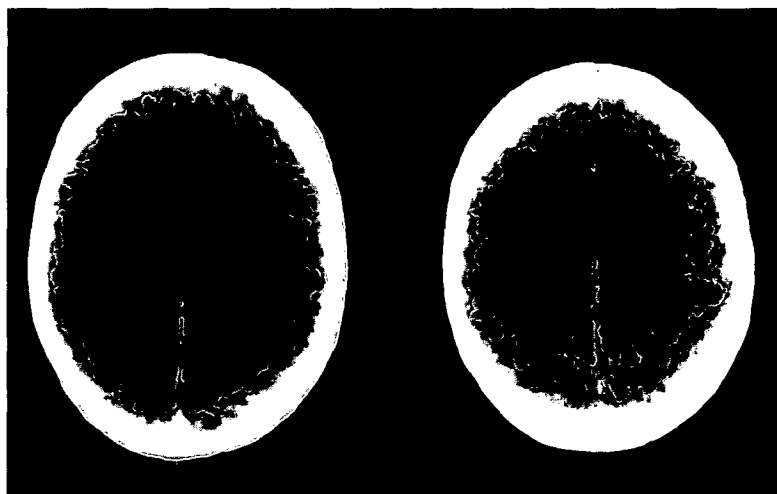

FIG. 9. Case 3. CT shows a low-density lesion involving the right inferior parietal lobule and the posterior superior temporal lobe.

ANALYSIS OF CASES

The accompanying neurological signs, and the EEG and CT findings suggested that aphasic symptoms in these three strongly right-handed patients were caused by right hemisphere lesions. Results of the first patient's dichotic listening task also supported this conclusion. Left parietal lesions which spare the temporal lobe usually cause a right ear advantage due in part to 'paradoxical' ipsilateral extinction

of dichotic verbal material (Sparks *et al.*, 1970; Damasio and Damasio, 1979). The marked left ear advantage of Case 1 was thus predicted on the basis of his deep right parietal infarct and right hemisphere language dominance. None of these cases had a strong family history of left handedness, none had had childhood brain injury, and none was bilingual. For Cases 1 and 2, language disturbances improved somewhat over a period of several months, and for Case 3 deficits persisted.

Analysis of spontaneous speech (Benson, 1967, 1979) showed that the language disturbance in each case was fluent (*see Table*).

FLUENCY IN SPONTANEOUS SPEECH

Case No.	Effort	Rate	Phrase length	Prosody	Articulation	Word choice	
						Syntax	Paraphasias
1	+	+	+	+	+	+	+
2	+	+	+	+	+	+	+
3	+	+	+	+	—	+	+

+ = features of fluent speech. Effort, rate, phrase length, prosody and articulation are normal or near normal. Syntactic word choice is normal or paragrammatic, and there are paraphasic errors.

— = features of nonfluent speech. Speech is effortful, rate and phrase length decreased, and prosody and articulation abnormal. Speech is agrammatic, and paraphasias are rare.

Mild idiopathic Parkinson's disease in Case 3 is likely to have been responsible for hypophonia and dysarthria but probably did not otherwise affect speech fluency. The first patient made predominately literal paraphasic errors, but verbal paraphasias were more frequent in spontaneous speech of the second and third patients. For Case 1, comprehension was almost normal, whereas it was impaired for Cases 2 and 3. The disorders were characteristic of conduction aphasia for Case 1 and Wernicke's aphasia for Cases 2 and 3.

Conduction aphasia occurs after posterior left hemisphere perisylvian lesions which include long association fibres between posterior and frontal language areas. For a typical right-hander, conduction aphasia may follow left hemisphere injury corresponding to the first patient's cortical and subcortical infarct in the right inferior parietal lobule (Benson *et al.*, 1973; Damasio, 1981). Involving the vascular territory of the lower division of the middle cerebral artery, the characteristic lesion of Wernicke's aphasia includes the posterior left superior temporal gyrus (Wernicke's area) and surrounding regions of the temporal and parietal lobes (Mazzocchi and Vignolo, 1979; Mohr, 1980; Damasio, 1981). Sites of the second and third patients' infarcts mirrored the usual left hemisphere lesion of Wernicke's aphasia.

Cases 2 and 3 also had features of the neglect syndrome. Case 2 was unconcerned and denied the extent of her disability. Both patients ignored left-sided sensory stimuli during bilateral simultaneous stimulation. Each showed unilateral neglect on a line bisection task and in line drawings. They copied drawings no better than they drew without a model. Their approach was piecemeal, and they placed

individual details without regard to the overall configuration (figs. 6 and 8). These visuoconstructive deficits are typical of those after right hemisphere damage (Paterson and Zangwill, 1944; Piercy *et al.*, 1960; Warrington *et al.*, 1966; Gainotti and Tiacci, 1970).

For several weeks after her stroke, Case 2 was confused, probably as a direct result of her right temporoparietal infarct (Mesulam *et al.*, 1976). Impaired attention is a cardinal symptom of confusion (Mesulam, 1981). Both the neglect syndrome and a transient confusional state may follow ischaemic injury to the right posterior hemisphere and have been attributed to the importance of posterior polymodal cortical association regions in mediating arousal and selective attention (Mesulam *et al.*, 1976; Mesulam, 1981). Hemispatial inattention, visuoconstructive impairments and, for Case 2, denial of illness and confusion suggest that right hemisphere dominance for attention and visuospatial functions did not differ from that of most right-handers.

In contrast, Case 1 recognized the extent and implications of his stroke. There was no inattention during bilateral stimulation. He accurately bisected lines, worked from left to right and did not ignore left-sided details when drawing. His simplified line drawings, however, were better when a model was provided for him to copy (fig. 2). This type of visuoconstructive disturbance is normally associated with left-sided injury (Piercy *et al.*, 1960; Warrington *et al.*, 1966; Gainotti and Tiacci, 1970), and right hemisphere representation of Case 1 for both linguistic and visuospatial skills seemed more typical of left hemisphere organization.

DISCUSSION

Since Dax (1865) and Broca (1863, 1865) first recognized that aphasia is caused by left hemisphere lesions, it has been known that higher cerebral functions may be asymmetrically represented within morphologically similar hemispheres. Jackson (1868), however, realized that aphasia associated with left hemiplegia might occur in some right-handers, and Bramwell (1899) later coined the term crossed aphasia (CA) to describe this seemingly anomalous discovery that language lateralization and handedness are not inexorably linked. CA has since come to refer to aphasia caused by right hemisphere lesions in right-handed persons. Its incidence is less than 1 per cent after right hemisphere lesions (Roberts, 1951; Hécaen *et al.*, 1971), and among right-handed aphasics, the prevalence of CA is also about 1 per cent (Gloning *et al.*, 1969). For left-handers, aphasia more often follows lesions of either cerebral hemisphere (Moutier, 1908; Goodglass and Quadfasel, 1954; Hécaen and Ajuriaguerra, 1964), and ambidexterity or 'ambilaterality' confounds some purported examples of CA (Kennedy, 1916; Ettlinger *et al.*, 1955).

A study of CA has implications for theories of cerebral dominance. Semmes (1968) posits that both right handedness and left hemisphere language specialization stem from focal representation of elementary sensory and motor functions, which converge at higher levels of cerebral organization to permit precise input encoding

and output modulation. Diffuse or overlapping right hemisphere representation favours polymodal integration important for visuospatial perception. Since handedness and language dominance depend on a common substrate, this theory predicts that right hemisphere language representation for CA should differ from that in the left hemisphere of other strongly right-handed adults.

A similar view of CA has been more recently advanced. Several authors (Angelergues *et al.*, 1962; Brown and Hécaen, 1976; Urbain *et al.*, 1978) suggest that CA, regardless of lesion localization within the right hemisphere, is characterized by nonfluency. They argue that linguistic functions are diffusely rather than focally represented within the language-dominant right hemisphere and that lesions at any site within a diffusely organized language area cause nonfluent aphasia. These models of CA contrast to the language representation of most right-handed adults in whom anterior and posterior language regions are differentially specialized for speech production and perception. Thus, focal lesions within left hemisphere language areas cause different aphasic syndromes depending upon the specific locus of damage.

Language lateralization in CA has been directly studied twice with the intracarotid sodium amylobarbitone test of Wada (Wada and Rasmussen, 1960). For a nonfluent patient with occlusion of the right Sylvian artery, bihemispheric linguistic capacity was suggested by speech deterioration after a left carotid injection (Angelergues *et al.*, 1962). The Wada test, however, confirmed unilateral right hemisphere language dominance for Zangwill's (1979) fluent aphasic, who had a right temporal haemorrhage. Fluent language deficits for the present three patients also differed from those predicted by a model of diffuse right hemisphere language representation. Because so few cases of CA are reported, these exceptions suggest the need to reappraise this theory.

Comparison of Crossed and 'Uncrossed' Aphasia

The occurrence of aphasia does not establish a linguistic role for the injured brain area in an intact nervous system (Jackson, 1915). Nevertheless, it is reasonable to postulate that if a right hemisphere lesion impairs language differently in CA than does the mirror image left hemisphere injury in uncrossed aphasia (UCA), then language representation within the right hemisphere of crossed aphasics would differ from that usually found within the left. A conclusion that intrahemispheric language organization differs for CA is tenable only if the method of linguistic comparison between cases of CA and UCA is valid, crossed aphasics are compared with uncrossed aphasics who are otherwise similar in terms of potentially confounding variables, and lesions responsible for aphasia can be reliably localized.

Speech Fluency as a Method of Clinical Comparison

Carl Wernicke (1908) distinguished the sparse oral output of Broca's aphasia from the voluble speech and distorted use of a large lexicon of Wernicke's aphasia. A clinical classification of aphasia based on this *fluency* dichotomy is experimentally

valid (Howes, 1964, 1967; Benson, 1967; Kerschensteiner *et al.*, 1972; Wagenaar *et al.*, 1975) and for classifying groups of aphasic patients is more useful than differences in language comprehension (Goodglass *et al.*, 1964; Poeck *et al.*, 1972).

Nonfluent speech is characterized by the sparse, effortful production of short phrases. Speech prosody, or 'melody', and articulation are impaired. Substantive words (nouns, verbs and adjectives) are used in preference to relational words such as articles, prepositions and conjunctions (agrammatism—Goodglass, 1976). In contrast, fluent speech is easily produced at a near normal rate. Phrase length (longest occasional uninterrupted string of words—Goodglass and Kaplan, 1972), articulation and prosody are normal, and a variety of grammatical constructions are used. There may be paraphasic errors and omissions of substantive words (Benson, 1967, 1979). Nonfluent language occurs with Broca's, transcortical motor and global aphasia; whereas Wernicke's, conduction and transcortical sensory aphasia are fluent. As inferred for UCA from the CT and the radioisotope brain scan findings, nonfluent patients have lesions centred anterior to the left central fissure, and most fluent aphasics have more posterior lesions (Benson, 1967; Mazzocchi and Vignolo, 1979; Damasio, 1981). Those with lesions of both anterior and posterior speech regions or with minor aphasic deficits such as anomia may be difficult to classify, and about one-fifth of chronic aphasics cannot be segregated into fluent and nonfluent dichotomies (Benson, 1967; Wagenaar *et al.*, 1975).

Potentially Confounding Variables

Our knowledge of left hemisphere aphasic syndromes is largely derived from observations on patients with ischaemic stroke. Infarction, unlike trauma or mass lesions, produces discrete damage amenable to clinical-anatomical correlation, and classic aphasic syndromes usually follow infarction within specific vascular territories (Boller, 1973; Mohr, 1976, 1980; Mohr *et al.*, 1978).

A large proportion of CA patients are polyglots (Marinesco *et al.*, 1938; Holmes and Sadoff, 1966; Hécaen *et al.*, 1971; Nair and Virmani, 1973; Wechsler, 1976; April and Tse, 1977; April, 1979; Zangwill, 1979; Trojanowski *et al.*, 1980), and bihemispheric language representation probably occurs more often among polyglots than monolinguals (Albert and Obler, 1978; Galloway, 1981). For each language, intrahemispheric representation is not always coextensive (Ojemann and Whitaker, 1978), linguistic functions can be selectively or differentially impaired, and recovery can be antagonistic or proceed at different rates (Pitres, 1895; Minkowski, 1963; Nair and Virmani, 1973; Paradis, 1977; Silverberg and Gordon, 1979). Although CA may be more prevalent among polyglots, bilingualism confounds extrapolation as to how linguistic functions might be organized within the right hemisphere of monolingual crossed aphasics.

Inferences concerning linguistic impairment and cerebral language organization in CA should ideally be derived from strongly right-handed monolingual adults without childhood brain damage, with adequate language testing and with discrete ischaemic lesions confined to the right hemisphere. Whether it is also necessary to

control for patient age (Harasymiw *et al.*, 1981), sex (McGlone, 1977), literacy (Cameron *et al.*, 1971; Wechsler, 1976; Damasio *et al.*, 1976), handedness of relatives (Subirana, 1958), hand posture when writing (Levy and Reid, 1976) or speech therapy (Basso *et al.*, 1979) is less certain.

Localization of Lesion

Among currently available diagnostic techniques, only postmortem examination and CT provide requisite sensitivity for confident lesion localization. The radioisotope brain scan detects recent, but not older, pre-existing infarcts (Benson and Patten, 1967). Angiographic evidence of arterial occlusion is often absent in infarction, and because of variable collateral circulation, its occurrence defines neither the presence nor extent of ischaemic injury (Mohr, 1976; Yarnell *et al.*, 1976).

Clinical-anatomical Correlation in CA and UCA

Among the 11 CA patients cited in support of the theory of diffuse cerebral language organization (Brown and Hécaen, 1976; Urbain *et al.*, 1978), 5 had aetiologies other than ischaemic stroke (Ettlinger *et al.*, 1955; Botez and Wertheim, 1959; Hécaen *et al.*, 1971; Brown and Wilson, 1973; Foroglou *et al.*, 1975), 8 did not have lesions localized by autopsy or CT (Ettlinger *et al.*, 1955; Botez and Wertheim, 1959; Angelergues *et al.*, 1962; Barraquer-Bordas *et al.*, 1963; Clarke and Zangwill, 1965; Hécaen *et al.*, 1971; Brown and Wilson, 1973; Foroglou *et al.*, 1975), one was ambidexterous (Ettlinger *et al.*, 1955), at least 3 were polyglots (Marinesco *et al.*, 1938; Hécaen *et al.*, 1971; Wechsler, 1976), and 2 patients had no documentation of language disturbances beyond the early period after onset of symptoms (Foroglou *et al.*, 1975; Urbain *et al.*, 1978). While there is little doubt that most of these patients did indeed have CA, inferences concerning linguistic-anatomical correlations must remain suspect.

In addition to the present 3 patients, there are only 7 cases in the world literature of strongly right-handed monolinguals without left hemisphere or childhood brain damage in whom chronic aphasia (defined as oral language deficits persisting for at least one month) followed CT or pathologically confirmed right hemisphere infarction (Lozano and Clark, 1976; Pillon *et al.*, 1979, Case 1; Yarnell, 1981, Cases 2 and 3; Denes and Caviezel, 1981; Brust *et al.*, 1982; Haaland and Miranda, 1982). As with my cases (Table), Benson's (1967, 1979) criteria were used to determine fluency from descriptions of spontaneous speech.

For anomic aphasia, deficits are too mild to permit valid correlation between fluency and site of lesion, and the CA case of Denes and Caviezel (1981) is therefore inappropriate for analysis. Three weeks after a predominantly right frontal infarct, he had a Broca's aphasia. Many acute Broca's aphasics evolve to a more fluent anomia (Goodglass *et al.*, 1964; Mohr, 1976), and six months later their patient's disturbance was that of anomic aphasia. Eight of the other 9 aphasics were fluent. For Case 1 of Pillon *et al.* (1979), fluent CA could be tentatively inferred from speech

described as sparse but grammatical with verbal paraphasias, and there was clearly a fluent agraphia. The CT report of a right subcortical rolandic infarct for this patient precludes precise localization along an anterior-posterior axis. The other 7 fluent patients had documented posterior lesions. Three of these had coexisting anterior damage (Lozano and Clark, 1976; Yarnell, 1981, Case 2; my Case 1). The one nonfluent patient had infarction of the medial aspect of the right frontal lobe (Brust *et al.*, 1982).

The predominance of fluent aphasia in this series is probably an artefact related to the small number of CA cases suitable for clinical-anatomical correlation. About two-thirds of all chronic aphasics are nonfluent (Benson, 1967; Wagenaar *et al.*, 1975), and a similar proportion of nonfluent CA patients is expected if right hemisphere language organization mirrors that usually present on the left. The theory of diffuse language representation, however, would demand a yet higher nonfluency rate. Aphasia was fluent for the 2 cases in which available anatomical information was inadequate to establish location of the lesion as predominately anterior or posterior (Lozano and Clark, 1976; Pillon *et al.*, 1979) and for the case in which both anterior and posterior language regions were extensively infarcted (Yarnell, 1981, Case 2). For the remaining patients, infarct localization accurately predicted fluency based on language deficits normally seen after focal *left* hemisphere damage (Benson, 1967; Mazzocchi and Vignolo, 1979; Damasio, 1981). Thus, CA is not characterized by nonfluency, and comparably located right hemisphere lesions for CA usually cause aphasic deficits similar to those for UCA after left hemisphere lesions. These observations strongly suggest that linguistic functions within the right hemisphere of most crossed aphasics are organized like those of the left hemisphere for normal right-handed adults.

Emotional Aspects of Speech

Each of the present 3 patients conveyed appropriate affective information in his spontaneous speech, correctly mimicked affective content during speech repetition and comprehended affective intonation in the examiner's speech (Ross, 1981). These emotional components of speech are normally spared in UCA and lost after right hemisphere damage (Ross, 1981). Melody when singing, which usually depends on right hemisphere integrity (Gordon and Bogen, 1974), was also spared. Preservation of these functions implies that certain nonverbal aspects of oral communication are lateralized opposite the language-dominant hemisphere. Similar observations have not been made for other CA patients, and additional study is needed to determine whether this contralateral relation necessarily holds.

Neglect Syndrome in Crossed Aphasia

Right hemisphere lesions are often accompanied by the neglect syndrome: denial of disability, inattention to contralateral personal and extrapersonal space, and visuoconstructive impairment. Focal injury of either hemisphere causes the syndrome, but symptom severity is greater after right-sided damage (Piercy *et al.*,

1960; Mesulam, 1981). It is unlikely that selection bias accounts for the preponderance of neglect patients with right hemisphere damage. Instead, the right hemisphere is probably dominant for attentional or visuospatial functions (Piercy *et al.*, 1960; Mesulam, 1981). Findings in Case 1 and in rare reports of other right-handed patients (Brown and Wilson, 1973; Zangwill, 1979; Denes and Caviezel, 1981) imply that reversed dominance for both language and visuospatial perception skills occasionally occurs. However, constructional disturbances and hemispatial inattention are reported for other cases of CA (Marinesco *et al.*, 1938; Angelergues *et al.*, 1962; Barraquer-Bordas *et al.*, 1963; Clarke and Zangwill, 1965; Holmes and Sadoff, 1966; Kreindler *et al.*, 1966; Lozano and Clark, 1976; Assal *et al.*, 1981; Carr *et al.*, 1981; Haaland and Miranda, 1982). The neglect syndrome of Cases 2 and 3 may thus be more typical for CA, suggesting that right-sided language representation does not usually affect right hemisphere dominance for attention and visuospatial perception. These findings fail to support the general hypothesis that the type of intrahemispheric organization necessary for language specialization (Semmes, 1968) precludes dominance for attentional or visuospatial skills. Rather, cerebral specialization for these functions may occur in the same or opposite hemispheres. A basis for this seemingly independent functional segregation is unknown, and even for strongly right-handed adults, the dominant hemisphere for language or for visuospatial functions cannot always be predicted.

ACKNOWLEDGEMENTS

For Case 1, Drs M. P. Alexander and B. Oken participated in clinical care and theoretical formulations, Dr N. H. Estabrooks administered the BDAE, Dr H. Goodglass provided tape and equipment for the dichotic listening task, and Dr M. A. Naeser reviewed the CT. Information about Case 1 was presented in part at the 106th annual meeting of the American Neurological Association, San Francisco, California, September 14–16, 1981. Case 3 was under the care of Drs H. C. H. Fang and R. E. Saul. Dr M. P. Alexander provided valuable suggestions on the manuscript.

REFERENCES

- ALBERT M L (1973) A simple test of visual neglect. *Neurology, Minneapolis*, **23**, 658–664.
- ALBERT M L, OBLER L K (1978) *The Bilingual Brain: Neuropsychological and Neurolinguistic Aspects of Bilingualism*. New York: Academic Press.
- APRIL R S (1979) Concepts actuels sur l'organisation cérébrale du langage a partir de quelques cas d'aphasie croisée chez les orientaux bilingues. *Revue Neurologique*, **135**, 375–378.
- APRIL R S, TSE P C (1977) Crossed aphasia in a Chinese bilingual dextral. *Archives of Neurology, Chicago*, **34**, 766–770.
- ANGELERGUES R, HÉCAEN H, DJINDJIAN R, JARRIÉ-HAZAN N (1962) Un cas d'aphasie croisée (thrombose de l'artère sylvienne droite chez une droitnière). *Revue Neurologique*, **107**, 543–545.
- ASSAL G, PERENTES E, DERUAZ J-P (1981) Crossed aphasia in a right-handed patient. Postmortem findings. *Archives of Neurology, Chicago*, **38**, 455–458.
- BARRAQUER-BORDAS L, MENDILAHARSU C, PERES-SERRA J, MENDILAHARSU S A DE, GRAU-VECIANA J M (1963) Estudio de dos casos de afasia cruzada en pacientes manidextros. *Acta Neurologica Latinoamericana*, **9**, 140–148.

- BASSO A, CAPITANI E, VIGNOLO L A (1979) Influence of rehabilitation on language skills in aphasic patients. A controlled study. *Archives of Neurology, Chicago*, **36**, 190–196.
- BENSON D F (1967) Fluency in aphasia: correlation with radioactive scan localization. *Cortex*, **3**, 373–394.
- BENSON D F (1979) *Aphasia, Alexia, and Agraphia*. New York: Churchill Livingstone, pp. 30–33.
- BENSON D F, PATTEN D H (1967) The use of radioactive isotopes in the localization of aphasia-producing lesions. *Cortex*, **3**, 258–271.
- BENSON D F, SHEREMATA W A, BOUCHARD R, SEGARRA J M, PRICE D, GESCHWIND N (1973) Conduction aphasia. A clinicopathological study. *Archives of Neurology, Chicago*, **28**, 339–346.
- BOLLER F (1973) Destruction of Wernicke's area without language disturbance. A fresh look at crossed aphasia. *Neuropsychologia*, **11**, 243–246.
- BOTEZ M I, WERTHEIM N (1959) Expressive aphasia and amusia following right frontal lesion in a right-handed man. *Brain*, **82**, 186–202.
- BRAMWELL B (1899) On 'crossed' aphasia and the factors which go to determine whether the 'leading' or 'driving' speech-centres shall be located in the left or in the right hemisphere of the brain, with notes of a case of 'crossed' aphasia (aphasia with right-sided hemiplegia) in a left-handed man. *Lancet*, **i**, 1473–1479.
- BROCA P (1863) Localisation des fonctions cérébrales. Siège du langage articulé. *Bulletins de la Société d'Anthropologie de Paris*, **4**, 200–204.
- BROCA P (1865) Sur le siège de la faculté du langage articulé. *Bulletins de la Société d'Anthropologie de Paris*, **6**, 377–393.
- BROWN J W, HÉCAEN H (1976) Lateralization and language representation. Observations on aphasia in children, left-handers, and 'anomalous' dextrals. *Neurology, Minneapolis*, **26**, 183–189.
- BROWN J W, WILSON F R (1973) Crossed aphasia in a dextral. A case report. *Neurology, Minneapolis*, **23**, 907–911.
- BRUST J C M, PLANK C, BURKE A, GUOBADIA M M I, HEALTON E B (1982) Language disorder in a right-hander after occlusion of the right anterior cerebral artery. *Neurology, New York*, **32**, 492–497.
- CAMERON R F, CURRIER R D, HAERER A F (1971) Aphasia and literacy. *British Journal of Disorders of Communication*, **6**, 161–163.
- CARR M S, JACOBSON T, BOLLER F (1981) Crossed aphasia: analysis of four cases. *Brain and Language*, **14**, 190–202.
- CLARKE B, ZANGWILL O L (1965) A case of 'crossed aphasia' in a dextral. *Neuropsychologia*, **3**, 81–86.
- DAMASIO A R, CASTRO-CALDAS A, GROSSO J T, FERRO J M (1976) Brain specialization for language does not depend on literacy. *Archives of Neurology, Chicago*, **33**, 300–301.
- DAMASIO H (1981) Cerebral localization in the aphasias. In: *Acquired Aphasia*. Edited by M. T. Sarno. New York: Academic Press.
- DAMASIO H, DAMASIO A (1979) 'Paradoxical' ear extinction in dichotic listening: possible anatomic significance. *Neurology, Minneapolis*, **29**, 644–653.
- DAX M (1865) Lésions de la moitié gauche de l'encéphale coïncidant avec l'oubli des signes de la pensée. *Gazette Hebdomadaire de Médecine et de Chirurgie*, **2**, 259–260.
- DENES G, CAVIEZEL F (1981) Dichotic listening in crossed aphasia. 'Paradoxical' ipsilateral suppression. *Archives of Neurology, Chicago*, **38**, 182–185.
- ETTLINGER G, JACKSON C V, ZANGWILL O L (1955) Dysphasia following right temporal lobectomy in a right-handed man. *Journal of Neurology, Neurosurgery and Psychiatry*, **18**, 214–217.
- FOROGLIOU G, ASSAL G, ZANDER E (1975) Une nouvelle observation d'aphasie croisée chez un droitier. *Archives Suisses de Neurologie, Neurochirurgie et de Psychiatrie*, **117**, 205–210.
- GAINOTTI G, TIACCI C (1970) Patterns of drawing disability in right and left hemispheric patients. *Neuropsychologia*, **8**, 379–384.

- GALLOWAY L M (1981) The convolutions of second language: a theoretical article with a critical review and some new hypotheses towards a neuropsychological model of bilingualism and second language performance. *Language Learning*, **31**, 439–464.
- GLONING I, GLONING K, HAUB G, QUATEMBER R (1969) Comparison of verbal behavior in right-handed and non right-handed patients with anatomically verified lesion of one hemisphere. *Cortex*, **5**, 43–52.
- GOODGLASS H (1976) Agrammatism. In: *Studies in Neurolinguistics*. Volume 1. Edited by H. Whitaker and H. A. Whitaker. New York: Academic Press.
- GOODGLASS H, KAPLAN E (1972) *The Assessment of Aphasia and Related Disorders*. Philadelphia: Lea and Febiger.
- GOODGLASS H, QUADFASSEL F A (1954) Language laterality in left-handed aphasics. *Brain*, **77**, 521–548.
- GOODGLASS H, QUADFASSEL F A, TIMBERLAKE W H (1964) Phrase length and the type and severity of aphasia. *Cortex*, **1**, 133–153.
- GORDON H W, BOGEN J E (1974) Hemispheric lateralization of singing after intracarotid sodium amylobarbitone. *Journal of Neurology, Neurosurgery and Psychiatry*, **37**, 727–738.
- HAALAND K Y, MIRANDA F (1982) Psychometric and CT scan measurements in a case of crossed aphasia in a dextral. *Brain and Language*, **17**, 240–260.
- HARASYMIW S J, HALPER A, SUTHERLAND B (1981) Sex, age, and aphasia type. *Brain and Language*, **12**, 190–198.
- HÉCAEN H, AJURIAGUERRA J DE (1964) *Left-handedness. Manual Superiority and Cerebral Dominance*. New York: Grune and Stratton.
- HÉCAEN H, MARCIE P (1974) Disorders of written language following right hemisphere lesions: spatial dysgraphia. In: *Hemisphere Function in the Human Brain*. Edited by S. J. Dimond and J. G. Beaumont. London: Elek Science.
- HÉCAEN H, MAZARS G, RAMIER A M, GOLDBLUM M C, MÉRIENNE L (1971) Aphasie croisée chez un sujet droitier bilingue (vietnamien-français). *Revue Neurologique*, **124**, 319–323.
- HOLMES J E, SADOFF R L (1966) Aphasia due to a right hemisphere tumor in a right-handed man. *Neurology, Minneapolis*, **16**, 392–397.
- HOWES D (1964) Application of the word-frequency concept to aphasia. In: *Ciba Foundation Symposium on Disorders of Language*. Edited by A. V. S. de Reuck and M. O'Connor. London: J. and A. Churchill.
- HOWES D (1967) Some experimental investigations of language in aphasia. In: *Research in Verbal Behavior and Some Neurophysiological Implications*. Edited by K. Salzinger and S. Salzinger. New York: Academic Press.
- JACKSON J H (1868) Defect of intellectual expression (aphasia) with left hemiplegia. *Lancet*, **i**, 457.
- JACKSON J H (1915) On the nature of the duality of the brain. *Brain*, **38**, 80–103.
- KENNEDY F (1916) Stock-brainedness, the causative factor in the so-called 'crossed aphasias'. *American Journal of the Medical Sciences*, **152**, 849–859.
- KERSCHENSTEINER M, POECK K, BRUNNER E (1972) The fluency-non fluency dimension in the classification of aphasic speech. *Cortex*, **8**, 233–247.
- KREINDLER A, FARDIS A, SEVASTOPOL N (1966) La répartition des dominances hémisphériques. *Neuropsychologia*, **4**, 143–149.
- LEVY J, REID M (1976) Variations in writing posture and cerebral organization. *Science*, **194**, 337–339.
- LOZANO R A, CLARK C A (1976) Aphasia recovery of a right-handed individual with right cerebral hemisphere infarction. In: *Clinical Aphasiology Conference Proceedings, 1976*. Edited by R. H. Brookshire. Minneapolis: BRK Publishers.
- MCGLONE J (1977) Sex differences in the cerebral organization of verbal functions in patients with unilateral brain lesions. *Brain*, **100**, 775–793.
- MARINESCO G, GRIGORESCO D, AXENTE S (1938) Considérations sur l'aphasie croisée. *Encéphale*, **33**, 27–46.

- MAZZOCCHI F, VIGNOLO L A (1979) Localisation of lesions in aphasia: clinical-CT scan correlations in stroke patients. *Cortex*, **15**, 627-653.
- MESULAM M-M (1981) A cortical network for directed attention and unilateral neglect. *Annals of Neurology*, **10**, 309-325.
- MESULAM M-M, WAXMAN S G, GESCHWIND N, SABIN T D (1976) Acute confusional states with right middle cerebral artery infarctions. *Journal of Neurology, Neurosurgery and Psychiatry*, **39**, 84-89.
- MINKOWSKI M (1963) On aphasia in polyglots. In: *Problems of Dynamic Neurology*. Edited by L. Halpern. Jerusalem: Jerusalem Post Press.
- MOHR J P (1976) Broca's area and Broca's aphasia. In: *Studies in Neurolinguistics*. Volume 1. Edited by H. Whitaker and H. A. Whitaker. New York: Academic Press.
- MOHR J P (1980) The vascular basis of Wernicke's aphasia. *Transactions of the American Neurological Association*, **105**, 133-137.
- MOHR J P, PESSIN M S, FINKELSTEIN S, FUNKENSTEIN H H, DUNCAN G W, DAVIS K R (1978) Broca aphasia: pathologic and clinical. *Neurology, Minneapolis*, **28**, 311-324.
- MOUTIER F (1908) *L'Aphasie de Broca*. Paris: Steinheil, pp. 115-128.
- NAIR K R, VIRMANI V (1973) Speech and language disturbances in hemiplegics. *Indian Journal of Medical Research*, **61**, 1395-1403.
- OJEMANN G A, WHITAKER H A (1978) The bilingual brain. *Archives of Neurology, Chicago*, **35**, 409-412.
- OLDFIELD R C (1971) The assessment and analysis of handedness: the Edinburgh Inventory. *Neuropsychologia*, **9**, 97-113.
- PARADIS M (1977) Bilingualism and aphasia. In: *Studies in Neurolinguistics*. Volume 3. Edited by H. Whitaker and H. A. Whitaker. New York: Academic Press.
- PATERSON A, ZANGWILL O L (1944) Disorders of visual space perception associated with lesions of the right cerebral hemisphere. *Brain*, **67**, 331-358.
- PIERCY M, HÉCAEN H, AJURIAGUERRA J DE (1960) Constructional apraxia associated with unilateral cerebral lesions—left and right sided cases compared. *Brain*, **83**, 225-242.
- PILLON B, DESI M, LHERMITTE F (1979) Deux cas d'aphasie croisée avec jargonographie chez des droitiers. *Revue Neurologique*, **135**, 15-30.
- PITRES A (1895) Étude sur l'aphasie chez les polyglottes. *Revue de Médecine*, **15**, 873-899.
- POECK K, KERSCHENSTEINER M, HARTJE W (1972) A quantitative study on language understanding in fluent and nonfluent aphasia. *Cortex*, **8**, 299-304.
- ROBERTS L (1951) Localization of speech in the cerebral cortex. *Transactions of the American Neurological Association*, **76**, 43-50.
- ROSS E D (1981) The aprosodias. Functional-anatomic organization of the affective components of language in the right hemisphere. *Archives of Neurology, Chicago*, **38**, 561-569.
- SEMMES J (1968) Hemispheric specialization: a possible clue to mechanism. *Neuropsychologia*, **6**, 11-26.
- SILVERBERG R, GORDON H W (1979) Differential aphasia in two bilingual individuals. *Neurology, Minneapolis*, **29**, 51-55.
- SPARKS R, GOODGLASS H, NICKEL B (1970) Ipsilateral versus contralateral extinction in dichotic listening resulting from hemisphere lesions. *Cortex*, **6**, 249-260.
- SUBIRANA A (1958) The prognosis in aphasia in relation to cerebral dominance and handedness. *Brain*, **81**, 415-425.
- TROJANOWSKI J Q, GREEN R C, LEVINE D N (1980) Crossed aphasia in a dextral: a clinicopathological study. *Neurology, Minneapolis*, **30**, 709-713.
- URBAIN E, SERON X, REMITS A, COBBEN A, VAN DER LINDEN M, MOUCHETTE R (1978) Aphasie croisée chez une droitère. A propos d'une observation. *Revue Neurologique*, **134**, 751-759.
- WADA J, RASMUSSEN T (1960) Intracarotid injection of sodium amytal for the lateralization of cerebral speech dominance. Experimental and clinical observations. *Journal of Neurosurgery*, **17**, 266-282.
- WAGENAAR E, SNOW C, PRINS R (1975) Spontaneous speech of aphasic patients: a psycholinguistic analysis. *Brain and Language*, **2**, 281-303.

- WARRINGTON E K, JAMES M, KINSBOURNE M (1966) Drawing disability in relation to laterality of cerebral lesion. *Brain*, **89**, 53–82.
- WECHSLER A F (1976) Crossed aphasia in an illiterate dextral. *Brain and Language*, **3**, 164–172.
- WECHSLER D (1955) *Wechsler Adult Intelligence Scale Manual*. New York: The Psychological Corporation.
- WERNICKE C (1908) The symptom-complex of aphasia. In: *Modern Clinical Medicine. Diseases of the Nervous System*. Edited by A. Church. New York: Appleton, pp. 265–324.
- YARNELL P R (1981) Crossed dextral aphasia: a clinical radiological correlation. *Brain and Language*, **12**, 128–139.
- YARNELL P R, MONROE P, SOBEL L (1976) Aphasia outcome in stroke: a clinical neuroradiological correlation. *Stroke*, **7**, 516–522.
- ZANGWILL O L (1979) Two cases of crossed aphasia in dextrals. *Neuropsychologia*, **17**, 167–172.

(Received September 23, 1982. Revised February 10, 1983)