

Angiographical Analysis of Acute Cerebral Infarction Followed by "Cascade"-Like Deterioration of Minor Neurological Deficits. What is Progressing Stroke?

TADAYOSHI IRINO, M.D., MANABU WATANABE, M.D., MASATO NISHIDE, M.D.,
MOTOKI GOTOH, M.D., AND TAKASHI TSUCHIYA, M.D.

SUMMARY In order to understand the mechanism of clinical worsening in patients with cerebral infarction, attention was focused on the changes in cerebral angiograms obtained repeatedly before and after neurological deterioration. Among 212 stroke patients with minor neurological deficits, incomplete hemiparesis progressed to complete hemiplegia in 15 patients several days after the beginning of symptoms. On admission, 3 had internal carotid artery occlusion, 2 had stenosis of the internal carotid artery, 5 had occlusion of the middle cerebral arterial trunk, 2 had occlusion of the middle cerebral arterial branch, and 3 had no angiographically visible occlusion. The changes between the first and the second angiograms were of different varieties: another recurrent occlusion, progression of occlusion, new occlusion in the cerebral arteries opacified through the collateral pathway, recanalization of the initially occluded artery, and no change. Such different patterns of pathophysiological events show that the mechanism of neurological worsening in infarcted patients is not uniform. Based on the results from the present study, several problems which arose during the investigation and the somewhat vague definition of "progressing stroke" currently in use are discussed.

Stroke, Vol 14, No. 3, 1983

VARIOUS KINDS OF TEMPORAL PROFILE exist for the symptomatological patterns of cerebrovascular disease. Transient ischemic attack, completed stroke, reversible ischemic neurological deficit, and progressing stroke are the clinical categories generally accepted. Especially in the acute stage of stroke, except for transient ischemic attack, clinical worsening of the neurological symptoms can be observed not infrequently by repeated careful observations. Clinical worsening of neurological symptoms in infarcted patients is generally caused by several intra- and/or extracranial pathological conditions. Recurrent attack also must be taken into consideration. The mode of deterioration is either, abrupt, stepwise or linear slope-like. In some cases, therefore, the definition between progressing stroke and other types of stroke followed by deterioration is not easy. The reasons, we consider, are that the definition of progressing stroke is obscure when compared with transient ischemic attack and that the pathophysiological aspects of progressing stroke have not been as fully investigated as other types of stroke.

In the present study, in order to understand the mechanism of clinical worsening in infarcted patients, attention was focused on the changes in neuroradiological examinations before and after clinical worsening in patients who had minor neurological deficits at the beginning of ischemic cerebrovascular disease. Results showed that the mechanism of clinical worsening was not uniform but complicated with various alterations of cerebral arterial occlusion. This paper also discusses several actual problems in the clinical study of progressing stroke and the need for clarification of the terminology.

Material and Methods

Patients selected for the present study were among

From the Division of Cerebrovascular Diseases, Hanwa Hospital, 11-11-7, Karita, Sumiyoshi, Osaka 558, Japan.
Received December 3, 1981; revision accepted January 18, 1983.

510 stroke patients admitted to the Division of Cerebrovascular Diseases of Hanwa Hospital between April 1978 and October 1980. All were diagnosed following physical and neuroradiological examinations including computed tomographies and/or cerebral angiographies. Among them, 212 patients diagnosed as having ischemic cerebrovascular disease had neither consciousness disorder nor complete hemiplegia; and 182 of them had incomplete hemiparesis, of whom 15 progressed to same-sided complete hemiplegia within several days after onset. The time intervals between onset and clinical worsening are summarized in figure 1.

The clinical and angiographical findings of these 15 patients are summarized in table 1 and 2. Thirteen were diagnosed as having ischemic stroke in the territory of the internal carotid artery, while the affected area of the remaining 2 was in the vertebrobasilar artery territory. Three had internal carotid artery occlusion, 2 had stenosis of the internal carotid artery, and 5 had occlusion or stenosis of the middle cerebral arterial branch. Angiographically visible occlusion of the cerebral arteries was not observed in 1 patient affected in the internal carotid artery territory, and in 2 patients affected in the vertebrobasilar artery territory.

For the 15 cases, additional cerebral angiographies and computed tomographies were performed after neurological worsening in order to check what had happened in the process of neurological deterioration. Angiographical changes observed before and after neurological deterioration were compared with each other to understand the pathophysiological developments participating in their neurological deterioration.

The judgment of neurological deterioration in the present study was based on the progression from incomplete hemiparesis to same-sided complete hemiplegia, with or without development of consciousness disorder. The initial neurological deficits lasted at least for more than 6 hours without symptomatological worsening. Eight patients with an unstable neurologi-

Intervals between Onset and Neurological Deterioration in 15 Cases of Ischemic Stroke

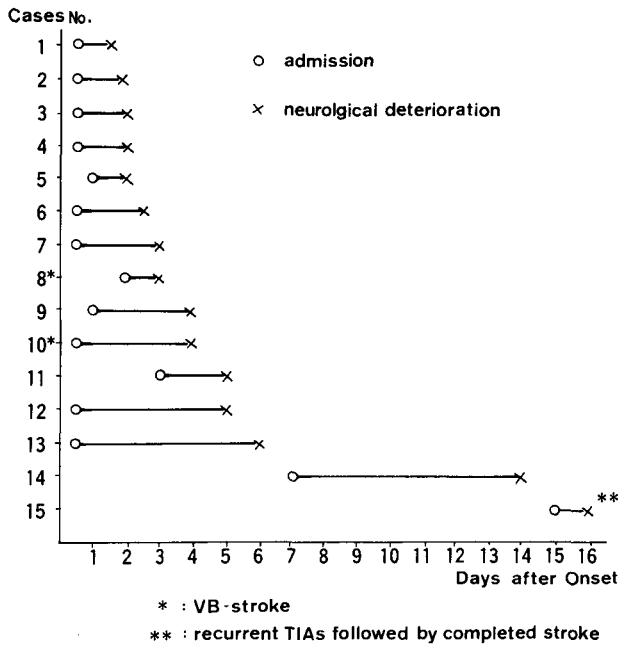


FIGURE 1. Intervals between onset and neurological deterioration in 15 cases of ischemic stroke.

cal condition, within a few hours after onset, were excluded from the present study. Those who developed motor dysfunction in the side contralateral to the initially affected side were also excluded, because this was assumed to be caused by another stroke, although it cannot be denied completely that a same-sided deterioration was caused by recurrent stroke.

Results

The changes in the repeated angiograms are summarized in table 3. The changes seen were of different varieties; i.e., recanalization, other occlusions, progression of the occlusion from the distal to the proximal portion, new occlusions in the cerebral arteries opacified through the collateral pathway, and no change. Computed tomography showed an increased low density area in three patients, while one case showed apparent hemorrhagic infarction after angio-

TABLE 1 Clinical Findings in 15 Patients Followed by Neurological Deterioration

Age	67 y.o. (average; 52-84)
Sex (M/F)	8/7
AF (+)	5
HBP	6
DM	3
p-stroke	
≦ 1 year	3
> 1 year	5

AF: atrial fibrillation, DM: diabetes mellitus, HBP: hypertension, p-stroke: previous stroke.

TABLE 2 Angiographical Findings on Admission in 15 Patients Followed by Apparent Neurological Deterioration

ICA: 13 cases	
ICA occlusion	3
stenosis	2
MCA stem occlusion	4
stem stenosis	1
MCA branch occlusion	2
non-visible occlusion	1*
VA: 2 cases	
non-visible occlusion	2*
Total	15 cases

*Non-visible is applied for those who had no angiographically visible occluded artery.

graphical recanalization of the initially occluded artery. Here are some typical patients who showed neurological deterioration (see fig. 1):

Case 1 (Case 7 in fig. 1)

A 46-year-old right-handed female was admitted 12 hours after the beginning of left-side hemiparesis with mild numbness. She could move her left arm and leg against gravity. Consciousness disturbance was not observed. The Babinski reflex was positive for the left side. Blood pressure on admission was 142/86 mm Hg and EKG revealed atrial fibrillation. Auscultation of the heart showed diastolic murmur typical of mitral regurgitation. The right carotid angiogram on admission showed occlusion of the right middle cerebral artery at its trifurcation, and the result of computed tomography was judged as normal.

The degree of hemiparesis gradually progressed to more on the second day of hospitalization. On the morning of the third day, the patient was alert and complained of complete left-sided hemiplegia. She could not move her left arm and leg even against slight gravity. At that time, additional angiography showed recanalization of the initially occluded point and computed tomography showed an apparent high density area suggesting the occurrence of hemorrhagic infarction (fig. 2).

Case 2 (Case 6 in fig. 1)

A 54-year-old right-handed male was admitted within 24 hours after onset following repeated epi-

TABLE 3 Alterations of Cerebral Angiographies Before and After Neurological Deterioration

I. recanalization	2 cases
II. progression of occlusion	
a. propagation	3
b. stenosis to occlusion	3
c. non-visible occlusion to stenosis	2*
III. occlusion on collateral	4
IV. no change	1
Total	15 cases

*Basilar artery occlusion.

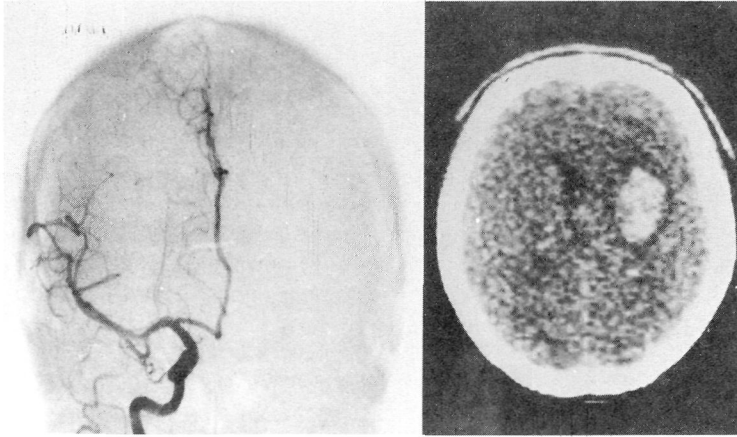


FIGURE 2. Right carotid angiogram and computed tomography in case 1 showing circulatory restoration and hemorrhagic infarction after recanalization of initially occluded middle cerebral artery at its trifurcation.

sodes of left-sided hemiparesis and numbness accompanying contralateral ocular nerve palsy. The deficits lasted for two days and right brachial retrograde angiography showed no visible angiographical occlusion in the territory of right carotid and vertebrobasilar artery. The degree of hemiparesis progressed a little on the next day. Two days later he developed consciousness disorder and complete left-sided hemiplegia. The Babinski was positive for the right as well as the left. At that time, transfemoral vertebral angiography was done and occlusion of the basilar artery was diagnosed. Computed tomography, repeatedly done, showed no diagnostic abnormalities.

Case 3 (Case 11 in fig. 1)

A 62-year-old right-handed male was admitted three days after the development of unilateral numbness. On August 23 1980, he suddenly developed right-sided hemiparesis and numbness with motor aphasia, but disturbance of consciousness was not observed. Nearly 10 hours after the beginning of right-sided hemiparesis, left-sided carotid angiography showed occlusion of the internal carotid artery and right carotid angiography clearly showed partial visualization of the middle cerebral arterial tree through the anterior communicating artery (fig. 3 (a)). On the following day, nearly 48 hours later, his hemiparesis progressed to complete hemiplegia without consciousness disturbance. Angiography at the time of clinical worsening demonstrated no change of the occluded internal carotid artery, but showed the occlusion opacified through the collateral pathway at its trifurcation (fig. 3 (b)).

Case 4 (Case 13 in fig. 1)

A 67-year-old right-handed female was admitted suffering from sudden onset of left-sided incomplete hemiparesis. Computed tomography on admission gave normal results and cerebral angiography showed occlusion of the right internal carotid artery with pretty good opacification of anterior and middle cerebral arterial trees through pial anastomosis (fig. 4 (a)). The Babinski reflex was positive on the left. Until the end of the fifth day, the hemiparesis showed gradual deterioration. On the sixth day of hospitalization, the hemiparesis progressed to complete hemiplegia, and less

apparent opacification of the middle cerebral arterial trees was diagnosed with the second angiography (fig. 4 (b)). Computed tomography, repeatedly performed, showed a low density area typical of middle cerebral arterial occlusion.

Case 5 (Case 9 in fig. 1)

A 63-year-old right-handed male was admitted following sudden onset of right-sided hemiparesis with motor aphasia. He could handle his right arm and leg against gravity. The Babinski was positive for the right side. On admission, nearly 7 hours after onset, computed tomography gave normal results, while left cerebral angiography demonstrated occlusion of the middle cerebral artery at its trifurcation. The patient was diagnosed as not having rheumatic heart disease even by two-dimensional echocardiography. EKG showed no atrial fibrillation. Hemiparesis showed slight progression on the third day. On the fourth day of hospitalization, the hemiparesis progressed to complete hemiplegia with decreased patellar tendon reflex with a positive Babinski sign. At the time, cerebral angiography showed occlusion of the middle cerebral artery at its trunk.

Discussion

Even patients showing angiographically minimal or nonvisible cerebral arterial occlusion frequently develop clinical worsening of neurological signs in careful neurological follow-up. In some cases with unilateral acute internal carotid arterial occlusion, consciousness disturbance apparently progresses from mild to severe in the acute stage¹ in which advancing brain edema might be considered to be responsible for the neurological deterioration.² In addition to pathophysiological events in the brain secondary to primary cerebrovascular occlusion, (i.e., ischemia, brain edema, and hemorrhagic infarction) recurrent stroke or visceral complications (such as pneumonia or renal insufficiency) are considered to be crucial factors.^{3,4} Visceral complications are mostly observed in patients suffering from severe brain damage with neurogenic influence on the visceral organs, while recurrence and intracerebral pathophysiological events may play roles in clinical worsening in those with all degrees of severity.

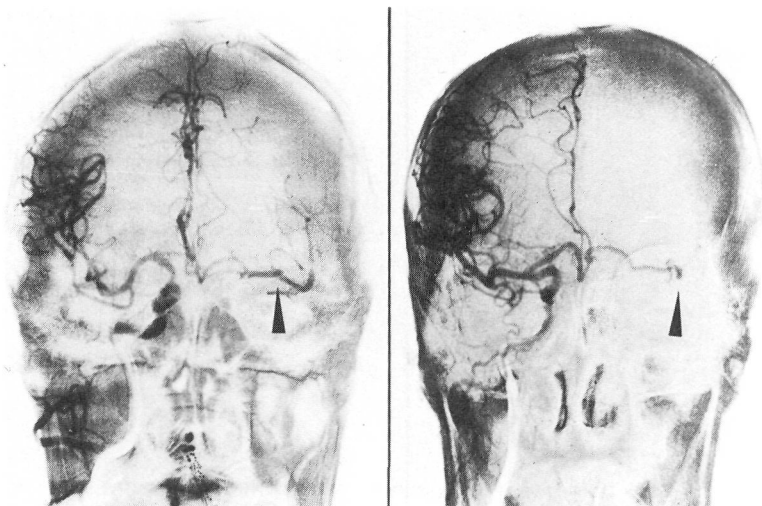


FIGURE 3. (a) (b) Repeated angiograms in case 3. Progression of occlusion of the middle cerebral artery opacified through anterior communicating artery can be seen.

The results of our study also suggest that patients with minor neurological deficits at the beginning of their symptoms are affected by varieties of vascular events, most of which can be considered to have a causative relationship with initial cerebrovascular occlusion. Although the definite conclusion cannot be obtained, cases 2 and 3 might be due to recurrence, while the other cases (cases 1, 2 and 5) might be caused by sequelae following initial occlusion. Thus the clinical

profile of progressing stroke also seems to be caused by different pathophysiological aspects, which might be one of the reasons that clinical stages such as transient ischemic attack, completed stroke, or progressing stroke have been simply classified based on their clinical features without these complicated pathological features being taken into consideration.⁵ However, detailed grouping of the clinical stages is sometimes necessary in order to perform specific treatment against clinical worsening, because pathophysiological events participating in the neurological deterioration are quite different as the present study has shown, as far as the changes of occlusive findings of cerebral arteries are concerned. The mechanism of the recurrent attack must be separated from other mechanism of clinical worsening.

The intracranial pathophysiological events in patients with ischemic cerebrovascular disease can be classified into two categories; occlusive changes in cerebral arteries and ischemic changes in the brain. These two are probably interrelated. The pathophysiological aspects for cerebral arterial occlusion can be conceptionally divided into two categories; progression of occlusion and recanalization of the occluded

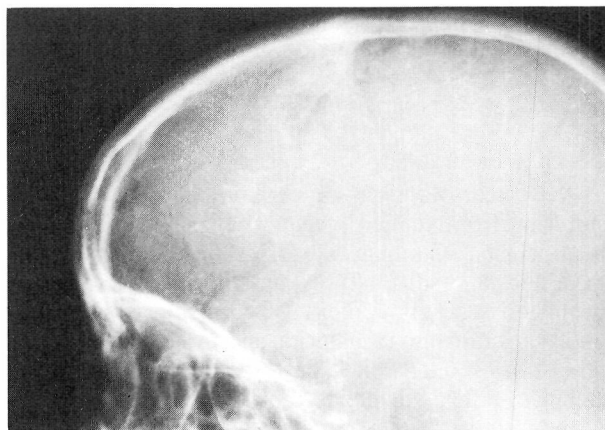
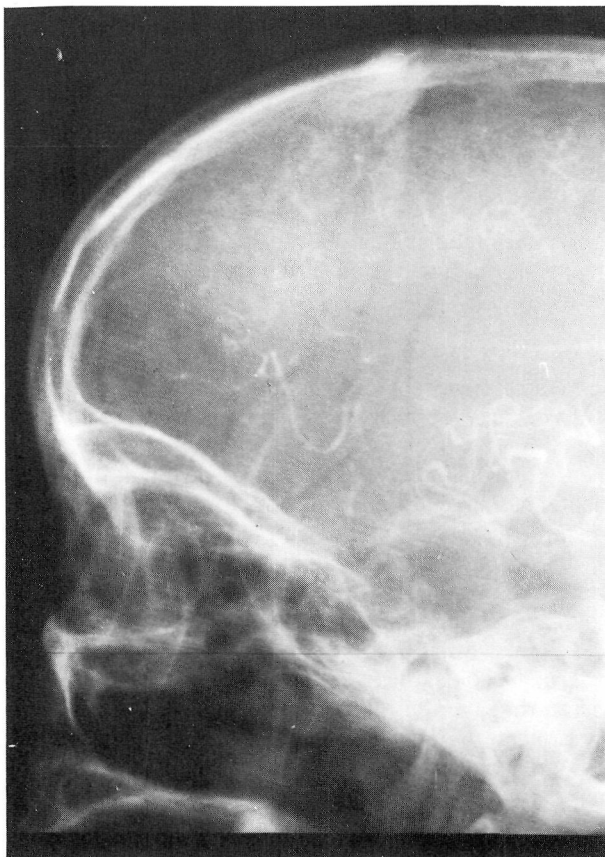

FIGURE 4. (a) (b) Repeated angiograms in case 4. Lessening of retrograde opacification of middle cerebral arterial trees through pial anastomosis can be noted.

artery. Lhermitte et al.⁶ reported that progression of the occlusion can be further divided into antegrade and retrograde thrombi. However, antegrade thrombus is difficult to detect even by careful reading of angiographies, because the contrast medium cannot reach into the distal portion beyond the arterial occlusion. Retrograde thrombus can often be recognized by repeated angiographies as a progression of the occlusion point from the distal to the proximal portion. However, we must remember that a newly developed embolus arising from any extracranial embolic source like the carotid artery or the heart would also show similar angiographical features. Therefore, the progression of occlusion seen in the present study might be due to an antegrade thrombus or a new embolus. Occlusion of the middle cerebral artery opacified through the anterior communicating artery in the internal carotid artery occlusion, as seen in case 3, might be caused by a newly developed embolic process either from an extracranial embolic source through a non-occluded internal carotid artery of the opposite side or from an occluded internal carotid arterial stump. The embolic process originating from the carotid stump has been well explained by Barnett et al.⁷ as for that through the reversed ophthalmic artery. Combined occlusion of middle cerebral artery supplied by collateral pathway in patients having internal carotid artery was reported by Ring.⁸ Another phenomenon, referred to as spontaneous recanalization, must also be taken into consideration when considering the pathophysiological changes of the infarcted brain. Some previous authors⁹⁻¹¹ have also paid attention to the angiographical circulatory restoration and found that this phenomenon mostly does not contribute to neurological improvement but to clinical worsening accompanying hemorrhagic infarction as seen in case 1. Summarizing the pathophysiological aspects for cerebrovascular occlusion shows that the mechanism participating in the development of clinical worsening is not uniform. These facts can be considered to explain controversies surrounding the therapeutic effects against various types of ischemic cerebrovascular disease including progressing stroke.

Although little has been reported about progressing stroke, a recent description of the treatment of progressing stroke by Millikan and McDowell¹² has contributed to the rearrangement of some ideas on stroke of this kind of clinical profile. A description has been given by Adams et al.¹ They retrospectively studied and observed pathological findings and comparatively observed clinical courses, then suggested that progression of occlusion of the cerebral arteries might occur in progressing stroke, although they stressed that it was very difficult to analyze the pathogenesis of progressing stroke using retrospective pathological study. Of the 4 cases described in their paper, 3 were patients having ischemic stroke in the territory of the vertebrobasilar artery and 1 in the internal carotid arterial territory. However, they did not give the details for the definition of progressing stroke. Also, their paper was published before the Ad Hoc Committee's definition

of 1975,⁵ and thus it is not clear if the profile of progressing stroke in their paper is suitable for comparison with current concepts. For example, they counted visceral complication as a cause of clinical worsening, especially in patients with late or terminal worsening with consciousness disorders; but this kind of deterioration process is seldom seen in patients with worsening of minor neurological deficits, as seen in the present study. Whisnant,¹³ commenting on a paper dealing with progressing stroke by Adams et al., said that whether "progressing occlusion" or "thrombosis with progressing ischemia" participate in neurological deterioration would be investigated.

The Ad Hoc Committee in 1975⁵ has defined progressing stroke as follows: "This category represents the common circumstance where focal ischemia is worsening and the process of infarction is beginning or extending." A case example was given to explain the clinical profile of progressing stroke. However, especially compared with TIA, the definition of progressing stroke is vague. This might be explained by the small number of papers concerning progressing stroke, because the nature, the degree, or the time duration of the neurological symptoms have not been defined in enough detail for a common working base for different investigators. In addition, several problems which have not yet been discussed, arise during the actual observations or judgment of progressing stroke: 1) Is the definition of progressing stroke clear-cut compared with TIA? 2) How to distinguish progressing stroke from natural course? 3) How to distinguish it from recurrence? 4) How to continue clinical observation even with interruption by patients' sleep period? In our present study using repeated cerebral angiographies, the clinical profile showing neurological worsening might be due to angiographical side effects, although the incidence of side effects in our institute has been low. Based on the answers to these practical problems and the present results obtained by neuroradiological analyses of stroke patients showing neurological deterioration (which might be expressed as "cascade stroke") the concept of the so-called "progressing stroke" should be clearly defined as soon as possible.

References

1. Adams RD, Torvik A, Fisher CM: Progressing stroke. Pathogenesis, *In* Millikan CH, Siekert RG, Whisnant JP (eds), *Cerebral vascular disease, Third Princeton Conference*, Grune & Stratton, New York, 1961, pp 133-150
2. Bruce DA, Hurtig HI: Incidence, course and significance of cerebral edema associated with cerebral infarction. *In* Price TR, Nelson E (eds), *Cerebrovascular disease, Eleventh Princeton Conference*, Raven Press, New York, 1979, pp 191-198
3. Meyer JS: Course, prognosis and medical management of patients with acute stroke. *In* Meyer JS, Shaw T (eds). "Diagnosis and management of stroke and TIAs". Addison-Wesley Publishing Company Inc., USA, 1982, pp 155-172
4. Carter AB: Prognosis of cerebral embolism. *Lancet* 2: 514-519, 1965
5. Millikan CH, Bauer RB, Goldschmidt J, et al.: A classification and outline of cerebrovascular disease. II. *Stroke* 6: 564-616, 1975
6. Lhermitte F, Gautier JC: Sites of cerebral arterial occlusion. *In* Williams D (ed), *Modern Trends in Neurology*, Butterworths, London, 1965, pp 123-140

7. Barnett HJM, Peerless SJ, Kaufmann JCE: "Stump" of internal carotid artery. A source of further cerebral embolic ischemia. *Stroke* 9: 448-456, 1978
8. Ring BA: Occlusio supra occlusionem. Intracranial occlusions following carotid thrombosis as diagnosed by cerebral angiography. *Stroke* 2: 487-493, 1971
9. Bladin PF: A radiologic and pathologic study of embolism of the internal carotid-middle cerebral arterial axis. *Radiology* 82: 615-624, 1964
10. Dalal PM, Shah PM, Aiyar RR: Arteriographic study of cerebral embolism. *Lancet* 1: 358-361, 1965
11. Irino T, Taneda M, Minami T: Sanguineous cerebrospinal fluid in recanalized cerebral infarction. *Stroke* 8: 24-27, 1977
12. Millikan CH, McDowell FH: Progress in cerebrovascular disease. Treatment of Progressing stroke. *Stroke* 12: 397-409, 1981
13. Whisnant JP: Discussion in Ref. (3)

Platelet Aggregability in Cerebral Thrombosis — Analyzed for Vessel Stenosis

YUZO OTSUKI, M.D.,* TOMOKO KONDO, M.D.,* HIDEO SHIO, M.D.,*
MASAKUNI KAMEYAMA, M.D.,* AND TSUNEMARO KOYAMA, M.D.†

SUMMARY Platelet aggregation in the post-acute phase of 48 patients with cerebral thrombosis was measured to see if any specific type of cerebral infarction is associated with enhanced platelet aggregation. All patients were examined with cerebral angiography and computed tomography (CT). Stenotic lesions in major cranial arteries were analyzed by measuring the apparent diameter. Severe stenosis was defined as 75 per cent constriction or more. Enhanced aggregation of platelets (secondary aggregation at 1 μ M ADP or less) was present in 5 of 25 patients (20%) who had severe vessel stenosis or occlusion. CT examination frequently revealed both cortical and deep involvement. On the other hand, 13 of 23 patients (57%) with less stenotic lesions showed enhanced aggregation and that was statistically significant ($p < 0.05$). Many patients of this group had persistent hypertension and small deep infarctions. Platelet aggregation was also measured in 20 hypertensive control subjects without stroke. Four of them (20%) showed enhanced aggregation. These findings suggest that a combination of enhanced platelet aggregation and hypertension increases the risk of small deep infarctions accompanied by mild stenotic changes of the major cranial arteries.

Stroke, Vol 14, No 3, 1983

SINCE IT WAS OBSERVED that arterial thrombus is initiated by white plugs of platelet, enhanced platelet activity as a risk factor for cardio and cerebrovascular diseases has been a matter of concern among many investigators. Computed tomography (CT) provides a useful tool to differentiate between cortical and deep cerebral infarctions. Previously noted risk factors should be re-evaluated with respect to each type of cerebral infarction. We studied platelet aggregation in patients with cerebral thrombosis who had CT and angiographic evaluation to assess the correlation between enhanced platelet aggregation, degree of vessel stenosis and type of cerebral infarction.

Patients and Methods

The diagnosis of cerebral thrombosis was based upon the clinical histories, neurological evaluations, CSF findings, and supported by above specialized examinations. Patients with myocardial infarction and/or atrial fibrillation were excluded because of the well-known association of embolism. A total of 48 patients were divided into two groups, according to their angiographic findings. Angiograms were analyzed for major

cranial artery abnormalities, e.g. the internal carotid, M₁ portions of middle cerebral, the vertebral, the basilar, and proximal portions of the posterior cerebral arteries. The severe stenotic group which showed 75 per cent or more constriction in some of these major cranial arteries consisted of 25 patients (19 males, 6 females, mean age 50 years). The remaining 23 patients (15 males, 8 females, mean age 58 years) were included in the less stenotic group: their angiograms showed moderate constriction (less than 75 per cent) or no stenosis.

Angiographic examination were usually performed by the direct puncture method and selection of appropriate vessels was based upon clinical symptoms, e.g. a left carotid angiogram was performed for a right hemiparesis. Complete four vessels study was undertaken in only a few patients. Diabetes mellitus was found in three patients, 2 in the severe stenotic and one in the less stenotic group. All hypertensive patients in the less stenotic group received antihypertensive medication. Despite this, labile hypertension persisted in half of the patients and the remaining half were highly resistant to therapy. The majority of the severe stenotic group were almost normotensive and required no therapy for hypertension after their stroke.

Platelet aggregation was examined by Born's turbidometric method, in the post-acute period of cerebral thrombosis (more than two weeks after onset). No subject was taking drugs known to affect platelet function within 7 days prior to examination. Blood was

From the *Department of Neurology and Geriatric Medicine, Faculty of Medicine, Kyoto University, 54 Shogoin-Kawaracho, Sakyo-ku, Kyoto 606, Japan, and †the Department of Neurosurgery, Ohtsu Municipal Hospital, 9-9 Motomiya, Ohtsu, Shiga, 520 Japan.

Address correspondence to: Yuzo Otsuki, M.D., 9-102 Kuze-Kamihotani, Jojo, Kyoto 610. Received July 28, 1981; second revision accepted October 27, 1982.

Angiographical analysis of acute cerebral infarction followed by "cascade"-like deterioration of minor neurological deficits. What is progressing stroke?

T Irino, M Watanabe, M Nishide, M Gotoh and T Tsuchiya

Stroke. 1983;14:363-368

doi: 10.1161/01.STR.14.3.363

Stroke is published by the American Heart Association, 7272 Greenville Avenue, Dallas, TX 75231

Copyright © 1983 American Heart Association, Inc. All rights reserved.

Print ISSN: 0039-2499. Online ISSN: 1524-4628

The online version of this article, along with updated information and services, is located on the World Wide Web at:

<http://stroke.ahajournals.org/content/14/3/363>

Permissions: Requests for permissions to reproduce figures, tables, or portions of articles originally published in *Stroke* can be obtained via RightsLink, a service of the Copyright Clearance Center, not the Editorial Office. Once the online version of the published article for which permission is being requested is located, click Request Permissions in the middle column of the Web page under Services. Further information about this process is available in the [Permissions and Rights Question and Answer](#) document.

Reprints: Information about reprints can be found online at:
<http://www.lww.com/reprints>

Subscriptions: Information about subscribing to *Stroke* is online at:
<http://stroke.ahajournals.org/subscriptions/>