

- tical reference to transtentorial herniation and the pathogenesis of secondary brain-stem hemorrhages. *Am J Pathol* **53**: 391-399, 1968
12. Vincent C, David M, Thiebaut F: Le cone de pression temporal dans les tumeurs des hémisphères cérébraux. Sa symptomatologie, sa gravité, les traitements qu'il convient de lui opposer. *Rev Neurol (Paris)* **65**: 536-545, 1936
  13. Van Gehuchten P: Le mécanisme de la mort dans certains cas de tumeur cérébrale. *Encéphale* **2**: 113-127, 1937
  14. Jefferson G: Tentorial pressure cone. *Arch Neurol Psychiat (Chicago)* **40**: 857-876, 1938
  15. Poppen JL, Kendrick JFJR, Hicks SF: Brain stem hemorrhages secondary to supratentorial space-taking lesions. *J Neuroopath Exp Neurol* **11**: 267-279, 1952
  16. Evans JP, Scheinker IM: Histologic studies of the brain following head trauma. *Arch Neurol Psychiat (Chicago)* **50**: 258-278, 1943
  17. Blackwood W, Corsellis JAN. *Greenfield's Neuropathology*. 3rd ed. London, Arnold, 1976, 121-124
  18. Johnson RT, Yates PO: Brain stem haemorrhages in expanding supratentorial conditions. *Acta Radiol (Stockholm)* **46**: 250-256, 1956
  19. Klinthworth GK: Evaluation of the role of neurosurgical procedure in the pathogenesis of secondary brain stem haemorrhage. *J Neurol Neurosurg Psychiat* **29**: 423-425, 1966
  20. Shaw C-M, Alvard EC Jr, Berry RG: Swelling of the brain following ischemic infarction with arterial occlusion. *Arch Neurol* **1**: 161-177, 1959
  21. Berry RG, Alpers BJ: Occlusion of the carotid circulation: Pathologic considerations. *Neurology (NY)* **7**: 223-237, 1957
  22. Terent A et al.: Ischemic edema in stroke. *Stroke* **12**: 33-39, 1981
  23. Bounds JV et al: Mechanisms and timing of deaths from cerebral infarction. *Stroke* **12**: 474-477, 1981
  24. Finney LA, Walker AF: *Transtentorial herniation*. Springfield Ill., Charles C Thomas, 1962
  25. Sutherland S: The tentorial notch and complications produced by herniations of the brain through that aperture. *Brit J Surg* **45**: 422-438, 1958
  26. Moore M, Stern K: Vascular lesions in the brain stem and occipital lobe occurring in association with brain tumors. *Brain* **61**: 70-98, 1938

## Hypertensive Putaminal Hemorrhage Presenting as Pure Motor Hemiparesis

JORGE F. TAPIA, M.D., CARLOS S. KASE, M.D., RICHARD H. SAWYER, M.D.

AND J. P. MOHR, M.D.

**SUMMARY** A 44 year old hypertensive man presented with a pure motor hemiparesis, and CT scan showed a putaminal hemorrhage. The clinical course was characterized by rapid resolution of the deficits. This case illustrates a variety of putaminal hemorrhage of good functional and vital prognosis, and stresses the value of CT scanning as a tool for diagnosis and prognosis.

*Stroke*, Vol 14, No 4, 1983

HEMIPARESIS OR HEMIPLEGIA without sensory, visual or speech deficit (Pure motor hemiparesis, PMH) is the classical presentation for lacunar infarction in the internal capsule or basis pontis.<sup>1</sup> Other reported causes of this clinical syndrome include: infarcts or cortical,<sup>2</sup> pyramidal<sup>1, 3, 4</sup> or midbrain<sup>5</sup> location, metastases,<sup>2, 3</sup> multiple sclerosis,<sup>2</sup> nocardial abscess,<sup>6</sup> post-craniotomy hemorrhage,<sup>7</sup> and hemorrhages in the basis pontis<sup>8</sup> or internal capsule.<sup>2, 9, 10</sup> PMH has not been described in the setting of primary hypertensive putaminal hemorrhage.<sup>11, 12</sup> This report documents, by detailed neurological evaluation in the acute stage, an instance of a syndrome of PMH in putaminal hemorrhage.

### Case Report

A 44 year old left-handed hypertensive male noticed right arm weakness and slurred speech after awakening on 8/8/82. He had no headache, nausea, vomiting or gait difficulties. Over the following 2 to 3 hours the right arm paresis worsened and a mild weakness of the

right leg developed. When examined 4 hours after the onset, he was alert, oriented, and gave an accurate description of the events leading to admission. His speech was dysarthric but free of dysphasia. The blood pressure was 220/130. Motor examination showed a moderate paresis of shoulder abduction and elbow flexion, with minimal weakness of distal movements. The lower extremity had slight paresis of foot dorsiflexion, with intact proximal strength. The deep tendon reflexes were slightly hyperactive in the right arm, and plantar reflexes were flexor. Coordination was intact bilaterally.

Sensation was intact for touch and pin-prick in limbs, trunk and face. The slightest stimulation of individual hairs on the right limbs was felt normally and symmetrically. He did not extinguish to double simultaneous tactile stimulation. Joint position and vibratory sense were intact. Stereognosis, barognosis and graphesthesia were normal and symmetric.

Cranial nerve testing showed a marked right inferior facial palsy. Otherwise the examination showed full visual fields to single and double simultaneous stimuli, normal extraocular movements without gaze preference or nystagmus, reactive pupils of 2 mm diameter, intact facial sensation, preserved palate and tongue movements, and absence of bucco-lingual dyspraxia.

CT scan on admission showed a small area of high attenuation (96 Hounsfield units) at the level of the left

From the Department of Neurology, University of South Alabama College of Medicine, Mobile, Alabama.

Address correspondence to: Carlos S. Kase, M.D., Department of Neurology, University of South Alabama, 2451 Fillingim Street, Mobile, Alabama 36617.

Received September 21, 1982; revision accepted December 20, 1982.

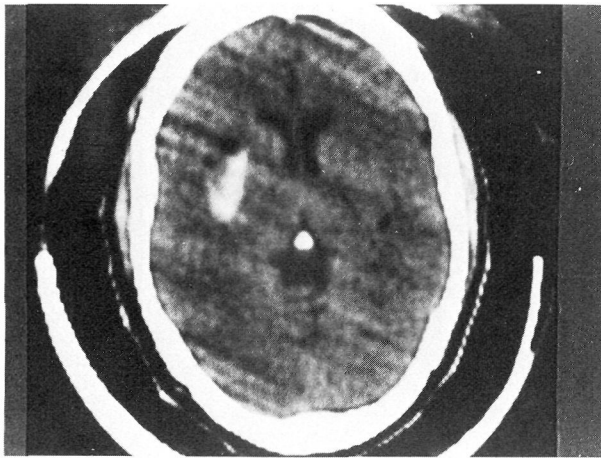


FIGURE 1. CT scan with hemorrhage at the level of the left putamen. Its posterior aspect is adjacent to the posterior limb of the internal capsule.

mid-posterior putamen, consistent with fresh hemorrhage (fig. 1). No blood was detected in cuts at the level of the body of the lateral ventricles. Coronal views performed 11 days after admission confirmed the lateral basal ganglionic location of the hematoma (fig. 2), which was impinging upon, but apparently not extending into, the posterior limb of the internal capsule. No ventricular extension of the hemorrhage or post-contrast enhancement were detected. The volume of this hematoma was estimated to be 8.5 cu mm.

The right hemiparesis progressively improved over the 24 to 48 hours following admission, and by day 4 the motor strength of the right limbs was within normal limits. The only residual deficit was a moderate right facial palsy, which persisted until discharge 15 days from the onset.

### Discussion

Hemorrhage into the internal capsule has accounted for PMH in 6 CT-documented cases.<sup>2, 9, 10</sup> These hemorrhages have been described as lenticulo-capsular,<sup>2</sup> thalamo-capsular,<sup>2, 9</sup> and as primary capsular hemorrhages.<sup>9, 10</sup> The clinical features of 5 of these cases were not provided in detail, as they were part of two large series of PMH cases.<sup>2, 9</sup> Our case represents a documented instance of PMH of an apparently pure putaminal hemorrhage, making exception to the notion that putaminal hemorrhages are always associated with a combination of motor and sensory defects.<sup>11, 12</sup> This observation suggests the clinical spectrum of putaminal hemorrhage needs to encompass cases of PMH, along with the classical forms producing combinations of motor, sensory, visual, oculomotor, language and behavioral deficits.<sup>11, 12</sup>

The rarity of our observation reflects the size and location of the hematoma: its size fell into the lowest portion of the spectrum of putaminal hemorrhage,<sup>12</sup> and, in particular, its lateral location along the mid- and posterior aspects of the putamen was responsible

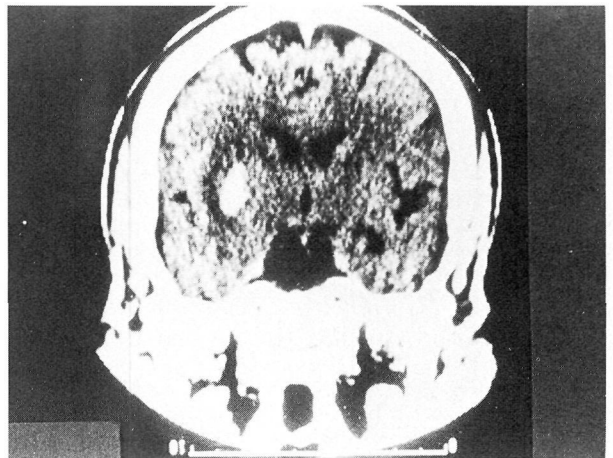


FIGURE 2. Coronal CT scan at a level corresponding to the mid-thalamus, showing the hemorrhage located laterally to the posterior limb of the internal capsule.

for pressure effects, rather than actual destruction, of the adjacent capsule. In addition, CT sections at a level corresponding to the body of the lateral ventricles showed no extension of the hematoma to that area. This CT scan sign has been correlated with good functional prognosis, as indicative of lack of extension of the bleed across the internal capsule.<sup>13</sup> These anatomical features explain the clinical presentation as PMH, as well as the unusual early regressive course of the deficit, which represents a distinctly uncommon observation in intracerebral hemorrhage in general.<sup>11</sup>

### References

1. Fisher CM, Curry HB: Pure motor hemiplegia of vascular origin. *Arch Neurol* **13**: 30-44, 1965
2. Weisberg LA: Computed tomography and pure motor hemiparesis. *Neurology (Ny)* **29**: 490-495, 1979
3. Chokroverty S, Rubino FA: 'Pure' motor hemiplegia. *J. Neurol Neurosurg Psychiatr* **38**: 896-899, 1975
4. Ropper AH, Fisher CM, Kleinman GM: Pyramidal infarction in the medulla: A cause of pure motor hemiplegia sparing the face. *Neurology (Ny)* **29**: 91-95, 1979
5. Ho KL: Pure motor hemiplegia due to infarction of the cerebral peduncle. *Arch Neurol* **39**: 524-526, 1982
6. Weintraub MI, Glaser GH: Nocardial brain abscess and pure motor hemiplegia. *NY State J Med* **70**: 2717-2721, 1970
7. Igashashi S, Mori K, Ishijimi Y: Pure motor hemiplegia after re-craniotomy for post-operative bleeding. *Arch Jap Chir* **41**: 32-37, 1972
8. Gobernado JM, Fernandez de Molina AR, Gimeno A: Pure motor hemiplegia due to hemorrhage in the lower pons. *Arch Neurol* **37**: 393, 1980
9. Rascol A, Clanet M, Manelfe C, Guiraud B, Bonafe A: Pure motor hemiplegia: CT study of 30 cases. *Stroke* **13**: 11-17, 1982
10. Obeso JA, Marti-Masso JF, Carrera N, Astudillo W: Pure motor quadriplegia secondary to bilateral capsular hematomas. *Arch Neurol* **37**: 248, 1980
11. Fisher CM: Clinical syndromes in cerebral hemorrhage. *In* Fields WS (ed): Pathogenesis and treatment of cerebrovascular disease. Springfield, IL, Charles C Thomas, 1961, pp 318-342
12. Hier DB, Davis KR, Richardson EP, Mohr JP: Hypertensive putaminal hemorrhage. *Ann Neurol* **1**: 152-159, 1977
13. Mizukami M, Nishijima M, Kin H: Computed tomographic findings of good prognosis for hemiplegia in hypertensive putaminal hemorrhage. *Stroke* **12**: 648-652, 1981

## Hypertensive putaminal hemorrhage presenting as pure motor hemiparesis.

J F Tapia, C S Kase, R H Sawyer and J P Mohr

*Stroke*. 1983;14:505-506

doi: 10.1161/01.STR.14.4.505

*Stroke* is published by the American Heart Association, 7272 Greenville Avenue, Dallas, TX 75231

Copyright © 1983 American Heart Association, Inc. All rights reserved.

Print ISSN: 0039-2499. Online ISSN: 1524-4628

The online version of this article, along with updated information and services, is located on the World Wide Web at:

<http://stroke.ahajournals.org/content/14/4/505>

**Permissions:** Requests for permissions to reproduce figures, tables, or portions of articles originally published in *Stroke* can be obtained via RightsLink, a service of the Copyright Clearance Center, not the Editorial Office. Once the online version of the published article for which permission is being requested is located, click Request Permissions in the middle column of the Web page under Services. Further information about this process is available in the [Permissions and Rights Question and Answer](#) document.

**Reprints:** Information about reprints can be found online at:  
<http://www.lww.com/reprints>

**Subscriptions:** Information about subscribing to *Stroke* is online at:  
<http://stroke.ahajournals.org/subscriptions/>