

Short Communication

A Cerebrovascular Accident with Unusual Features

J.C. GAUTIER, A. AWADA, AND PH. LORON

SUMMARY A 64 y/o man experienced during 2 weeks TIA's or TIA's like episodes, once or twice a day, with or without contralateral pain in the head. CT Scans showed peculiar enhanced areas appended to the superior sagittal sinus. Angiography was refused. Twenty-seven months later during mild exertion a left frontal hematoma developed. Among frontal symptoms and signs laconism, abulia and a striking whispering were prominent. Angiography showed a dural arteriovenous fistula draining into cortical veins on the inner aspect of the left hemisphere. The fistula was successfully operated.

Stroke, Vol 14, No 5, 1983

UNUSUAL NEUROLOGICAL DISORDERS of an unusual cause with an unusual CT Scan picture are the main characteristics of the following case.

Case Report

A 64 year old right-handed manager was admitted on January 1st 1982 for 'right hemiplegia and aphasia'. On the eve of the New Year he was uncorking a bottle in the kitchen when his wife heard a thud. He was found on the ground, conscious, unable to move his right side and to speak. There was no evidence of headache and he did not vomit.

Two years previously, on August 17, 1979 while bending below the dashboard of his car he had felt a sharp non throbbing pain in the left parietal region. This lasted 2 minutes. Simultaneously he had experienced difficulty in moving his right lower limb for 10 minutes. Medical examination half an hour later was reported normal. From August 19 to September 2, once or twice a day, he had a transient motor deficit of his right lower limb for 5 to 10 minutes, with or without concomitant left parietal headache. No particular activity or exertion were noted at the onset of these episodes. On September 1, 1979 he felt pin and needles in his left thigh for 10 minutes. One of us (J.C.G) saw him on September 4, 1979. Neurological examination was considered normal. No bruit was heard in the neck or over the skull. Blood pressure was 150/90 and heart clinically normal. Optic disks were normal. Previous history disclosed poor sight of the left eye due to hemorrhages and glaucoma. The sight of the right eye was somewhat impaired by hemorrhages despite photocoagulation in 1970 and Laser in 1978. Ultrasonic examination of neck arteries was normal. A CT Scan with contrast injection on October 3, 1979 showed no cerebral area of abnormal density, and no displacement of cerebral structures. Some small high density areas were present along the superior sagittal sinus (fig. 1). Cerebral angiography was refused.

From September 1979 to December 31, 1981 he

remained asymptomatic. A repeat CT Scan on April 16, 1980 showed images similar to the first ones.

On admission (January 1, 1982), the patient was alert with a slight paresis of the right lower limb and a total absence of speech. The plantar reflex was equivocal on the right, flexor on the left side. When left to himself the patient lay immobile quietly in his bed but upon requests he could quite freely move his right limbs. No gross disorders of sensation and visual field were present. A right grasping reflex was present. There was bladder and rectal incontinence with handling of stools. No bruit was heard on neck arteries and skull. Auscultation of the heart was normal. Blood pressure was: 140/80 mmHg.

On January 3-4, 1982, he still lay immobile in his bed but when asked he could sit, stand up and walk around his bed. Speech reappeared upon strong inciting. There was no aphasia and no dysarthria. Comprehension of spoken speech appeared normal. There was no ideomotor apraxia. However, sentences were very short with perseverations and utterances were strikingly whispered either spontaneously or despite requests to speak in a loud voice.

In a few days the grasping reflex subsided. A CT scan showed a left frontal hematoma (fig. 2). The hematoma was above the frontal horn and anterior part of the lateral ventricle. It was subcortical mainly internal and reached the cortex on the internal aspect of the frontal lobe resulting in a slight shift of the midline. There was no evidence of subarachnoid hemorrhage. On January 15 the patient walked spontaneously. Whispering and abulia, bladder and rectal incontinence, handling of stools were still present. Left and right carotid angiography on January 13 showed an arterio-venous fistula on the left side of the superior sagittal sinus. Blood came from the left middle meningeal and occipital arteries and from the right middle meningeal artery and was drained to veins into the internal aspect of the left hemisphere (fig. 3a, b).

During the following month there was gradual improvement. Whispering was followed by a weak voice with some instances of echolalia. By mid-February the voice was normal. Bladder and rectal incontinence became less and less frequent. On March 3 a CT Scan showed no high density area but a large low density

From Service d'Urgences Cerebrovasculaires, Hopital de la Salpetriere, 47, Bd de l'Hopital, 75013, Paris, France.

Address correspondence to: Professor J. C. Gautier, Service d'Urgences Cerebrovasculaires, Hopital de la Salpetriere, 47 Bd de l'Hopital, 75013, Paris, France.

Received February 11, 1983; accepted March 16, 1983.

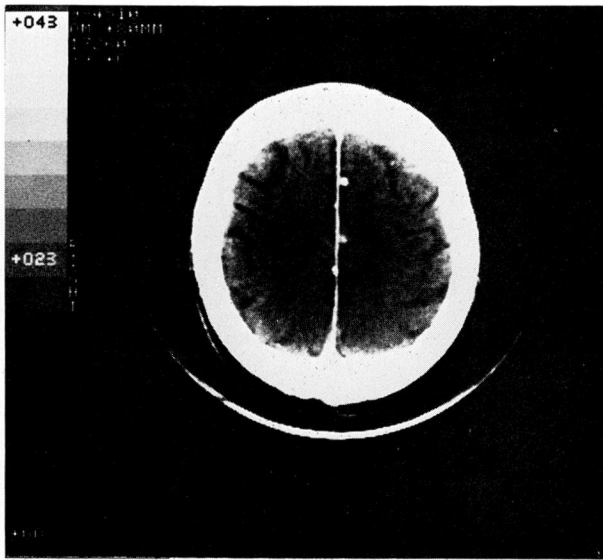


FIGURE 1. CT Scan with contrast. High density areas appended to the superior sagittal sinus.

area persisted in the left frontal lobe. On March 18 the malformation was operated (Pr Pertuiset). The abnormal veins were outside the brain and were excised. Post-operative angiography showed no abnormal vessels. The evolution was simple and the patient was discharged home.

He was seen again as an outpatient on June 6, 1982. Voice and speech were normal: bladder and rectal control were normal. The patient thought that his intellect was normal. He had not resumed his professional activities.

Comments

Several classifications of dural arterio-venous fistulae (AVF) have been proposed.¹⁻³ The more recent one⁴ distinguishing among pure meningeal AVF those draining: 1) into a sinus or meningeal vein; 2) into a sinus with a significant reflux into veins that arrive at the sinus; 3) into cortical veins; 4) into large dural or subdural lakes, acting like space occupying lesions. Our case belongs to (3) a condition which is obviously liable to result in cerebral and/or subarachnoid hemorrhage.

Two years and 3 months prior to the cerebral hemorrhage there were during two weeks, once or twice a day, transient episodes of paresis of the right lower limb. Once the transient episode was of a sensory nature. There were never jerks. The first episode occurred while the patient was bent forward below the dashboard of his car but no particular exertion or posture was noticeable at the beginning of the numerous other episodes. Some of the latter were accompanied by a sharp non throbbing pain in the left parietal region but many were not. What were these episodes? Obviously their brief duration rules out hemorrhage. There were no jerks prior to the motor deficit and no march of pin and needles so epilepsy is unlikely. Were they transient ischemic episodes? Pain concomitant to TIA's is rare indeed but the pathological condition of

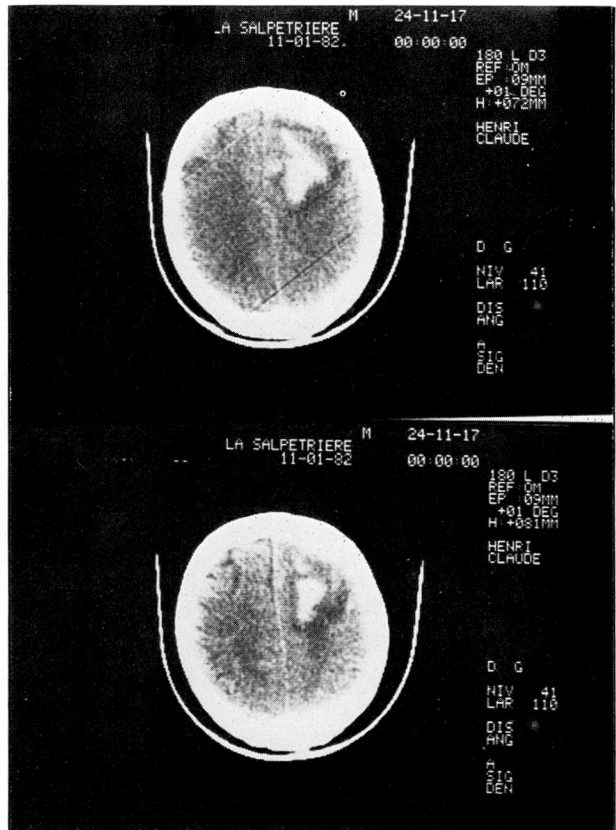
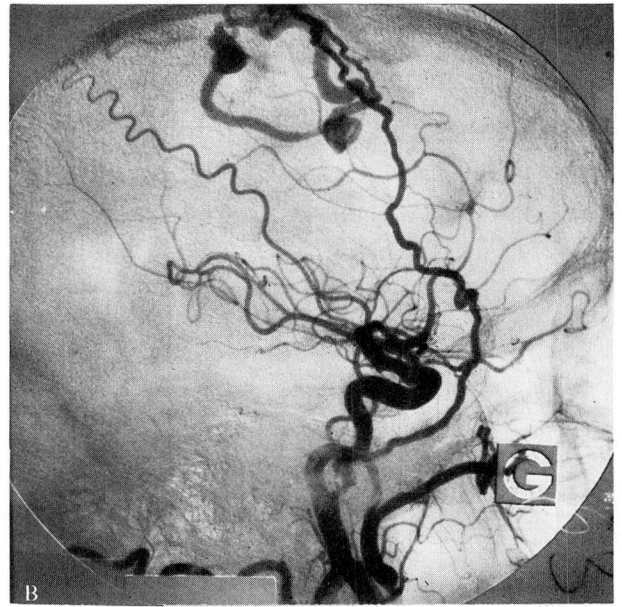
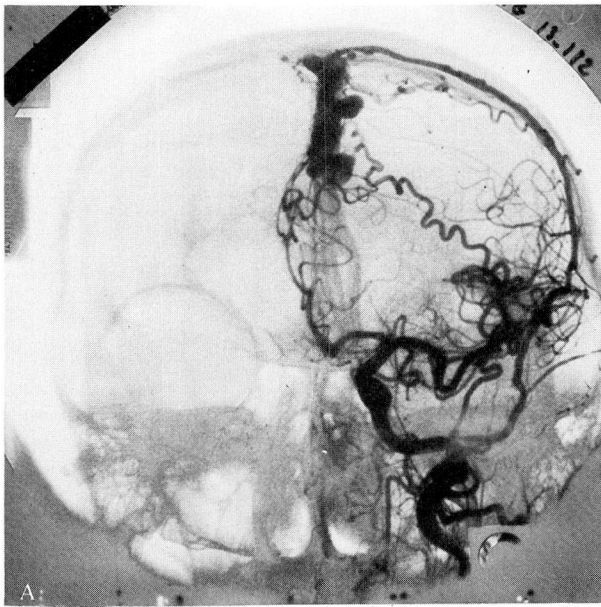


FIGURE 2. CT scan without contrast. Left frontal hematoma.

this patient, i.e. dural AVF draining into cortical veins is rare as well. It might be that we are here dealing with a particular kind of TIA in which pain in the head would be a particular feature.

Between September 1, 1979 and December 31, 1981 there were no symptoms. During this period 2 CT Scans with contrast showed an unusual picture of the superior sagittal sinus (fig. 1) to which several hyperdense nodes were appended. This picture didn't lead to diagnosis and among (false) hypotheses a rare kind of meningiomatosis was mentioned by a neurosurgeon to whom the case was submitted. CT Scan appearances of dural AVF are not well known and this particular picture appears not to be included in a recent paper.⁵ Can this picture be explained *a posteriori*? It is likely to be due to reflux of contrast medium into veins adjacent to the superior sagittal sinus meaning high pressure in the sinus and this of course is suggestive of an AVF. Anyway the CT Scan is so particular as to be easily reminded with its particular cause in this particular patient.

The left frontal hematoma resulted in a rather typical syndrome of the frontal lobe: contralateral grasping reflex, disorders of sphincter control, laconic responses, abulia. The latter has been recently briefly commented.⁶ A striking feature of speech was whispering. Although the latter is listed in classical Textbooks in the anterior cerebral artery syndrome⁷ its physiopathology is not easily understood. In our patient (and maybe generally) it might represent a period



FIGURES 3A AND B. Left carotid angiography (a) front (b) lateral views. Dural fistula. The left superficial meningeal artery feeds enlarged cortical veins. Right carotid angiography showed in addition that the right superficial meningeal artery also supplied the abnormal cortical veins.

between mutism and normal speech or voice. It may be for voice what akinesia and hypokinesia are for movements. Is it present in right frontal lobe lesions as well as in left ones? If yes, are there some dissimilarities? Additional cases deserve to be reported with more detailed studies.

References

1. Aminoff MJ: Vascular anomalies in the intracranial dura mater. *Brain* **96**: 601-612, 1974
2. Houser OW, Baker HL, Rhoton AL, Okazaki H: Intracranial dural arterio-venous malformations. *Radiology* **105**: 55-64, 1972
3. Castaigne P, Bories J, Brunet P, Merland JJ, Meininger V: Les fistules artério-veineuses méningées pures à drainage veineux cortical. *Rev Neurol (Paris)* **132**: 169-181, 1976
4. Djindjian R, Merland JJ: *In* Superselective arteriography of the External Carotid Artery. Springer Verlag, 1978
5. Chiras J, Bories J, Léger JM, Gaston A, Launay M: CT Scan of Dural Arteriovenous Fistulas. *Neuroradiol* **23**: 185-194, 1982
6. Mohr JP: The Evaluation of Aphasia. *Stroke* **13**: 399-401, 1982
7. Mohr JP, Miller Fisher C, Adams RD: *Cerebrovascular Diseases in Harrison's Principles of Internal Medicine*, 8th Edition. McGraw-Hill Book Co, New York, 1977