

MENKES' DISEASE AND SWAYBACK

A Comparative Study of Two Copper Deficiency Syndromes

NOEL TAN and HENRY URICH

Department of Neuropathology, Royal Perth Hospital, Perth, Western Australia (Australia)

(Received 9 June, 1983)

(Accepted 20 July, 1983)

SUMMARY

The neuropathological findings in two siblings with Menkes' disease were compared with representative material obtained from lambs suffering from swayback (enzootic ataxia). The aim of the study was to demonstrate the similarity of lesions in a genetic and a nutritional form of copper deficiency in support of the view that all lesions in Menkes' disease could be ascribed to simple hypocupraemia. All lesions of Menkes' disease were shown to have their counterpart in swayback, with exception of the abnormal arborisations of the Purkinje cell dendrites. These have often been interpreted as malformations and cited in evidence of the prenatal origin of the cerebral lesions. They are, however, non-specific and similar lesions have been reported in conditions arising in later life. While there is abundant collateral evidence of disturbed copper metabolism in utero, the problem of the prenatal versus postnatal origin of cerebral damage remains unresolved.

Key words: *Copper deficiency – Enzootic ataxia – Hypocupraemia – Menkes' disease – Swayback*

INTRODUCTION

Menkes' disease (Menkes et al. 1962) is a well established genetic entity, inherited as a sex-linked recessive, and affecting the central nervous system, skin, hair, blood vessels and bones. The underlying metabolic defect is copper deficiency

Correspondence to: Dr. N. Tan, Department of Neuropathology, Royal Perth Hospital, Box X2213 G.P.O., Perth, W.A. 6001, Australia

caused primarily by malabsorption from the gut (Danks et al. 1972). Despite extensive experimental studies many problems of pathogenesis, particularly of lesions in the CNS, remain unsolved. The closest animal model is a mouse mutant, the mottled brindled (Mo^{br}) mouse and this has been studied both from a morphological (Nagara et al. 1980; Suzuki and Nagara 1981) and biochemical point of view (Camakaris et al. 1979; Mann et al. 1979a,b). Genetic conditions, however, pose the question whether all lesions can be ascribed to the underlying metabolic disorder or may be independent expressions of the abnormal genome. It is therefore of interest to compare Menkes' disease with a nutritional copper deficiency such as swayback, or enzootic ataxia, of lambs. Danks (1980) presented a brief survey of lesions caused by copper deficiency of different aetiology in a wide range of species and Smith (1981) reviewed the literature on Menkes' disease, swayback and the mottled brindled mouse, emphasizing the similarity of findings. What is lacking is a comparative study of the neuropathology of Menkes' disease and swayback, based on personal observations on material from both conditions.

MATERIALS AND METHODS

Material for the study of Menkes' disease consisted of two siblings, the elder of which was already briefly reported by Hockey and Masters (1977). Their findings, with some additional observations, will be briefly recapitulated and compared with those in the younger sibling. The material was studied in paraffin sections, stained with standard neuropathological methods. In addition, Cajal's silver impregnations were carried out on frozen sections of the cerebellum.

Material from swayback was put at our disposal by the Department of Veterinary Medicine, University of Cambridge, the Central Veterinary Laboratory of the Ministry of Agriculture, Weybridge, and the Department of Veterinary Pathology, Murdoch University, Western Australia. It consisted of cases both of congenital and delayed swayback (classification after Howell et al. 1982). In the former group both cases with and without cerebral involvement were included. Most of the material consisted of paraffin sections stained with haematoxylin and eosin. No material was available for silver impregnations.

OBSERVATIONS

Menkes' disease

Case 1 (X74-338)

Clinical history: M.B., a male and first child of Maltese and Australian parents was born after a 33 weeks' gestation. The prenatal and perinatal periods were uneventful. At 2 months he appeared floppy and developed generalised seizures. The scalp hair was lustreless, depigmented and showed pili torti and trichorrhexis nodosa. His further physical and mental development was retarded, punctuated by feeding problems and episodes of hypothermia. His reflexes were brisk with ankle clonus. Serum copper was $6.2 \mu\text{mol/l}$ (normal 11–25) and copper oxidase 0.06 g/l (normal 0.21–0.43). A diagnosis of Menkes' disease was made. During the following year he became progressively retarded in physical growth and mental development, had constant myoclonus and respiratory problems until his death at 2 years.

Post mortem examination: confirmed bronchopneumonia. The long bones showed thickening of the periosteum with numerous erosions of the cortical bone and osteoclastic activity. Microscopy of representative systemic and cerebral arteries disclosed no significant changes.

Neuropathology: The brain weighed 521 g (normal for age 1100 g) and showed severe generalised atrophy with ventricular dilatation and areas of cortical softening in the frontal, temporal and parietal lobes. The cerebellar folia, particularly those of the vermis, were severely atrophic.

Microscopy: There was diffuse, but not uniform, atrophy of the cerebral cortex. Neuronal loss was severe in places, with almost total loss of small neurons in layer IV, and patchy status spongiosus in layer V. The white matter was poorly myelinated and contained reactive astrocytes. Mild neuronal loss was also present in the basal ganglia and thalamus.

In the brain stem the most striking lesion was the presence of chromatolytic neurons in the reticular formation (Figs. 1A and B). These were large, up to about 35 μ m in diameter, with homogeneous acidophilic cytoplasm and small fragments of Nissl bodies in the periphery. Their nuclei were enlarged and distorted, with ill defined nuclear membrane and a large, eosinophilic nucleolus. Some were represented by ghost cells which had lost all their cytoplasmic and nuclear structures.

The cerebellar cortex showed severe loss of granule cells and moderate loss of Purkinje cells with corresponding Bergmann gliosis. In silver impregnations the remaining Purkinje cells showed abnormal dendritic ramifications in the form of antler-like expansions (Fig. 2A). Polydentritic neurons

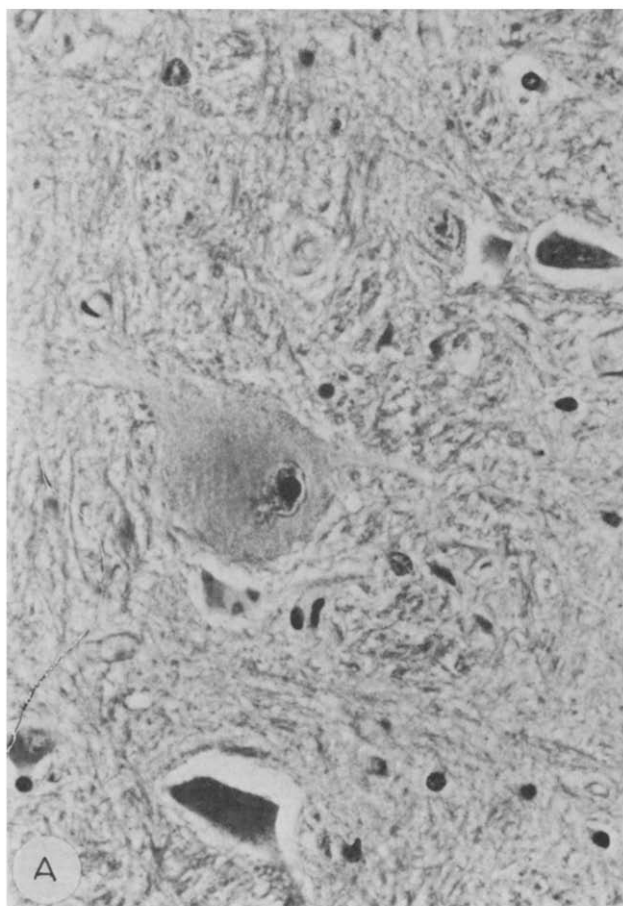


Fig. 1. Menkes' disease (Case 1) (A and B, see p. 98). Two chromatolytic cells from reticular substance in medulla. H&E. $\times 450$.

were also present and formed to patterns: numerous fine processes radiating from the cell body (Fig. 2B) or several coarse, branching dendrites (Fig. 2C). Occasional axonal swellings ("torpedoes") were also seen. Basket fibres were absent. Mild gliosis of the dentate nucleus was apparent.

In the spinal cord the most striking lesion was neuronal loss and gliosis of Clarke's column. Occasional chromatolytic cells were seen in Clarke's column and the large celled nucleus of the posterior horn. Degeneration of the dorsal spinocerebellar and corticospinal tracts was present throughout the cord.

Case 2 (X79-162)

Clinical history: S.B., the brother of the first patient, was delivered by caesarian section at 34 weeks of gestation because of placenta praevia. He had feeding problems, hypotonia and episodes of hypothermia almost since birth. His hair was sparse and stubby with pili torti. Serum copper was $2 \mu\text{mol/l}$ and the caeruloplasmin concentration 0.02 optical density units. The child did not thrive and succumbed to suppurative pneumonia at the age of $5\frac{1}{2}$ months.

Post mortem examination: confirmed the presence of suppurative bronchitis and pneumonia. Otherwise lesions were confined to blood vessels. Sections of the aorta, common carotid, coronary and iliac arteries showed duplication and fraying of the internal elastic laminae, intimal fibrosis and stenosis of the lumen. The cerebral arteries were free from these changes.

Neuropathology: The brain weighed 719 g and was swollen and congested. Coronal sections of the fixed brain showed focal necrosis of the cerebral cortex and softening of the subcortical and

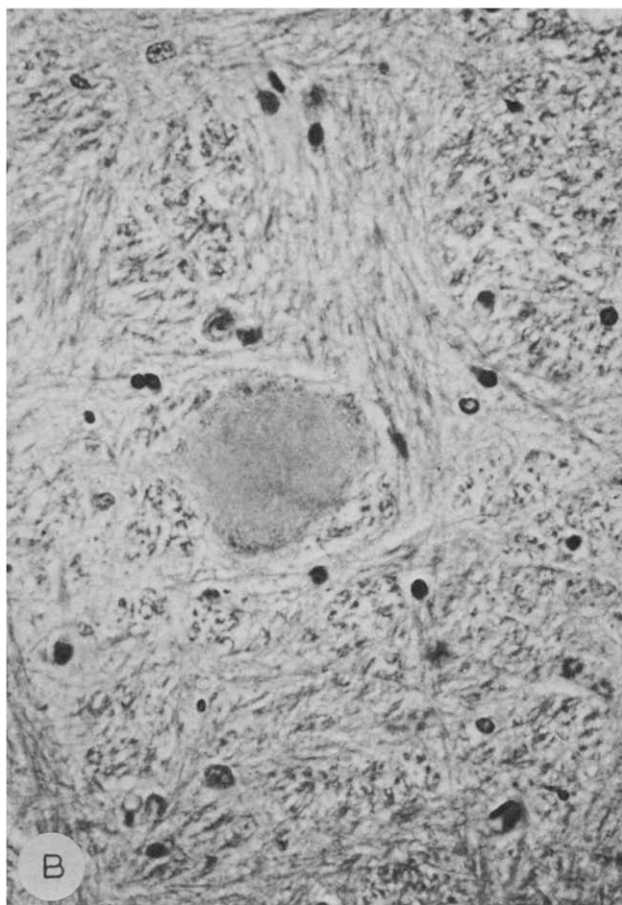


Fig. 1B.

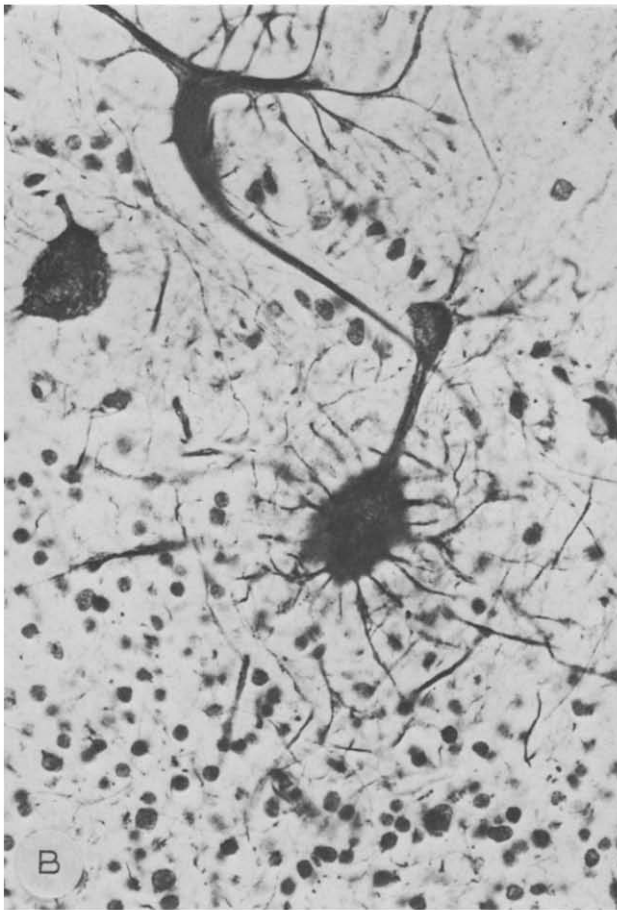
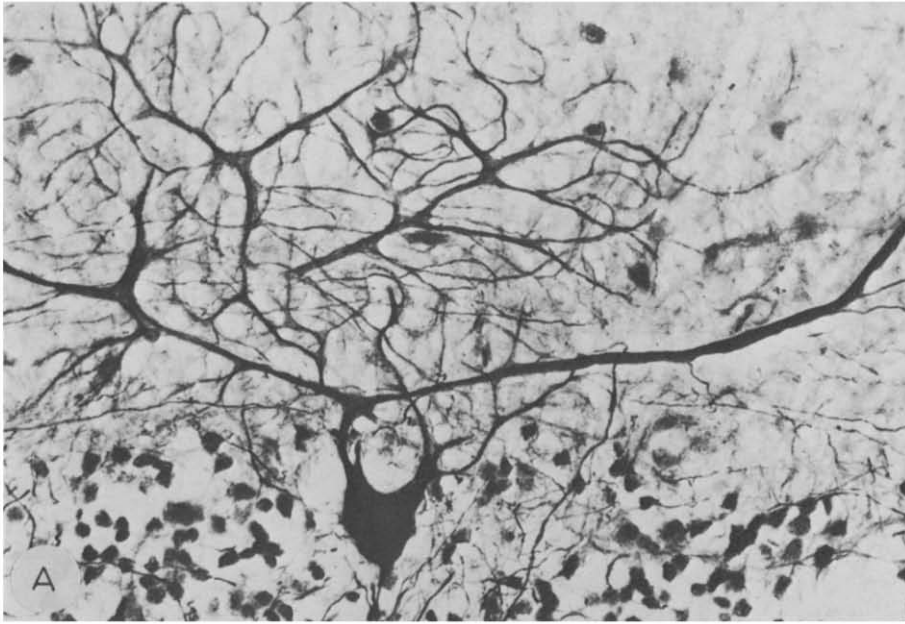


Fig. 2. Menkes' disease (Case 1). Abnormalities of Purkinje cell dendrites. *A*: "Antler" or "staghorn" deformity; *B*: Polydendritic cell with numerous fine perisomatic processes; *C*: Polydendritic cell with several coarse branching dendrites. Cajal's silver impregnation, $\times 450$.

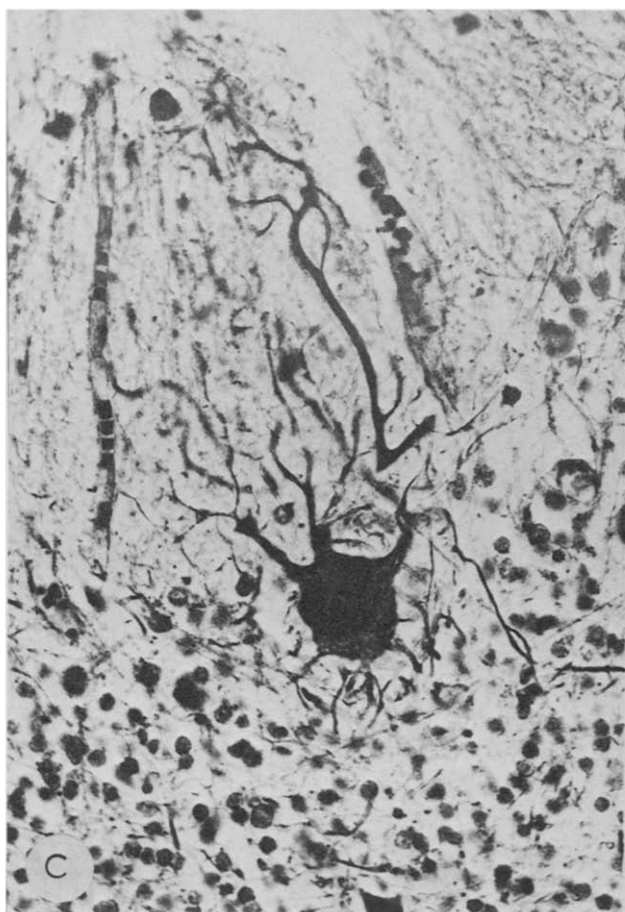


Fig. 2C.

central white matter, most pronounced in the lateral and inferior parts of the frontal, temporal and parietal lobes. The basal ganglia and thalamus were preserved and the ventricles reduced in size. The cerebellum showed generalised atrophy, the brainstem and spinal cord appeared normal.

Microscopy: The cortex showed extensive laminar necrosis involving predominantly layers III and V. Large areas of white matter were devoid of myelinated fibres and replaced by a meshwork of astroglia, containing scattered small cavities with sharply demarcated edges and devoid of lipid macrophages (Fig. 3). The white matter of the severely damaged insula and the adjacent basal ganglia contained several dilated tortuous veins.

Chromatolytic neurons were less conspicuous than in Case 1, but some were present in the reticular substance of the medulla.

In the cerebellar cortex abnormalities were seen in all layers (Fig. 4). The internal granular was severely depleted. Purkinje cells were abundant, but many of them were necrotic, and some showed coarse vacuolation of their cytoplasm. The external granular layer was present at a thickness appropriate for the age, but showed peculiar rosette-like clusters irregularly dispersed in the molecular layer. Silver impregnations showed abnormal arborisations of the Purkinje cell dendrites, some of which divided high in the molecular layer with secondary and tertiary branches directed towards the deeper layers of the cortex (the "weeping willow" pattern) (Fig. 5). A few cells showed short and stubby perisomatic dendrites.

The spinal cord showed minimal changes. There was no appreciable loss of neurons in Clarke's column, but some reactive astrocytes were present. Some degenerating neurons were seen in various

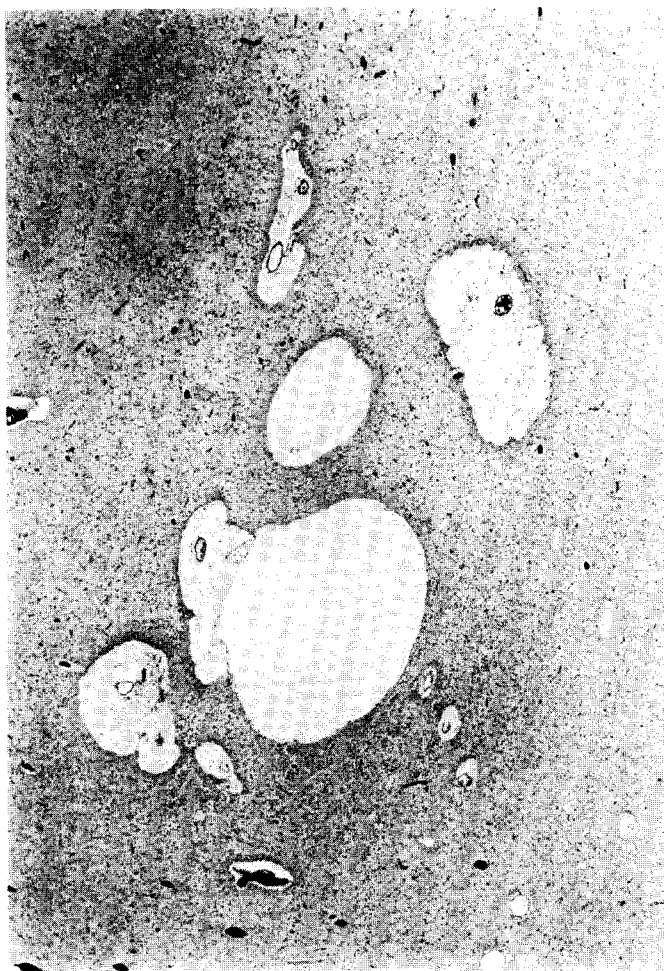


Fig. 3. Menkes' disease (Case 2). Cavitation of white matter. Luxol-fast blue and neutral red. $\times 25$.

parts of the cord, but none showed the typical chromatolytic pattern. A few vacuolated neurons were seen in the intermedio-lateral group in the thoracic cord. No definite abnormality was seen in the long tracts.

Swayback

In cases of congenital swayback with cerebral involvement both the cerebral cortex and the white matter were involved. In the oedematous variant, laminar or patchy neuronal necrosis was present in the cortex with rarefaction and vacuolation of the neuropil. The white matter showed extensive loss of myelinated fibres with replacement by a loose glial meshwork of reactive astrocytes and their processes. These lesions could be unilateral or bilateral. In the more common type cavitation of the white matter was the most prominent feature. The cavities had sharply demarcated edges with a thin glial wall, and showed very little, if any, evidence of microglial activity or phagocytosis. In some cases there was laminar loss of neurons in the cortex with status spongiosus and scattered ferruginated cells. In one case focal aggregations of lipid macrophages were prominent in the cortex.

In the brainstem the main feature was the presence of large chromatolytic neurons, mainly in the red nucleus, the vestibular nuclei and the reticular substance. These changes were not accompanied by obvious tract degenerations.

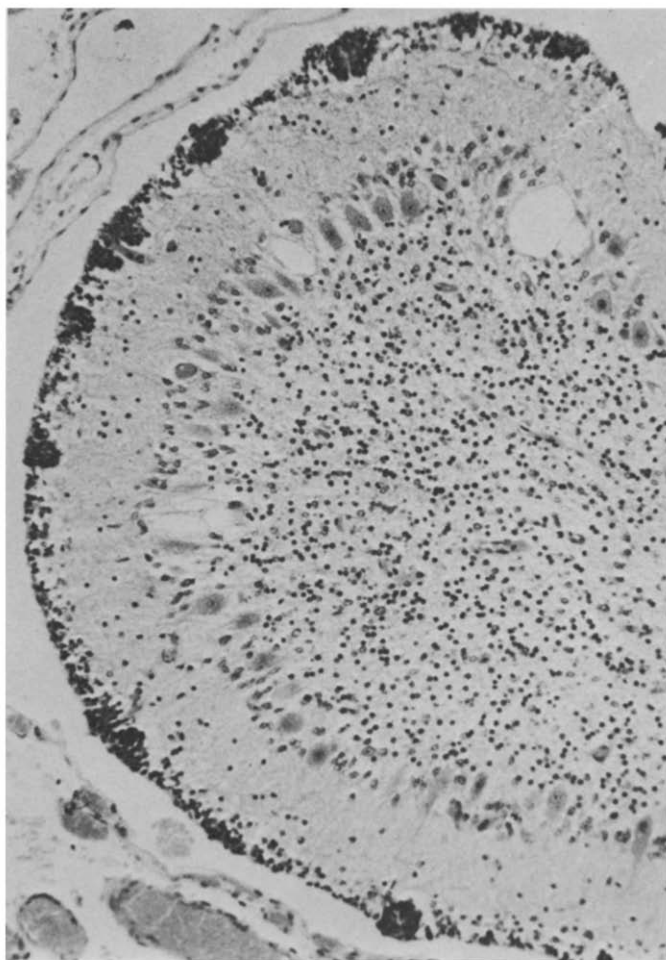


Fig. 4. Menkes' disease (Case 2). Cerebellar cortex showing clusters of cells in external granular layer, depletion of internal granular layer and vacuolation of Purkinje cells. H&E. $\times 250$.

The cerebellum was affected in only a few cases, either in a patchy or a diffuse fashion. The characteristic lesion consisted of widening of the normally thin external granular layer and corresponding thinning and rarefaction of the internal granular layer (Figs. 6A, B). Some of the cells of the external layer showed degenerative changes and in some places that layer had disappeared completely (Figs. 7A, B). The Purkinje cells were generally well preserved, but some loss, necrosis or coarse vacuolation were found in places. Malorientation and displacement of Purkinje cells into the molecular layer were fairly common.

The spinal cord was affected in all cases, both congenital and delayed. The constant features were degeneration of the white matter and chromatolysis of neurons in the grey matter. The tract degeneration involved both axons and myelin sheaths and was confined to the ventrolateral columns with preservation of the dorsal columns. Chromatolytic neurons were conspicuous in the ventral horns (Fig. 8) with a less prominent involvement of Clarke's column.

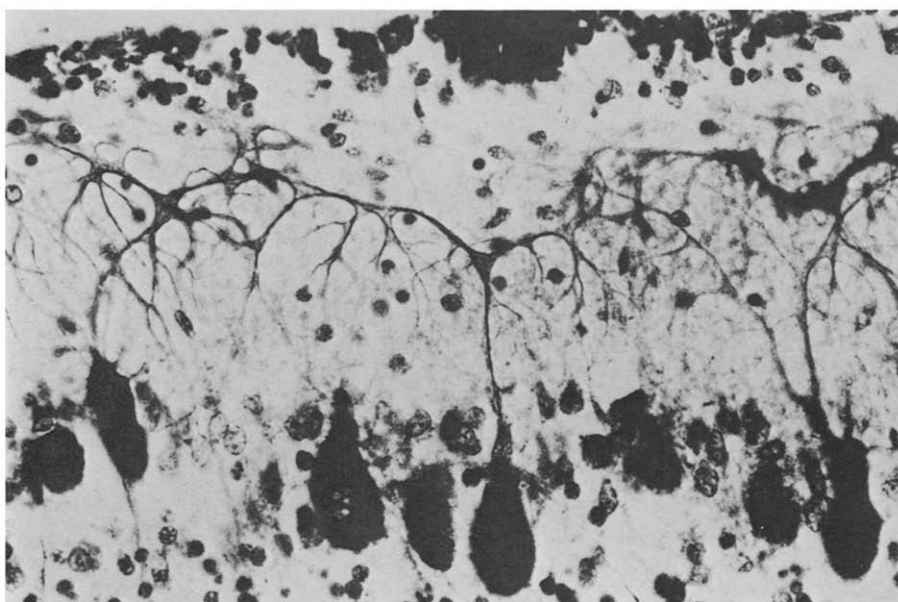


Fig. 5. Menkes' disease (Case 2). "Weeping willow" pattern of Purkinje cell dendrite. Glees and Marsland's silver impregnation, $\times 450$.

DISCUSSION

The paucity of comparative studies of Menkes' disease and swayback may perhaps be due to a difference in emphasis on the localisation of the lesions in the two conditions. Swayback has been presented as a disease affecting primarily the white matter: a demyelinating condition resembling Schilder's disease (Innes 1939; Innes and Shearer 1940), or different from any human disease (Spais et al. 1961) or due to myelin aplasia rather than demyelination (Howell et al. 1964; Howell 1968). In Menkes' disease the emphasis has been on grey matter lesions ("trichopolydystrophy", French et al. 1972). It has, however, become increasingly apparent that lesions are widespread in both diseases. Neuronal lesions are important in swayback (Barlow et al. 1960; Barlow 1963), while degeneration of the white matter may be sufficiently prominent in Menkes' disease to mimic leucodystrophy (Vagn-Hansen et al. 1973). There is considerable variation in incidence and severity of the various lesions between the two species and between individuals in each species.

One may also question the validity of a comparison of a prenatal copper deficiency in swayback and a predominantly postnatal malabsorption syndrome in Menkes' disease. However, the brain of newborn ruminants is far more mature than that of a human neonate. Myelination of the cerebral hemispheres is well advanced in the lamb and the migration of cerebellar neurons is almost complete. The last 6 of the 21 weeks of gestation in sheep are comparable with the postnatal

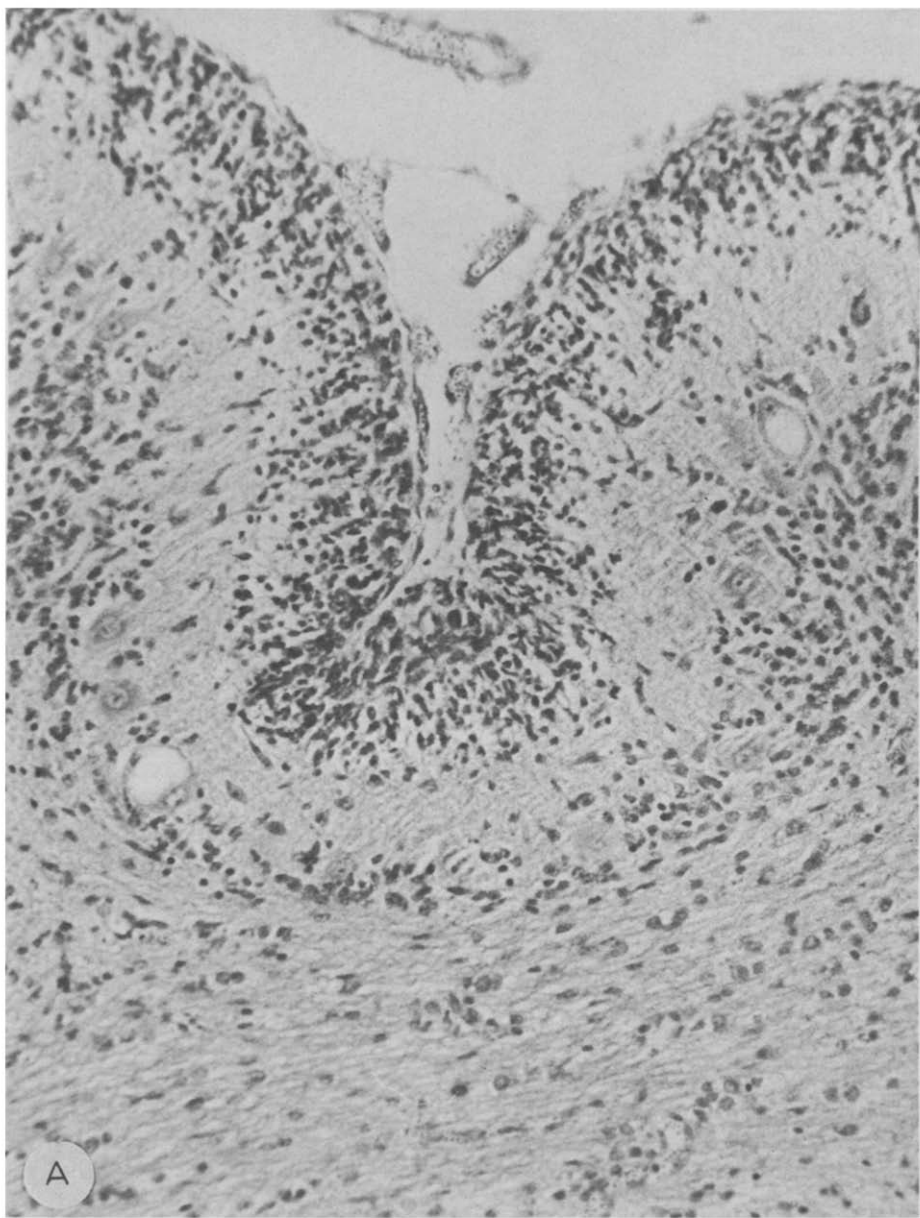
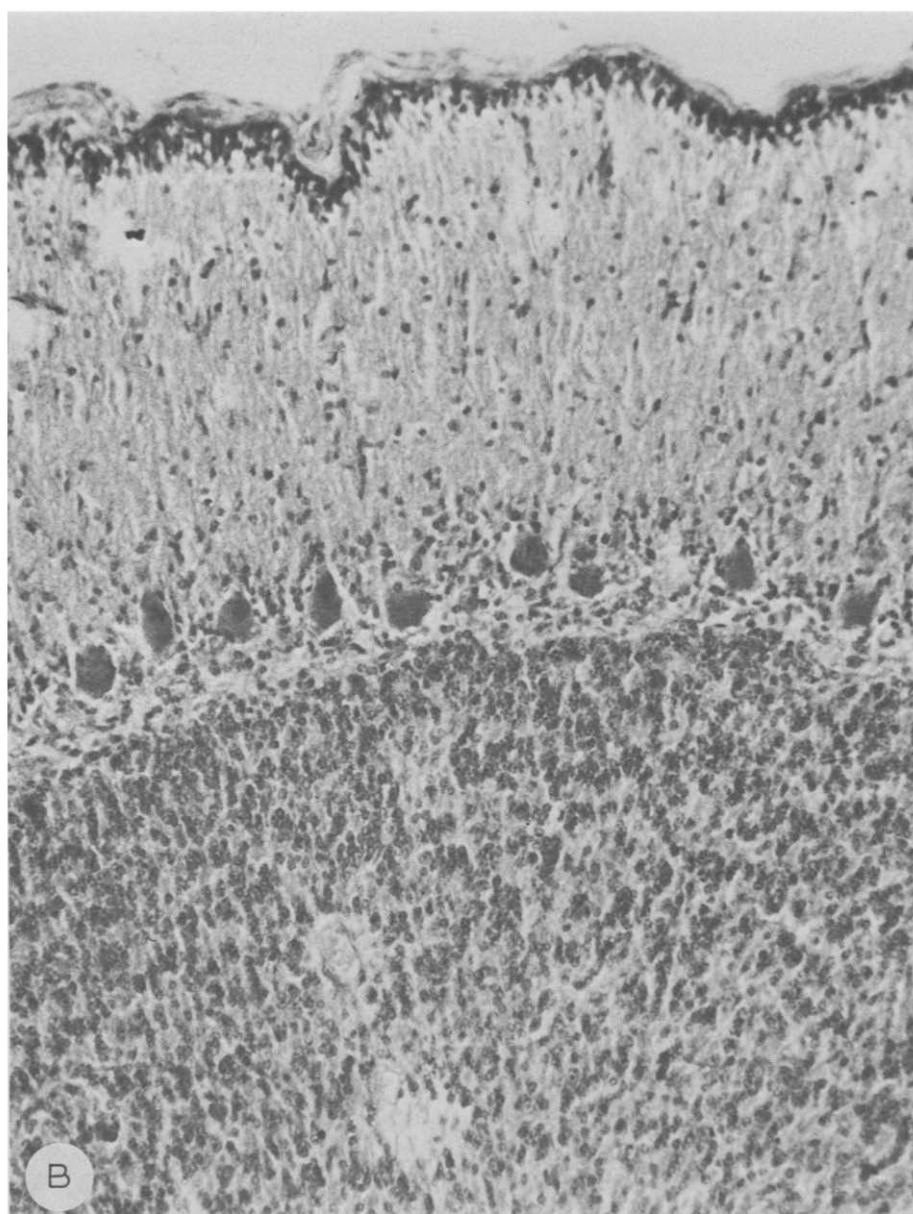


Fig. 6. Swayback. Cerebellar cortex showing (A) widening of external and thinning of internal granular layer and vacuolation of Purkinje cells, and (B) normal appearances in adjacent lobule. H&E, $\times 250$.



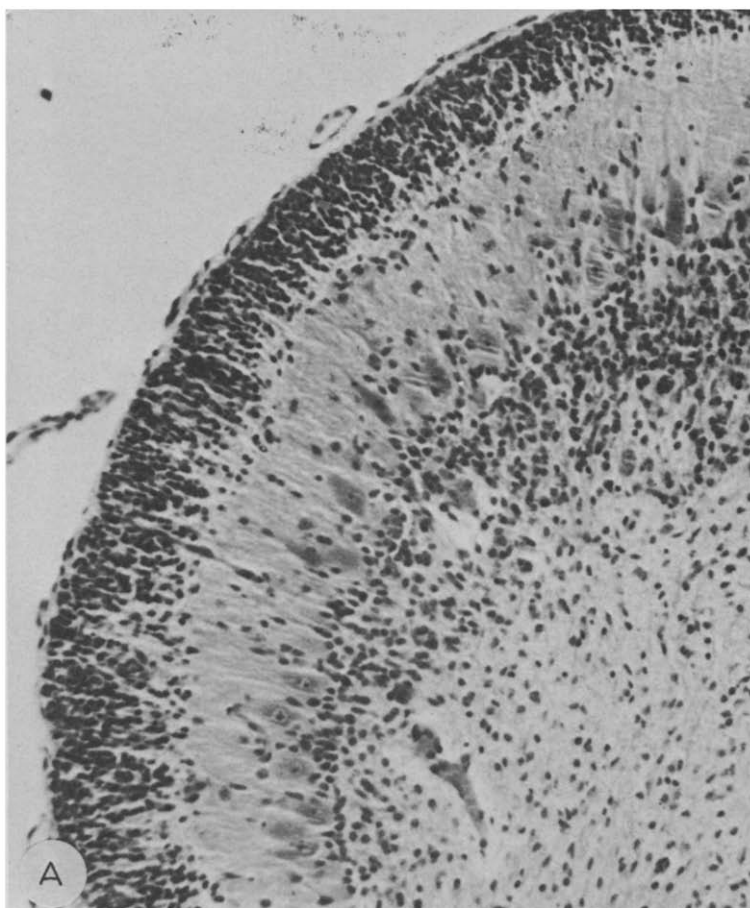


Fig. 7. Swayback. Two adjacent areas of the same cerebellar folium. *A*: Showing broad external granular layer, and (*B*) almost total destruction of this layer. H&E, $\times 240$.

development in infants, and it is during that period that the lesions of swayback develop and can be prevented by administration of copper supplements to the pregnant ewes (Dunlop et al. 1939). The earliest lesions in the spinal cord were recorded on the 99th day of gestation (Smith et al. 1977).

Furthermore, Menkes' disease may not be an exclusively postnatal process. While malabsorption of copper from the gut is undoubtedly the main defect, other mechanisms may also be significant, such as reduced levels of copper in the heterozygous mother, impaired transport of copper through the placenta, or a defect in intracellular transport of this element. Demonstration of excessive incorporation of ^{64}Cu into amniotic cells has confirmed the disturbance of fetal copper metabolism (Horn 1976). Yet its significance in the pathogenesis of the disease remains unclear and may have been overstated in an attempt to explain certain apparent prenatal malformations, particularly in the cerebellum.

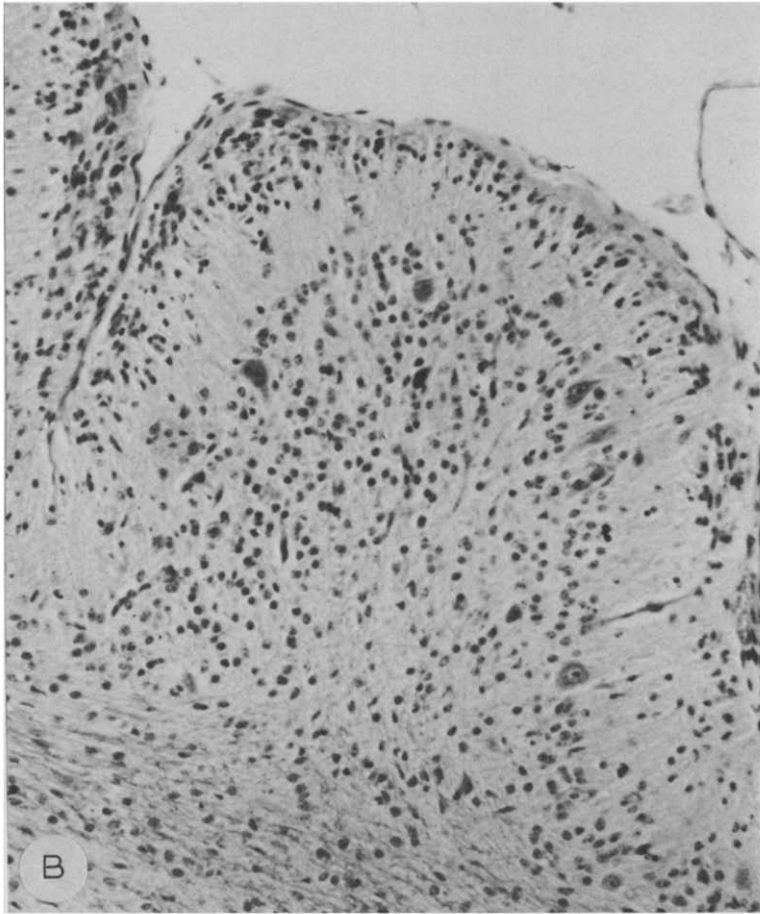


Fig. 7B.

The lesions occurring in both conditions at various levels of the neuraxis are compared in Table 1, and only a few features require further comment.

Chromatolysis of large neurones is one of the most constant features of all variants of swayback. In the brain stem it is found in the red nucleus, vestibular nuclei and reticular formation (Barlow et al. 1960). In the spinal cord the cells of the ventral horns, Clarke's column, ventral grey commissure and lateral horns are affected (Barlow 1963). The appearance of these cells superficially resembles that of axonal reaction, but differs from it both histochemically (Barlow and Cancilla 1966) and ultrastructurally (Cancilla and Barlow 1966). Chromatolytic cells are rarely seen at birth, but become prominent between 6 and 12 weeks of age (Smith et al. 1978). This lesion seems to have escaped notice in Menkes' disease and was found only after prolonged search in our two siblings. Iwata et al. (1979a,b) found loss of neurons in the nucleus ventralis oralis of the thalamus, the red nucleus, and

in Clarke's column, associated with degeneration of the dorsal spinocerebellar tracts, among the most constant lesions of Menkes' disease. Tract degenerations in the spinal cord are difficult to compare because of major anatomical differences between man and sheep, but in both species the dorsal columns remain intact.

White matter lesions, both in the form of gelatinous oedema and frank cavitation, are undoubtedly more common in swayback. In the oedematous form (Roberts et al. 1966) the white matter of the affected hemispheres is devoid of myelinated fibres and replaced by a meshwork of reactive astrocytes and glial fibres. The cavities, which form the most conspicuous lesions in a proportion of cases (Innes and Shearer 1960), are sharply demarcated, surrounded by a thin glial wall and generally devoid of products of tissue breakdown. In Menkes' disease there is general poverty of myelination of the centrum semiovale without evidence of active myelin breakdown (Vagn-Hansen et al. 1973, our Case 1). This suggests impaired myelin formation and supports Howell's concept of myelin aplasia, although

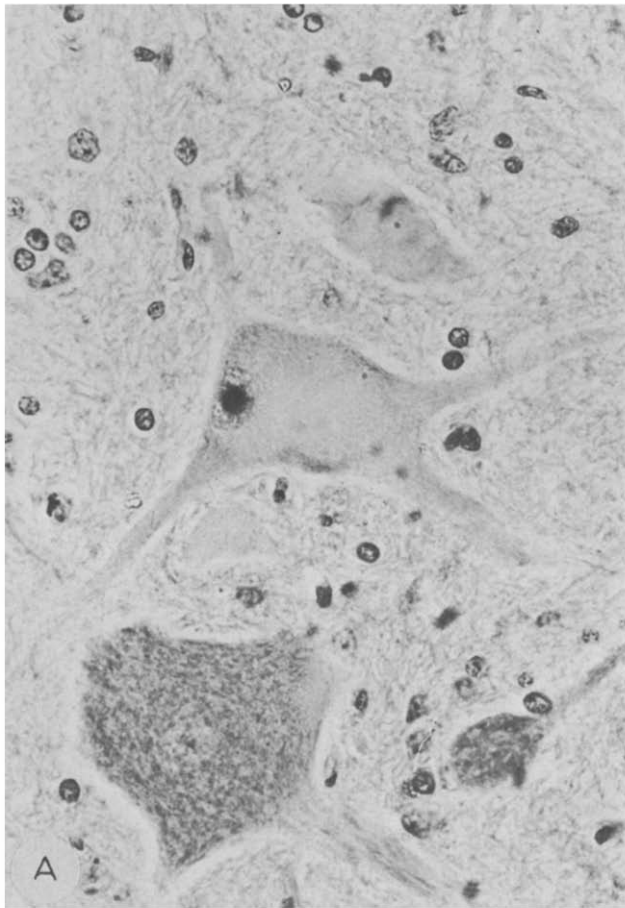


Fig. 8. Swayback (*A* and *B*). Two chromatolytic cells from ventral horn of spinal cord. H&E. $\times 450$.

loss of cortical and thalamic axons may also play a part. The lesions in Case 2 were reminiscent of classical swayback with a loose meshwork of glia interspersed with small cavities. Whether the vascular lesions, conspicuous in Case 2 and absent in Case 1, were responsible for the differences between the siblings remains debatable, as in swayback lesions of the white matter occur in the absence of any lesions in the cerebral arteries (Danks 1980).

Cerebellar atrophy is an almost constant feature of Menkes' disease, an intact cerebellum having been observed only once (Martin et al. 1978). In lambs, the cerebellum is affected in a minority of cases (Barlow 1963), but the lesion appears to be more common in copper deficient goats (Owen et al. 1965; Cordy and Knight 1978). In all species there is a considerable reduction in the number of granule cells associated with a variety of abnormalities in Purkinje cells. Barnard et al. (1978) noted an abnormal thickness of the external granular layer (EGL) in the affected parts of the cerebellar cortex in a case of Menkes' disease and

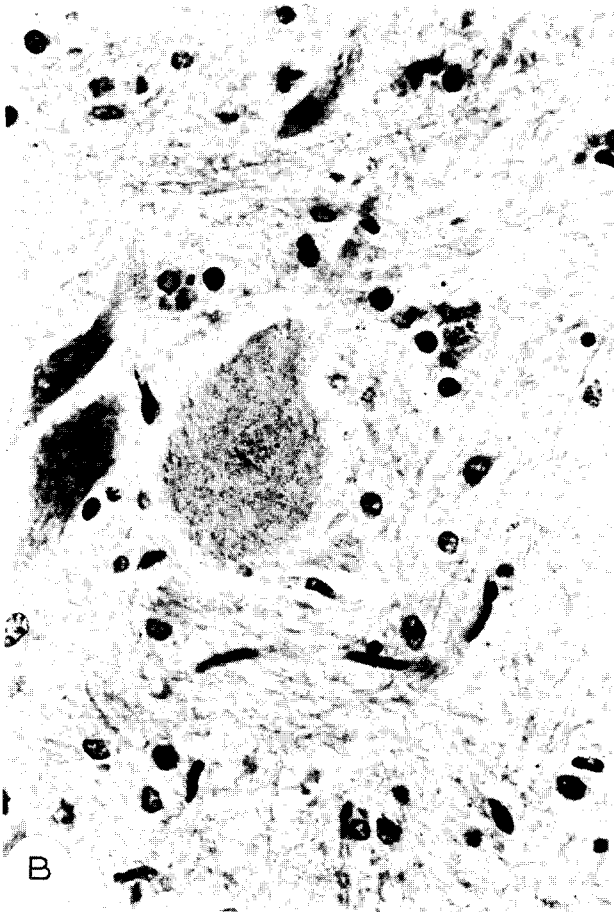


Fig. 8B.

TABLE 1

CNS LESIONS IN MENKES' DISEASE AND SWAYBACK

Type of lesion	Menkes' disease	Swayback
<i>Neuronal degenerations</i>		
Necrosis	Widespread	Widespread
Ferrugination	Common	Common
Vacuolation	Purkinje cells	Purkinje cells and cortical neurons
Chromatolysis	Rare (or unrecorded?)	Constant in a definite age group
<i>Cortical lesions</i>		
Laminar necrosis	Present in all cases	Present in all cases
Neuronal loss		with cerebral involvement
Status spongiosus		
<i>White matter lesions</i>		
Hypomyelination	Common	"Myelin aplasia"
Glial meshwork	Rare	in oedematous form common
Cavitation	Rare	
<i>Brainstem lesions</i>		
	Degeneration of red nucleus.	Chromatolytic cells in red nucleus,
	Rare chromatolytic cells	vestibular nuclei and reticular substance.
<i>Cerebellar lesions</i>		
	Almost constant	Uncommon in sheep.
		More common in goats.
<i>Spinal cord lesions</i>		
	Rare chromatolytic cells	Widespread chromatolytic cells.
	Degeneration of spino-cerebellar and pyramidal tracts	Degeneration of ventro-lateral columns

suggested that the depletion of the internal granular layer (IGL) was due to a migration arrest. Observations on swayback support this view. The EGL in newborn lambs is only 1–2 cells deep, while over the affected areas its thickness may reach 8–10 cells. The arrested cells subsequently undergo degeneration and areas devoid of the EGL may occur side by side with those of excessive thickness. No evidence of a uniform broadening of the EGL was found in our Case 2, only focal, rosette-like, aggregates of cells similar to the "cell knots" of Vagn-Hansen et al. (1973). Iwata et al. (1979b) expressed doubts about migration arrest and favoured progressive degeneration of the ICL, as they found increasing depletion of granule cells and, to a lesser extent, Purkinje cells with prolonged survival. The two views, however, are not mutually exclusive.

The abnormalities of Purkinje cells have been cited in evidence of the prenatal origin of the cerebellar lesions (Hockey and Masters 1977; Williams et al. 1977; Smith 1981). The relevant deviations from the normal pattern fall into three groups: (1) bizarre arborisations of the apical dendrites, (2) presence of polydendritic

neurons, (3) heterotopias. At present there is no evidence of these abnormalities in other species and they can only be compared with findings in other human diseases. The expansion, displacement and malorientation of the apical dendrites and their secondary and tertiary branches are the least specific of these features. They have been observed in a large variety of conditions associated with depletion of the granular cell layer, both congenital and acquired, and may be interpreted as a response of the Purkinje cell to partial deafferentation (Urich 1983). The presence of polydendritic cells constitutes a more pertinent argument. The fetal perisomatic dendrites are shed during maturation around the 35th week of gestation (Zcević and Rakić 1976). It is therefore reasonable to argue that retention of perisomatic dendrites implies an arrest in normal maturation and that the responsible factors must have operated in utero. Yet, as Purpura et al. (1976) remarked, they may be formed *de novo* after the fetal dendrites have disappeared. Their presence in acquired conditions such as industrial organic mercury poisoning (Hunter and Russell 1954) and olivopontocerebellar degeneration (Fujisawa and Nakamura 1982) supports this view. It is therefore possible to view all dendritic abnormalities as expression of neuronal plasticity. There are at present no criteria by which one could confidently distinguish developmental from reactive plasticity.

Subcortical heterotopias of Purkinje cells have been reported in one case only (Erdohazi et al. 1976; Barnard et al. 1978). This represents a disorder of migration and is therefore a genuine prenatal malformation. It is, however, one of the more common cerebellar abnormalities and has been observed in otherwise normal infants (Rorke et al. 1968). Its relevance to the pathogenesis of Menkes' disease thus requires further elucidation. The authors claim it as the first malformation recorded in Menkes' disease, thus implying that they consider the abnormalities of the Purkinje cells to be reactive. Similarly Vagn-Hansen et al. (1973) dismiss these changes as reactive without further comment.

In conclusion, this study has revealed that all lesions of Menkes' disease have their counterpart in swayback and can therefore be confidently ascribed to copper deficiency. The problem of the prenatal versus postnatal origin of lesions remains unresolved. While some disturbances of copper metabolism are undoubtedly present in the fetus their significance in the pathogenesis of the cerebellar lesions cannot be deduced from morphological findings alone, as these are not specific, occur in a variety of conditions, and are open to alternative interpretations.

ACKNOWLEDGEMENTS

We are indebted to Dr. P.J. Pemberton for his clinical records, Dr. G.J. Cullity for referring material for examination, Drs. A. Hockey and C.L. Masters for permission to re-examine Case 1 of Menkes' disease. We are grateful to Dr. A.C. Palmer, Department of Veterinary Medicine, Cambridge, Dr. S. Terlecki and Mr. Martin Jeffrey, Central Veterinary Laboratory, Weybridge and Professor J. McC. Howell, Department of Veterinary Pathology, Murdoch University for access to their swayback material and helpful discussions. Our thanks are due to

Professor B. A. Kakulas for his interest and encouragement, to the technologists of the Department of Neuropathology for technical work, Richard Timm for photography and Dianne Chantler and Patsy Cunningham for secretarial help.

REFERENCES

- Barlow, R. M. (1963) Further observations on swayback, Part 1 (Transitional pathology). *J. Comp. Path.*, 73: 51-60.
- Barlow, R. M. and P. A. Cancilla (1966) Structural changes of the central nervous system in swayback (enzootic ataxia) of lambs, Part 1 (Light microscopy using phosphatases as organelle markers). *Acta Neuropath. (Berl.)*, 6: 175-180.
- Barlow, R. M., D. Purves, E. G. Butler and I. J. Macintyre (1960) Swayback in South-East Scotland, Part 2 (Clinical pathological and biochemical aspects). *J. Comp. Path.*, 60: 411-427.
- Barnard, R. O., P. V. Best and M. Erdohazi (1978) Neuropathology of Menkes' disease. *Dev. Med. Child Neurol.*, 20: 586-597.
- Camakaris, J., J. R. Mann and D. M. Danks (1979) Copper metabolism in mottled mouse mutants — Copper concentrations in tissues during development. *Biochem. J.*, 180: 597-604.
- Cancilla, P. A. and R. M. Barlow (1966) Structural changes of the central nervous system in swayback (enzootic ataxia) of lambs, Part 2 (Electron microscopy of the lower motor neuron). *Acta Neuropath. (Berl.)*, 6: 251-259.
- Cordy, D. R. and H. D. Knight (1978) California goats with a disease resembling enzootic ataxia or swayback. *Vet. Path.*, 15: 179-185.
- Danks, D. M. (1980) Copper deficiency in humans. In: D. Evered and G. Lawrenson (Eds.), *Biological Roles of Copper* (Ciba Foundation Symposium 79), Excerpta Medica, Amsterdam, Oxford, New York, pp. 209-225.
- Danks, D. M., P. E. Campbell, B. J. Stevens and E. Cartwright (1972) Menkes' kinky hair syndrome — An inherited defect in copper absorption with widespread effects. *Pediatrics*, 50: 188-201.
- Dunlop, G., J. R. M. Innes, G. D. Shearer and H. E. Wells (1939) "Swayback" studies in North Derbyshire, Part 1 (The feeding of copper to pregnant ewes in the control of "swayback"). *J. Comp. Path.*, 52: 259-265.
- Erdohazi, M., N. D. Barnes, M. J. Robinson and B. D. Lake (1976) Cerebral malformation associated with metabolic disorder. *Acta Neuropath. (Berl.)*, 36: 315-325.
- French, J. H., E. S. Sherard, H. Lubell, M. Brotz and C. L. Moore (1972) Trichopolydystrophy, Part 1 (Report of a case and biochemical studies). *Arch. Neurol. (Chic.)*, 26: 229-244.
- Fujisawa, K. and A. Nakamura (1982) The human Purkinje cells — A Golgi study in pathology. *Acta Neuropath. (Berl.)*, 56: 255-264.
- Hockey, A. and C. L. Masters (1977) Menkes' kinky (steely) hair disease. *Aust. J. Derm.*, 18: 77-80.
- Horn, N. (1976) Copper incorporation studies on cultured cells for prenatal diagnosis of Menkes' disease. *Lancet*, i: 1156-1158.
- Howell, J. McC. (1968) Observations on the histology and possible pathogenesis of lesions in the central nervous system of sheep with swayback. *Proc. Nutr. Soc.*, 27: 85-88.
- Howell, J. McC., A. N. Davison and J. Oxberry (1964) Biochemical and neuropathological changes in swayback. *Res. Vet. Sci.*, 5: 376-384.
- Howell, J. McC., D. A. Pass and S. Terlecki (1982) Swayback lesions and vulnerable periods of development. In: J. M. Gawthorne, J. McC. Howell and C. L. White (Eds.), *Trace Element Metabolism in Man and Animals*, Springer-Verlag, Berlin, Heidelberg, New York, pp. 298-301.
- Hunter, D. and D. S. Russell (1954) Focal cerebral and cerebellar atrophy in a human subject due to organic mercury compounds. *J. Neurol. Neurosurg. Psychiat.*, 17: 235-241.
- Innes, J. R. M. (1939) Swayback: a demyelinating disease of lambs with affinities to Schilder's encephalitis and its prevention by copper. *J. Neurol. Psychiat.*, N.S. 2: 323-334.
- Innes, J. R. M. and G. D. Shearer (1940) "Swayback": a demyelinating disease of lambs with affinities to Schilder's encephalitis in man. *J. Comp. Path.*, 53: 1-41.
- Iwata, M., A. Hirano and J. H. French (1979a) Thalamic degeneration in X-chromosome linked copper malabsorption. *Ann. Neurol.*, 5: 359-366.
- Iwata, M., A. Hirano and J. H. French (1979b) Degeneration of the cerebellar system in X-chromosome linked copper malabsorption. *Ann. Neurol.*, 5: 542-549.

- Mann, J. R., J. Camakaris, D. M. Danks and E. Walliczer (1979a) Copper metabolism in mottled mouse mutants – Copper therapy of brindled (Mo^{br}) mice, *Biochem. J.*, 180: 605–612.
- Mann, J. R., J. Camakaris and D. M. Danks (1979b) Copper metabolism in mottled mouse mutants – Distribution of ^{64}Cn in brindled (Mo^{br}) mice, *Biochem. J.*, 180: 613–619.
- Martin, J. J., J. Flament-Durand, J. P. Farriaux, N. Buyssens, P. Ketelbant-Balasse and C. Jansen (1978) Menkes' kinky hair disease – A report on its pathology, *Acta Neuropath. (Berl.)*, 42: 25–32.
- Menkes, J. H., M. Alter, G. K. Steigleder, D. R. Weakley and J. H. Sung (1962) A sex-linked recessive disorder with retardation of growth, peculiar hair and focal cerebral and cerebellar degeneration, *Pediatrics*, 29: 764–779.
- Nagara, H., K. Yajima and K. Suzuki (1980) An ultrastructural study of the cerebellum in the brindled mouse, *Acta Neuropath. (Berl.)*, 52: 41–50.
- Owen, E. C., R. Proudfoot, J. M. Robertson, R. M. Barlow, E. J. Butler and B. S. W. Smith (1965) Pathological and biochemical studies of an outbreak of swayback in goats, *J. Comp. Path.*, 75: 241–251.
- Purpura, D. P., A. Hirano and J. H. French (1976) Polydendritic Purkinje cells in X-chromosome linked copper malabsorption – A Golgi study, *Brain Res.*, 117: 125–129.
- Rorke, L. B., H. E. Riggs and M. H. Fogelson (1968) Cerebellar heterotopia in infancy, *J. Neuropath. Exp. Neurol.*, 27: 140.
- Smith, R. M. (1981) Menkes' disease and the role of copper in brain development. In: B. S. Hetzel and R. M. Smith (Eds.), *Fetal Brain Disorders – Recent Approaches to the Problem of Mental Deficiency*, Elsevier/North-Holland, Amsterdam, New York, Oxford, pp. 365–388.
- Smith, R. M., F. J. Fraser, G. R. Russell and J. S. Robertson (1977) Enzootic ataxia in lambs – Appearance of lesion in the spinal cord during foetal development, *J. Comp. Path.*, 87: 119–128.
- Smith, R. M., F. J. Fraser and J. S. Robertson (1978) Enzootic ataxia in lambs – Absence of detectable neuronal pathology in foetal and neonatal spinal cord, *J. Comp. Path.*, 88: 401–408.
- Spais, A., P. A. Palsson and L. Van Bogaert (1961) Pathology of enzootic ataxia of lambs, *Acta Neuropath. (Berl.)*, 1: 56–72.
- Suzuki, K. and H. Nagara (1981) Brindled mottled mouse – Morphological changes of brain and visceral organs in hemizygous males following copper supplementation, *Acta Neuropath. (Berl.)*, 55: 251–255.
- Urieh, H. (1983) The plasticity of the Purkinje cell, *Clin. Exp. Neurol.*, Eds. J. Tyrer and M. Eadie (Eds.), ADIS Health Science Press. In press.
- Vagn-Hansen, P. L., E. Reske-Nielsen and H. C. Lou (1973) Menkes' disease: a new leucodystrophy – A clinical and neuropathological review together with a new case, *Acta Neuropath. (Berl.)*, 25: 103–119.
- Williams, R. S., P. C. Marshall, I. T. Lott and V. S. Caviness (1978) The cellular pathology of Menkes' steely hair syndrome, *Neurology (Minneapolis)*, 28: 575–583.
- Zecević, N. and P. Rakić (1976) Differentiation of Purkinje cells and their relationship to other components of developing cerebellar cortex in man, *J. Comp. Neurol.*, 167: 27–48.