

Vertebro-Basilar Arterial Occlusion in Childhood —Report of a Case and Review of the Literature—

Bernard Echenne, MD, Michel Gras, MD, Jacques Astruc, MD,
Philippe Castan, MD and Denis Brunel, MD

A 9-year-old boy developed ataxia, right transient hemiparesis, left transient hemichorea, dysarthria and swallowing difficulties with left velar paralysis following two transient episodes of vomiting, headache and dizziness. Angiography demonstrated an occlusion of the distal part of the basilar artery. Thirty-six previously reported cases of vertebro-basilar arterial occlusion in children were reviewed, with particular regard to possible etiologies.

Echenne B, Gras M, Astruc J, Castan P, Brunel D. Vertebro-basilar arterial occlusion in childhood – Report of a case and review of the literature. Brain Dev 1983;5:577-81

Vertebro-basilar artery occlusion is a rare occurrence during childhood. We report a case in a 9-year-old boy, with analysis of the relevant literature.

Case Report

B.J. was a 9-year-old boy in good health until he developed headache, vomiting, and dizziness on November 29, 1981. There was no definite history of trauma. These manifestations lasted for three days and were followed by complete recovery. Ten days later he had a vertiginous attack lasting about 24 hours, during which he vomited and developed headache. One month later on December 29, he experienced another recurrence of symptoms, with headache, vomiting, nystagmus, ataxia and left-sided choreic movements.

He was admitted to the hospital on December 31. There was no fever (37.1°C), he was

somnolent, and exhibited inappropriate behaviour, with occasional bursts of uncontrollable laughter. He complained of headache with nausea and vomiting. His speech was slow and slurred. Neurological examination revealed a moderate ataxia; he had a clumsy, wide-based gait and bilateral dysmetria on heel-shin tapping, greater on the left. Bilateral dysmetria and dysdiadochokinesia were observed, being more severe on the left side. The choreic movements had disappeared. Pupils were equal and no ptosis or nystagmus were noted. The cranial nerves were normal. There was no leg paralysis; muscle stretch reflexes were normal and equal on both sides. The physical examination was otherwise normal except for a systolic cardiac murmur with a well-tolerated ventricular septal defect which has been apparent since the first months of life.

On January 2 a rapid worsening was noted. The ataxia became more severe and a right hemiparesis with Babinski sign was observed for 48 hours with spontaneous disappearance. Dysarthria and dysphonia with hoarseness were noted, and swallowing difficulties required transitory tube-feeding. There was left velar paralysis at examination.

From the Clinique des Maladies Infectieuses B (Service de Pédiatrie); Service de Neuroradiologie, Centre GUI de CHAULIAC, Montpellier.

Received for publication: June 18, 1983.

Accepted for publication: November 1, 1983.

Key words: Basilar artery occlusion, arterial diseases.

Correspondence address: Dr. Bernard Echenne, Neurologie Infantile, Centre GUI de CHAULIAC, F-34059 Montpellier cedex, France.

Laboratory Data

There was no leucocytosis and erythrocyte sedimentation rate and serum protein electro-

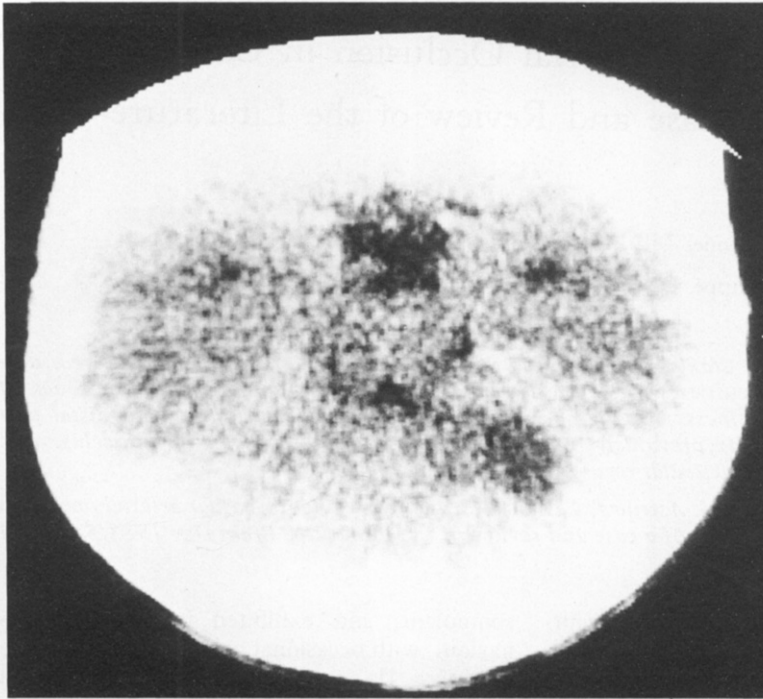


Fig 1 CT scan. An area of decreased density in the peripheral part of the left cerebellar hemisphere can be seen.

phoresis were normal. Chest roentgenograms and ECG were also within normal limits. Urine tests for homocystinuria were negative. EEG was slowed, with predominance of delta and theta waves on the left side. Results of fundoscopic examination were normal. The opening fluid pressure was 150 mm H₂O and the CSF was clear and colorless with a normal blood cell count and chemistry. CT scan on December 31, 1981, and January 8, 1982, showed an area of decreased density in the left cerebellar hemisphere (Fig 1) that was not enhanced by contrast injection. Cerebral angiography was performed on January 8. Left brachial and then right brachial angiograms showed a filling defect at the distal portion of the basilar artery (Fig 2). The posterior inferior cerebellar arteries were clearly seen and normal. The superior cerebellar arteries were not seen directly, but were later filled from distal anastomosis with the distal branches of the anterior inferior cerebellar arteries. Carotid angiograms demonstrated a normal course of the anterior and middle cerebral arteries. The posterior cerebral arteries were normal.

Follow-Up

The cause of the basilar artery occlusion was not found; there was no history of trauma, no endocarditis, and despite a ventricular septal defect grade I, the left cardiac cavities were normal upon bidimensional echocardiography. Coagulation tests and antithrombin III were normal, as were lipids and lipoproteins, with normal levels of triglycerides and of low and high density lipoprotein cholesterol. Skull roentgenograms and tomograms were within normal limits.

The patient was treated with acetylsalicylic acid and dipyridamole. Thereafter, the symptoms improved gradually. The patient's mental state rapidly became normal, and swallowing difficulties and dysarthria disappeared within a few days, and the ataxia progressively improved. He was discharged home one month after admission. Neurologic examination on June 5, 1983, was quite normal except for a mild residual dysarthria and left-sided ataxia. CT scan and bilateral angiography showed the same abnormalities obtained on the December 31 angiograms.

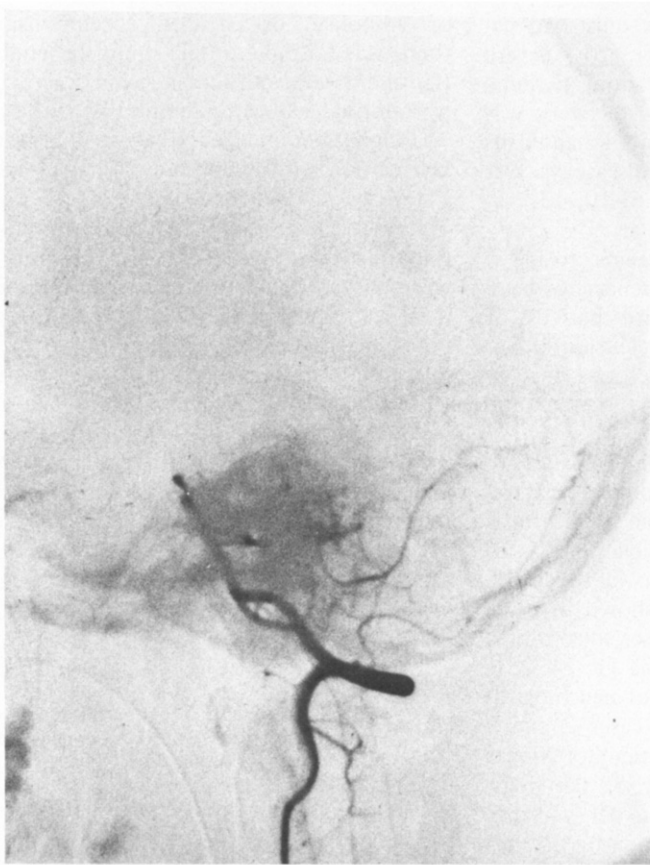


Fig 2 *Left brachial angiogram. A thrombosis of the distal portion of the basilar artery is noted.*

Comments

In contrast to the well-documented and frequent occurrence of basilar artery occlusion in adults, to our knowledge there are only 36 childhood cases described [1-29], with a strong predominance of males (sex ratio M/F = 10:1), but with no particular age distribution (from nine months to 16 years of age). The common initial symptoms in children are the same as in adults. One can generally observe several attacks of transient basilar insufficiency, the patient being well in the intervals. These manifestations are of sudden onset and can last from some hours to several days, with recovery lasting several weeks or months [8, 9, 12, 18, 25]. All grades of severity may be seen, from occasional brief attacks of vertigo to the apoplectic occurrence of coma. Neurological signs are miscellaneous: headache, vomiting, hemiparesis or hemiplegia, ataxia, vertigo, disturbance of consciousness varying from stuporous state to deep coma, oculomotor

nerve palsies, and uni- or bilateral facial palsy are the more frequent signs observed. Less frequently, quadriplegia, dysarthria, nystagmus, facial or bodily paresthesiae, 9th, 10th and 11th cranial nerve palsies with swallowing difficulties or irregular breathing, paralysis of the 12th and generalized tonic-clonic fits can be seen. Wallenberg's and Horner's syndromes have been described [7, 8, 11, 20].

In our patient, recurrent vertigo and left-sided ataxia, right transient hemiparesis, left transient hemi-chorea, dysarthria, hoarseness and then aphony and swallowing difficulties with left velar paralysis seemed to correspond to an ischemia affecting the left part of the cerebellar hemisphere and of the brain stem.

The prognosis is good when any definite cause can be found. Though seven patients died [1, 3, 5, 7, 17, 19], five of them experienced either vascular dysplasia [17, 19], or a concomitant severe illness (generalized sepsis [3], cardiorespiratory insufficiency [7],

trauma [1]). Death occurred in only two patients with unproved etiology [3, 5]. Severe sequelae had been observed in three patients [9, 16, 24]. In the other cases, recovery was complete (10 cases) or with mild handicaps (10 cases). The evolution of the disease was not described in seven cases [2, 4, 6, 10, 13, 15, 16].

Vertebro-basilar occlusion seems to be a unique pathology and no recurrence has been described, except for the third patient of Latchaw et al [16], in whom occlusion of the basilar and left vertebral arteries was demonstrated 15 years after the first post-traumatic episode.

The causes of vertebro-basilar occlusion are rarely demonstrated. Basilar embolism has rarely been observed during bacterial endocarditis [9], cardiorespiratory insufficiency [7], or generalized sepsis [3]. Arteritis or dysplasia of the arterial wall had been shown in three cases [17, 19, 24]. In some cases, thrombosis was secondary to a severe trauma [1, 14, 25]; head trauma prior to the onset of neurological symptoms was documented in cases 2 and 3 of Latchaw et al [16]. The patient of Singer et al [18] had an abnormality of the dens, permitting a subluxation of the C1 vertebra on C2 with secondary compression of the vertebral arteries. Stenosis of the distal vertebral arteries resulting from simple neck turning has been reported by Bergen et al [28]. In some cases it seems that the vertebral arteries were congenitally tortuous at the C2 level [12], predisposing the patient to intermittent occlusion depending on the neck position. In other cases, mild trauma or repeated spontaneous subluxations of C1 on C2 can lead to stretching and tearing of the vertebral arteries, with gradual occlusion and thrombosis. Vertebral occlusion at the C2 level has often been seen angiographically [9, 12, 14, 16, 18, 22, 25], suggesting a vulnerability of the vertebral artery in its cervical course. It is important to emphasize that some cases of C1-C2 dislocation may not be shown in plain cervical spine films and may require flexion-extension views and tomograms for diagnosis [30].

In the majority of cases, however, the cause remains unknown, as it is in 19 out of the 32 cases where the etiology is mentioned. In our case, the coexistence of a ventricular septal defect grade I made us consider the possibility

of embolism or paradoxical embolism, but there was no right to left shunt, no endocarditis, and a left ventricular lesion was excluded by a normal echocardiogram.

Diagnosis of vertebro-basilar thrombosis is facilitated by CT scan and is characterized by an area of decreased density affecting the cerebellar hemisphere [25, 27], the wall of the fourth ventricle [25], or the pons [23], without ventricular dilatation or mass effect. Contrast injection is necessary because of the possibility of transitory disappearance of the infarcted zone between the 10th and the 20th days [31]. However a combination of carotid and vertebral angiography is always required to define brain perfusion by unusual routes, and to demonstrate vertebral artery occlusion [6].

References

1. Murray DS. Post-traumatic thrombosis of the internal carotid and vertebral arteries after non penetrating injuries in the neck. *Br J Surg* 1957; 44:556-61.
2. Okada R, Fukuyama Y, Arima M, Maruyama H. A case of transient vertebro-basilar insufficiency (in Japanese). *J Pediatr Pract (Tokyo)* 1962;24: 1353-61.
3. Fowler M. Two cases of basilar artery occlusion in childhood. *Arch Dis Child* 1962;37:78-81.
4. Kowada M, Narita A, Sasao T. Two cases of basilar artery occlusion (in Japanese). *Clin Neurol (Tokyo)* 1962;2:201-3.
5. Komatsu F. Pathology of basilar artery obstruction (in Japanese). *Clin Neurol (Tokyo)* 1965;4: 66-84.
6. Schechter MM, Zingesser LH. The radiology of basilar thrombosis. *Radiology* 1965;85:23-32.
7. Richwien R, Unger G. Beobachtung eines Wallenberg-Syndroms im Kindesalter nebst Bemerkungen zum kindlichen cerebralen Gefäß-prozess. *M Schr Kinderheilk* 1966;8:442-3.
8. Dooley JM, Smith KR. Occlusion of the basilar artery in a 6-year-old boy. *Neurology* 1968;18: 1034-6.
9. Ouvrier RA, Hopkins IJ. Occlusive disease of the vertebro-basilar system in childhood. *Dev Med Child Neurol* 1970;12:186-92.
10. Harwood-Nash DC, McDonald P, Argent W. Cerebral artery disease in children: An angiographic study of 40 cases. *Am J Roentgenol* 1971;111:672-86.
11. Isler W. Acute hemiplegias and hemisyndromes in childhood. *Clinics in developmental medicine* No 41/42. London: Heinemann, 1971:56.
12. De Vivo DC, Farrel FW Jr. Vertebrobasilar occlusive disease in children. *Arch Neurol* 1972; 26:278-81.
13. Moscow NP, Newton TH. Angiographic implication in diagnosis and prognosis of basilar artery

- occlusion. *Am J Roentgenol* 1972;26:278-81.
14. Marks RL, Freed MM. Non penetrating injuries of the neck and cerebrovascular accident. *Arch Neurol* 1973;28:412-4.
 15. Shimizu T, Masuzawa H, Nakazawa H, Muranushi Y. A case of vertebrobasilar artery occlusion in childhood (in Japanese). *Clin Neurol (Tokyo)* 1973;13:405.
 16. Latchaw RE, Seeger JF, Gabrielsen TO. Vertebrobasilar arterial occlusion in children. *Neuroradiology* 1974;8:141-7.
 17. Marsden HB. Basilar artery thrombosis and giant cell arteritis. *Arch Dis Child* 1974;49:75.
 18. Singer WD, Haller JS, Wolpert SM. Occlusive vertebrobasilar artery disease associated with cervical spine anomaly. *Am J Dis Child* 1975;129:492-5.
 19. Sakata R, Itoh H, Miwa T. A case of occlusion of vertebrobasilar artery in childhood (in Japanese). *Clin Neurol (Tokyo)* 1975;15:609-19.
 20. Klein RA, Snyder RD, Schwarz HJ. Lateral medullary syndrome in a child. Arteriographic confirmation of vertebral artery occlusion. *JAMA* 1976;235:940-1.
 21. Lillquist KB, Ingstrup HM. Spontaneous cerebral thrombosis in children: Report of two cases. *Acta Paediatr Scand* 1976;65:119-24.
 22. Pascual-Castroviejo I, Pascual-Pascual JI, Mulas F, Roche MC, Tendero A. Bilateral obstruction of the vertebral arteries in a three-year-old child. *Dev Med Child Neurol* 1977;19:232-7.
 23. Ackerman ES, Levinsohn MW, Richards D, Bonstelle C, Mitchell M. Basilar artery occlusion in A 10-year-old boy. *Ann Neurol* 1977;1:204-5.
 24. Matsumoto Y, Shimizu H, Sai Y, Sumi K, Murata S. A case of basilar artery occlusion in childhood (in Japanese). *Nō To Hattatsu (Tokyo)* 1977;9:499-503.
 25. Zimmermann AW, Kumar AJ, Gadoth N, Hodges FJ. Traumatic vertebrobasilar occlusive disease in childhood. *Neurology* 1978;28:185-8.
 26. Mori K, Miwa S, Murata T, Okumura A, Handa H. Basilar artery occlusion in childhood. Report of a case. *Arch Neurol* 1979;36:100-2.
 27. Livet MO, Raybaud C, Pinsard N, Bernard R. Aspects diagnostiques des occlusions artérielles cérébrales de l'enfant. *Ann Pediatr* 1980;27:277-85.
 28. Bergen BJ, Batnitzky S, Morantz RA, Price HI. Cerebellar infarction with associated acute hydrocephalus due to vertebral artery occlusion in a child. *Neurosurgery* 1981;8:383-7.
 29. Matsuishi T, Yano E, Terasawa K, et al. Basilar artery occlusion in a case of Duchenne muscular atrophy. *Brain Dev (Tokyo)* 1982;4:379-84.
 30. Fraser RAR, Zimble SM. Hindbrain stroke in children caused by extracranial vertebral artery trauma. *Stroke* 1975;6:153-9.
 31. Backer H, Desch H, Hacker H, Penez A. CT fogging effect with ischemic cerebral infarcts. *Neuroradiology* 1979;18:185-92.