

Cavernous sinus thrombosis with retrobulbar mass and hemiplegia

R. Rodrigues, M.D., R. Merchant, M.D. and S. Parekh, M.R.C.P.

The clinical course and investigations of a three year old child who developed cavernous sinus thrombosis are presented, and the problems in the diagnosis and management highlighted. The peculiar features of this case were the presence of a retrobulbar mass and hemiplegia.

Key words: Cavernous sinus thrombosis; retrobulbar mass; hemiplegia.

Cavernous sinus thrombosis (CST) is not an uncommon entity in children. Before the antibiotic era the condition was uniformly fatal, while currently reported mortality is about 25 percent in treated cases.¹ It was first described by Abercrombie (1818) and Duncan (1821).² The cavernous sinus has numerous connections with the face, eyes, sinuses, mastoid, middle ear, pituitary, cerebrium, cerebellum as well as the opposite cavernous sinus, thus allowing for an easy spread of infection. In most reported cases the face is the primary site of infection and the commonest organism isolated is *Staphylococcus aureus*.³ The complications encountered are blindness, cranial nerve palsies, meningitis, subdural empyema, hypopituitarism⁴ and metastatic spread of infection to other organs.

Case report

A three year old female child who had previously been in good health, presented with a boil in the right nostril and high fever, followed by a progressive swelling of the right eye. On the seventh day of fever she developed weakness of the left side of the body and a facial asymmetry. There was no

history to suggest sinusitis, ear discharge, trauma or involvement of the other eye. On examination she was conscious, febrile and highly irritable. There was marked proptosis, chemosis and sub conjunctival haemorrhage, a fixed dilated pupil, ptosis and complete ophthalmoplegia of the right eye. There was no audible bruit. Examination of the left eye revealed no abnormality. The child had a dense left hemiparesis, left facial weakness, neck stiffness and a positive Kerning's sign.

The hemoglobin was 8.0 gms/dl, total white cell count was 9200/cu mm with 68 percent polymorphs, 30 percent lymphocytes and 2 percent eosinophils. The chest and skull radiographs were normal. The cerebrospinal fluid (CSF) on admission was turbid with 500 cells, 60 mg percent proteins and 36 mg percent sugar. After two weeks of treatment the CSF was clear with 18 cells, 40 mg percent proteins and 56 mg percent sugar. CSF and blood cultures were sterile. A radioisotope brain scan with dynamic cerebral blood flow studies showed absent perfusion of right middle cerebral artery (MCA) and a large area of abnormal concentration triangular in shape corresponding to the area supplied by the MCA. The electro-encephalogram showed marked asymmetry of electrical activity with decreased activity on the right side, particularly the temporal area consistent with a state of cerebral infarction.

Bai Jerbai Wadia Children's Hospital and Institute of Child Health, Parel, Bombay-400 0022.

Reprint requests: Dr. R. Merchant, Hon. Associate Pediatrician

Ultrasound of the right eye revealed a retrobulbar, sonolucent mass of 1.2 cms size with well defined borders. The optic nerve, retina and lens appeared normal. The computerised tomography (CT) scan reported a very large infarct in the peripheral portion on the right cerebral hemisphere (Fig. 1) and a highly attenuated retrobulbar mass (Fig. 2).

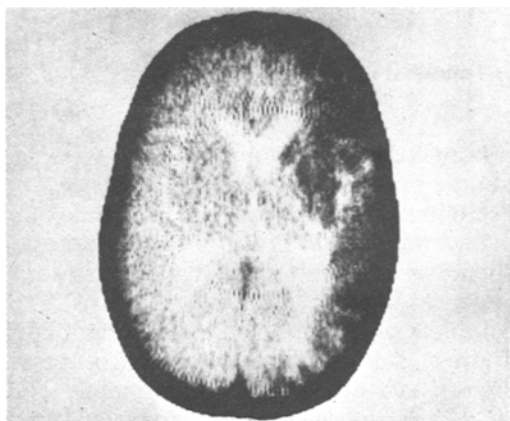


Fig. 1. The CT scan which shows a massive infarct in the periphery of the right cerebral hemisphere.

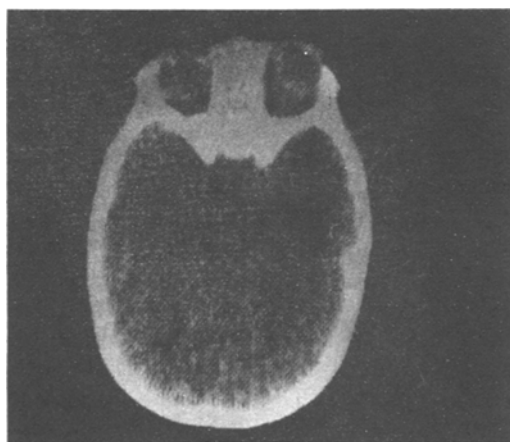


Fig. 2. The presence of proptosis and a retrobulbar mass on the right side can be appreciated on this section of the CT scan.

The patient after admission was treated with high doses of parenteral antibiotics along with usual supportive therapy. Anti-coagulants were not administered at any time. She showed a gradual improvement in clinical status and made an uneventful recovery. Six weeks later there was reduction in the proptosis, the ophthalmoplegia had disappeared, the pupil was reacting to light and the power on the left side had improved.

Discussion

The child we have described exhibited the classical sequence of events one sees in CST, namely a primary infection in the nose followed by signs of involvement of the cavernous sinus on the same side. There were two unusual features in this case, the retrobulbar mass and the hemiplegia. The retrobulbar mass was detected by both the ultrasound as well as the CT scan. A differential diagnosis of retrobulbar edema or abscess was considered. We were unable to come across references of ultrasound of the eye in CST and were in a dilemma as what to do. At this time the child's condition had settled, she appeared to be recovering and hence we decided to follow a course of watchful expectancy. This paid dividends as shown by the outcome of the disease.

Hemiplegia is a fairly unusual presentation in CST and in most cases is due to involvement of the internal carotid artery. Although internal carotid arteritis is a common entity in children, CST as a cause of this is quite rare. A case of CST with involvement of the carotid artery and a vascular steal syndrome has been described.⁵ Our case in all probability had involvement of the internal carotid artery and this could have been confirmed by carotid angiography. In view of the invasiveness of the procedure and the fact that other non-invasive techniques had provided adequate information, we did not do a carotid angiogram.

References

1. Friberg T, Gogg R: Ischaemic optic neuropathy in cavernous sinus thrombosis. **Arch Ophthalm** 96: 453, 1978
2. Gupta MC, Ahuja OP, Kumar S: Cavernous sinus thrombosis with a brief review of literature. **Indian J Med Sci** 24: 748, 1970
3. Dhir BK, Rathore UG: Cavernous sinus thrombophlebitis due to boil on the nose. **J Indian Med Assoc** 43: 393, 1964
4. Oliven A, Horel D, Rosenfeld T, Spindel A, Gidron E: Hypopituitarism after aseptic cavernous sinus thrombosis. **Neurology** 30: 897, 1980
5. Kinnard PM, Acker JD, Snead OC: Cavernous sinus thrombosis with vascular steal syndrome. **J Pediatr** 94: 410, 1979