

Short report

Isolated facial palsy: a new lacunar syndrome

CHENYA HUANG, GERALD BROE

From the Department of Medicine, University of Hong Kong, Queen Mary Hospital, Hong Kong and Department of Neurology, Lidcombe Hospital, Lidcombe, Australia

SUMMARY Three cases of sudden isolated upper motor neuron facial palsy and two with associated pseudobulbar palsy have been seen. All were without significant limb weakness. Computed tomography demonstrated small deep infarcts in the internal capsular/corona radiata regions. Pure upper motor neuron facial palsy may be another lacunar syndrome, due to a lesion in the internal capsule or corona radiata.

Most facial palsies are lower motor neuron lesions. Occasionally however, an isolated facial palsy is seen which appears to be upper motor neuron in nature. Prior to the availability of CT scan, the site of such lesion was unknown. Some have been ascribed to peripheral facial nerve lesions.¹ Puvendren, Wong and Ransome described in 1979 five patients with sudden onset of dysarthria, dysphagia and upper motor neuron facial palsy.² EEG and isotope scans were normal in all their cases. They postulated that the lesion may have been in the corticobulbar tracts in the brainstem. We have seen five cases of facial palsy, showing capsular/corona radiata lesions on the CT scans.

Case histories

Case 1

Four weeks prior to admission to hospital this 49-year-old Egyptian male patient noted the sudden onset of difficulty in speaking associated with weakness of the right side of the face. A diagnosis of Bell's palsy was made by his doctor and he was treated with prednisone. Gradual and almost complete recovery of speech and facial weakness occurred over the following weeks. Two days prior to admission to hospital in August 1979, he noted the sudden onset of weakness of the left side of the face associated with complete inability to speak or swallow. There was no associated disorder of language or understanding and no ataxia nor disturbance of limb function. There was no previous history of hypertension, diabetes or vascular disease. The patient smoked 50 cigarettes a day.

Address for reprint requests: Dr CY Huang, Department of Medicine, University of Hong Kong, Queen Mary Hospital, Hong Kong.

Received 22 July 1983. Accepted 6 August 1983.

On examination blood pressure was 130/90 mm Hg. He had a left upper motor neuron facial paresis, complete anarthria and aphagia. Jaw jerk was not increased. Tone, power, coordination and sensation were normal; however the patient veered slightly to the left on walking. CSF examination showed 1 mononuclear cell/mm³ with normal biochemistry and serology. EMG of facial muscles showed no abnormality. CT scan showed small low density lesions bilaterally in the region of corona radiata adjacent to the basal ganglia (fig 1). Haematology and biochemistry were normal. Two months later a severe residual dysarthria remained. There was almost full recovery on review after two years.

Case 2

This 61-year-old Laotian male patient developed sudden right-sided throbbing headache which was not severe and lasted about 24 hours. This was associated with left-side facial weakness but no other neurological symptoms. There was a 10 year history of controlled hypertension and he smoked 20 cigarettes a day. On examination he showed a mild left facial weakness of upper motor neurone type with no other neurological deficit. CT scan showed a small deep infarct in the region of the right corona radiata (fig 2). Other investigations including nuclear scan and EMG were normal. His facial palsy resolved over a few days.

Case 3

This 55-year-old Chinese female patient suddenly developed a dysarthria, dysphagia, incontinence of urine and unsteady gait. Previous health had been unremarkable. On admission blood pressure was 140/90 mm Hg with a right upper motor neuron facial palsy, dysarthria, dysphagia, poor tongue movement, normal gag reflex, bilateral brisk tendon reflexes and extensor plantar response. Tone, power, coordination and sensations were however normal. Routine investigations were normal. She rapidly improved within the next two days. CT scan showed bilateral small infarction in the corona radiata anteriorly (fig 3).

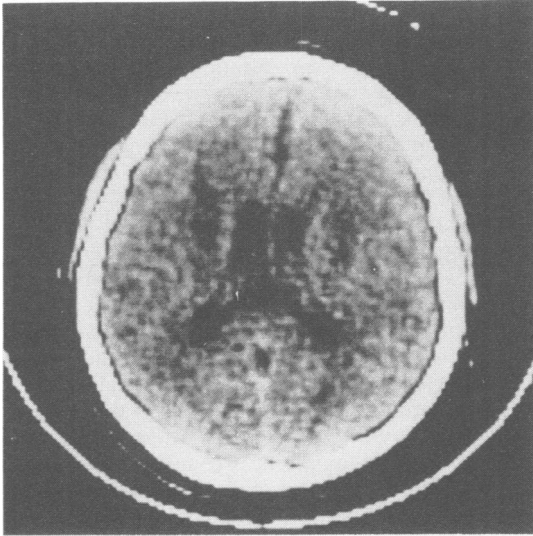


Fig 1 CT scan shows small low density lesions bilaterally in the region of corona radiata adjacent to the basal ganglia.

Case 4

This 80-year-old Caucasian lady presented with sudden dysarthria on waking in the morning. There was no history

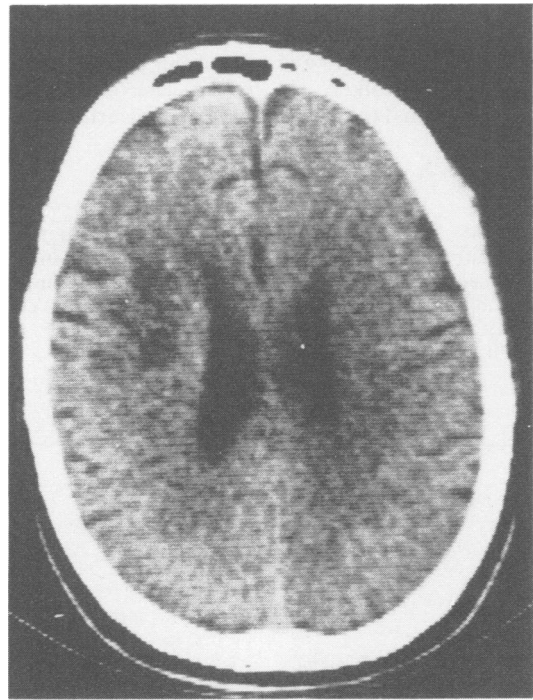


Fig 2 CT scan shows a small deep infarct in the region of the right corona radiata.

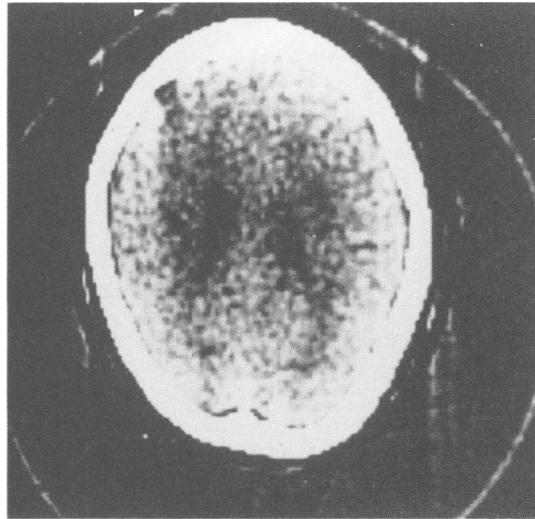


Fig 3 CT scan shows bilateral small infarction in the corona radiata anteriorly.

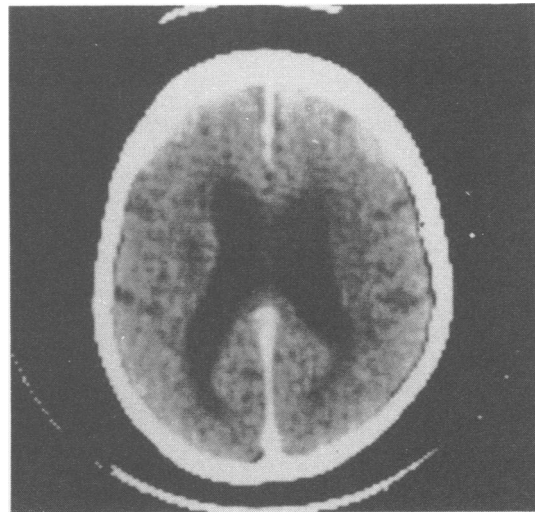


Fig 4 CT scan shows a small lacunar infarct in the left corona radiata region.

of hypertension, ischaemia, heart disease, diabetes, or cerebrovascular disease. On admission, the patient was normotensive, in sinus rhythm. On neurological examination, she had marked dysarthria, a mild right upper motor neuron facial palsy, and weakness in protrusion of the tongue to the right. There was no limb weakness, reflex abnormality or other abnormalities. Investigation showed haemoglobin 15.1 gm/100 ml, ESR 32 mm/h, random glucose 8.4 mmol/l, ECG showed a left anterior hemiblock, CT scan showed a small lacunar infarct in the left corona

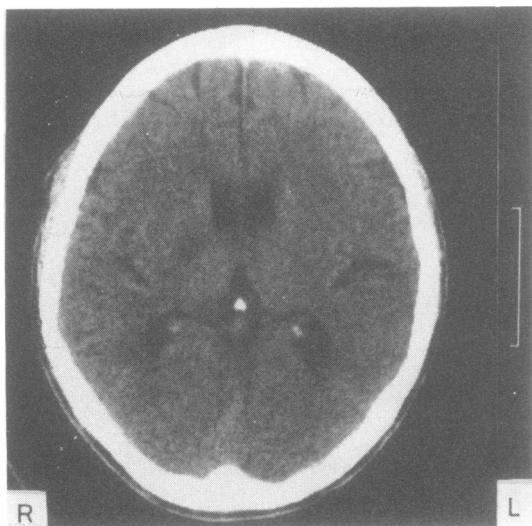


Fig 5 CT scan shows a small infarct in the posterior limb of the right internal capsule.

radiata region (fig 4). She rapidly lost her facial palsy and dysarthria.

Case 5

A 63-year-old male Chinese was admitted because of dysarthria. At the onset of symptoms he noted some transient left hand paraesthesiae and weakness. Nine months ago he had an episode of quadriparesis which recovered after 2–3 hours, for which he did not seek medical advice. Six months ago hypertension had been diagnosed but he did not continue treatment. He smoked 20 cigarettes a day for 30 years. On admission he was found to have blood pressure of 190/100 mm Hg, there was a mild dysarthria with a mild left facial palsy. No other neurological abnormality was noted. CT scan revealed a small infarct in the posterior limb of the right internal capsule (fig 5). The facial palsy resolved quickly. Nine months later however, he developed sudden expressive dysphasia with right hemiparesis.

Discussion

Since Fisher first called attention to the lacunar syndromes in the sixties with a series of papers, many lacunar syndromes have been established: pure motor hemiparesis, pure sensory stroke, dysarthria-clumsy hand syndrome, homolateral ataxia and crural paresis, hemichorea-hemiballismus.³

Our five cases were characterised by the presence of facial palsy alone or associated with dysarthria, dysphagia and reflex changes suggesting more diffuse corticospinal pathway involvement. However, there was no actual limb weakness. The CT scan were similar in showing small deep infarcts in the corona radiata regions in four and internal capsule in one. All the patients made a good recovery (table).

Our five cases and the five others previously reported by Puvenendren, Wong and Ransome (table) draw attention to a syndrome of sudden onset facio-bulbar weakness which may be confused with Bell's Palsy because of relative sparing of the limbs and good outcome. It appears that such lesions when bilateral may cause both facial palsy and selective pseudobulbar palsy with sparing of limbs. The corona radiata may be the preferential site of lesions in such cases, since the corticospinal projections are more separate and not as tightly packed together as in the internal capsule. Four of the patients were hypertensive, one diabetic and one of Puvenendren's cases had a previous stroke and four of our patients were smokers. It is likely, as in the case of lacunar syndromes, that the actual cause of the arterial lesion varies.

References

- ¹ May M, Hardin WB. Facial palsy: interpretation of neurologic findings. *Laryngoscope* 1978;**88**:1352–62.
- ² Puvenendren K, Wong PK, Ransome GA. Syndrome of Dejerine's Fourth Reich. *Acta Neurologica Scand* 1978;**58**:345–53.
- ³ Mohr JP. Lacunas. *Stroke* 1982;**13**:3–11.

Table 1 Clinical features of isolated UMN facial palsy syndrome

Puvenendren et al	Sex/Age	Risk factor	Presentation			
			Dysarthria	Dysphagia	Facial palsy	Others
Case 1	F/41	hypertension	+	+	left	—
2	F/60	diabetes	+	+	left	—
3	M/57	—	+	+	right	—
4	F/62	hypertension	+	+	bilateral	—
5	M/63	previous R hemiplegia	+	+	left	—
Present Series						
1	M/49	smoker	+	+	bilateral	veers to left
2	M/61	smoker hypertension	—	—	right	—
3	F/56	smoker	+	+	right	bilateral extensor plantar
4	F/80	—	+	—	right	—
5	M/63	smoker hypertension	+	—	left	transient LUL weakness