

## DELAYED DETERIORATION FOLLOWING MILD HEAD INJURY IN CHILDREN

by J. W. SNOEK<sup>1</sup>, J. M. MINDERHOUD<sup>1</sup> and J. T. WILMINK<sup>2</sup>

(From the Departments of Neurology<sup>1</sup> and Neuroradiology<sup>2</sup>, University Hospital,  
PO Box 30.001, 9700 RB Groningen, The Netherlands)

### SUMMARY

A series of 42 children is described who, following a seemingly minor or trivial head injury, developed neurological signs after a lucid or symptom-free period. This group constitutes 4.34 per cent of 967 consecutive patients aged 2 months to 17 years who were seen by members of the neurological staff during the years 1978-1981.

Only one patient had an intracranial haematoma. The majority of patients showed a benign transient syndrome consisting of either convulsive or nonconvulsive signs with a spontaneous and full recovery. There were, however, 3 deaths in this series, apparently due to severe and uncontrollable unilateral or diffuse brain swelling, demonstrating the malignant counterpart of this benign syndrome.

The theories seeking to explain these phenomena are reviewed. Special reference is made to the hypotheses of Bruce and his associates regarding brain swelling as a causative factor. It is considered that an adequate theory to explain the pathogenesis is still lacking.

It is concluded that the juvenile brain responds to cranial trauma in a manner different from the adult brain. This implies a different approach in policy to hospital admission.

### INTRODUCTION

It is a well established fact that children with head injuries who deteriorate following a lucid interval usually do not have an expanding intracranial haematoma, unlike adults where secondary deterioration following trauma is a strong indication that such a haematoma is present (Walton and Brooks, 1897; Pickles, 1949; Lindenberg *et al.*, 1955; Galbraith and Smith, 1976; James, 1979; Bruce *et al.*, 1979, 1981a).

Secondary deterioration not due to intracranial haematoma has been attributed to acute cerebral oedema (Pickles, 1949; Biemond, 1970), convulsions (Small and Woolf, 1957; Livingston and Mahludji, 1961; Grand, 1974; Reilly *et al.*, 1975; Rose *et al.*, 1977), spreading depression of Leão (Oka *et al.*, 1977), a migrainous mechanism (Haas *et al.*, 1975), a functional disturbance of the rostral brainstem (Todorow and Feller, 1982), concomitant viral meningoencephalitis (Peters *et al.*, 1978), complicating meningitis (Rose *et al.*, 1977) or to unknown causes (Plum and Posner, 1980), whereas recent reports deal with the syndrome of diffuse cerebral swelling, which is attributed to acute cerebral hyperaemia (Langfitt and Bruce, 1975; Bruce *et al.*, 1979, 1981a, b). The CT scans of children with this diffuse cerebral swelling show a diminution or obliteration of the cerebral ventricles and the

perimesencephalic cisterns, whereas the hyperaemia is related to increased CT attenuation numbers of the deep frontal white matter (Zimmerman *et al.*, 1978).

The present study was undertaken in order to investigate retrospectively the incidence of lucid or symptom-free periods in a consecutive series of head-injured children, to describe the different clinical pictures presented by these patients and to correlate the clinical findings with the results of both EEG and CT studies.

#### PATIENTS AND METHODS

The University Hospital of Groningen has approximately 1100 beds and serves a population of 400000 for primary referrals and 2 million for secondary referrals.

In 1972 a Head Injury Research Study was set up in collaboration with neurosurgical centres in Rotterdam, Glasgow and Los Angeles (Jennett *et al.*, 1977). All injured patients in whom a head injury is suspected are seen by staff of the Neurology Department at the Accident and Emergency Clinic and assessed in a uniform way, using the Glasgow Coma Scale (Teasdale and Jennett, 1974). In order to study the occurrence of lucid or symptom-free periods in children after head injury, the records of all head-injured children (aged 0 to 17 yrs), seen during the years 1978-1981, were reviewed. During this period a total of 967 patients in this age group were seen as primary referrals, that is, not having previously been admitted to another hospital. The neurological assessment usually took place within 1 or 2 h after the accident, in all cases within 24 h.

Patients were included in the present series if, after a head injury not causing unconsciousness or only a very brief period of unconsciousness (not exceeding 5 min), this symptom-free period was followed by a subsequent deterioration of the level of consciousness or by the onset of focal neurological signs, or both. The clinical findings of these patients were compared with the EEGs, skull radiographs and CT scans if available. Where appropriate, attenuation numbers expressed as EMI units of the deep frontal white matter were obtained as described by Zimmerman *et al.* (1978). These attenuation values were compared with those of an appropriate control group of children. Average CT attenuation numbers of the deep frontal white matter in a series of control scans, as will be described later in this paper, ranged from 11.7 EMI units (SD 2.08) to 19.5 EMI units (SD 2.42).

#### RESULTS

Fig. 1 shows the characteristics of the group of 967 consecutive juvenile patients. Of these, 5 were either dead on arrival or died within a few minutes afterwards. Fig. 2 shows the age distribution of the remaining 962 patients. These patients have been classified according to the Abbreviated Injury Scale (AIS; Ommaya, 1979), which is summarized in Table 1. Because post-traumatic amnesia is usually difficult to assess in children (especially in the younger ones), only the estimated period of unconsciousness has been taken into account.

As fig. 1 shows, 5 patients with linear skull fractures were not admitted, usually because the head injury had occurred more than 12 h previously. Of all admitted patients, 22 died (5.7 per cent), death being attributable to primarily extracranial lesions in 4 cases.

In a total of 40 children a history of a lucid or symptom-free period was found following a head injury which had caused no immediate loss of consciousness. This group of patients meets the criteria of a 'trivial injury' according to Jennett (1962, 1975) (no amnesia, haematoma or skull fracture, or linear fracture only). Two cases

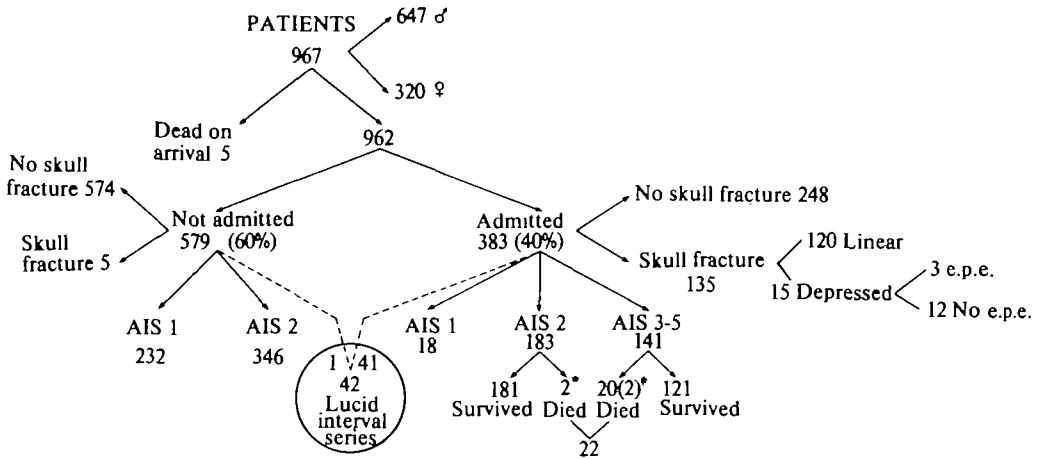


FIG. 1. Characteristics of the group of 967 consecutive patients, aged 2 months to 17 years. AIS = Abbreviated Injury Scale (see text). e.p.e. = early post-traumatic epilepsy. \* = death attributable primarily to extracranial injuries.

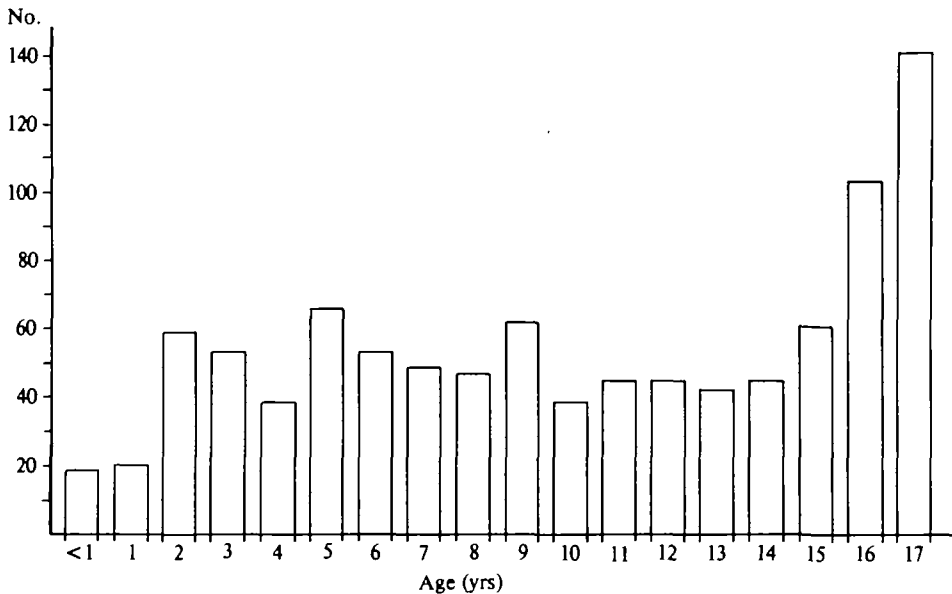


FIG. 2. Age distribution of 962 consecutive head-injured children, aged 2 months to 17 years.

TABLE 1. ABBREVIATED INJURY SCALE

<i>Description of injury</i>	<i>AIS code</i>	<i>Degree of injury</i>
Cerebral injury with headache; dizziness; no loss of consciousness.	1	Minor
Cerebral injury with or without skull fracture, with less than 15 min unconsciousness; undisplaced skull fracture; no post-traumatic amnesia.	2	Moderate
Cerebral injury with or without skull fracture, with unconsciousness more than 15 min, without severe neurological signs; brief PTA* (less than 3 h).	3	Severe (not life threatening)
Cerebral injury with or without skull fracture, with unconsciousness of more than 15 min with definite neurological signs; PTA 3-12 h. Compound skull fracture.	4	Severe (life threatening; survival probable)
Cerebral injury with or without skull fracture with unconsciousness of more than 24 h; PTA > 12 h; intracranial haemorrhage; signs of raised intracranial pressure.	5	Critical (survival uncertain)

\*PTA = post-traumatic amnesia.

with a history of a brief loss of consciousness (not exceeding 5 min) followed by a lucid period, were included, bringing the total number to 42 (4.37 per cent of all patients). Forty of the patients were admitted immediately after the first neurological assessment, 2 had been allowed to go home, one of whom was subsequently admitted on the same day. In one patient the (short) transient period of deterioration had occurred several hours previously and at the time of neurological examination this patient had no symptoms; he therefore was allowed to go home. Fig. 3 shows the age distribution of the 42 patients. The patients were divided into two categories (fig. 4), the criterion being the occurrence or absence of convulsions (Oka *et al.*, 1977).

#### *Group 1. Convulsive Cases*

Thirteen children (31 per cent) had early post-traumatic seizures, occurring in the first week after injury (Jennett, 1962, 1969, 1975). Table 2 presents the characteristics of this group. Seven patients developed a focal or generalized status epilepticus, which necessitated intubation and controlled ventilation in 6. More than half of the patients developed these seizures within one hour after injury, 12 out of 13 within two hours, and only one after a longer period (28 h).

*Case 1.* A 5-year-old-boy fell off his bicycle. He did not lose consciousness and resumed cycling immediately. One hour after injury he developed focal seizures involving the right hand and arm. On admission one hour later, the boy was in generalized status epilepticus, which reacted promptly to intravenous diazepam. A CT scan performed within three hours after injury showed no abnormalities. The mean CT attenuation numbers of the deep frontal white matter were 15.9 EMI units (SD 2.59).

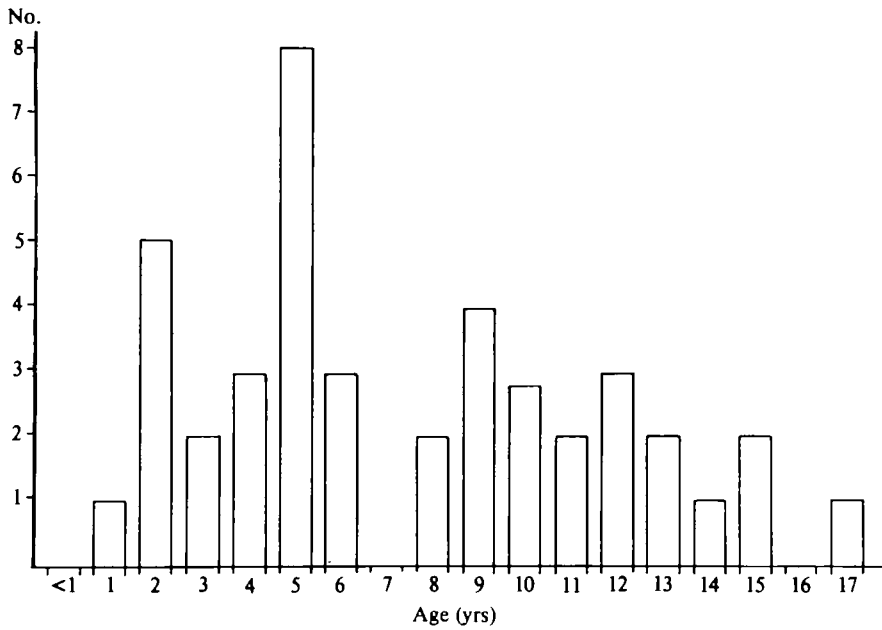


FIG. 3. Age distribution of 42 children with a lucid interval following mild head injury.

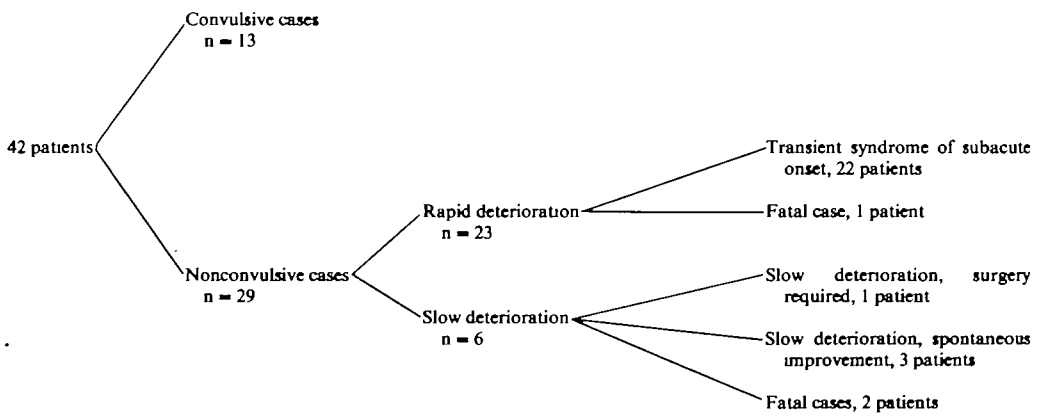


FIG. 4. Lucid interval series. Clinical course.



convulsions after a previous trivial injury). One patient possibly had a rubella infection and was readmitted with a second episode of status epilepticus a week later at which time an increased rubella titre was found. Apart from this patient no recurrence of seizures was noted in the follow-up period (six months to three years).

One or more EEGs were performed in 11 cases, usually within 24 h after injury (range 6 h to 9 days). Table 3 shows that there was no relation between the EEG findings and the type of seizure.

In only 2 patients was CT performed immediately following the convulsions. Both were normal. The densities measured in the deep frontal white matter were 15.9 EMI units, SD 2.59 (Case 1) and 11.3 EMI units, SD 1.60, respectively.

### *Group 2. Nonconvulsive Cases*

These 29 children did not develop early post-traumatic seizures. In the majority (23 cases), there was a history of acute or subacute deterioration (i.e. from a level of no signs, the full clinical picture was reached within 15 min) at varying times after injury, whereas in the remaining 6 cases there was a slow, gradual deterioration.

*Cases with rapid deterioration. A. Patients with a transient syndrome of acute or subacute onset.* Patients were included in this group if the following criteria were met. (1) Acute or subacute onset. (2) Signs ending quickly, sometimes abruptly, mostly after a short period (not exceeding 12 h). (3) Nature of signs: loss of consciousness with or without focal neurological signs, focal neurological signs only or a period of severe restlessness or confusion following a period of normal behaviour.

This subgroup consists of 22 patients whose characteristics are listed in Table 4.

TABLE 4. CHARACTERISTICS OF NONCONVULSIVE CASES WITH A TRANSIENT SYNDROME OF ACUTE OR SUBACUTE ONSET

<i>Number:</i>	22
<i>Mean age:</i>	6 years (range 2-13)
<i>Cause of injury:</i>	fall, 15 traffic accident, 5 struck by object, 2
<i>Skull fracture:</i>	5 (23 per cent)
<i>Onset after injury:</i>	5-30 min, 12 30-60 min, 4 1-2 h, 5 36 h, 1
<i>Duration of signs:</i>	15-30 min, 5 30 min-2 h, 2 2-12 h, 15
<i>Vomiting at onset:</i>	21 (95 per cent)
<i>Signs:</i>	disturbances of sensory level only, 7 disturbances of sensory level with focal neurological signs, 9 focal neurological signs only, 1 confusion, 5

The past medical history was unremarkable in all but 3 cases. One girl (aged 12 years) was known to have behavioural problems and EEG abnormalities (bilateral synchronous spike and wave complexes) without history of seizures. One boy (aged 5 years) had had febrile convulsions in the past. There was a family history of epilepsy but no history of seizures in another boy (aged 6 years), whose EEG subsequently showed spike and wave complexes. One patient was admitted with fever, the CSF showing no abnormalities.

There were remarkable differences in the severity of the presenting clinical picture as is illustrated by the following case histories.

*Case 2.* A 2-year-old boy fell down some stairs. He cried immediately. One hour later he became unresponsive within a few minutes. On admission he was obtunded with a left hemiparesis. A CT scan, performed within three hours of injury, was normal, with frontal white matter attenuation values of 11.7 EMI units, SD 1.57. Within four hours after the injury the hemiparesis disappeared and the level of consciousness became normal. Two days later the boy was discharged. An EEG, performed on the same day, showed slow waves over the whole of the right hemisphere.

*Case 3.* A 5-year-old boy was struck by a car. He was unconscious for less than five minutes. In the ambulance the right pupil dilated while he was talking. He subsequently became comatose with bilaterally dilated unreactive pupils. On admission, one hour after the accident, he was awake with normally reacting pupils. The EEG (day 5) showed only slight diffuse abnormalities. He was discharged after six days.

A similar short-lasting but alarming picture, consisting of deep coma with bilaterally unreactive pupils, resembling acute tentorial herniation by a rapidly expanding mass, was seen in one other patient in this group, a girl aged 12 years. In this patient these signs occurred 36 h after injury. The CT scan performed at that time showed small ventricles with obliterated cisterns (fig. 5). The deep frontal white matter densities were 17.4 EMI units, SD 2.47.

The most frequently observed focal neurological signs were pupillary abnormalities (in 4 out of 10 patients), followed by conjugate eye deviation and hemiparesis. A combination of focal signs was seen in 2 children. Two patients presented with transient blindness. In both patients the onset of blindness (some minutes and one hour after injury, respectively) occurred in combination with sudden vomiting. The period of blindness lasted less than one hour in both cases and ended abruptly. One child had struck his forehead, the other had fallen on his occiput.

In this group of patients, 6 EEGs were performed within one to five days after injury. Three of these showed local slow activity, 1 slight diffuse abnormalities, whereas bilateral synchronous sharp and slow wave complexes were noted in 2. A CT scan was performed in only 2 cases (*presented above*).

**B. Fatal case with a rapid deterioration.** *Case 4.* An 8-year-old boy jumped from a slowly moving cart and fell on his head. He got up immediately, walked towards his father and said 'I feel so funny in my head'. He then became flaccid. His mother, a nurse, subsequently stated that she had noticed dilated pupils at the time. On admission one hour later the boy was shocked and respiration was shallow. He was unresponsive and both pupils were dilated and fixed. No bruises were found on the head and there was no skull fracture. Echoencephalography showed no midline shift. The boy was



intubated and ventilated. Soon after admission massive pulmonary oedema developed. It was felt that the situation was hopeless and no attempts were made at further investigation. He died within hours of admission. Permission for donor nephrectomy was granted by his parents; no attempts were made to obtain permission for autopsy.

*Slow deterioration. A. Slow deterioration, treated surgically. Case 5.* A 10-year-old boy struck his head against a wall while being tossed by his friends. He was briefly unconscious, probably less than one minute, but recovered quickly. On admission he opened his eyes on request, obeyed commands and was fully orientated. There was a small occipital fracture. He deteriorated slowly over the following day. Laboratory screening revealed a clotting disorder, which was found to be a variant of von Willebrand-Jürgens disease. A CT scan showed a hyperdense area in the posterior fossa, which on exploration proved to be an extradural haematoma. He made a slow but excellent recovery.

*B. Slow deterioration with gradual spontaneous improvement.* In 3 patients (aged 10, 12 and 15 years, respectively) the signs developed slowly over a period of time after a lucid interval and then gradually resolved. In 2 patients these symptoms consisted of slowly progressive confusion with focal abnormalities in both the EEG and CT scan, located in the frontal region in one patient and in the left temporal region in the other. In the third case (Case 6) the deterioration consisted of more severe confusion, with signs of uncal herniation.

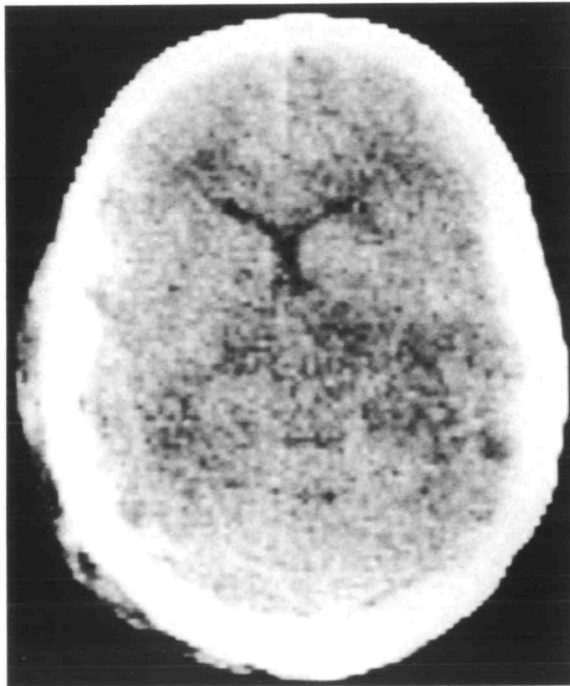


FIG. 5. Example of CT section at the level of the anterior horns and the mesencephalon. Note the narrow aspect of the ventricular horns which are not significantly displaced from the midline. The CSF cistern behind the quadrigeminal plate is obliterated.

*Case 6.* A boy aged 12 years was hit by a car. He did not lose consciousness. On admission he was lucid but nauseated. There was no skull fracture. Twelve hours after the accident he started to deteriorate with confusion and an enlarged pupil on the right. Angiography (because of unavailability of our CT scanner) showed a shift of the midline vessels with signs of a swollen right temporal lobe. No avascular mass was discovered. Several hours later his level of consciousness started to improve and the pupils became normal. The boy remained drowsy for two more days after which he recovered quickly. An EEG performed four days after injury showed diffuse slowing together with a local area of slow activity in the right temporal region.

*C. Fatal cases with slow deterioration. Case 7.* A 13-year-old girl fell off her bicycle. She did not lose consciousness at the time. On examination, three hours after the accident, she was lucid but nauseated. No neurological abnormalities were found. There was no skull fracture. She was sent home. Several hours later she developed a left hemiparesis and became drowsy. She was admitted to our hospital. A CT scan showed a marked shift of the compressed ventricles to the left. No abnormalities in the brain parenchyma were detected. Unfortunately raw CT data are no longer available, so no frontal white matter attenuation values can be measured in retrospect. An angiogram, performed in order to exclude an isodense haematoma, showed slowed intracerebral circulation, but no avascular mass. The girl was intubated and ventilated; high doses of corticosteroids were given, together with mannitol. She deteriorated over the next few hours and died on the following day. Autopsy was not performed.

*Case 8.* A boy aged 9 years fell off his skateboard. He resumed playing immediately, not having lost consciousness. Later that day he watched television for several hours and then went to bed. The next morning he complained of a headache and told his mother that he had difficulty in walking. Some time later he became stuporose and vomited. On admission, 16 hours after the accident, he did not open his eyes to painful stimuli, but he located these adequately while moaning. A bruise was noted in the right parietal area. There was no skull fracture. The left pupil was dilated, the right pupil somewhat smaller; neither reacted to light. While the patient was being examined both pupils started to react to light spontaneously. As the CT scanner was not available, an angiogram had been scheduled. It was felt, however, that the spontaneous improvement made an expanding intracranial mass less likely. Without having further deteriorated in the meantime, the boy suddenly developed fixed dilated pupils and apnoea. He was immediately taken to the operating theatre where bilateral burr holes revealed a swollen brain but no haematoma. The boy died 15 hours after admission. Consent for autopsy was refused.

## DISCUSSION

The largest series of head-injured children, 4465 consecutively admitted cases, was reported by Hendrick *et al.* (1964). It was shown that almost 50 per cent of those who died were not in coma at the time of admission to hospital. Also, a history of a short or prolonged lucid period was present in 0.8 per cent of the patients, whereas the level of consciousness deteriorated gradually from the moment of impact in 1.8 per cent. Only the last category was correlated with a high percentage of intracranial, mostly extradural, haematomas.

In this study we assessed children who, following a minor or trivial injury, developed neurological signs following a lucid or symptom-free period. As these included cases with focal neurological signs in conscious children and early post-traumatic convulsions not leading to coma, it is not possible, strictly speaking, to use the term 'lucid interval', which refers to level of consciousness only, in these cases.

Therefore the criterion 'symptom-free' has been added. It does not seem illogical to use these criteria because in this way it is possible to focus attention on all those patients who demonstrated disturbed cerebral function after an injury which at first had appeared to be minor or even trivial.

In 4.37 per cent of 962 patients such a symptom-free period was encountered. In only one of these patients was an intracranial haematoma subsequently found. The remaining 41 patients showed a syndrome consisting of either convulsive or nonconvulsive signs.

### *Post-traumatic Epilepsy*

Early post-traumatic epilepsy was noted in 16 head-injured children (1.6 per cent of our total series of 962). The 3 patients not having had a lucid interval all had a depressed fracture (fig. 1). According to Jennett (1962, 1973, 1975), early post-traumatic epilepsy is seen in about 5 per cent of all head-injured patients admitted to hospital. In children under 5 years of age, however, the incidence is twice as high. Hendrick and Harris (1968) also give an incidence of about 10 per cent in this age group. In patients under 5 years of age we found a percentage of 3.2 per cent. The difference between the incidence found by Jennett and by Hendrick and Harris, and by us, probably reflects the distinction between patient populations in neurosurgical and neurological departments.

According to Jennett, epilepsy rarely follows a trivial injury except in children under 5 years. The only adults encountered with epilepsy after trivial injury are those with 'immediate' epilepsy, when a seizure occurs at the moment the head sustains an impact. In the present series, the occurrence of early post-traumatic epilepsy was not limited to the under 5 age group, as 6 of the 13 patients were between 6 and 17 years of age. A similar age distribution has been described by Grand (1974).

Two explanations are possible for the relatively high frequency of early post-traumatic epilepsy following trauma in children as compared to adults (Jennett, 1962, 1975). The first is that children are predisposed to epilepsy, related to underlying but hitherto undetected brain damage. The second, favoured by Jennett and by Oka *et al.* (1977), is that children are somehow more liable to react to stress of different kinds by a seizure. Our finding that in almost half of the convulsive cases there was, albeit ill defined, a past medical history (*see* Table 2), which may have resulted in a liability to develop convulsions, gives some support to the first possibility expressed by Jennett. According to this author, the major significance of early post-traumatic epilepsy is the risk of late epilepsy, which he found to be 25 per cent. Focal early epilepsy in children was the only kind of early epilepsy in his series which did not significantly increase the risk of late epilepsy. Except for the child that was readmitted in a second episode of status epilepticus one week after the accident, no other cases of late epilepsy were encountered during the follow-up (three months to three years) of our patients with early epilepsy following trivial injury (Table 2). Oka *et al.* (1977) did not find a single case of late epilepsy in their series.

In the literature several explanations have been offered for the delayed deterioration in children following minor injuries. Several authors considered both convulsive and nonconvulsive signs as part of one syndrome and have attempted to give an explanation for its occurrence (Biemond, 1970; Haas *et al.*, 1975; Oka *et al.*, 1977); others have confined themselves to giving an explanation for the occurrence of convulsions only (Livingston and Mahloudji, 1961) or of nonconvulsive signs only (Walton and Brooks, 1897; Pickles, 1949; Gjerris and Mellemegaard, 1969; Bruce *et al.*, 1979, 1981*a, b*; Todorow and Feller, 1982).

### *Spreading Depression of Leão*

By dividing our patients into two groups, convulsive and nonconvulsive cases, we follow Oka *et al.* (1977). They described a series of 37 children in whom transient neurological disorders occurred in the acute stage of trivial head injury and for whom no surgical treatment was subsequently required. The ages of their patients ranged from 10 months to 21 years, but the majority were under 14 years of age. Of these 37 children, 28 developed convulsive attacks and 9 children demonstrated nonconvulsive signs following a head injury without initial loss of consciousness. As in our series, most of the convulsive patients were under 8 years of age. Our group of patients with a transient syndrome of subacute or acute onset (Table 4) shows the greatest resemblance to their group of nonconvulsive cases, although our patients tended to be younger. They considered the nonconvulsive signs to be the primary and basic disturbance and they regarded the convulsive attacks as secondary phenomena. According to these authors, both phenomena can be explained as manifestations of the experimental phenomenon designated as spreading depression of Leão. In rabbits, Leão (1944) found that weak faradic or mechanical stimulation of the exposed cerebral cortex elicits a characteristic response, consisting of a marked enduring reduction of the spontaneous electrical activity of the cortex. Typical discharges of experimental epilepsy were noted in cortical regions when these were reached by a spreading wave of depression. Oka *et al.* suggested that the fact that the nonconvulsive disturbance was followed by convulsions in the younger children could be ascribed to a maturational factor, but that the primary process, the spreading depression, was identical in both groups. Thus, according to these authors, only the age factor determines whether the syndrome of transient neurological disorders, which include headache, nausea and vomiting, pallor, somnolence, irritability and restlessness, stupor, hemiparesis and aphasia, is followed by convulsive attacks. We noted some differences between our convulsive and nonconvulsive patients, however, which may indicate that the two phenomena are not as closely linked as these authors suggest. First there was, as stated earlier, a past medical history in almost half of the convulsive patients, which may have resulted in a liability to develop convulsions. Secondly, although a nonspecific sign such as vomiting was noted at the onset of the deterioration of almost all patients in the nonconvulsive group (Table 4), this sign was only rarely seen in patients with early post-traumatic convulsions (Table 2). We were unable to confirm the finding

of Oka *et al.* (1977) that the convulsive attacks did not develop directly from a lucid interval, but were nearly always preceded by nonconvulsive signs to a greater or lesser degree.

#### *A Migrainous Mechanism*

Haas *et al.* (1975), in a study of 25 patients, described 50 attacks consisting of transient neurological signs following mild head trauma; 40 of the attacks occurred in children under 14 years of age. All attacks developed after a latent interval, generally of one to ten minutes. Attacks were grouped into 4 clinical types: (1) hemiparesis; (2) somnolence, irritability and vomiting; (3) blindness and (4) brainstem signs. Two patients had an epileptic seizure. Five of the children later had spontaneous attacks which resembled their triggered attacks closely enough to be considered the same experience. The authors concluded that the temporary post-traumatic syndromes mentioned by them can be seen as diverse manifestations of a common underlying process which involves the cerebral vasculature, and that they resemble spontaneous classical migraine attacks in juveniles closely enough to postulate an underlying mechanism similar to migraine. Several authors (*see* Oka *et al.*, 1977; Shinohara *et al.*, 1979) regard this mechanism as analogous or identical with the mechanism underlying migraine.

#### *A Functional Disturbance of the Rostral Brainstem*

Todorow and Feller (1982) have recently described 49 children with mild post-traumatic stupor. This 'sleepy state', which lasted for 3 to 5 h, occurred in 9 per cent of all children admitted after a minor head injury. The lucid interval ranged from 15 min to 3 h. In almost one-third of the patients minor neurological signs were noted (pupillary abnormalities, pyramidal tract signs or ataxia), while EEG abnormalities were found in more than half. These EEG abnormalities mostly consisted of slight to moderate slowing of background frequency and, in many cases, persisted for a considerable time (from 5 days to 6 weeks) after the clinical signs had subsided. The authors postulate that both the secondary disturbance of consciousness and the EEG abnormalities can be explained by a functional disturbance of the rostral brain stem, probably related to the lability of arousal mechanisms in children.

In our series we have not regarded sleepiness in itself as a sign of secondary deterioration. Many children will fall asleep some time after the shock of an injury and the subsequent examination and treatment in an unfamiliar hospital setting. We cannot exclude the possibility, however, that the children in the Todorow and Feller series who became somnolent without developing focal neurological signs may represent the mildest form of the 'delayed deterioration syndrome'.

#### *Direct Contusion of the Cerebral Cortex*

Livingston and Mahludji (1961) reported 4 patients between 2 and 4 years of age who developed convulsive seizures after a latent interval following mild head injury. They postulated that, since this picture has only been seen in young children at an

age when the cranium is rather malleable, deformation of the cranium at the moment of impact produces direct contusion of the cortex.

*Focal or Generalized Brain Swelling, Due either to Rapid Oedema Formation or to Cerebral Hyperaemia*

For almost a century there have been reports of clinical findings in head-injured children and adolescents strongly suggesting the presence of a rapidly expanding intracranial haematoma, but with these findings apparently being due to some other condition. The first case reports were published by Walton (1898) and Walton and Brooks (1897).

Pickles (1949) concluded that transient acute cortical oedema, with associated capillary anaemia, best explained the rapid and complete recovery without operation. Biemond (1970) also considered rapid oedema formation to be the cause of the transient cortical dysfunction accompanied by loss of consciousness. He differentiated between the more common benign transient syndrome and the rare fatal cases, which he saw only three times during his long career. These three children died after an exploratory craniotomy yielding negative results. Post-mortem examination showed diffuse cerebral swelling with microscopic findings of hyperaemia in the smaller arteries and precapillaries. He concluded that there was evidence both of brain swelling and brain oedema and he considered the brain swelling to be the primary event, probably attributable to diencephalic lesions.

Lindenberg *et al.* (1955) described the post-mortem findings of children dying from blunt head injuries. Diffuse cerebral swelling was the most consistent finding. They concluded that this post-traumatic brain swelling is markedly more common in children than in adults and that it may develop after a seemingly minor head trauma without subsequent loss of consciousness. Similar findings have been recorded by other pathologists (Adams and Graham, 1972; Adams, 1975), who also reported that they could not find distinct abnormalities on histological examination.

Until recently, post-traumatic brain swelling has always been attributed to brain oedema, but the crucial evidence for this cause is lacking. According to Miller and Corales (1981), direct measurements of water content of the brain have not been reported in patients with head injury. The concept of brain oedema causing diffuse cerebral swelling has now been replaced by the alternative explanation of increased cerebral blood volume. Bruce *et al.* (1979, 1981*a, b*) and Zimmerman *et al.* (1978) described the CT appearance of diffuse cerebral swelling, which they considered to be the commonest CT finding in head-injured children. This CT picture consists of obliteration or narrowing of the lateral and third ventricles and perimesencephalic cisterns, while cerebral attenuation values are higher than on follow-up scans. According to these authors, these attenuation numbers (measured in the deep frontal white matter) are also higher than the normal range defined from values measured in normal paediatric CT scans and certainly higher than would be expected if brain oedema were the cause of this cerebral swelling, as an increase in water content of the brain is linearly related to a decrease in attenuation numbers.

The finding of increased cerebral blood flow (CBF) in the patients who showed this CT pattern of diffuse cerebral swelling is taken to suggest a relationship between the increased attenuation at CT, and this increased CBF and the cerebral swelling is therefore ascribed to cerebral hyperaemia. The association of diffuse cerebral swelling and hyperaemia has also been reported by Obrist *et al.* (1979) from the same institution. Cerebral metabolism studies in their hyperaemic patients yielded a very low oxygen uptake and arteriovenous oxygen difference, indicating that the high blood flow is a true 'luxury perfusion'. The cause of the cerebral vasodilatation, which allegedly leads to cerebral swelling, is as yet unknown. Meyer *et al.* (1971) found in their animal model that the areas which caused increases in CBF when stimulated were located in the pontine and midbrain reticular formation, the thalamus and the hypothalamus. Raichle *et al.* (1978) assumed that locus coeruleus stimulation may change both CBF and cerebral capillary permeability, probably through central vascular aminergic pathways. Recently, Mies *et al.* (1981), using autoradiographic techniques, observed an increase in cerebral blood flow during spreading depression in animals. This finding thus appears to link the theories of Bruce *et al.* (1979, 1981a, b) with those of Oka *et al.* (1977). The increase in CBF found by Mies *et al.* (1981), however, was linked with increased metabolism, which means that apparently the increase in CBF during spreading depression cannot be interpreted as 'luxury perfusion'.

There are some unresolved problems relating both to the CT appearance of diffuse cerebral swelling and to the theory ascribing this swelling to vascular engorgement. Until clearly defined criteria for minimal ventricular size in normal children are set, caution is needed in interpreting the sign of 'small ventricles' (Snoek *et al.*, 1979). The perimesencephalic cisterns are normally quite evident in children, but the same caution is needed in attaching any value to an alleged 'compression or narrowing'; in our opinion only clear absence of these cisterns on the CT scan warrants a conclusion of cerebral swelling.

The unresolved problems in the theory ascribing the CT picture of diffuse cerebral swelling to vascular engorgement are threefold. The first is the reliability of cerebral attenuation coefficients determined by CT. We feel that relatively small changes in CT attenuation numbers, as described by Zimmerman *et al.* (1978), should be interpreted with circumspection. We have attempted to reproduce the normal range of values established by these authors (14.6 to 16.6 EMI units in the deep frontal white matter of 18 normal hemispheres). We determined average attenuation numbers in the same fashion in circular fields of 150 to 350 pixels each in the deep frontal white matter of 6 hemispheres of children aged 1 to 12 years, in whom no signs of cerebral swelling could be found at CT. All the examinations had been performed on the same scanner (EMI 5005) using a 160 × 160 matrix, 10 or 13 mm slice thickness. In some subjects a scan time of 70 s per slice was selected, in others 20 s. The same variable scanning parameters were used in the other subjects whose CT characteristics are mentioned elsewhere in this study. In our 6 subjects white matter CT attenuation numbers ranged from a maximum average of 19.5 EMI units

per measuring field (SD 2.42) to a minimum of 11.7 EMI units (SD 2.08). This is a much larger spread of normal values than is presented in the material of Zimmerman *et al.* (1978).

A number of factors may influence the assessment of tissue attenuation coefficients as expressed in CT numbers.

(1) *Scanner characteristics.* These vary from one manufacturer to another with regard to acquisition of data (scanner generation, presence or absence of a water bag), as well as the method of reconstruction. Extreme caution must be exercised in any comparison of different types of scanners often functioning under dissimilar operating conditions (Speller *et al.*, 1981). With regard to a single CT scanner, consistency of performance may be influenced by the state of maintenance (McCullough, 1977). The EMI 5005 whole body scanner mentioned in our study is serviced by contract with the manufacturer. It is also interesting to note that, as the linear attenuation coefficient of water decreases with increasing temperature, there is a difference in CT attenuation numbers of 2.5 to 3.0 EMI units between water at room temperature and water at body temperature. This should be taken into account in calibration of the scanner (Bydder and Kreel, 1979). Factors such as voxel size (determined by slice thickness and area represented by a pixel) may be expected to influence the statistical accuracy of the attenuation measurement. It is also our experience that in the EMI 5005 scanner CT attenuation numbers determined in a 20 s rapid scan are usually significantly higher than in a 70 s slow scan performed in the same region. We have no explanation for this discrepancy. Finally, changes in position of the head within the scanner ring can cause variations in CT numbers measured in the same cerebral region in serial examinations, as can changes in kilovoltage between examinations (Levi *et al.*, 1982).

(2) *Factors related to the patient.* The most important of these appears to be skull thickness. As the x-ray beam traverses tissue, its composition is altered. The lower-energy photons are filtered out, and while the x-ray beam as a whole is attenuated, the mean kinetic energy of the remaining photons is higher. This beam-hardening effect is especially marked in substances with a high linear attenuation coefficient such as bone, and when a large thickness of skull has to be traversed, this will influence attenuation measurement of skull contents (Di Chiro *et al.*, 1978). Shifts of some 7.5 EMI units have been noted between maximum and minimum skull thickness (Payne and Latchaw, 1978).

(3) *Partial volume effect.* Cerebral grey matter has a mean attenuation number some 3 EMI units higher than white matter (Weinstein *et al.*, 1977; Phelps *et al.*, 1975). If the field of measurement located in the frontal white matter should inadvertently contain grey matter, this will induce an upward bias in the mean CT attenuation value through a partial volume effect. This could happen if the field of measurement were located too near to the cerebral surface in the CT section, but also if a CT section were selected for measurement which contains in its basal portion some of the frontobasal grey matter.

The minor increase in CT attenuation number of 1.6 EMI units described by



Zimmerman *et al.* (1978) in their group of patients with post-traumatic brain swelling achieves statistical significance when serial measurements are performed in the same patient using the same CT scanner under identical operating conditions. We would like to warn, however, against attributing diagnostic significance to marginal variations in mean CT attenuation numbers measured in the first CT examination in an individual patient.

The second unresolved problem in relating the CT picture of diffuse cerebral swelling to hyperaemia is as follows. Although the increase of 1.6 EMI units in ET attenuation numbers mentioned above is relatively small in the context of other variable factors influencing the measurements, it represents a large shift if it is to be explained solely on the basis of increase in blood content. The blood concentration of cerebral white matter is reported to be 2.2 per cent and of grey matter 5.6 per cent (Ladurner, 1978). The CT number for blood is given as 27 EMI units (New and Scott, 1975), and for subfrontal white matter as 16.5 EMI units (Arimitsu *et al.*, 1977). In order to cause an increase of the value for white matter in the order of 1.6 EMI units, its blood content would have to increase very substantially. By the same token doubling the cerebral blood volume would result in an increase in total cerebral volume of only 3.5 per cent, and an increase of this amount of blood volume is hardly ever seen (Raichle, 1979).

The third unresolved problem is that the crucial measurement is cerebral blood *volume* rather than cerebral blood *flow*, as measured by Bruce *et al.* (Miller and Corales, 1981). Determination of cerebral blood volume (CBV) by emission tomography in 4 head-injured children belonging to the series of Bruce *et al.* (1981a) failed to demonstrate an increase in CBV in 3 of them (Kuhl *et al.*, 1980). These authors state that the CT pattern characteristic of diffuse brain swelling may occur in head-injured children without discernible increases in CBV and that this picture therefore cannot be explained by increases in CBV alone.

The clinical significance of the finding of a CT appearance suggesting diffuse cerebral swelling caused by cerebral hyperaemia is as yet unresolved. The crucial question is whether such a swelling (leading to severely increased intracranial pressure only in exceptional cases) is the *cause* of the deterioration in head-injured children or whether in most patients it is an epiphenomenon caused by the same processes which lead to the clinical deterioration. Cold and Jensen (1980) found that hyperaemia following head injury is a common phenomenon in children, that this hyperaemic phase lasts for some days to several weeks and that it is of no prognostic importance. The CT pattern of diffuse cerebral swelling is seen in 29 per cent of head-injured children and adolescents. There is a higher incidence in patients with a low score on the Glasgow Coma Score (41 per cent with a score of 8 or less) than in patients with a score greater than 8 (15 per cent) (Bruce *et al.*, 1981a). These authors do not specifically mention the rate of occurrence of this CT pattern in children with a lucid interval. Conversely, in the clinical description of their group of 63 juvenile patients with the CT pattern of diffuse cerebral swelling, 37 per cent had experienced some form of lucid interval. Within the latter group two subgroups are described. In

a typical case of the first subgroup (8 cases) there was a lucid interval with a period of talking and complete consciousness from minutes to hours after injury, followed by the onset of vomiting, headache and frequently pallor and sweating, associated with decreased alertness. These patients exhibited evidence of decreased spontaneous motor activity, and loss of spontaneous speech and eye opening. No mention is made of focal neurological signs. None of these patients progressed to coma according to the criteria of Teasdale and Jennett (1974) and the intracranial pressure when measured in these patients remained normal. All these patients made a good recovery. The other subgroup consisted of 15 patients who were unconscious following trauma and then had an interval associated with recovery of eye opening, occasional words and more spontaneous motor function. This was followed by rapid deterioration leading to coma (Glasgow Coma Score of less than 8). One of these patients died as a result of delayed brain swelling. The others all made a good recovery. The patients of our series are by definition only comparable with their first group of patients. As most of our patients showed a benign, often shortlasting syndrome, few CT scans were made. In only one out of 4 scans, performed in children with a rapid deterioration consisting of either convulsive or nonconvulsive signs, was the typical CT appearance consistent with diffuse cerebral swelling seen (fig. 5), which leads us to the conclusion that in the majority of cases deterioration apparently is not associated with such cerebral swelling and that, therefore, there must be other explanations for this rapid deterioration.

The CT scan of Case 7, a girl with a slow deterioration, was consistent with swelling of one hemisphere, a finding which has been described in CT scans performed in the period immediately after injury (Kobrine *et al.*, 1977; Waga *et al.*, 1979). In both cases this swelling was, on the basis of attenuation measurements, also attributed to vasodilatation and not to oedema. The results of the angiogram in our Case 6, also a child with a slow deterioration, support the interpretation that local damage can be followed by local swelling, associated with clinical deterioration. The clinical course, radiological and (in one case) surgical findings in our fatal cases, although not confirmed by autopsy, strongly suggest that 'malignant brain swelling' following trivial head injury in children does exist. Excluding the rare occurrence of intracranial haematoma, we feel, however, that the syndrome of delayed deterioration following mild head injury in children in fact covers a variety of pathological states and that neither the clinical nor the CT findings support the view that brain swelling caused by cerebral hyperaemia is the only or even the usual underlying cause for such deterioration.

We conclude that trivial injuries in children are not infrequently followed by a deterioration which is preceded by a lucid or symptom-free period and which is usually transient. It is very likely that only in a minority of affected children signs of such severity occur that these children will come under medical care. On clinical grounds it is possible to differentiate between several distinct pictures. At this moment it can only be speculated whether or not the different clinical pictures presented by these patients reflect different pathophysiological entities. With the

exclusion of the relatively rare extracerebral haematoma, these clinical pictures point either to focal or generalized cerebral dysfunction, both with and without seizures. Although the recent theories developed by Bruce *et al.* relate the occurrence of cerebral dysfunction with diffuse cerebral swelling to hyperaemia, insufficient data are available so far to discriminate between this swelling being a causative factor for the deterioration or just an epiphenomenon in the majority of cases. We feel that caution is needed in interpreting the findings of marginally increased attenuation values in CT scans with small ventricles and compressed perimesencephalic cisterns as a state of diffuse cerebral hyperaemia and also in basing a therapeutic regimen solely on this interpretation. The rarity of this CT pattern in our patients does not give support to the assumption that in the majority of children diffuse cerebral swelling was the cause of the transient deterioration. There is now some evidence, however, that for unknown reasons some patients develop severe and often uncontrollable unilateral or diffuse brain swelling, as indicated by the radiological and surgical evidence in 2 out of our 3 fatal cases.

The fact that not infrequently deterioration following a trivial head injury may occur in children makes it mandatory in our opinion to accept a rather strict admission policy for head-injured children, especially if there is an indication in the past medical history that cerebral damage has been suffered in earlier life. In a deteriorating head-injured child that was symptomless before, the possibility of an expanding intracranial mass will always have to be excluded, preferably by CT scanning, although few haematomas will be found. The remaining patients usually show a benign and shortlasting syndrome followed by a spontaneous and full recovery in most, but not in all cases.

#### REFERENCES

- ADAMS J H (1975) Neuropathology of head injuries. In: *Handbook of Clinical Neurology*. Edited by P. J. Vinken and G. W. Bruyn. Amsterdam: North Holland, Volume 23, pp. 35-65.
- ADAMS J H, GRAHAM D I (1972) The pathology of blunt head injuries. In: *Scientific Foundations of Neurology*. Edited by M. Critchley, J. L. O'Leary and B. Jennett. London: Heinemann, pp. 478-491.
- ARIMITSU T, DI CHIRO G, BROOKS R A, SMITH P B (1977) White-gray matter differentiation in computed tomography. *Journal of Computer Assisted Tomography*, **1**, 437-442.
- BIEMOND A (1970) *Brain Diseases*. Amsterdam: Elsevier, pp. 771-785.
- BRUCE D A, RAPHAELY R C, GOLDBERG A I, ZIMMERMAN R A, BILANIUK L T, SCHUT L, KUHL D E (1979) Pathophysiology, treatment and outcome following severe head injury in children. *Child's Brain*, **5**, 174-191.
- BRUCE D A, ALAVI A, BILANIUK L T, DOLINSKAS C, OBRIST W, UZZELL B (1981a) Diffuse cerebral swelling following head injuries in children: the syndrome of 'malignant brain edema'. *Journal of Neurosurgery*, **54**, 170-178.
- BRUCE D A, SUTTON L N, SCHUT L (1981b) Acute brain swelling and cerebral edema in children. In: *Brain Edema*. Edited by M. de Vlieger, S. A. de Lange and J. W. F. Beks. New York: John Wiley, pp. 125-145.
- BYDDER G M, KREEL L (1979) The temperature dependence of computed tomography attenuation values. *Journal of Computer Assisted Tomography*, **3**, 506-510.

- COLD G E, JENSEN F T (1980) Cerebral blood flow in the acute phase after head injury. I. Correlation to age of the patients, clinical outcome and localisation of the injured region. *Acta Anaesthetica Scandinavica*, **24**, 245-251.
- DI CHIRO G, BROOKS R A, DUBAL L, CHEW E (1978) The apical artifact: elevated attenuation values toward the apex of the skull. *Journal of Computer Assisted Tomography*, **2**, 65-70.
- GALBRAITH S, SMITH J (1976) Acute traumatic intracranial haematoma without skull fracture. *Lancet*, **i**, 501-502.
- GJERRIS F, MELLEMGAAARD L (1969) Transitory cortical blindness in head injury. *Acta Neurologica Scandinavica*, **45**, 623-631.
- GRAND W (1974) The significance of post-traumatic status epilepticus in childhood. *Journal of Neurology, Neurosurgery and Psychiatry*, **37**, 178-180.
- HAAS D C, PINEDA G S, LOURIE H (1975) Juvenile head trauma syndromes and their relationship to migraine. *Archives of Neurology, Chicago*, **32**, 727-730.
- HENDRICK E B, HARRIS L (1968) Post-traumatic epilepsy in children. *Journal of Trauma*, **8**, 547-556.
- HENDRICK E B, HARWOOD-HASH D C F, HUDSON A R (1964) Head injuries in children: a survey of 4465 consecutive cases at the Hospital for Sick Children, Toronto, Canada. In: *Clinical Neurosurgery. Proceedings of the Congress of Neurological Surgeons*. Baltimore: Williams and Wilkins, pp. 46-65.
- JAMES H E (1979) Analysis of therapeutic modalities for head-injured children. *Child's Brain*, **5**, 263-271.
- JENNETT W B (1962, 1975) *Epilepsy after Non-missile Head Injuries*. London: Heinemann. First edition 1962; second edition 1975.
- JENNETT W B (1969) Early traumatic epilepsy. Definition and identity. *Lancet*, **i**, 1023-1025.
- JENNETT W B (1973) Trauma as a cause of epilepsy in childhood. *Developmental Medicine and Child Neurology*, **15**, 56-62.
- JENNETT W B, TEASDALE G, GALBRAITH S, PICKARD J, GRANT H, BRAAKMAN R, AVEZAAT C, MAAS A, MINDERHOUD J, VECHT C J, HEIDEN J, SMALL R, CATON W, KURZE T (1977) Severe head injuries in three countries. *Journal of Neurology, Neurosurgery and Psychiatry*, **40**, 291-298.
- KOBRINE A I, TIMMINS E, RAJJOUR R K, RIZZOLI H V, DAVIS D O (1977) Demonstration of massive traumatic brain swelling within 20 minutes after injury. Case report. *Journal of Neurosurgery*, **46**, 256-258.
- KUHL D E, LAVI A, HOFFMAN E J, PHELPS M E, ZIMMERMAN R A, OBRIST W D, BRUCE D A, GREENBERG J H, UZZELL B (1980) Local cerebral blood volume in head-injured patients. Determination by emission computed tomography of  $^{99m}\text{Tc}$ -labeled red cells. *Journal of Neurosurgery*, **52**, 309-320.
- LADURNER G (1978) Die Bestimmung des zerebralen Blutvolumens mit der Computer-tomographie in grauer und weisser Substanz. *Fortschritte der Neurologie-Psychiatrie und ihrer Grenzgebiete*, **46**, 369-381.
- LANGFITT T W, BRUCE D A (1975) Microcirculation and brain edema in head injury. In: *Handbook of Clinical Neurology*. Edited by P. J. Vinken and G. W. Bruyn. Amsterdam: North Holland, Volume 23, pp. 133-161.
- LEÃO A A P (1944) Spreading depression of activity in cerebral cortex. *Journal of Neurophysiology*, **7**, 359-390.
- LEVI C, GRAY J E, McCULLOUGH E C, HATTERY R R (1982) The unreliability of CT numbers as absolute values. *American Journal of Roentgenology*, **139**, 443-447.
- LINDENBERG R, FISHER R S, DURLACHER S H, LOVITT W V JR, FREYTAG E (1955) The pathology of the brain in blunt head injuries of infants and children. In: *Proceedings of the Second International Congress of Neuropathology*. Part II. Amsterdam: Excerpta Medica, pp. 477-479.
- LIVINGSTON K E, MAHLOUJJI M (1961) Delayed focal convulsive seizures after head injury in infants and children. A syndrome that may mimic extradural hematoma. *Neurology, Minneapolis*, **11**, 1017-1020.

- McCULLOUGH E C (1977) Factors affecting the use of quantitative information from a CT scanner. *Radiology*, **124**, 99-107.
- MEYER J S, TERAURA T, SAKOMOTO K, KONDO A (1971) Central neurogenic control of cerebral blood flow. *Neurology, Minneapolis*, **21**, 247-262.
- MIES G, NIEBUHR I, HOSSMANN K-A (1981) Simultaneous measurement of blood flow and glucose metabolism by autoradiographic techniques. *Stroke*, **12**, 581-588.
- MILLER J D, CORALES R L (1981) Brain edema as a result of head injury: fact or fallacy? In: *Brain Edema*. Edited by M. de Vlieger, S. A. de Lange and J. W. F. Beks. New York: John Wiley, pp. 99-115.
- NEW P F J, SCOTT W R (1975) *Computed Tomography of the Brain and Orbit (EMI Scanning)*. Baltimore: Williams and Wilkins, pp. 263-267.
- OBRIST W D, GENNARELLI T A, SEGAWA H, DOLINSKAS C A, LANGFITT T W (1979) Relation of cerebral blood flow to neurological status and outcome in head-injured patients. *Journal of Neurosurgery*, **51**, 292-300.
- OKA H, KAKO M, MATSUSHIMA M, ANDO K (1977) Traumatic spreading depression syndrome. Review of a particular type of head injury in 37 patients. *Brain*, **100**, 287-298.
- OMMAYA K (1979) Indices of neural trauma: an overview of the present status. In: *Neural Trauma*. Edited by A. J. Popp, R. S. Bourke, L. R. Nelson, and H. K. Kimelberg. New York: Raven Press, pp. 205-216.
- PAYNE J T, LATCHAW R (1978) Variation and nonuniform CT number response for intracranial contents as a function of skull thickness and head size. *Journal of Computer Assisted Tomography*, **2**, 509.
- PETERS A C B, VERSTEEG J, LINDEMAN J, BOTS G Th A M (1978) Viral meningoencephalitis and head injury. *Acta Neurologica Scandinavica*, **57**, 77-87.
- PHELPS M E, HOFFMAN E J, TER-POGOSSIAN M M (1975) Attenuation coefficients at various body tissues, fluids, and lesions at photon energies of 18 to 136 keV. *Radiology*, **117**, 573-583.
- PICKLES W (1949) Acute focal edema of the brain in children with head injuries. *New England Journal of Medicine*, **240**, 92-95.
- PLUM F, POSNER J B (1980) Supratentorial lesions causing coma. In: *The Diagnosis of Stupor and Coma*. Philadelphia: F. A. Davis. Third edition, pp. 87-151.
- RAICHLE M E (1979) Discussion. In: *Neural Trauma*. Edited by A. J. Popp, R. S. Bourke, L. R. Nelson and H. K. Kimelberg. New York: Raven Press, p. 49.
- RAICHLE M E, GRUBB R L JR, PHELPS M E, GADO M H, CARONNA J J (1978) Cerebral hemodynamics and metabolism in pseudotumor cerebri. *Annals of Neurology*, **4**, 104-111.
- REILLY P L, GRAHAM D I, ADAMS J H, JENNETT B (1975) Patients with head injury who talk and die. *Lancet*, **ii**, 375-377.
- ROSE J, VALTONEN S, JENNETT B (1977) Avoidable factors contributing to death after head injury. *British Medical Journal*, **2**, 615-618.
- SHINOHARA M, DOLLINGER B, BROWN G, RAPOPORT S, SOKOLOFF L (1979) Cerebral glucose utilization: local changes during and after recovery from spreading cortical depression. *Science*, **203**, 188-190.
- SMALL J M, WOOLF A L (1957) Fatal damage to the brain by epileptic convulsions after a trivial injury to the head. *Journal of Neurology, Neurosurgery and Psychiatry*, **20**, 293-301.
- SNOEK J, JENNETT B, ADAMS J H, GRAHAM D I, DOYLE D (1979) Computerised tomography after recent severe head injury in patients without acute intracranial haematoma. *Journal of Neurology, Neurosurgery and Psychiatry*, **42**, 215-225.
- SPELLER R D, WHITE D R, SHOWALTER C K, ROTHENBERG L N, PENTLOW K S, MORGAN T J, SHOPE T B (1981) An evaluation of CT systems from ten manufacturers. *British Journal of Radiology*, **54**, 1053-1061.
- TEASDALE G, JENNETT B (1974) Assessment of coma and impaired consciousness. A practical scale. *Lancet*, **ii**, 81-84.

- TODOROW S, FELLER A-M (1982) Ueber das Vorkommen benigner sekundärer Bewusstseinstäubung— das Einschlafsyndrom—nach Schädel-Hirn-Trauma bei Kindern. *Zeitschrift für Kinderchirurgie*, **36**, 83–87.
- WAGA S, TOCHIO H, SAKAKURA M (1979) Traumatic cerebral swelling developing within 30 minutes after injury. *Surgical Neurology*, **11**, 191–193.
- WALTON G L (1898) Subarachnoid serous exudation productive of pressure symptoms after head injuries. *American Journal of the Medical Sciences*, **116**, 267–275.
- WALTON G L, BROOKS W A JR (1897) Observations on brain surgery suggested by a case of multiple cerebral hemorrhage. *Boston Medical and Surgical Journal*, **136**, 301–305.
- WEINSTEIN M A, DUCHESNEAU P M, MACINTYRE W J (1977) White and gray matter of the brain differentiated by computed tomography. *Radiology*, **122**, 699–702.
- ZIMMERMAN R A, BILANIUK L T, BRUCE D, DOLINSKAS C, OBRIST W, KUHL D (1978) Computed tomography of pediatric head trauma: acute general cerebral swelling. *Radiology*, **126**, 403–408.

(Received February 8, 1983. Revised April 26, 1983)