

# Neuropathology of Familial Erythrophagocytic Lymphohistiocytosis:

## Six Cases and Review of the Literature

MICHIO AKIMA, MD, AND S. M. SUMI, MD

The authors report the brain findings in six cases of familial erythrophagocytic lymphohistiocytosis (FEL) and review the literature, focusing primarily on the neurologic and neuropathologic aspects. Clinically, the most common neurologic abnormalities in the six patients were stupor or coma and seizures, with hemiplegia and cranial nerve palsies. Neuropathologic changes were characterized by infiltration of the meninges by lymphocytes and histiocytes and perivascular lymphocytic cuffing and diffuse proliferation of histiocytes in the brain parenchyma. The severity of the brain involvement was variable. In the mildest case there was only meningeal involvement. More severely involved cases showed meningeal and perivascular infiltration of lymphoid cells in the brain. In the most severely involved cases, there was, in addition, diffuse cerebral infiltration by histiocytes accompanied by multifocal necrosis. Some cases showed disproportionately greater involvement of the brain than of the visceral organs. The authors conclude that "meningoencephalitis," histiocytic invasion, and necrotizing brain lesions are characteristic of FEL, although the mechanism of their production is not known. Frequent seizures and disseminated intravascular coagulopathy may be contributory. *HUM PATHOL* 15:161-168, 1984.

Farquhar and Claireaux<sup>1</sup> first delineated a form of infantile recituloendotheliosis that is distinct from Letterer-Siwe disease and is characterized by erythrophagocytosis, which they designated "familial hemophagocytic reticulosis." Since then, a number of similar cases have been reported under a variety of diagnostic terms, of which the most widely accepted appears to be "familial erythrophagocytic lymphohistiocytosis," a term introduced by MacMahon et al.<sup>2</sup> in 1963.

These cases had a number of clinical and pathologic characteristics in common, including infantile onset, familial occurrence, and rapidly progressive febrile illness with anemia, pancytopenia, hepatosplenomegaly, and proliferation of histiocytes containing erythrocytes. Although Farquhar et al.<sup>1,3</sup> did not mention any neurologic symptoms in their patients, subsequent authors<sup>2,4,5</sup> have noted that neurologic abnormalities commonly include alteration of the level of consciousness, nuchal rigidity, seizures, and hemiparesis. However, most reports have made only superficial reference to the neurologic and neuropathologic findings in these patients.

---

Received October 25, 1982, from the Laboratory of Neuropathology, Department of Pathology, and Child Development and Mental Retardation Center, University of Washington School of Medicine, Seattle, Washington. Revision accepted for publication February 10, 1983.

Dr. Akima is currently at the Department of Pathology, Toho University School of Medicine, Tokyo, Japan.

Address correspondence and reprint requests to Dr. Sumi: RJ-05 Neuropathology, University of Washington School of Medicine, Seattle, WA 98195.

We examined the brains of six patients with this disorder, five at autopsy and one by cortical biopsy, and reviewed the literature, focusing primarily on the neurologic and neuropathologic findings.

### REPORT OF SIX CASES

The pertinent findings are summarized in tables 1, 2 and 3. All the patients were admitted to Children's Orthopedic Hospital in Seattle, Washington.

*Case 1.* A 6-month-old female infant, an only child, was admitted with fever, hepatosplenomegaly, and a petechial skin rash. Hemoglobin was 28 per cent, and the leukocyte count was 5,400/mm<sup>3</sup> with 65 per cent lymphocytes. Skeletal radiographs were normal. Cerebrospinal fluid (CSF) contained 73 erythrocytes/mm<sup>3</sup> and nine leukocytes/mm<sup>3</sup>, with 120 mg/dl protein and 40 mg/dl glucose. The patient's course was complicated by disseminated intravascular coagulopathy. She went into status epilepticus with conjugate gaze palsy to the left and a right facial palsy. She died one and a half months after the onset of her illness.

Autopsy revealed jaundice, diffuse macular cutaneous hemorrhages, and hepatosplenomegaly. All organs were infiltrated by lymphocytes and histiocytes, some of which had engulfed erythrocytes.

The brain weighed 690 g after fixation. The leptomeninges were thickened and opaque over the cerebral convexities. The cerebrum was soft, and there were diffuse, symmetrical, indistinctly demarcated granular, necrotic areas throughout the occipito-parieto-temporal gray and white matter, with smaller areas of necrosis in the basal ganglia (fig. 1). In addition, bilateral multifocal hemorrhagic necrosis of the cerebellar white matter (fig. 2), inferior colliculi, and substantia nigra were present.

There was diffuse infiltration of the meninges by lymphoid cells and histiocytes, some of which contained erythrocytes (fig. 3). The cerebrum was diffusely infiltrated by fat-laden histiocytes and the normal architecture was destroyed. Histiocytic proliferation was more prominent in the cortex, but the deeper structures appeared to be more edematous. In places, cortical necrosis had a laminar appearance. There was extensive perivascular lymphocytic infiltration. Erythrophagocytosis was again easily identified. There was extensive necrosis and histiocytic infiltration in the putamen, midbrain, and cerebellum with perivascular accumulation of lymphocytes.

*Case 2.* A 4-month-old female infant was admitted one month before death, with fever, hepatosplenomegaly, anemia, and thrombocytopenia. An older sister had died at 3 months of age with an autopsy diagnosis of "atypical Letterer-Siwe disease." The patient's hematocrit was 33 per cent and the leukocyte count was 1,600/mm<sup>3</sup> with 90 per cent lymphocytes. Mild thrombocytopenia was present. Diagnosis of familial erythrophagocytic lymphohistiocytosis was made by liver biopsy.

**TABLE 1.** Clinical and Laboratory Findings in Six Cases of Familial Erythrophagocytic Lymphohistiocytosis

	Age at Onset (months), Sex	Familial Occurrence	Duration of illness (weeks)	Fever	Hepato-splenomegaly	Anemia	Leukocytes/mm <sup>3</sup> (% Lymph)	Thrombocytopenia	Biopsy Findings
Case 1	5½, F	No (only child)	6	+	+	+	4,800 (70)	+	Bone marrow: erythroid hyperplasia and histiocytosis
Case 2	4, F	Yes	2	+	+	+	1,600 (90)	+	Bone marrow: normal; liver: lymphohistiocytic infiltration
Case 3	4½, F	Yes	10	+	+	+	Pancytopenia	+	Bone marrow: reticuloendotheliosis; liver: non-diagnostic; lymph node: non-diagnostic
Case 4	5, F	Yes	20	+	+	+	15,300 (66)	-	Liver: lymphohistiocytic infiltration; lymph node: histiocytosis
Case 5	1½, M	Yes	16	+	+	+	5,200 (63)	+	Bone marrow: non-diagnostic; lymph node: histiocytosis
Case 6	1½, M	Yes	1	+	+	+	6,100 (80)	-	

Subsequently, the patient developed otitis media and became lethargic. Left-sided seizures, which became generalized, followed. Left hemiparesis and multifocal seizure disorder continued, and the patient remained in coma.

At autopsy there was generalized lymphadenopathy and a moderate hepatosplenomegaly with infiltration of all organs by lymphocytes and histiocytes, some of which showed erythrophagocytosis. In addition, small infarctions were present in the spleen.

The brain weighed 750 g after fixation and appeared normal externally, but on sectioning diffuse pseudolaminar necrosis of the cerebral cortex was observed, which was most marked in the temporal lobes. There was a focal area of softening in the right parietal lobe. Histologically, there was diffuse meningeal infiltration by lymphocytes and histiocytes. Erythrophagocytosis was noted. Shrunken, eosinophilic neurons with pyknotic nuclei were present in the cerebral cortex, and some regions showed extensive neuronal loss, pseudolaminar necrosis, and proliferation of capillaries. Again, perivascular lymphocytic infiltration and large numbers of foamy histiocytes were found in the cerebral white matter, basal ganglia, and thalamus (fig. 4). Similar changes were present in the cerebellum.

*Case 3.* A female infant, one of identical twins, was admitted at 4½ months of age, with fever, hepatosplenomegaly, mild lymphadenopathy, anemia, and pancytopenia. Cerebrospinal fluid findings were normal. Liver and lymph node biopsy findings were inconclusive. She was readmitted at 6½ months of age with fever and increasing lethargy, followed by left- and right-sided focal seizures. Although the pupils were reactive to light, she would not follow light. The fundi were normal. She appeared to hear. The arms were held in flexion, and there was opisthotonus. At this time the CSF contained 3,000 erythrocytes, 20 neutrophils, and 60 monocytes per cubic millimeter, with 89 mg/dl protein and 51 mg/dl glucose. A ventriculogram showed slight ventricular dilation. Skeletal radiographs showed only slight widening of the cranial sutures. The patient died 11 days after admission.

General autopsy findings included an enlarged liver, spleen, and lymph nodes and infiltration by lymphocytes and macrophages with occasional erythrophagocytosis.

The brain weighed 740 g after fixation. The brain was not swollen and showed only a small hematoma over the

right frontal convexity at the site of the ventricular needling. Sections of the cerebral hemispheres, cerebellum, and brainstem showed no other gross abnormality. Microscopically, there was diffuse infiltration of the meninges by lymphocytes and large histiocytes, many of which had engulfed the erythrocytes in the hemorrhagic area. There was diffuse histiocytic and perivascular lymphocytic infiltration of both the cerebral cortex and the white matter. The perivascular inflammation was so extensive that it resembled an encephalitic process (fig. 5). A mild proliferation of astrocytes was intermingled with the histiocytes. Striking perivascular lymphocytic infiltration was also observed in the thalamus, globus pallidus, midbrain, and pons. In the cerebellum there was perivascular lymphocytic infiltration in the white matter, but the cortex was not involved, and similar, but milder, changes were found in the spinal cord. Definite areas of necrosis were not found.

*Case 4.* The patient was the identical twin sister of the patient described in case 3. She was admitted at 5 months of age with fever, hepatosplenomegaly, and anemia. The leukocyte count was 15,300/mm<sup>3</sup> with 34 per cent neutrophils, 52 per cent lymphocytes, and 14 per cent monocytes. Chest and skeletal radiographs were normal.

The patient was readmitted at 8 months of age, with fever and transient tremor of the head and trunk, which was followed by stupor. Hepatosplenomegaly persisted, and she had nuchal rigidity. There was decreased muscle tone and bilateral Babinski signs.

The CSF contained 27 mononuclear cells/mm<sup>3</sup> and 60 mg/dl protein. Splenectomy and liver and lymph node biopsies revealed infiltration by mononuclear cells in these organs, and a diagnosis of reticuloendotheliosis was made. The patient had increasing numbers of generalized convulsions, and the course of her illness was complicated by otitis media. She died two months after admission.

At autopsy the liver was markedly enlarged with periportal infiltration by lymphoid cells and a few histiocytes. Similar changes were found in the kidneys and the lungs. Lymph nodes showed mild lymphocyte depletion and histiocytic proliferation. No erythrophagocytosis was seen.

The brain weight was not available. The brain was very soft and friable, and the normal structures could not be identified. There was slight ventricular dilatation. Histologically, there was diffuse meningeal infiltration by lymphocytes and large histiocytes, many of which had engulfed the erythrocytes in the hemorrhagic area. There was diffuse histiocytic and perivascular lymphocytic infiltration of both the cerebral cortex and the white matter. The perivascular inflammation was so extensive that it resembled an encephalitic process (fig. 5). A mild proliferation of astrocytes was intermingled with the histiocytes. Striking perivascular lymphocytic infiltration was also observed in the thalamus, globus pallidus, midbrain, and pons. In the cerebellum there was perivascular lymphocytic infiltration in the white matter, but the cortex was not involved, and similar, but milder, changes were found in the spinal cord. Definite areas of necrosis were not found.

TABLE 2. Neurological Findings, All Cases

Reference	Case No.	Meningeal Signs	Seizures	Focal Signs	Stupor/Coma	CSF		
						Leukocytes/mm <sup>3</sup> (%, lymphocytes)	Protein (mg/dl)	Glucose (mg/dl)
This report	1	-	+	+	+	9 (100)	120	40
	2	-	+	+	+	7 (100)	32	63
	3	-	+	NA	+	80 (75)	89	51
	4	+	+	NA	+	27 (100)	60	NA
	5	-	+	+	+	86 (72)	252	37
	6	-	NA	NA	NA	2	31	30
Reese and Levy <sup>8</sup>	1	NA	+	NA	NA	NA	NA	NA
	2	NA	NA	NA	NA	NA	NA	NA
Farquhar and Claireaux <sup>1</sup>	1	NA	NA	NA	NA	NA	NA	NA
Falk and Gellei <sup>9</sup>	2	NA	NA	NA	NA	NA	NA	NA
	3	NA	NA	NA	NA	NA	NA	NA
Nelson et al. <sup>7</sup>	1	NA	+	NA	NA	128 (100)	NA	NA
	2	NA	NA	NA	NA	226 (99)	162	38
	3	+	NA	NA	+	407 (96)	177	16
Farber and Vawter <sup>10</sup>		NA	+	NA	NA	NA	NA	NA
MacMahon et al. <sup>2</sup>	2	+	NA	NA	NA	63 (100)	476	64
Schoeck et al. <sup>11</sup>	1	NA	NA	NA	NA	NA	NA	NA
Miller <sup>13</sup>	L	NA	NA	NA	NA	NA	NA	NA
	S	NA	+	NA	NA	N	N	N
	V	NA	NA	NA	NA	NA	NA	NA
Berard et al. <sup>12</sup>	1	NCS	NCS	NCS	NA	N	N	N
Bell et al. <sup>14</sup>	1	+	NA	NA	+	16 (100)	50	N
Buist et al. <sup>16</sup>	1	NA	NA	NA	NA	NA	NA	NA
	2	+	NA	NA	NA	40 (100)	35	NA
Price et al. <sup>6</sup>	1	NA	+	+	+	4 (100)	440	NA
	2	NA	+	-	+	365 (100)	NA	NA
	3	NA	+	-	+	S	E	E
O'Brien et al. <sup>17</sup>	2	NA	NA	NA	NA	N	N	N
Weinberg and Rogers <sup>18</sup>	1	NA	+	NA	+	8 (100)	10	63
Koto et al. <sup>4</sup>		NA	NA	NA	+	NA	NA	NA
Appen et al. <sup>20</sup>		+	+	NA	NA	56 (36)	160	42
Frisell et al. <sup>22</sup>	1	NA	NA	NA	NA	NA	NA	NA
	2	NA	NA	NA	NA	NA	NA	NA
Ambruso et al. <sup>23</sup>	1	NA	+	NA	+	NA	NA	NA
Miller et al. <sup>5</sup>		NA	+	+	+	NA	NA	NA
Lilleyman <sup>24</sup>	1	NA	NA	NA	NA	150 (80)*	NA	NA
	2	NA	NA	NA	NA	NA	NA	NA

KEY: NA, not available; N, "normal"; NCS, "no CNS signs"; S, "small number"; E, "elevated"; +, present; -, absent.

\* Histiocytes, 19 per cent.

phoid and histiocytic cells. The former were more abundant around blood vessels, and the latter had engulfed erythrocytes and other cellular debris. There was extensive necrosis of the cerebrum so that the gray matter and white matter were indistinguishable. The molecular layer of the cortex was marked by proliferation of gemistocytic astrocytes, and the rest of the brain consisted of a loose accumulation of large foamy macrophages, which showed active phagocytosis and marked perivascular infiltration by lymphoid cells with scattered islands of large astrocytes.

The thalamus and basal ganglia were also necrotic and infiltrated by microglia. There was extensive loss of the

normal architecture in the midbrain, pons, and medulla, with gliosis, perivascular lymphoid cell accumulation, and histiocytic proliferation. The spinal cord was better preserved and showed only perivascular lymphocytic infiltration.

*Case 5.* The patient was the older brother of the twin sisters described in cases 3 and 4. He became ill at 6 weeks of age, with fever, hepatosplenomegaly, and anemia. The leukocyte count was 5,200/mm<sup>3</sup>, with 63 per cent lymphocytes. The platelet count was 32,000/mm<sup>3</sup>. Reticuloendotheliosis was diagnosed on lymph node biopsy. Fever recurred when the patient was 4½ months of age, and he

**TABLE 3.** Neuropathological Findings, All Cases

Reference	Case No.	Gross Findings	Meningeal Infiltration	Perivascular Cuffing	Cerebral Histiocytic Infiltration	Necrosis
This report	1	Necrosis	+	+	+	+
	2	Necrosis	+	+	+	+
	3	Small hematoma	+	+	+	-
	4	Necrosis	+	+	+	+
	5	(Biopsy only)	No meninges	+	-	-
	6	Subarachnoid hemorrhage	+	-	-	-
Reese and Levy <sup>8</sup>	1	Petechiae	NA	NA	NA	NA
	2	Normal	NA	NA	NA	NA
Farquhar and Claireaux <sup>1</sup>	1	Normal	NA	NA	NA	NA
Falk and Gellei <sup>9</sup>	2	NA	NA	+	NA	NA
	3	NA	NA	+	NA	NA
Nelson et al. <sup>7</sup>	1	Petechiae	+	+	NA	NA
	2	NA	+	+	NA	NA
	3	Normal	+	+	NA	NA
Farber and Vawter <sup>10</sup>		Normal	+	+	NA	NA
MacMahon et al. <sup>2</sup>	2	Meningeal thickening	+	+	+	NA
Schoeck et al. <sup>11</sup>	1	NA	+	NA	NA	NA
Miller <sup>13</sup>	L	NA	+	+	NA	NA
	S	NA	+	+	NA	NA
	V	NA	+	+	NA	NA
Berard et al. <sup>12</sup>	1	Normal	-	-	-	-
Bell et al. <sup>14</sup>	1	Reduced cortical thickness	+	+	+	-
Buist et al. <sup>16</sup>	1	Subdural hematoma	+	NA	NA	NA
	2	NA	+	NA	NA	NA
Price et al. <sup>6</sup>	1	Necrosis	+	+	+	+
	2	Necrosis	+	+	+	+
	3	NA	+	+	+	-
O'Brien et al. <sup>17</sup>	2	NA	NA	+	NA	NA
Weinberg and Rogers <sup>18</sup>	1	Normal	+	+	NA	NA
Koto et al. <sup>4</sup>		Normal	+	+	NA	NA
Appen et al. <sup>20</sup>		Meningeal hemorrhage along the brainstem	+	+	NA	NA
Frisell et al. <sup>22</sup>	1	NA	NA	+	NA	NA
	2	NA	NA	+	NA	NA
Ambruso et al. <sup>23</sup>	1	NA	+	PML	NA	NA
Miller et al. <sup>5</sup>		White matter necrosis	+	+	+	EMB
Lilleyman. <sup>24</sup>	1	NA	+	+	NA	NA
	2	(Biopsy only)	-	-	NA	NA

KEY: NA, not available; PML, "pathological features of progressive multifocal leukoencephalopathy"<sup>23</sup>; EMB, "extensive myelin breakdown"; +, present; -, absent.

\* With erythrophagocytosis.

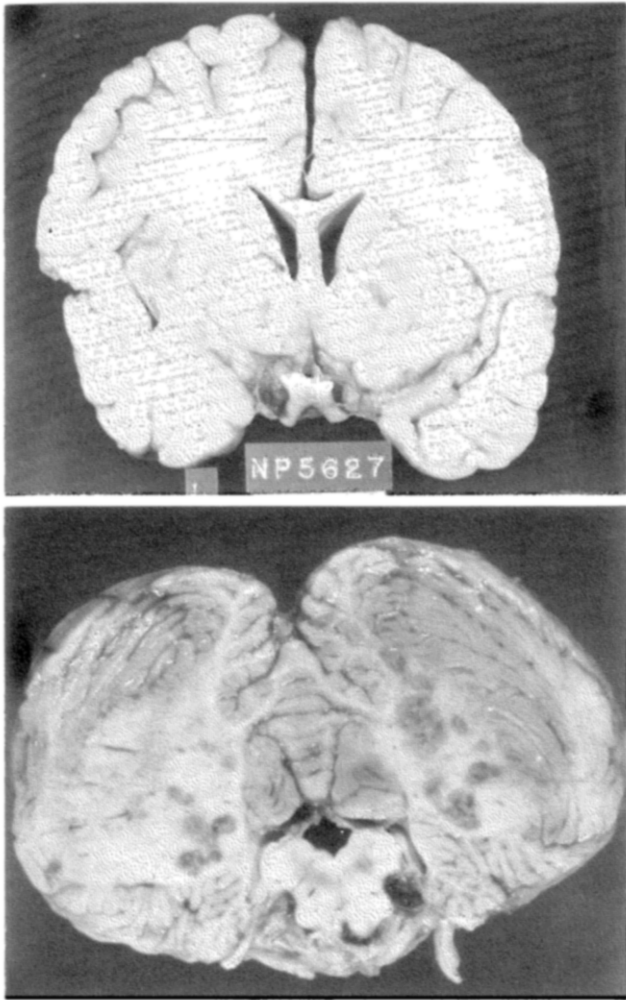
had twitching of the left eyelid, face, arm, and leg. The CSF contained 11,400 erythrocytes, 63 mononuclear cells, and 23 neutrophils per cubic millimeter. Protein was 152 mg/dl, and glucose was 37 mg/dl. The patient had frequent left facial seizures, right facial weakness, and hyperactive tendon reflexes bilaterally. Subdural taps were negative, but 10 days later they revealed a large subdural hematoma, which was removed surgically. Cerebral cortical biopsy was performed. The patient continued to have spasticity and frequent muscle twitching, and he died at home at 5½ months of age.

An autopsy was not performed. The brain biopsy

showed dense gliosis with perivascular cuffing of lymphocytes.

*Case 6.* A 7-week-old male infant was in good health until four days before his death, when he was admitted with fever, hepatosplenomegaly, and anemia. Cerebrospinal fluid contained 2 lymphocytes/mm<sup>3</sup>, with 70 mg/dl protein and 52 mg/dl glucose. Despite administration of antibiotics, steroids, and  $\gamma$  globulin, the patient died. An older sister with a similar history had died, but no autopsy had been performed.

General autopsy findings for the male infant included jaundice, hepatosplenomegaly, and generalized lymphad-



**FIGURE 1** (top). Case 1. Multiple foci of necrosis of the frontal, insular, and temporal cortices and in the central white matter, putamen, and pallidum.

**FIGURE 2** (bottom). Case 1. Multiple areas of hemorrhagic necrosis in the cerebellar white matter.

enopathy, with infiltration by lymphoid cells and histiocytes that exhibited erythrophagocytosis.

The brain weighed 580 g after fixation. There was a small amount of subarachnoid blood in the right precentral region. Bile-staining of the choroid plexus was the only other abnormality observed in the gross brain. Microscopically, there was lymphocytic and histiocytic infiltration of the leptomeninges (fig. 6), but no parenchymal involvement was seen.

## DISCUSSION

All our patients had the clinical and pathologic features of familial erythrophagocytic lymphohistiocytosis (FEL). Fever, hepatosplenomegaly, and anemia were common to all, and lymphohistiocytosis with erythrophagocytosis was present in the viscera or the brain in all.

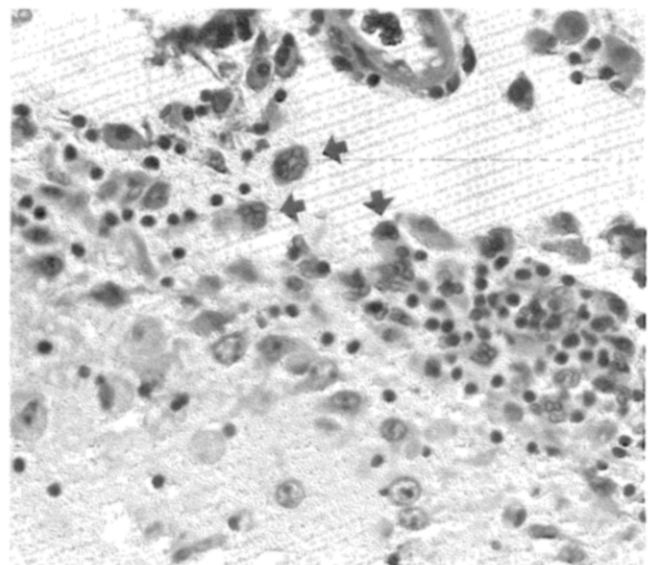
Four of our six patients were girls, and two were boys. In all but one (an only child, case 1), there was

at least one other similarly affected sibling and consanguinity was not a factor. Similar familial involvement was present in the majority of the reported cases. These data support an autosomal recessive mode of inheritance. In all our patients, the illness began within the first six months of life and the duration of illness was brief, all patients succumbing within five months.

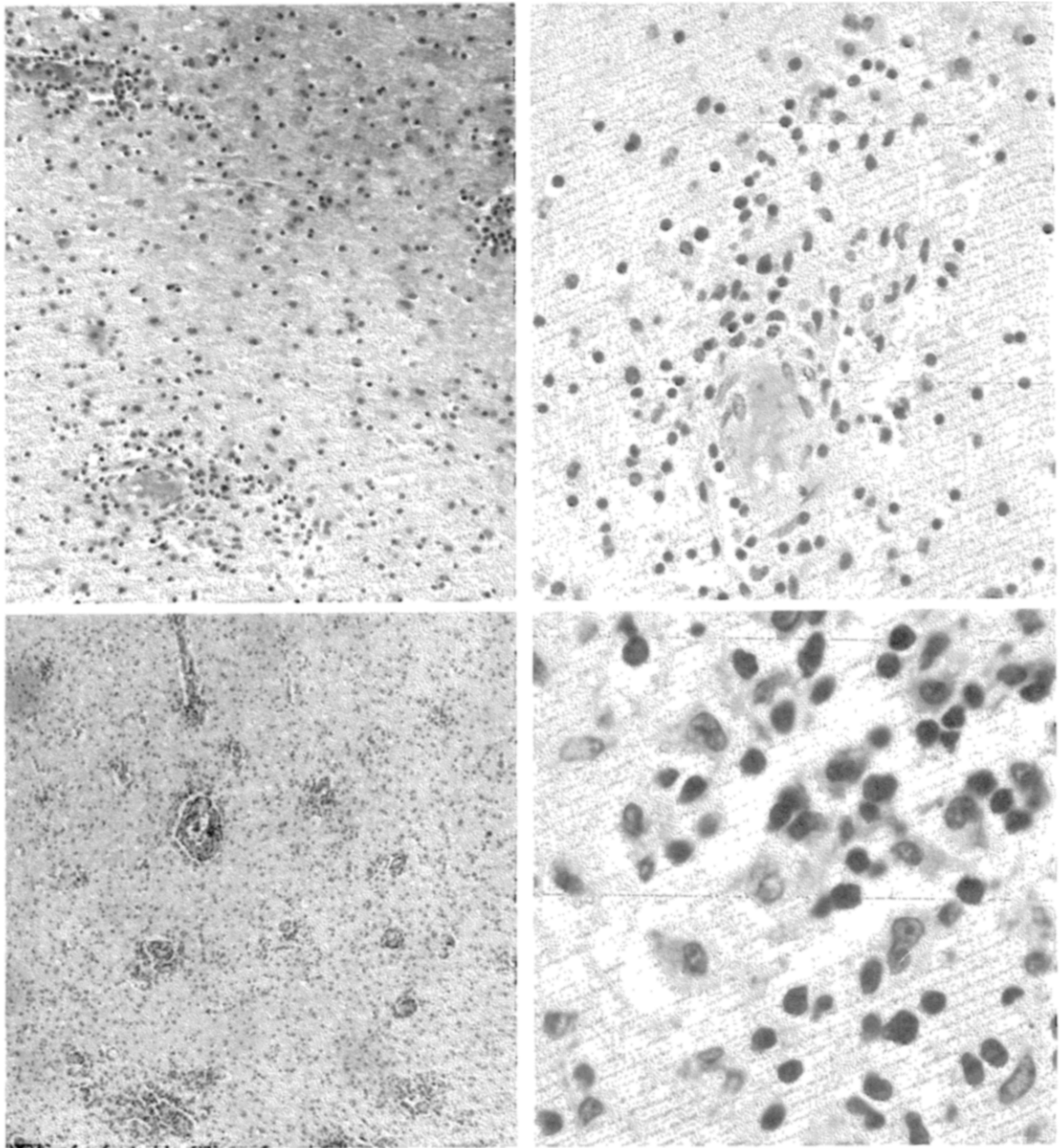
The age distribution of our patients conforms to that reported by most authors. Exceptions were the family reported by Price et al.,<sup>6</sup> in which the youngest affected child was 7 months old and the others were 10 months, 18 months, and 6 years old at onset of disease, and the families reported by Nelson et al.,<sup>7</sup> two of whose patients were 3 and 7 years old, respectively.

We restricted our literature review to those reports in which reference was made to the brain, either at autopsy or on biopsy. There were 31 cases in 20 reports that fulfilled this criterion,<sup>1,2,4-14,16-18,20,22-24</sup> but very few of these reports contained detailed clinical or pathologic descriptions of the nervous system. The thoroughness with which the nervous system was evaluated varied greatly (tables 2 and 3), so it was impossible to determine the true incidence of neurologic involvement in this disease.

The most common brain abnormality was the microscopic appearance of "leptomeningitis," consisting of diffuse or patchy infiltration by lymphocytes and histiocytes. This was found in all our patients and in 21 of the 31 reported cases. Grossly visible leptomeningeal thickening was observed in only one of our cases (case 2) and in case 2 of MacMahon et al.,<sup>2</sup> and in neither was it striking. Erythrophagocytosis was present in the meninges in all five of our autopsied cases and in six reported cases (table 3). In contrast, nuchal rigidity was an unusual clinical finding, being



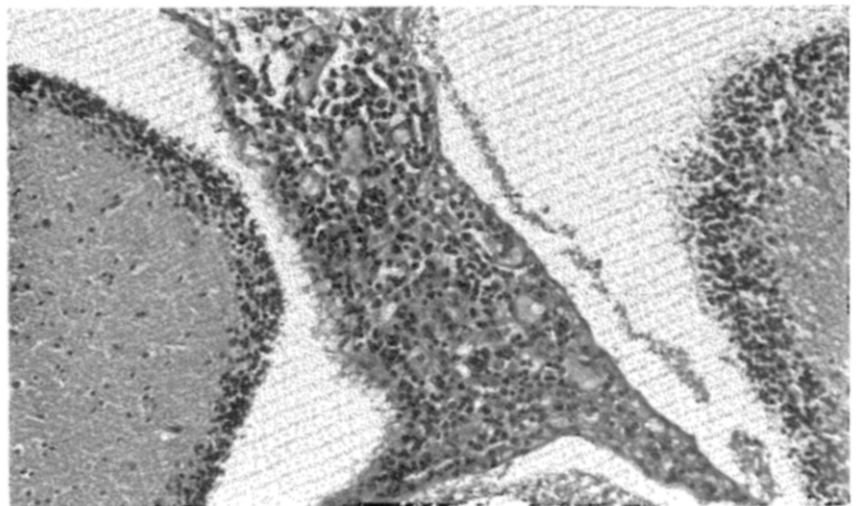
**FIGURE 3.** Case 1. Infiltration of the pia mater by lymphocytes and histiocytic cells containing erythrocytes (arrows) in case 1. The subpial region shows proliferation of astrocytes and histiocytic infiltration. (Hematoxylin-eosin stain,  $\times 400$ )



**FIGURE 4** (top row). Case 2. *Left*, several foci of perivascular lymphocytic accumulation, and diffuse infiltration of adjacent brain tissue by macrophages. (Hematoxylin–eosin stain,  $\times 100$ .) *Right*, one such focus at higher magnification. (Hematoxylin–eosin stain,  $\times 230$ .)

**FIGURE 5** (middle row). Case 3. *Left*, occipital lobe white matter with an "encephalitic" appearance due to extensive perivascular lymphocytic infiltration. (Hematoxylin–eosin stain,  $\times 40$ .) *Right*, high-power view showing details of infiltrating cells, lymphocytes, and foamy macrophages. (Hematoxylin–eosin stain,  $\times 500$ .)

**FIGURE 6** (bottom). Case 6. Meningeal infiltration by lymphocytes and histiocytes, cerebellum. (Hematoxylin–eosin stain,  $\times 100$ .)



present only in our case 4 and in five of the reported cases (table 2). Cerebrospinal fluid abnormalities correlated much better and were a frequent finding. In all five of our cases in which the CSF was examined, there was mononuclear leukocytosis, elevation of protein, and depression of glucose content. Similar results were reported for 12 of the 15 published cases in which this examination was carried out (table 2). Although the leukocytosis and increased protein content can be readily explained by the autopsy findings, the reason for the relative depression of glucose is not readily apparent. There was no evidence of bacterial or fungal infection in any of these cases. The hypoglycorrhachia may have been due to the rapid proliferation of histiocytes and lymphocytes, to the phagocytic activity of the histiocytes, or to an alteration in the blood-CSF barrier to glucose, as has been suggested to explain the hypoglycorrhachia associated with meningeal cancer<sup>25</sup> and meningitis.<sup>26-29</sup> Hemophagocytosis in the CSF was recorded in one patient by Hsu and Komp<sup>30</sup> on cytopathologic examination, a technique that may provide further aid in establishing this diagnosis in future cases.

Grossly, only a single focal hemorrhage was present in each of two cases—at the site of a frontal ventricular needling in case 1 and in the precentral region in case 6. No other macroscopic abnormality was observed in these cases. Subdural hematoma occurred in one patient (case 5) and in the first patient reported by Buist et al.<sup>16</sup> In our patient, a child with thrombocytopenia, the hematoma was probably the result of the negative ventricular tap performed 10 days previously.

In addition to the infiltration of the leptomeninges, another constant microscopic finding was perivascular accumulation of lymphocytes and foamy histiocytes. This was present in all our cases and in 23 cases from the literature (table 3). There also was diffuse histiocytic infiltration of the brain parenchyma without evident necrosis in case 3, which was apparently found in three reported cases. In three of our cases and in four other reported cases, multifocal or diffuse areas of necrosis were present, but in none of the cases was vascular occlusion demonstrated.

The severity of the brain abnormalities appeared to be related, in part, to the duration of the illness. The mildest involvement, consisting of only patchy meningeal infiltration, was observed in patient 6, who survived only one week, while the most severe changes were present in patients 1 and 4, who survived 20 and 6 weeks, respectively. Necrotic lesions were present also in three patients described by Price et al.<sup>6</sup> who survived five months, ten months, and six years, respectively; in that of Miller et al.,<sup>5</sup> who survived two months; and in that of Ambruso et al.,<sup>23</sup> who survived more than 13 weeks. In some patients—our cases 1 and 4 and those of Price et al.<sup>6</sup>—the brain abnormalities were much more extensive than those in the visceral organs. These patients had the longest survival times. In fact, the almost complete sparing of the viscera despite the extensive in-

volvement of the nervous system as well as the later onset of the illness in the patients reported by Price et al. raises the possibility that they suffered from a closely related but separate disease. However, until the pathogenesis of this disease is understood, it is impossible to determine whether this was the case.

Two patients with apparent restriction of the necrosis to the cerebral white matter have been described. In one, Ambruso et al.<sup>23</sup> reported "pathological features of progressive multifocal leukoencephalopathy" without viral inclusions. In the other, Miller et al.<sup>5</sup> found "extensive myelin destruction" with sparing of the subcortical U fibers, in addition to the lymphocytic and histiocytic infiltration of the leptomeninges and the brain.

Although erythrophagocytosis was demonstrated in leptomeningeal histiocytes in all five of our cases examined at autopsy, this feature was observed in the cerebrum in only two (cases 1 and 4). Erythrophagocytosis was recorded in only six reported cases—four in the leptomeninges and two in the cerebrum (table 3). This may be a reflection of the care with which the brain was examined and the findings recorded.

Peterson and Kuwabara<sup>15</sup> and Appen et al.<sup>20</sup> described ocular lesions in two patients, consisting of swelling of the optic nerve head with infiltration by histiocytes and lymphocytes. The eyes were not studied in any of our cases. Patient 1 would not follow light, but the fundoscopic examination revealed no abnormalities.

The surprising rarity of nuchal rigidity, with almost constant microscopic meningeal infiltration, has already been noted. In contrast, alterations in level of consciousness were very common findings, even in the absence of other neurologic abnormalities and may have been due in some patients to the metabolic changes induced by the multiple organ involvement. In others, such alterations may have resulted from cellular infiltration ("encephalitis") of the brainstem, and in others they may have been a consequence of convulsions. It seems unlikely that this was a reflection of increased intracranial pressure due to cerebral swelling or hydrocephalus, since these changes were conspicuous by their absence.

Although the pathogenesis of the CNS involvement in FEL has not been established, the disease is considered a non-neoplastic histiocytosis<sup>4</sup> whose cause has not been identified. The leptomeningeal and perivascular infiltration by lymphocytes and histiocytes suggests an inflammatory process. As Hsu and Komp<sup>30</sup> have noted, there has been frequent mention of "meningitis" in the older siblings of affected patients. However, no infectious agent has been identified. Although Ambruso et al.<sup>23</sup> thought that their findings suggested progressive multifocal leukoencephalopathy (PML), no other reported cases, including ours, had such a distribution of lesions, and those investigators<sup>23</sup> did not find intranuclear inclusions in oligodendroglia or atypical astrocytes, the diagnostic features of PML.<sup>31</sup> Similarly,

perivenous demyelination suggesting post-infectious or para-infectious encephalomyelitis as reported by Miller et al.<sup>5</sup> appears to be a unique observation in FEL. Such an "allergic" inflammatory disease appears to be very rare in infants, de Vries<sup>32</sup> having reported that he was unable to find any instance of encephalomyelitis after vaccination in children under 2 years of age.

Two reports have documented immunologic abnormalities in patients with FEL. Fullerton et al.<sup>19</sup> found marked deficiency in the lymphocytic reaction to phytohemagglutinin, decreased glucose oxidation by phagocytosing cells, and low IgA levels. Ladisch et al.<sup>33</sup> also found defects in both humoral and cellular immunity. Whether these immunologic deficiencies are the primary defects in FEL is not known.

Previously, Miller<sup>13</sup> had suggested that FEL is a manifestation of a graft-versus-host reaction to maternal-to-fetal "transplant" of lymphocytes. However, the distribution of T and B cells is normal,<sup>21</sup> and maternal lymphocytes have not been demonstrated.<sup>19</sup>

Necrotic lesions in the brain may be due to multiple infarctions, but occluded blood vessels have not been described in any patient with FEL. Disseminated intravascular coagulation, which was observed in two of our patients (cases 1 and 2), is a recognized complication,<sup>4,17</sup> and small blood vessel occlusions could lead to multifocal seizure, coma, and focal neurologic findings. Such lesions could explain the histiocytic infiltration in areas of necrosis, but perivascular lymphocytic infiltration is never a prominent feature of cerebral infarction. In addition, there are cases with extensive histiocytic infiltration without necrosis.

At this time, therefore, there is no obvious explanation for the frequent occurrence of neurologic and neuropathologic abnormalities in FEL except as part of a generalized, multi-organ dissemination of disease.

*Acknowledgment.* The authors thank the members of the Department of Pathology, Children's Orthopedic Hospital, Seattle, for making the autopsy and biopsy material and their reports freely available to us.

## REFERENCES

- Farquhar JW, Claireaux AE: Familial haemophagocytic reticulosis. *Arch Dis Child* 27:519, 1952
- MacMahon HE, Bedizel M, Ellis CA: Familial erythrophagocytic lymphohistiocytosis. *Pediatrics* 32:868, 1963
- Farquhar JW, MacGregor AR, Richmond J: Familial haemophagocytic reticulosis. *Br Med J* 2:1561, 1958
- Koto A, Morecki R, Santorineou M: Congenital hemophagocytic reticulosis. *Am J Clin Pathol* 65:495, 1976
- Miller CA, Shulman I, Taylor C: Demyelination with hemophagocytic lymphohistiocytosis of the CNS. *Acta Neuropathol* 54:153, 1981
- Price DL, Woolsey JE, Rosman NP, et al: Familial lymphohistiocytosis of the nervous system. *Arch Neurol* 24:270, 1971
- Nelson P, Santamaria A, Olson RL, et al: Generalized lymphohistiocytic infiltration: a familial disease not previously described and different from Letterer-Siwe disease and Chediak-Higashi syndrome. *Pediatrics* 27:931, 1961
- Reese AJM, Levy E: Familial incidence of non-lipoid reticuloendotheliosis (Letterer-Siwe disease). *Arch Dis Child* 26:258, 1951
- Falk W, Gellei B: The familial occurrence of Letterer-Siwe disease. *Acta Pediatr* 46:471, 1957
- Farber S, Vawter GF: Clinical pathological conference: The Children's Hospital Medical Center, Boston. *J Pediatr* 61:312, 1962
- Schoeck VW, Peterson RDA, Good RA: Familial occurrence of Letterer-Siwe disease. *Pediatrics* 32:1055, 1963
- Berard C, Cooper RA, Freireich EJ, et al: Disseminated histiocytosis associated with atypical lymphoid cells (lymphohistiocytosis). *Cancer* 19:1429, 1966
- Miller DR: Familial reticuloendotheliosis: concurrence of disease in five siblings. *Pediatrics* 38:986, 1966
- Bell RJM, Brafield AJE, Barnes ND, et al: Familial haemophagocytic reticulosis. *Arch Dis Child* 43:601, 1968
- Peterson RA, Kuwabara T: Ocular manifestation of familial lymphohistiocytosis. *Arch Ophthalmol* 79:413, 1968
- Buist NRM, Jones RN, Cavens TR: Familial haemophagocytic reticulosis in first cousins. *Arch Dis Child* 46:728, 1971
- O'Brien RT, Schwartz AD, Pearson HA, et al: Reticuloendothelial failure in familial erythrophagocytic lymphohistiocytosis. *J Pediatr* 81:543, 1972
- Weinberg AG, Rogers LE: Hepatosplenomegaly, pancytopenia, and fever. *J Pediatr* 82:879, 1973
- Fullerton P, Ekert H, Hosking C, et al: Hemophagocytic reticulosis: a case report with investigations of immune and white cell function. *Cancer* 36:441, 1975
- Appen RE, Weber SW, de Venecia G, et al: Ocular and cerebral involvement in familial lymphohistiocytosis. *Am J Ophthalmol* 82:758, 1976
- Perry MC, Harrison EG Jr, Burgert EO Jr, et al: Familial erythrophagocytic lymphohistiocytosis: report of two cases and clinicopathologic review. *Cancer* 38:209, 1976
- Frisell E, Bjorksten B, Holmgren G, et al: Familial occurrence of histiocytosis. *Clin Genet* 11:163, 1977
- Ambruso DR, Hays T, Zwartjes WL, et al: Successful treatment of lymphohistiocytic reticulosis with phagocytosis with epipodophyllotoxin VP 16-213. *Cancer* 45:2516, 1980
- Lilleman JS: The treatment of familial erythrophagocytic lymphohistiocytosis. *Cancer* 46:468, 1980
- Berg L: Hypoglycorrhachia of non-infectious origin: diffuse meningeal neoplasia. *Neurology* 3:811, 1953
- Petersdorf RG, Harter DH: The fall in cerebrospinal fluid sugar in meningitis: some experimental observations. *Arch Neurol* 4:21, 1961
- Weichsel M, Herzog G: Significance of the diminution of the spinal fluid sugar in tuberculous meningitis. *J Pediatr* 9:763, 1936
- Sifontes JE, Williams RO, Lincoln EM, et al: Observations on the effect of induced hyperglycemia on the glucose content of the cerebrospinal fluid in patients with tuberculous meningitis. *Am Rev Tuberc* 67:732, 1953
- Menkes HM: The cause for low spinal fluid sugar in bacterial meningitis: another look. *Pediatrics* 44:1, 1969
- Hsu TS, Komp DM: Clinical features of familial histiocytosis. *Am J Pediatr Hematol Oncol* 3:61, 1981
- Astrom KE, Mancall EL, Richardson EP: Progressive multifocal leukoencephalopathy. *Brain* 81:93, 1958
- de Vries E: Postvaccinal Perivenous Encephalitis. New York, Elsevier Pub Co, 1960
- Ladisch S, Poplack DG, Holiman B, et al: Immunodeficiency in familial erythrophagocytic lymphohistiocytosis. *Lancet* 1:581, 1978