

# Posterior Internal Capsule Infarction Associated With Neglect

José M. Ferro, MD, Andrew Kertesz, MD, FRCP(C)

● A persistent hemispatial neglect developed in a patient following a small infarction of the posterior limb of the right internal capsule. This defect was restricted to tasks requiring spontaneous motor performance on the contralateral hemispace, especially when carried out under visual control. It was not associated with an extinction phenomenon. Verbal cues improved exploratory behavior, suggesting that hemispatial akinesia in this case was due to an intentional disorder. A pulvinar-parietal disconnection, depriving the right parietal cortex from relevant visuospatial information from the contralateral hemispace, was probably the anatomic basis of hemispatial neglect in this case.

(Arch Neurol 1984;41:422-424)

Neglect is classically associated with right parietal damage.<sup>1-4</sup> Lesions on a postulated corticolimbic-reticular loop<sup>5</sup>, which mediates selective attention, have also been shown to produce neglect. These include the dorsolateral frontal lobe,<sup>6-10</sup> cingulate gyrus,<sup>7</sup> striatum,<sup>10-15</sup> and thalamus.<sup>16-19</sup> These structures seem to play different roles in hemispheric activation and preparation to respond. Less information is available on the role of the white matter tracts that connect these anatomic sites.

We report a case of hemispatial neglect in a patient with a discrete lesion of the posterior limb of the right internal capsule.

## REPORT OF A CASE

A 61-year-old, right-handed, hypertensive, diabetic man was admitted to St Joseph's Hospital, London, Ontario, on July 28, 1982, because of the sudden onset of left-sided weakness. His BP was 210/120 mm Hg. Neurologic examination disclosed a complete left homonymous hemianopia,

left-sided facial weakness, and moderate left hemiparesis. There was a slight decrease in pinprick sensation on the left side but position, vibration, and light touch sensation were normal. There was no extinction on double simultaneous tactile stimulation. Reflexes were slightly brisker on the left and there was a left upgoing toe. The patient had a history of hypertension treated with propranolol hydrochloride and methyldopa. Despite intramuscular administration of hydralazine, the BP fluctuated between 200/110 and 160/90 mm Hg; that evening his hemiparesis worsened. The next morning there was complete paralysis on the left, mild left hypoesthesia, and decreased pinprick position and vibration sense, and the left lateral conjugate gaze was impaired. He had clear-cut left hemispatial neglect on drawing. A computed tomographic (CT) scan was performed that showed a small, non-enhancing lucency on the posterior limb of the internal capsule (Fig 1). This lesion crossed the line described by Mizukami et al<sup>20</sup> joining the genu of the internal capsule to the posterior end of the putamen. This indicated the posterior internal capsular location of the lesion. The thalamus was apparently uninvolved as the lesion was lateral to a line joining the posterior outer aspect of the frontal horn to the choroidal plexus.<sup>21</sup> A CT scan performed one year later showed the same lesion with the lucency extended to the parietal centrum semiovale. An EEG showed slow waves in right central leads. Angiograms were not made. An isotope brain scan performed on the 15th day after admission was normal.

## Neuropsychologic Examination

The patient received a comprehensive neuropsychologic assessment two weeks after his stroke. He was alert, fully oriented, and cooperative. His spontaneous speech was fluent and his performance on the language subtests of the Western Aphasia Battery (WAB)<sup>22</sup> was normal. His aphasia quotient was 96.3 (maximum, 100). The patient had no trouble reading letters or words, but reading sentences was laborious as he tended to omit the first (left-sided) words. Reading comprehension was normal when he was instructed to look to the left edge of the stimulus card. On writing he tended to use mainly the right half of the page. On copying a sentence the patient omitted the left half, while on dictation he made several neglect-induced paraphasias, mostly in the form of extra strokes on letters (with-wuth) or omission of the left half of letters (hammer-hammer). Praxis and calculation were not

impaired. On the drawing subtest of the WAB he scored 8 of 30 points. He used only the right half of the page and neglected the left half of a cube, clock, house, and tree (Fig 2). The patient could not duplicate any block designs and his score on the Raven's Coloured Progressive Matrices (RCPM) was only in the fifth percentile for his age. A tendency to neglect correct choices on the left part of the test pages contributed to his low score. He had no prosopagnosia as tested by 20 famous faces and he could recognize 13 of 15 familiar melodies.

The patient was aware of his defects and worried about them; he would cry easily when questioned about his stroke. He could identify affective speech (18/20). He could also recognize the emotional category of "affective situations" in drawings (14/16), but he was mildly impaired in the identification of emotional facial expressions (8/12).

## Neglect Testing

Neglect was further investigated with a comprehensive neglect testing battery that included visual, auditory, tactile, and motor simultaneous stimulation, cancellation and line bisection tests, tactile search, spatial representation, and visual spatial memory tests.

At rest the patient's eyes and head were on the midline, and on verbal command or pursuit the lateral gaze was full to the right and the left. Spontaneous gaze was more often directed to the right. Complete left hemianopia and left hemiplegia precluded motor and visual simultaneous stimulation testing. Simultaneous auditory stimulation was tested by placing a stethoscope on the patient's ears and gently tapping the membrane. On ten trials he reported the sound as bilateral in nine and as referred to the right ear only in one trial. He did not show extinction on simultaneous tactile stimulation. On unilateral right tactile stimulation he reported the stimuli to the right on five trials and both to the right and left on the remaining five trials. A similar behavior that could be labeled *inverted allesthesia* was described by Critchley<sup>4</sup> in a man with a right parietal neoplasm; Critchley suggested that this was a form of tactile hallucination.

On the cancellation test, where he was asked to cross out 20 lines distributed evenly on a test sheet, the patient failed to cross all the left ones while crossing seven of ten on the right. The line bisection test was modified from Schenkenberg et al.<sup>23</sup> A test sheet with six horizontal lines (lengths, 80, 120, 100, 120, 80, and 100 mm) having a block letter at each end<sup>24</sup> was placed in front

Accepted for publication Aug 13, 1983.

From the Department of Clinical Neurological Sciences, University of Western Ontario, St Joseph's Hospital, London (Drs Ferro and Kertesz); and the Department of Neurology, Hospital de St Maria, Lisbon (Dr Ferro).

Reprint requests to Department of Clinical Neurological Sciences, University of Western Ontario, St Joseph's Hospital, London, Ontario, Canada N6A 4V2 (Dr Kertesz).

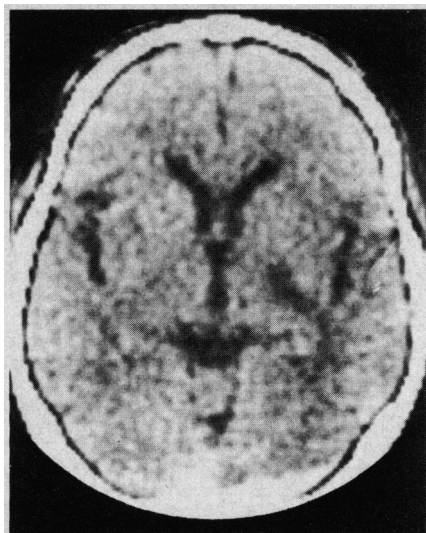


Fig 1.—Computed tomographic scan showing infarction on posterior limb of right internal capsule, involving retrolenticular and part of sublenticular and lenticulothalamic portions.

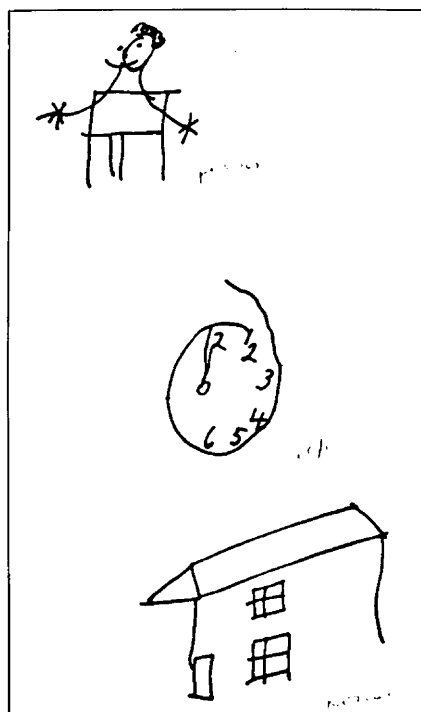


Fig 2.—Spontaneous drawing of person and copying of clock and house demonstrating left hemispatial neglect (three months after onset).

of the patient. The patient was asked to read the letters and then bisect the line. This procedure ensures that failure to bisect is not secondary to hemianopia or visual scanning deficit. The sum of right deviation on the bisection of the six lines was 70 mm (mean,  $11.7 \pm 8.2$  mm).

On a tactile search test the patient was shown a board with nine pegs (three on the right, three on the left, and three central). After he counted all of the pegs, he was blindfolded and asked to pick up the nine

Line Bisection Performance		
Experimental Condition	Total R Deviation on 6 Lines, mm	Mean ( $\pm$ SD) R Deviation, mm
2 wk after onset		
Lines on center, visual control	70	$11.7 \pm 8.2$
3 mo after onset		
Lines on left, visual control*	54, 52	$9.0 \pm 6.4, 8.7 \pm 3.9$
Lines on right, visual control*	5, 39†	$0.8 \pm 9.1, 6.5 \pm 9.7†$
Lines on center, visual control	58	$9.7 \pm 10.6$
Lines on center, somesthetic control	55	$9.2 \pm 13.2$

\* Measured on two occasions.

† Deviation was to the left.

pegs. The patient performed well on this task. The ability to recall spatial details of a familiar image was tested by asking the patient to imagine a map of Canada placed in front of him, and then asking him to name the provinces on the right and left parts of this imaginary map. The ability to recall the spatial location of recently presented visual stimuli was assessed by presenting a card with a horizontal row of six drawings of objects (used in the WAB). The patient, after naming all the drawings, was requested to recall (after a 20-s delay during which he had to count aloud the lines of the cancellation test) their spatial location. His performance was normal on both tests.

#### Follow-up Study

The patient was studied again three months after onset. He still had complete hemianopia and hemiplegia on the left, but his hemisensory loss had improved, especially for light touch and position sense. He did not complain of pain or dysesthesia.

On neuropsychologic examination, reading and writing were normal, although the patient continued to use mainly the right half of the page. The same behavior was observed on drawing, where his performance was improved, although he still showed neglect on drawing a person, clock, and house (Fig 2). He was still impaired on block design and on RCPM. Recognition of environmental sounds was perfect (15/15). He was worried and sad about his defects.

On the neglect testing battery there was no auditory or tactile extinction, and performance on the spatial representation, visual memory, and tactile search tests was normal. The patient missed only one left line on the cancellation task. However, he was still impaired on line bisection. Line bisection was worse when the lines were placed on the left hemisphere than when they were placed on the right. This was confirmed on two occasions (Table). Somesthetic cueing (following the lines with his right index finger before bisecting them) did not improve his performance.

The patient's ability to use his left hemisphere, without visual control and when explicitly requested to do so, was evaluated in the following tasks. He was blindfolded in both tests. In the first test he was asked to draw two crosses on a blank sheet placed in front of him, one on the left and the other on the right. Then he was requested to draw four other crosses below each of

the first ones. Crosses were drawn alternately on the left and right. The patient's performance was accurate and he did not demonstrate any tendency to right deviation. In the second test he was asked (while blindfolded) to draw three crosses on a blank sheet of paper placed in front of him. He succeeded in following the instructions that required him to draw one cross on the left, one on the right, and the third at mid-distance between the first two crosses. On four trials he only showed a tendency for right deviation (34 mm) on the central crosses, but this was within normal controls range ( $-5$  to  $45$  mm).

#### COMMENT

A typical and durable hemispatial neglect developed in our patient following a lesion of the posterior limb of the internal capsule. Hemispatial neglect disturbed reading and writing and was impressive on drawing, cancellation, and line bisection tests. This deficit was restricted to tasks requiring spontaneous motor performance under visual control on the contralateral hemisphere and was not associated with an extinction phenomenon.

Although this patient was hemianopic, his performance on line bisection could not be explained by his visual field defect, as he had to read the letters on the left side of each line prior to bisection. Tracing the lines with his fingers did not help him either. It could be argued that, although he saw the whole line, he quickly forgot the left part and then bisected the "remaining" right part. However, in the present case both remote and recent visual memory were spared as spatial details of the old and recent visual stimuli could be adequately recollected and described verbally, suggesting also that his mental representation of space was intact.

Heilman and Valenstein<sup>24</sup> proposed that hemispatial neglect is secondary to a hypokinesia for any act that must be performed in the neglected hemispatial field. Like the patients of Heilman and Valenstein, our patient's performance on line bisection was worse when the lines were placed in

the left hemispace. Hemispatial akinesia was present mostly when the motor exploratory activity was carried out under visual control. When direct visual control was removed and the patient used an internal representation of space, particularly on tasks where verbal instructions specified that the patient should describe or explore the left and right parts of the presented stimuli, neglect was no longer present. This superiority of verbal cues over free-style performance was also noted by Diller and Weinberg,<sup>25</sup> Laplane et al,<sup>19</sup> and Bisiach et al.<sup>26</sup> The fact that verbal cues can act as "external volition" and improve exploratory behavior suggests that hemispatial akinesia in this case is due to an intentional disorder, a defect of the will to explore the contralateral halfspace and not to a loss of the motor programs for the distribution of movements within extrapersonal space.

Healton et al,<sup>13</sup> Bisiach et al,<sup>26</sup> and Kertesz and Dobrowolski<sup>10</sup> reported cases of deep central lesions causing neglect. In some cases the internal capsule was damaged in association with other structures (thalamus, lenticular nucleus). In the present case it is unlikely that neglect was caused by temporary dysfunction (diaschisis)<sup>27</sup> of neighboring structures such as the nucleus reticularis (NR) of the thalamus because neglect was still present three months after onset. Furthermore, the usual clinical features of the thalamic syndrome were absent.

Several ascending and descending pathways run through the posterior limb of the internal capsule or are in close anatomic relation to it.<sup>28</sup> Those include the pyramidal, corticorubral, and temporo-pontine tracts, and auditory, visual, and thalamic radiations. The thalamic radiation includes fibers connecting the posterior part of the ventral nuclei of the thalamus with the somesthetic sensory cortex, nonspecific thalamic fibers projecting from the NR to the multimodal parietal cortex, and corticothalamic fibers, namely, collaterals to the NR.<sup>17</sup> The retrolenticular portion includes efferent connections from the pulvinar<sup>29</sup> to the multimodal parietal cortex. Thalamolenticular connections,<sup>30</sup> which are important to motor activation and preparation to respond, also cross the internal capsule.

In our patient, the thalamometathalamic connections with the visual and somesthetic areas and with the multimodal parietal cortex appeared to be important. The internal capsule lesion probably deprived the postero-

parietal cortex of visual information from ipsilateral visual associative areas (by damaging optic radiation) and the pulvinar. Valenstein et al<sup>31</sup> were able to produce nonsensory neglect from parietotemporal lesions in monkeys. Electrophysiologic studies have demonstrated that some posteroparietal cells fire before a motor response to a relevant stimulus is made.<sup>32,33</sup> Based on these findings, Mountcastle et al<sup>33</sup> proposed that the posteroparietal association cortex commands operations within extrapersonal space. The principal visual input to the posteroparietal lobule comes from the pulvinar.<sup>34</sup> A pulvinar-parietal disconnection was probably the anatomic basis of hemispatial neglect in our patient. The compensating effect of verbal cues suggests that the left hemisphere is able to activate the right parietal lobe and the motor exploratory programs toward the contralateral halfspace through intact interhemispheric connections. In the series by Bisiach et al, patients showing a disruption of the left half of the conscious representation of outside space had large corticosubcortical lesions involving the parietal lobe.<sup>26-35</sup> Preservation of the parietal lobe explains why our patient could describe accurately the left half of recollected images.

This study was supported in part by the Instituto Nacional de Investigação Científica, Portugal (Dr Ferro), and Ontario Heart Foundation grant 3-33 (Dr Kertesz).

#### References

1. Brain WR: Visual disorientation with special reference to lesions of the right cerebral hemisphere. *Brain* 1941;64:224-272.
2. Hécaen H, Penfield W, Bertrand C, et al: The syndrome of apraxognosia due to lesions of the minor cerebral hemisphere. *Arch Neurol Psychiatry* 1956;75:400-434.
3. McFie J, Piercy MF, Zangwill OL: Visual-spatial agnosia associated with lesions of the right cerebral hemisphere. *Brain* 1950;73:167-190.
4. Critchley M: *The Parietal Lobes*. London, Edward Arnold Ltd, 1953.
5. Heilman KM: Neglect and related disorders, in Heilman KM, Valenstein E (eds): *Clinical Neuropsychology*. New York, Oxford University Press, 1979, pp 268-307.
6. Silberpfennig J: Contribution to the problem of eye movements. *Confin Neurol* 1941;4:1-13.
7. Heilman KM, Valenstein E: Frontal lobe neglect in man. *Neurology* 1972;22:660-664.
8. Castaigne P, Laplane D, Degos JD: Trois cas de négligence motrice par lésion frontale prérolandique. *Rev Neurol* 1980;18:123-132.
9. Chain F, Chedru F, Leblanc M, et al: Renseignements fournis par l'enregistrement du regard dans les pseudo-hémianopsies d'origine frontale chez l'homme. *Rev Electroencephalogr Neurophysiol Clin* 1972;2:223-232.
10. Kertesz A, Dobrowolski S: Right-hemisphere deficits, lesion size and location. *J Clin Neuropsychol* 1981;3:283-299.
11. Heir DB, Davis KR, Richardson ET, et al: Hypertensive putaminal hemorrhage. *Ann Neurol* 1977;1:152-159.
12. Damasio AR, Damasio H, Chui HC: Neglect following damage to frontal lobe or basal ganglia. *Neuropsychologia* 1980;18:123-132.
13. Healton EB, Navarro C, Bressman S, et al: Subcortical neglect. *Neurology* 1981;31:62.
14. Valenstein E, Heilman KM: Unilateral hypokinesia and motor extinction. *Neurology* 1981;31:445-448.
15. Ferro JM, Martins IP, Pinto F, et al: Aphasia following right striato insular infarction in a left handed child: A clinico-radiological study. *Dev Med Child Neurol* 1982;24:173-182.
16. Watson RT, Heilman KM: Thalamic neglect. *Neurology* 1979;29:690-694.
17. Watson RT, Valenstein E, Heilman KM: Thalamic neglect: Possible role of the medial thalamus and nucleus reticularis in behavior. *Arch Neurol* 1981;38:501-506.
18. Schott B, Laurent B, Maugiere F, et al: Negligence motrice par hématomie thalamique droit. *Rev Neurol* 1981;137:447-455.
19. Laplane D, Escourrolle R, Degos JD, et al: La négligence motrice d'origine thalamique. *Rev Neurol* 1982;138:201-211.
20. Mizukami M, Nishijima M, Kin H: Computed tomographic findings of good prognosis for hemiplegia in hypertensive putaminal hemorrhage. *Stroke* 1981;12:648-652.
21. Matsui T, Hirano A: *An Atlas of the Human Brain for Computerized Tomography*. Tokyo, Igaku-Shoin Ltd, 1978.
22. Kertesz A: *The Western Aphasia Battery*. New York, Grune & Stratton Inc, 1982.
23. Schenkenberg T, Bradford DC, Ajax ET: Line bisection and unilateral visual neglect in patients with neurological impairment. *Neurology* 1980;30:509-517.
24. Heilman KM, Valenstein E: Mechanisms underlying hemispatial neglect. *Ann Neurol* 1979;5:166-170.
25. Diller L, Weinberg J: Hemi-inattention in rehabilitation: The evolution of a rational remediation program, in Weinstein EA, Friedland RP (eds): *Advances in Neurology*. New York, Raven Press, 1977, vol 18, pp 63-82.
26. Bisiach E, Capitani E, Luzzatti C, et al: Brain and conscious representation of outside reality. *Neuropsychologia* 1981;19:543-551.
27. Von Monakow C: *Die Lokalisation im Grosshirn und der Abbau der Funktionen durch corticale Herde*. Wiesbaden, Germany, Bergmann, 1914.
28. Ranson SW, Clark SL: *The Anatomy of the Nervous System*. Philadelphia, WB Saunders Co, 1959.
29. Trojanowski JW, Jacobson S: Areal and laminar distribution of some pulvinar cortical efferents in rhesus monkey. *J Comp Neurol* 1976;169:371-392.
30. Kalil K: Patch-like termination of thalamic fibers in the putamen of the rhesus monkey: An autoradiographic study. *Brain Res* 1978;146:145-150.
31. Valenstein E, Heilman KM, Watson RT, et al: Nonsensory neglect from parietotemporal lesions in monkeys. *Neurology* 1982;32:1198-1201.
32. Hyvarenen J, Poranen A: Function of the parietal associative area 7 as revealed from cellular discharges in alert monkeys. *Brain* 1974;97:673-692.
33. Mountcastle VB, Lynch JC, Georgopoulos A, et al: Posterior parietal association cortex of the monkey: Command functions for operations within extrapersonal space. *J Neurophysiol* 1975;38:875-908.
34. Yin TC, Mountcastle VB: Visual input to the visuomotor mechanisms of the monkey's parietal lobe. *Science* 1977;197:1381-1383.
35. Bisiach E, Luzzatti C, Perani D: Unilateral neglect, representational schema and consciousness. *Brain* 1979;102:609-618.