

Chorea as a manifestation of epidural hematoma

Case report

JOHN R. ADLER, M.D., AND KEN R. WINSTON, M.D.

Department of Neurosurgery, Children's Hospital, and Department of Surgery (Neurosurgery), Brigham and Women's Hospital and Harvard Medical School, Boston, Massachusetts

✓ A child with epidural hematoma presented with choreiform movements which promptly resolved following the evacuation of the hematoma.

KEY WORDS • epidural hematoma • chorea • head injury

THERE have been several reports of chronic subdural hematoma associated with extrapyramidal movement disorders.^{1-4,6-8} In each, a causal relationship between the two was implied by the eventual resolution of symptoms following evacuation of the hematoma. An adolescent patient with what is believed to be the first documented case of chorea resulting from an epidural hematoma is the subject of this report.

Case Report

This 16-year-old boy was found unconscious on the gymnasium floor moments after an unwitnessed fall from a vaulting horse. The patient could not be aroused for less than a minute, after which he became fully alert. In the hospital emergency room the patient had a normal neurological examination and therefore was sent home. Over the ensuing 24 hours, he complained of mild headache, appeared lethargic, and vomited several times, after which both the emesis and lethargy resolved. Because of persistent right frontal headache, he took several aspirin. Approximately 48 hours after the accident, his headache worsened and his parents noted "shaky movements" in his upper and lower extremities. In addition, his gait became increasingly unsteady and his speech, which was normally dysarthric secondary to congenital deafness, became even less intelligible. Further progression of the extraneous movements precluded his feeding himself and led to such an extreme impairment in gait that he needed to be carried when he came into the emergency room.

The patient's past medical history is notable for syndactyly of both of his feet and his left hand, which

had been surgically reconstructed. He also had dysmorphic facies as well as congenital deafness. This constellation of congenital anomalies did not fit any known genetic disorder. His full-scale intelligence quotient was reported to be in the average range.

Examination. The patient was mildly drowsy but oriented to person and place. He was agitated and was slow in responding to commands. His speech was slow and dysarthric. There were no external signs of head trauma, and his neck was supple. Cranial nerves were normal except for the congenital hearing deficit. There was no papilledema. Motor function examination revealed normal muscle tone and power. Reflexes were normal except for bilateral Babinski signs. The patient's voluntary movements, which were slow and poorly sustained, were accompanied by symmetrical arrhythmic involuntary jerky movements involving his neck and all extremities. These continuous choreiform movements incapacitated volitional activity. The patient was not able to sit or stand independently because of the overwhelming choreiform movements in his lower extremities. The remainder of the physical examination was unremarkable except for the dysmorphic facies and syndactyly.

Computerized tomography demonstrated a large right parietal epidural hematoma (Fig. 1). There was effacement of the lateral ventricle with a shift of the midline structures toward the left.

Operation. While being taken to the operating room, the patient developed signs of progressive right uncal herniation with a dilated right pupil and a left hemiparesis. A 3 cm-thick epidural hematoma was

Chorea with epidural hematoma

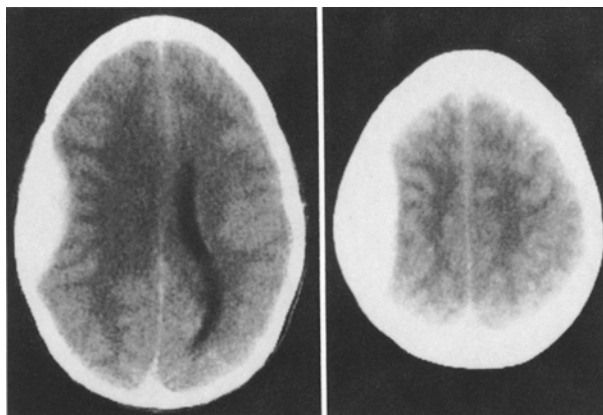


FIG. 1. Computerized tomography scans demonstrating a right parietal biconvex area of density (epidural hematoma) which effaced the right lateral ventricle and shifted midline structures to the left.

promptly evacuated via a right parietal craniotomy. An undisplaced linear parietal skull fracture was noted. After recovery from anesthesia, the patient had no choreiform movements. He was discharged home on the 3rd postoperative day.

Discussion

Choreiform movements were the most striking feature in the presentation of this teenage patient with acute epidural hematoma. Because of the prompt cessation of choreiform movements following surgery and in the absence of evidence for any of the other known causes of movement disorders, we believe that the intracranial hematoma and the movement disorder were causally related. Extraparapyramidal movement disorders accompanying subdural hematomas have been described. Martin⁵ reported a patient with recent onset of right hemiballismus who was found at autopsy to have a right subdural hematoma. Samiy⁶ described a patient with right parkinsonism and a left frontal chronic subdural hematoma. His patient's right-sided cogwheel rigidity and resting tremor improved after evacuation of the hematoma. Sandyk and Kahn⁷ reported the case of a woman whose generalized parkinsonism resolved gradually upon removal of a left-sided subdural hematoma.

The first case of choreiform movements associated with an extracerebral hematoma was described by Bean and Ladisch² in a 12-year-old boy with leukemia. The boy had immediate resolution of his generalized extrapyramidal symptoms following evacuation of a left hemispheric subdural hematoma. There are also accounts of bilateral chorea which improved after evacuation of bilateral subdural hematomas.^{1,4} The associ-

ation between subdural hematoma and choreiform movements in the patient reported by Gilmore and Brenner³ may have been coincidental, because the movement disorder appeared 3 months after the removal of the subdural hematoma.

Direct mechanical pressure and/or torsion of the basal ganglia by a hemispheric mass might, in itself, cause dysfunction of these nuclei.⁷ Martin⁵ postulated that displacement of the brain by subdural hematoma impaired circulation in the posterior cerebral artery, leading to ischemia of the subthalamic nuclei. Gilmore and Brenner³ attributed the extrapyramidal movements which accompanied subdural hematoma to tentorial herniation which injured the basal ganglia. Signs of uncal herniation in our patient suggest that mechanical pressure on blood vessels near the tentorial hiatus may have a role in this presentation of extracerebral hematomas. The rapidity with which the choreiform movements in our patient both appeared and were alleviated by surgery reinforces the above hypothesis. It is reasonable to postulate that such herniation may be accompanied by an impairment in blood flow to the basal ganglia via the posterior cerebral arteries.

We suspect that the rarity of this presentation for extracerebral hematomas derives from the requirement for a critical anatomical arrangement of the blood vessels at the base of the brain with respect to the tentorial hiatus. We cannot exclude the possibility that our patient, who had several congenital anomalies, also had abnormalities in the brain or cranium which, in some way, predisposed to this peculiar presentation of an acute epidural hematoma.

References

1. Bae SH, Vates TS Jr, Kenton EJ III: Generalized chorea associated with chronic subdural hematomas. *Ann Neurol* 8:449-450, 1980
2. Bean SC, Ladisch S: Chorea associated with a subdural hematoma in a child with leukemia. *J Pediatr* 90:255-256, 1977
3. Gilmore PC, Brenner RP: Chorea: a late complication of a subdural hematoma. *Neurology* 29:1044-1045, 1979
4. Kotagal S, Shuter E, Horenstein S: Chorea as a manifestation of bilateral subdural hematoma in an elderly man. *Arch Neurol* 38:195, 1981
5. Martin JP: Hemichorea (hemiballismus) without lesions in the corpus luyisii. *Brain* 80:1-10, 1957
6. Samiy E: Chronic subdural hematoma presenting a parkinsonian syndrome. *J Neurosurg* 20:903, 1963
7. Sandyk R, Kahn I: Parkinsonism due to subdural hematoma. Case report. *J Neurosurg* 58:298-299, 1983
8. Vincent FM: Chorea: a late complication of a subdural hematoma. *Neurology* 30:335-336, 1980 (Letter)

Manuscript received August 8, 1983.

Address reprint requests to: Ken R. Winston, M.D., Department of Neurosurgery, Children's Hospital Medical Center, 300 Longwood Avenue, Boston, Massachusetts 02115.