

Neglect in Children

José M. Ferro, MD,* Isabel Pavão Martins, MD,* and Luis Távora, MD†

Three children developed neglect following right-hemispheric lesions. In the first, computed tomography (CT) demonstrated a striatoinfilar infarction. In the second, CT revealed a large meningioma compressing the right hemisphere, and in the third, CT revealed two intracerebral hemorrhages in the right posterior parietal and occipital lobes. Neglect in these children produced a clinical picture comparable to that occurring in adults, but there was a rapid and complete recovery. The paucity of reports of neglect in children may be a function of the rapid recovery, the phenomenon being missed if not looked for in the acute stage. We conclude that, at least for children aged 6 years or more, the right hemisphere is dominant for directed selective attention.

Ferro JM, Martins IP, Távora L: Neglect in children. *Ann Neurol* 15:281–284, 1984

In human adults neglect reflects a disturbance in the spatial distribution of directed attention and has been associated with lesions of the inferior parietal and dorsolateral frontal lobes, cingulate and supplementary motor gyrus, striatum, and thalamus [8, 10]. These are interconnected areas whose lesions, according to Heilman [8], interrupt a cortical-limbic-reticular loop that mediates orienting responses and arousal to meaningful stimuli presented in the contralateral hemisphere.

In childhood neuropsychological studies of acquired unilateral hemispheric lesions have focused mainly on left hemispheric and language disturbances, and except for a case briefly described by Hécaen [5], no mention of neglect is made in several other studies [1, 2, 8, 10, 11]. We report three cases of neglect in children, induced by right hemispheric lesions.

Case Reports

Patient 1

A 6-year-old left-handed girl suddenly developed nonfluent aphasia, left hemiparesis, and left hypesthesia for touch, pain, and postural sensation. On visual confrontation testing, a left hemianopia was detected. She did not respond to threatening gestures from the left side, and she failed to notice people coming or talking to her from the left. Conjugate eye movements were full, both to verbal commands and pursuit. When writing with her right hand, she demonstrated a typical spatial dysgraphia. She neglected the left half of sentences or words, and lines of writing showed variable degrees of inclination. She tended to use only the right part of the paper, and she separated letters by leaving blank spaces between them. Her performance was slightly better on dictation than on copying. Visuoconstructional ability was also impaired. On Benton's Visual Retention Test (form C) she often omitted or distorted the left peripheral figures. She also showed a typical

pattern of left visual inattention on a cancellation test. In this test (Fig 1) the patient is asked to cross out all the lines drawn in three rows on a sheet of paper placed in front of her. Although she could always detect left unilateral somatic stimulation, on simultaneous tactile stimulation she failed to notice stimuli on the left. On a dichotic listening task (pairs of nouns), she demonstrated a left-channel extinction.

A computed tomographic (CT) scan performed on the sixth day of illness demonstrated a right paraventricular infarction involving the internal capsule and insula, and the lentiform nucleus and a small area of white matter over it. This lesion produced no perifocal edema or mass effect (Fig 2). Right carotid angiogram showed corkscrew irregularities in the supraclinoid segment of the internal carotid artery and in the proximal part of the middle and anterior cerebral arteries suggestive of fibromuscular dysplasia. Two weeks later hemispatial neglect, as well as visual, auditory, and tactile extinction, had disappeared. Aphasia was also improved. Writing to dictation was better, but the patient still demonstrated spatial errors (confused lines) when reading sentences aloud.

Patient 2

A 9-year-old boy with idiopathic thrombocytopenic purpura was admitted to the hospital because of gum bleeding, generalized cutaneous petechiae, and ecchymoses. Platelet count was 15,000 per cubic millimeter on admission and remained low despite platelet transfusions and steroid therapy. Four days later the patient had several generalized seizures, complained of headache and drowsiness, and vomited. Neurological examination disclosed a mild left-side weakness and sensory loss. Electroencephalogram showed right hemispheric slowing, and computed tomographic (CT) scan demonstrated two right intrahemispheric hemorrhages, one posterior parietal and one occipital, associated with edema (Fig 3).

The patient was treated with anticonvulsant agents and

From the Departments of *Neurology and †Neurosurgery, Neurobehavioral Unit, Centro de Estudos Egas Moniz, Hospital Santa Maria, Lisbon, Portugal.

Received Apr 14, 1983, and in revised form Aug 8. Accepted for publication Aug 13, 1983.

Address reprint requests to Dr Ferro, Neurobehavioral Unit, Centro de Estudos Egas Moniz, 1600 Lisbon, Portugal.

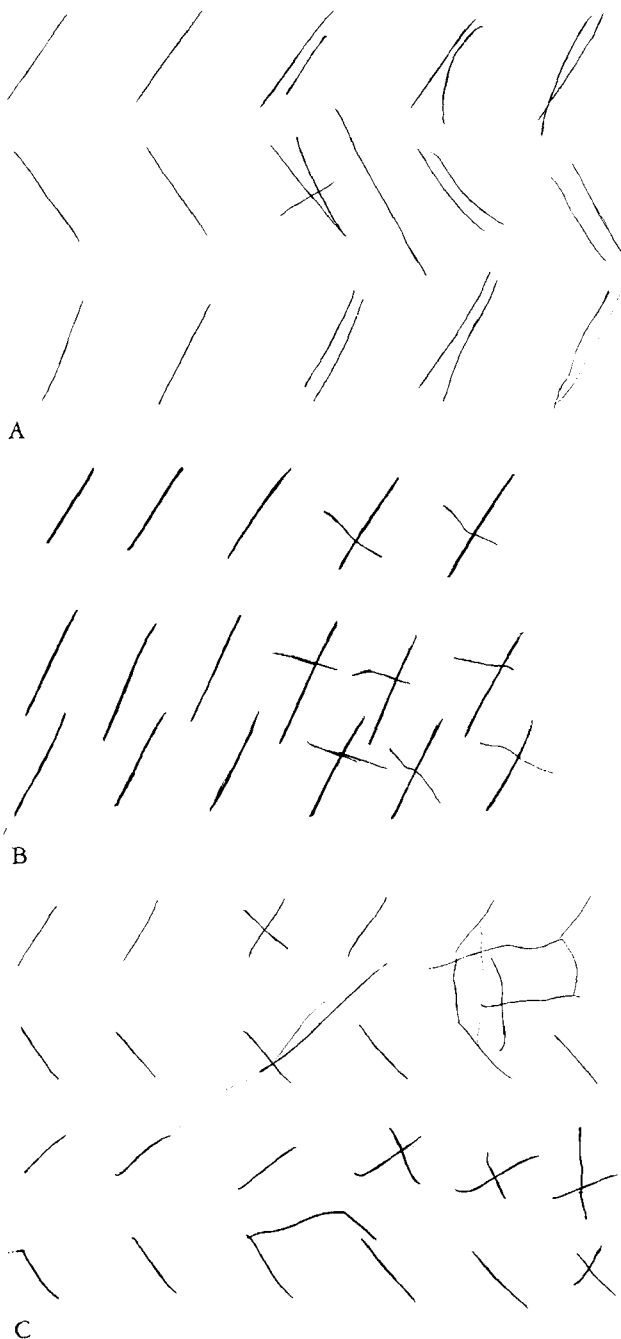


Fig 1. Performance on cancellation tasks. (A) Patient 1; (B) patient 2; (C) patient 3. Patients failed to notice lines drawn on the left half of the test sheet.

anticerebral edema medications and received repeated platelet transfusions. Bleeding stopped, and on the next day he became fully alert. Left-side weakness and hypesthesia were less evident, but a crossing-out task performed at bedside disclosed left hemispatial inattention (see Fig 1). One month after admission, findings on general neurological examination were normal. There was no extinction on simultaneous visual, tactile, or auditory stimulation. Performance on dichotic listening tests, constructional tasks, cancellation and line bisection tests, spontaneous drawing, and tactile

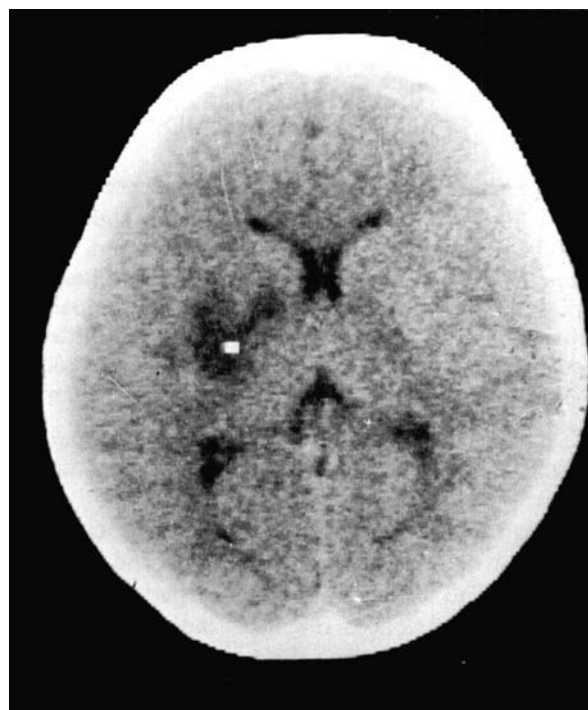


Fig 2. Computed tomographic scan of patient 1, demonstrating hypodense area in right hemisphere, involving the internal capsule and lenticular nucleus.

searching was normal. Mean simple visual reaction time was 26.1 ± 3.5 (SD) ms for the right hand and 30.1 ± 5.6 for the left, a significant difference ($t = 3.32$, $p < 0.01$), and on Benton's Judgment of Line Orientation Test (form V), the patient scored 1 SD below the mean. CT scan showed a residual hypodense right posterior parietal lesion.

Patient 3

A 5-year-old right-handed boy was admitted to the hospital because of vomiting, malaise, restlessness, and episodes of nocturnal fecal and urinary incontinence that had started 15 days before. For five months the child had been less active, showing no interest in playing or drawing. He had increasing difficulty in dressing. Neurological examination revealed an alert but easily fatigable child. Language was unimpaired. Ocular fundi were normal. There was a slight left hemiparesis and a left facial hypalgesia. The left plantar response was extensor, and there was a moderate truncal ataxia and left-side deviation when walking.

He presented a severe visuospatial disability: his performance on Benton's Visual Retention Test and his spontaneous drawing of a human figure were poor. He demonstrated left hemispatial neglect on cancellation and line bisection tasks (see Fig 1). His performance following simultaneous tactile stimulation was normal. On a task of repeated movements with both hands, the left hand tended gradually to stop. On a dichotic listening test he presented a left-channel extinction.

A CT scan revealed a very large hyperdense mass occupying most of the right cranial cavity that enhanced homogeneously with contrast. The mass had almost collapsed the

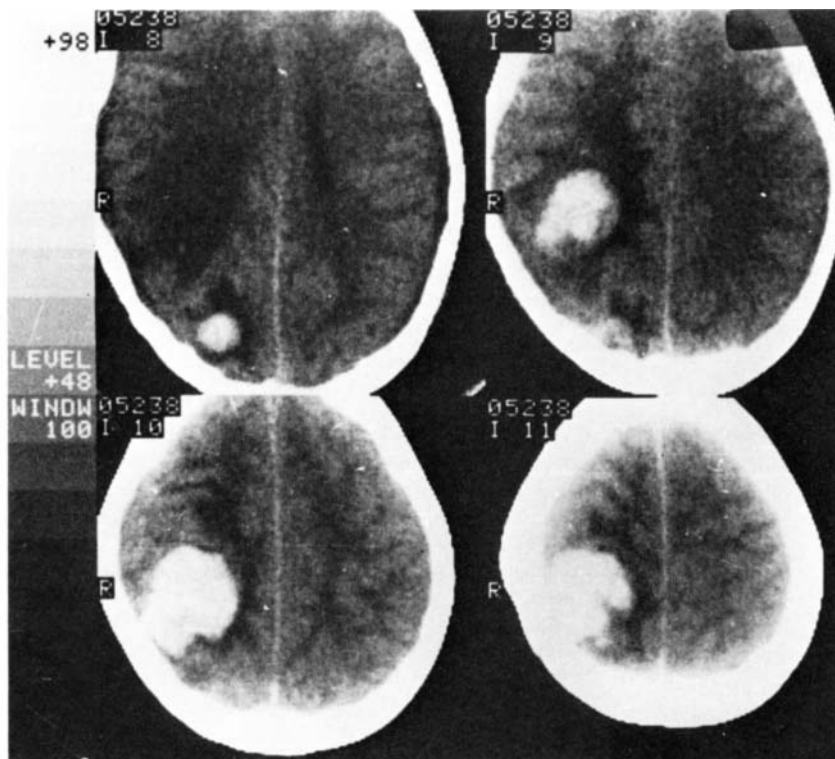


Fig 3. First computed tomographic scan of patient 2. Note two hyperdense areas in the right hemisphere, posterior parietal and occipital, associated with grade II edema.

right hemisphere and had produced marked midline shift (Fig 4). Right cerebral arteriography showed a medial displacement of the sylvian arteries by a relatively vascular mass. The tumor, which proved to be a fibroblastic meningioma, was removed in two stages. Two days before the second operation a bedside cancellation test no longer showed evidence of neglect. Spontaneous drawing was still poor.

One month postoperatively muscle strength, sensory and visual field findings, and performance on cancellation and line bisection tests were normal. His performance on the Visual Retention Test was improved. He still presented a left-channel extinction on dichotic listening tests but no extinction on simultaneous tactile or visual stimulation. The left hand no longer stopped moving in a task requiring simultaneous hand movements.

Discussion

Neglect in these three children resembled that observed in adults with similarly localized lesions. All had right hemispheric lesions. Although patient 1 was left handed and her right hemisphere was probably dominant for language, she presented a typical "nondominant syndrome" consisting of left-side neglect, constructional apraxia, and spatial dysgraphia. In adult sinistrals neglect is also much more common with right than with left hemispheric lesions [6]. Lesion location was also similar to that of lesions that produce neglect

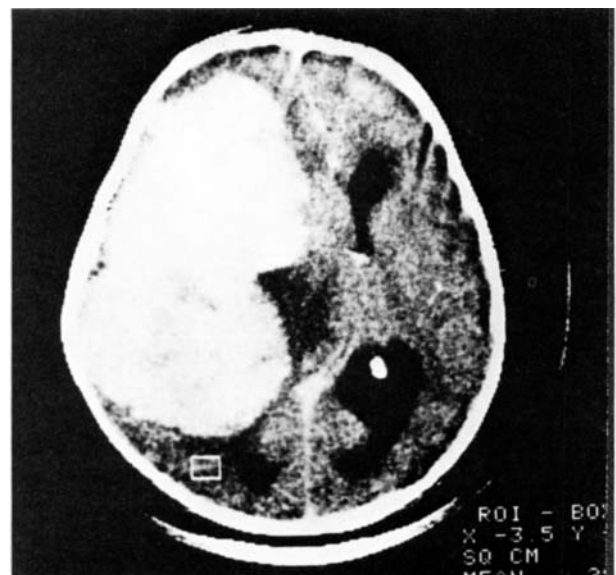

Fig 4. Computed tomographic scan of patient 3, demonstrating a very large hyperdense mass occupying most of the right cranial cavity that enhanced homogeneously with contrast.

in adults [7, 9]. Occipital and posterior parietal lesions (patient 2) are a well-established anatomical correlate of neglect, and a few reports [3, 4] describe neglect following striatal infarcts (as in patient 1).

In regard to the clinical signs, we note that on the visual modality all patients ignored stimuli in the left hemispace, showing hemispatial neglect on a cancella-

tion test. Patient 1 also showed left extinction on simultaneous tactile stimulation, and patients 1 and 3 a left-channel extinction on a dichotic listening test. In patient 1, whose lentiform lesion spared the geniculotemporal and the intertemporal pathways, this pattern can be interpreted as left auditory inattention.

The paucity of reports of neglect in children may have several causes: (1) In series of childhood hemispheric lesions, in which hemianopia has been a frequent finding, neglect could have been attributed to visual field defects [1, 8, 9]. (2) In other series of right brain-damaged children, no tests for visual neglect are mentioned [1, 2, 8, 10, 11]. (3) Neglect in children may be transient and show rapid recovery, and thus be overlooked if not searched for during the acute stage. Indeed, in our patients neglect was present only during the acute stage and disappeared quickly. Recovery from neglect was faster than that from aphasia. (4) It is possible that the rarity of neglect in children stems from a lack of right hemispheric dominance for attention. In adults the right parietal lobe is said to attend to both hemispaces, whereas the left parietal lobe attends only to the right hemisphere [7, 9]. If in children both hemispheres were equipotential for attention and could react to both hemispaces, unilateral lesions would not cause the striking disturbance of attention that occurs in adults. This interpretation is not supported by the present findings, however. At least for children aged six years or more, the right hemisphere appears dominant for directed selective attention.

The authors thank Drs R. Morris and K. M. Heilman for their most helpful suggestions and criticism, and Maria de Fátima Pereira for typing the manuscript.

References

1. Basser LS: Hemiplegia of early onset and the faculty of speech with special reference to the effects of hemispherectomy. *Brain* 85:427-460, 1962
2. Carter S, Gold AP: Acute infantile hemiplegia. *Pediatr Clin North Am* 14:851-864, 1967
3. Damasio AR, Damasio H, Chang Chui H: Neglect following damage to frontal lobe or basal ganglia. *Neuropsychologia* 18:123-132, 1980
4. Heaton ED, Navarro C, Bressman S, Brust JCM: Subcortical neglect. *Neurology (NY)* 32:776-778, 1982
5. Hécaen H: Acquired aphasia in children and the ontogenesis of hemispheric functional specialization. *Brain Lang* 3:114-134, 1976
6. Hécaen H, Sauguet J: Cerebral dominance in left-handed subjects. *Cortex* 7:19-48, 1971
7. Heilman KM: Neglect and related disorders. In Heilman KM, Valenstein E (eds): *Clinical Neuropsychology*. New York, Oxford University Press, 1979, pp 268-307
8. Isler W: Acute Hemiplegia and Hemis syndromes in Childhood. *Clinics in Developmental Medicine*, Vols 41-42. Philadelphia, Lippincott, 1971
9. Mesulam M-M: A cortical network for directed attention and unilateral neglect. *Ann Neurol* 10:309-325, 1981
10. Woods BT, Teuber H-L: Changing patterns of childhood aphasia. *Ann Neurol* 3:273-280, 1978
11. Woods BT: The restricted effects of right-hemisphere lesions after age one: Wechsler test data. *Neuropsychologia* 18:65-70, 1980