

However, serum prolactin was elevated as well, which also would suggest altered hypothalamic regulation. Without evidence of a primary structural pituitary lesion, these hormonal changes are more likely to be caused by interference with normal inhibitory control exerted by corresponding hypothalamic factors.

Our patient showed a favorable biochemical and clinical response to bromocriptine with the exception of somatomedin C levels, which remained elevated during treatment. Levels of growth hormone and prolactin fell to within the normal range, and carbohydrate homeostasis was restored. Thyroid-stimulating hormone levels were unchanged. These hormonal effects suggest that bromocriptine can restore hypothalamic-pituitary feedback mechanisms produced by a primary childhood hypothalamic disturbance.

Bromocriptine, an ergot derivative with dopamine receptor agonistic actions, has been used to treat adult pituitary tumors and acromegaly [5, 7, 13, 16]. Although its primary site of action is believed to be in the pituitary gland [9], a direct hypothalamic effect has also been suggested [16]. The efficacy of bromocriptine in lowering serum prolactin seems well established, but its role in inducing biochemical and clinical improvement in acromegaly recently has been questioned [6]. Its part in reducing pituitary tumor size following bromocriptine administration is equally uncertain [13].

The possibility that our patient's tumor was functionally active and secreting a growth hormone-releasing peptide is a consideration. The association between carcinoid tumors and acromegaly has been recognized [13, 14]; in addition, a peptide has been characterized, and its ability to stimulate growth hormone release from human somatotrophic adenoma *in vitro* has been demonstrated [15]. However, because of the concomitant alterations in prolactin level in our patient, we favor a "functional geographic" effect with dual action, leading to decreased somatostatin secretion, exaggerated growth hormone release, and a decrease in "prolactin inhibiting factor."

## References

1. Costin G: Endocrine disorders associated with tumors of the pituitary and hypothalamus. *Pediatr Clin North Am* 26:15-31, 1979
2. Costin G, Fefferman RA, Kogut MD: Hypothalamic gigantism. *J Pediatr* 83:419-425, 1973
3. Dabek JT: Bronchial carcinoid tumor with acromegaly in two patients. *J Clin Endocrinol Metab* 38:329-333, 1974
4. Fienman NL, Yakovac NC: Neurofibromatosis in childhood. *J Pediatr* 76:339-346, 1970
5. Kobberling J, Blossey HC, Dirks H, Mayer G: More on bromocriptine in acromegaly. *N Engl J Med* 306:748, 1982
6. Lindholm J, Riishede J, Vestergaard S, et al: No effect of bromocriptine in acromegaly. *N Engl J Med* 304:1450-1454, 1981
7. McGregor AM, Scanlon MF, Hall K, et al: Reduction in size of a pituitary tumor by bromocriptine therapy. *N Engl J Med* 300:291-293, 1979
8. Parker JC, Smith JL, Reyes P, Vuksanovic MM: Chiasmal optic

- glioma after radiation therapy. Neuro-ophthalmologic/pathologic correlation. *J Clin Neuro Ophthalmol* 1:31-43, 1981
9. Parkes D: Bromocriptine. *N Engl J Med* 301:873-878, 1979
10. Riccardi VM: Von Recklinghausen's neurofibromatosis. *N Engl J Med* 305:1617-1627, 1981
11. Richardson RR, Noronha A, Leetsma J, Siqueira EB: Multiple neoplastic associations with central and peripheral Von Recklinghausen's disease. *South Med J* 73:1074-1077, 1980
12. Rosman NP, Pearce J: The brain in multiple neurofibromatosis (Von Recklinghausen's disease): a suggested neuropathological basis for the associated mental defect. *Brain* 90:839-850, 1967
13. Salti IS, Istfan N: Bromocriptine fails to stop growth of eosinophilic adenomas in acromegaly. *N Engl J Med* 301:386, 1979
14. Sonksen PH, Ayers AB, Braimbridge M, et al: Acromegaly caused by bronchial carcinoid tumors. *Clin Endocrinol (Oxf)* 5:503-513, 1976
15. Webb CB, Thominet JL, Frohman LA: Ectopic growth hormone releasing factor stimulates growth hormone release from human somatotroph adenomas *in vitro*. *J Clin Endocrinol Metab* 56:417-419, 1982
16. Zervas NT, Martin JB: Management of hormone-secreting pituitary adenomas. *N Engl J Med* 302:210-214, 1980

## Transfer of Language Dominance

Henry Lee, MD, Tsutomu Nakada, MD,  
Jon L. Deal, PhD, Stan Lin, MD, and Ingrid L. Kwee, MD

It has been suggested that recovery from aphasia may depend on the ability of the nondominant hemisphere to subserve language functions. We describe a patient who illustrates a possible "transfer" of language dominance. The patients sustained two infarcts two years apart, one in each hemisphere, involving mirror image territories in the temporoparietal area. The clinical course of each infarct was almost identical, consisting of an initial Wernicke's aphasia which evolved into anomia during recovery.

Lee H, Nakada T, Deal JL, Lin S, Kwee IL:  
Transfer of language dominance.  
*Ann Neurol* 15:304-307, 1984

Recovery from aphasia is a complex and mechanistically poorly understood process [4]. We report a case of recurrent aphasia following a right temporoparietal infarct in a right-handed patient who earlier had suffered a stroke in the left hemisphere. The findings in this patient suggest a transfer or resumption of language function in the right hemisphere.

From the Department of Neurology, University of California, Davis, and the Veterans Administration Medical Center, Martinez, CA.

Received July 18, 1983, and in revised form Aug 12. Accepted for publication Aug 13, 1983.

Address reprint requests to Dr Lee, Department of Neurology, University of California, Veterans Administration Medical Center, 150 Muir Rd, Martinez, CA 94553.

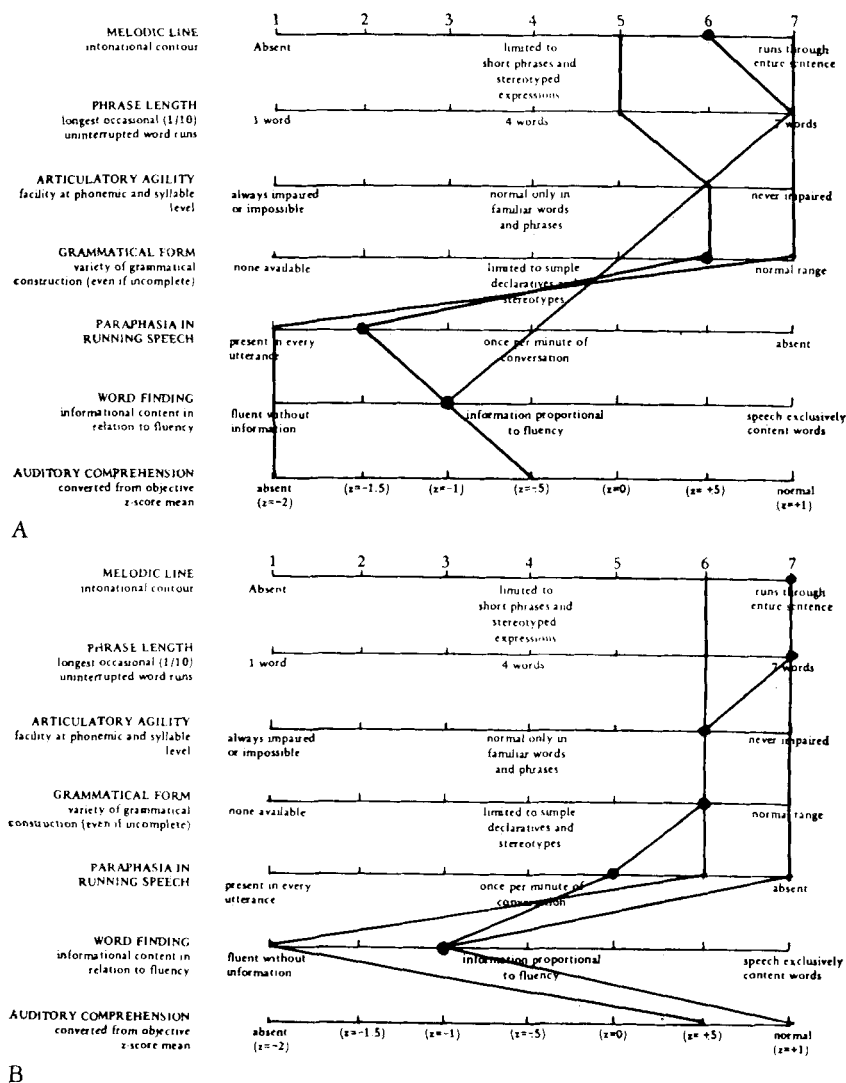


Fig 1. Rating scale profile of speech characteristics on Boston Diagnostic Aphasia Examination. (A) Initial testing, in the first week of hospital admission, resulted in a profile compatible with that of a patient with Wernicke's aphasia. (B) The profile on follow-up testing, three months after admission, was compatible with that of a patient with anomic aphasia.

A 57-year-old, right-handed man was admitted one week after sudden onset of difficulty in understanding spoken and written language. Two years earlier he had suffered a left hemisphere stroke and aphasia. The aphasia was described as being of a Wernicke's type initially, which evolved into mild anomia over a six-month period.

On neurological examination, the patient's speech was fluent with circumlocutions and moderate word-finding difficulty. There was no finger agnosia or right-left confusion. Results of cranial nerve examination were within normal limits except for mild lower facial weakness on the right side. The patient's strength was normal. He showed a slight pronator drift on the right side of the body. Sensory examination showed a subtle hypesthesia on the right side. Two-point discrimination, graphesthesia, and stereognosis were intact.

The patient's gait and results of cerebellar examination were normal. Deep tendon reflexes were normal with bilateral flexor plantar responses.

In the first week of hospital admission the patient was tested using the Boston Diagnostic Aphasia Examination (BDAE) [2a]. The auditory comprehension z score was -0.5. He had particular difficulty with sequential common and complex material. He was able to repeat single words, but sentence repetition, especially repetition of low probability sentences, was impaired. Numerous verbal and some literal paraphasias were noted. The patient experienced some difficulty with the naming sections of the test. Ability to copy was intact, but writing to dictation was moderately impaired. Reading comprehension was mildly impaired. The BDAE profile was that of a patient with Wernicke's aphasia (Fig 1A).

On follow-up examination, three months after admission, the auditory comprehension z score was +0.75. The patient was able to follow all but the most complex commands exactly, and comprehension of complex material had improved notably. Sentence repetition, especially repetition of low probability sentences, was more accurate. The frequency of literal and verbal paraphasias had decreased markedly. Naming had improved. The patient's reading comprehension and

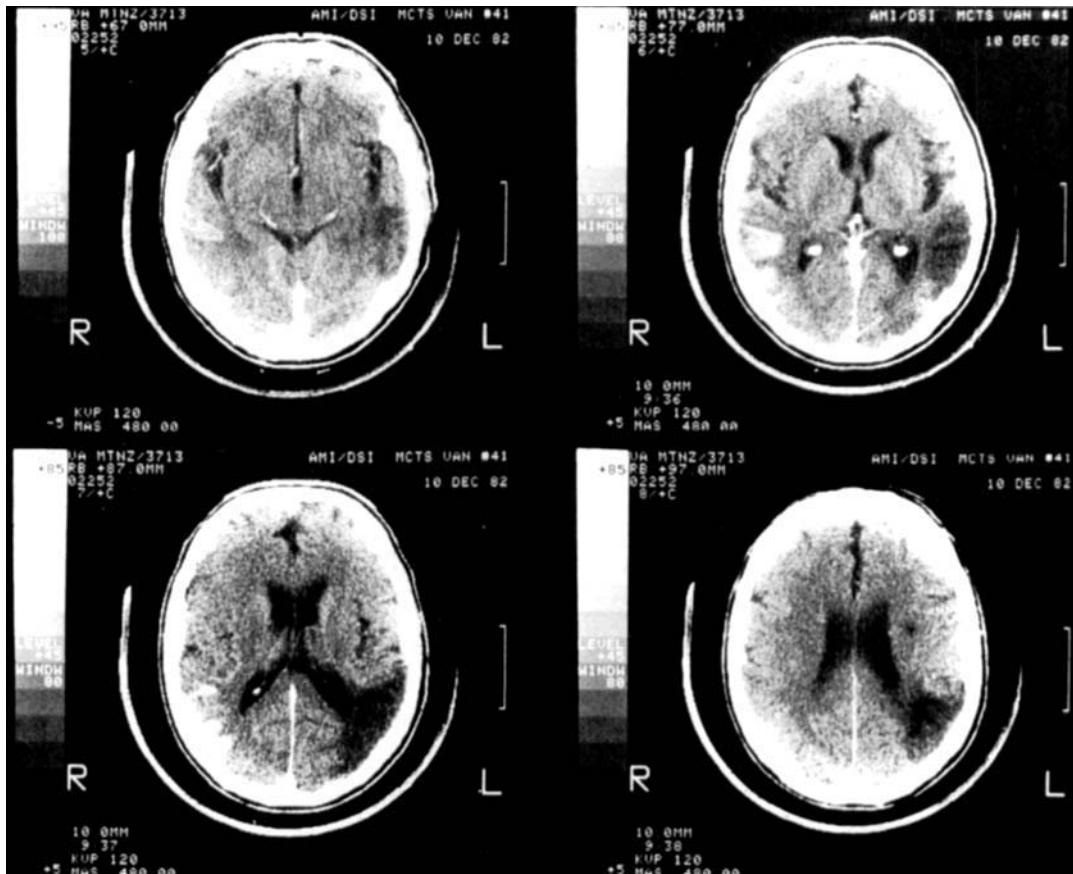


Fig 2. Computed tomography with contrast enhancement shows an old infarct in the left temporoparietal region and an acute enhanced infarct in the right temporoparietal region.

writing to dictation had improved slightly. The BDAE profile was most compatible with that of a patient with anomic aphasia (Fig 1B).

Computed tomography (CT) on the fourth day of admission showed an old left temporoparietal infarct involving the left angular and posterior temporal artery territories. Following infusion of contrast material, cortical enhancement was noted in the right angular and posterior temporal artery territories, indicating a recent infarct (Fig 2).

### Discussion

The role of the nondominant hemisphere in linguistic function remains a controversial issue. It is thought to have a minor role in language function, involving mainly the emotional aspect, or prosody of language [9, 10, 12]. However, the capacity of the nondominant hemisphere for developing a major function in language following injury in the dominant hemisphere has been observed [3, 5–8]. Studies of patients who underwent commissurotomy reveal that the right hemisphere has simple vocabulary and some grammatical capability [2]. It is more capable of semantic than phonetic information processing and has some plasticity for acquiring certain language functions generally believed to belong to the left hemisphere [11]. The patient described by Cummings and colleagues [1] re-

covered partially from global aphasia following an embolic infarct involving both Wernicke's and Broca's areas as demonstrated by CT. These authors suggested that a "transfer" of language function to the right hemisphere was the basis of the recovery observed.

Our patient presumably illustrates this transfer phenomenon. Alternately, he may be part of that 15% of the population that apparently possesses bilateral language representation in the hemispheres. Another possible explanation is that the new infarct seen on the CT scan was accompanied by a fresh lesion on the left that was not seen on CT, but which was responsible for exacerbation of the aphasia. This explanation seems unlikely. Whether the recurrence of Wernicke's aphasia with a new right hemisphere lesion represents damage to a transferred language function or to a preexisting right hemisphere language capacity cannot be determined, however.

A question of equal importance is the mechanism of recovery from the second occurrence of aphasia. Several hypotheses can be derived from this case: (1) the

area of infarct in this patient is not the primary area for storing the language function, but rather the secondary area, which activates the primary language storage area; (2) a "third" area capable of acquiring the language function is present in this patient; or (3) recovery from the second aphasia resulted from healing of the lesion itself. The answers to these questions await further studies.

### References

1. Cummings JL, Benson DF, Walsh MJ, Levine HL: Left-to-right transfer of language dominance: a case study. *Neurology* 29:1547-1550, 1979
2. Gazzaniga MS, Volpe BT, Smylie CS, et al: Plasticity in speech organization following commissurotomy. *Brain* 102:805-815, 1979
- 2a. Goodglass H, Kaplan E: *The Assessment of Aphasia and Related Disorders*, Philadelphia, Lea & Febiger, 1972
3. Henschen SE: *Klinische und anatomische Beiträge zur Pathologie des Gehirns*. Vols 5-7. Stockholm, Nordiska Bokhandlin, 1922
4. Kertesz A: Recovery and Treatment. In Heilman KW, Valenstein E (eds): *Clinical Neuropsychology*. New York, Oxford University Press, 1979, pp 503-524
5. Kinsbourne M: The minor cerebral hemisphere as a source of aphasic speech. *Arch Neurol* 25:302-306, 1971
6. Lenneberg EH: *Biological Foundations of Language*. New York, John Wiley & Sons, 1967, pp 142-158
7. Luria AR: *Restoration of Function after Brain Injury*. London, Pergamon Press, 1963
8. Nielson JM: *Agnosia, Apraxia, Aphasia*. New York, Paul B Hoeber, Inc, 1936, pp 93-241
9. Ross ED: The aprosodias. *Arch Neurol* 38:561-569, 1981
10. Ross ED, Mesulam MM: Dominant language functions of the right hemisphere? *Arch Neurol* 36:144-148, 1979
11. Sidtis JJ, Volpe BT, Wilson DH, et al: Variability in right hemisphere language function after callosal section: evidence for a continuum of generative capacity. *J Neurosci* 1:323-331, 1981
12. Tucker DM, Watson RT, Heilman KM: Discrimination and evocation of affectively intoned speech in patients with right parietal disease. *Neurology* 27:947-950, 1977