

Language Disturbance

An Initial Symptom of Cortical Degenerations and Dementia

Howard S. Kirshner, MD; Wanda G. Webb, PhD; Mark P. Kelly, PhD; Charles E. Wells, MD

● Six patients manifested progressive language disturbance, resembling aphasia secondary to a focal dominant hemisphere lesion, as either an isolated initial symptom or a prominent early feature of a more generalized dementing illness. None had a history of transient ischemic attacks or stroke, and in all cases an extensive clinical and laboratory investigation failed to show either a focal brain lesion or a definable etiology of dementia. This article discusses the relationship of isolated or early aphasia to known dementing syndromes. Patients who consult physicians for language disturbance should be evaluated and followed up both for evidence of progressive language deterioration and for the development of a generalized dementia.

(*Arch Neurol* 1984;41:491-496)

Dementia has attracted widespread interest in recent years because of its frequency and tragic consequences for patients, families, and society as a whole. Definitions of dementia have stressed the global or diffuse deterioration of cognitive functions due to diffuse anatomic disease of the brain.¹ Language impairment, while recognized as one aspect of this global deterioration, has not traditionally received emphasis in bedside mental

status examinations or in discussions of dementia. Recent surveys, however, have noted language dysfunction in a high proportion of demented patients.^{2,4} One study suggested that language deterioration may be a predictor of mortality in dementia,⁵ while another found language tests among the most useful cognitive measures in distinguishing demented patients from normal senescent subjects.⁶

In this study, a subset of patients is described in whom language disturbance was either an isolated initial symptom or a prominent part of the more general cognitive deterioration of dementia. Only the progressive course identified the disease as degenerative. Our patients varied in age from 61 to 78 years, were right-handed, and had good premonitory reading and writing skills. None had a history of stroke or transient ischemic attacks. In all cases, extensive neurological and laboratory evaluation failed to show either a focal brain lesion or a definable cause of dementia.

METHODS

All patients underwent bedside testing of language and mental status, standard language testing with the Boston Diagnostic Aphasia Examination (BDAE),⁷ and neuropsychological testing. In some cases, the severity of the language deficits rendered most standard neuropsychological tests impossible to administer. Where feasible, subjects were tested with the Wechsler Adult Intelligence Scale (WAIS), the Wechsler Memory Scale, and a previously reported and standardized battery of specific cognitive tests.⁸ In some instances, additional tests were given, as mentioned.

The Table lists the test battery; references to individual tests can be found in a standard text.⁹ Medical evaluations included computed tomographic (CT) scans of the head, EEGs, and multiple blood tests, including determination of electrolyte values; renal, hepatic, and thyroid function tests; measurement of calcium and phosphate levels, as well as vitamin B₁₂ and folate levels; serologic tests for syphilis; and, in some cases, urine drug and heavy metal assays. Results of these tests, with the exceptions of the CT scans and EEGs, are mentioned only when abnormal. The CT scans were read by neuroradiological colleagues without knowledge of the study. All scans were interpreted as normal or as showing diffuse, symmetric atrophy, with the single exception of focal dilatation of the left sylvian fissure in the patient in case 3.

REPORT OF CASES

CASE 1.—A 69-year-old woman had noted the insidious onset five years earlier of halting speech, with frequent word substitutions and difficulty understanding others. She had consulted a number of physicians and had had two CT scans, a normal audiogram, and extensive speech therapy and neuropsychological evaluations. Her deficits progressed steadily to the point that she spoke little and understood little of what was said to her. She read well at first and communicated with her family largely in writing, but word substitutions had begun to creep into her written productions, and reading became more difficult. She maintained an excellent memory for dates, kept her own house, and did the cooking. Her medical history was remarkable for mild hypertension treated with hydrochlorothiazide, borderline diabetes, chronic low-back pain treated with ibuprofen, and a prior hysterectomy. She was also taking amitriptyline hydrochloride for possible depression.

Accepted for publication June 11, 1983.

From the Departments of Neurology (Drs Kirshner, Webb, and Wells), Hearing and Speech Sciences (Drs Kirshner and Webb), and Psychiatry (Drs Kelly and Wells), Vanderbilt University School of Medicine, Nashville, Tenn.

Reprint requests to Department of Neurology, Vanderbilt Medical Center South, 21st and Pierce Ave, Nashville, TN 37212 (Dr Kirshner).

Neuropsychological Test Battery

Wechsler Adult Intelligence Scale
 Wechsler Memory Scale
 Picture Absurdities (subtest of Stanford Binet Intelligence Scale)
 Benton Right-Left Discrimination Battery (portion)
 Spreen-Benton Apraxia Test (portion)
 Wells-Ruesch Memory Span for Objects Test (modification)
 Peabody Picture Vocabulary Test
 Sentence Production (subtest of the Minnesota Test for Differential Diagnosis of Aphasia)
 Finger Tapping Test (from the Halstead-Reitan battery)
 Stereognosis test

The physical and neurological findings were relevant only for an apical systolic cardiac murmur and behavioral deficits. She was a well-dressed, cooperative woman who spoke little and required several repetitions before comprehending even the simplest questions. She was oriented to the date and place, recalled three of three object names at five minutes, and named the past four US presidents. She copied geometric figures and performed written additions and subtractions without error.

On both the bedside and BDAE examinations, striking aphasic deficits were evident. The most severe deficit was the nearly total loss of auditory comprehension, resembling pure word deafness. She seemed to understand better if the examiner spoke softly rather than loudly. She was able to name most simple objects and colors, although often with literal paraphasic errors ("therm" for "thumb," "wen" for "pen," "tear" for "tie"). She could not reliably repeat even single words. She read silently and followed simple and even some multistage commands, but she seemed almost entirely unable to read aloud. Writing was mechanically neat and fluent, with some word substitutions and omissions.

Neuropsychological testing confirmed the language deficits, which had worsened considerably since a previous evaluation two years earlier. The severity of her language deficit made it impossible to administer standard tests such as WAIS. Despite the aphasic deficits, however, she showed sparing of some other abilities. She performed reading tests, including sentence and paragraph reading and the Peabody Individual Achievement Test, at above eighth-grade level. The Benton Visual Retention Test and Bender gestalt drawings were normal, suggesting normal memory and visual-constructional function. Nonverbal reasoning on the Raven's Progressive Matrices was impaired, but she had difficulty understanding the instructions. She identified nine of 13 common sounds (eg, bell, applause). Results of laboratory tests were unremarkable. The EEG was normal, with a background of predominantly low-amplitude beta activity. A CT scan showed minimal enlargement of the lateral ventricles and cortical sulci consistent with age (Fig 1).

CASE 2.—A 61-year-old man, whose unusual language deficit profile has been

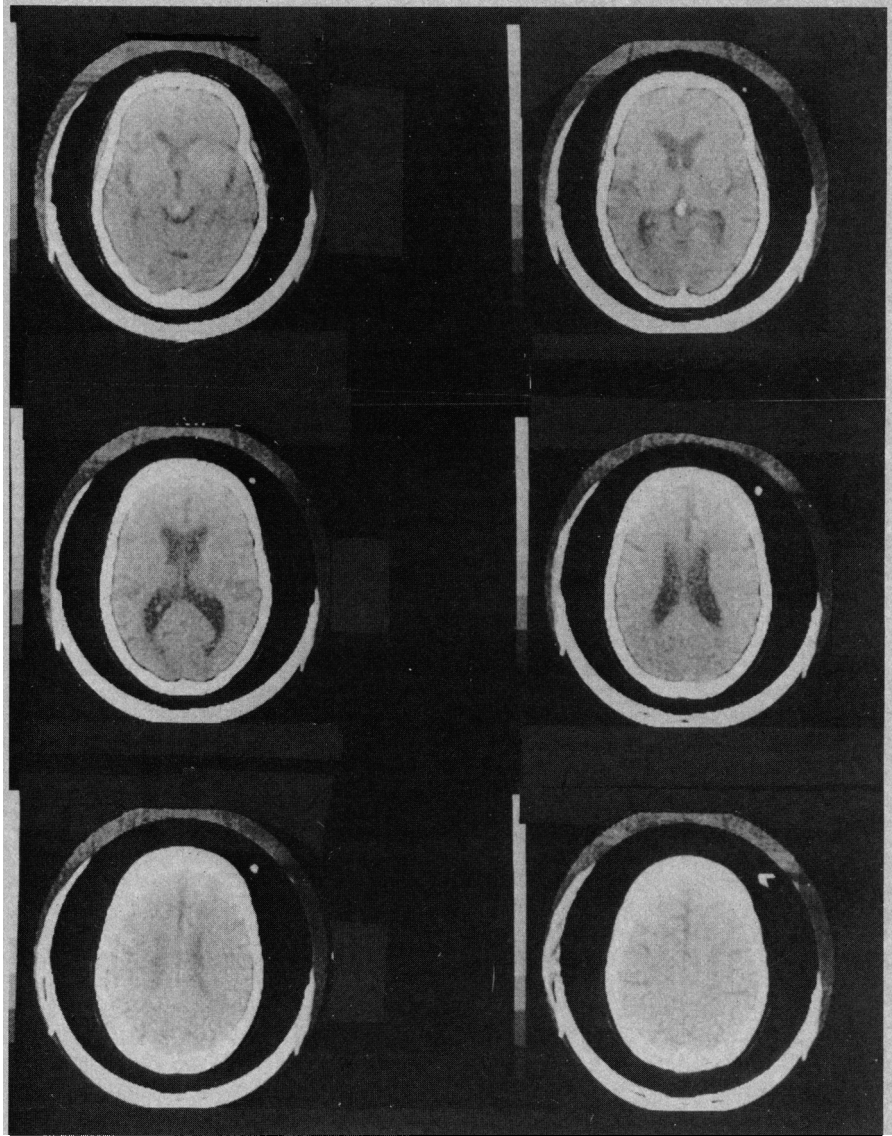


Fig 1.—Case 1. Computed tomographic scan of head. Cortical sulci and ventricular size are considered normal for patient's age.

reported previously,¹⁰ first noted a "stutter" and difficulty expressing himself after witnessing the cardiac resuscitation of his wife in 1976. He had previously been known to have a mild hearing loss, attributed to industrial noise exposure. Over the next two years, his stuttering became progressively worse, and his wife noted limited comprehension as well. Audiometry disclosed only mild bilateral high-frequency hearing loss. His history was otherwise unremarkable.

Physical and neurological findings were notable only for a thoracic kyphosis and language impairment. He was alert, fully oriented, well dressed, and cooperative. Memory, calculations, fund of information, and copying of geometric figures were intact on bedside testing.

The BDAE and bedside language examination showed severe aphasic deficits. As in case 1, the predominant deficit was in auditory comprehension, although other language modalities were also affected.

Spontaneous speech was characterized by the prefixing and suffixing of numerous extra syllables to words, resulting in a stuttering cadence, and by literal and verbal paraphasias. Naming was accurate. Auditory comprehension was severely deficient; he required several repetitions to perform even one-step commands. In contrast, he carried out even multistep printed commands, although mild deficits were noted in paragraph reading. He was able to repeat short, familiar phrases, but not longer phrases or polysyllabic words. He wrote from dictation and copied short sentences accurately.

Neuropsychological testing was remarkable largely for the language deficits, which rendered verbal tests impossible. In contrast, nonverbal skills were generally excellent. Nonverbal reasoning on the Raven's Colored Progressive Matrices was at the 90th percentile. Bender gestalt drawings were excellent. Nonverbal memory was entirely normal on both the Benton

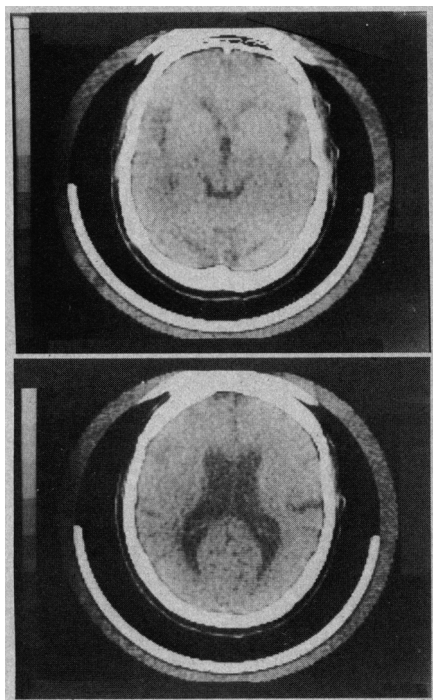


Fig 2.—Case 2. Computed tomographic scan of head. Generalized cortical atrophy and ventricular enlargement are evident.

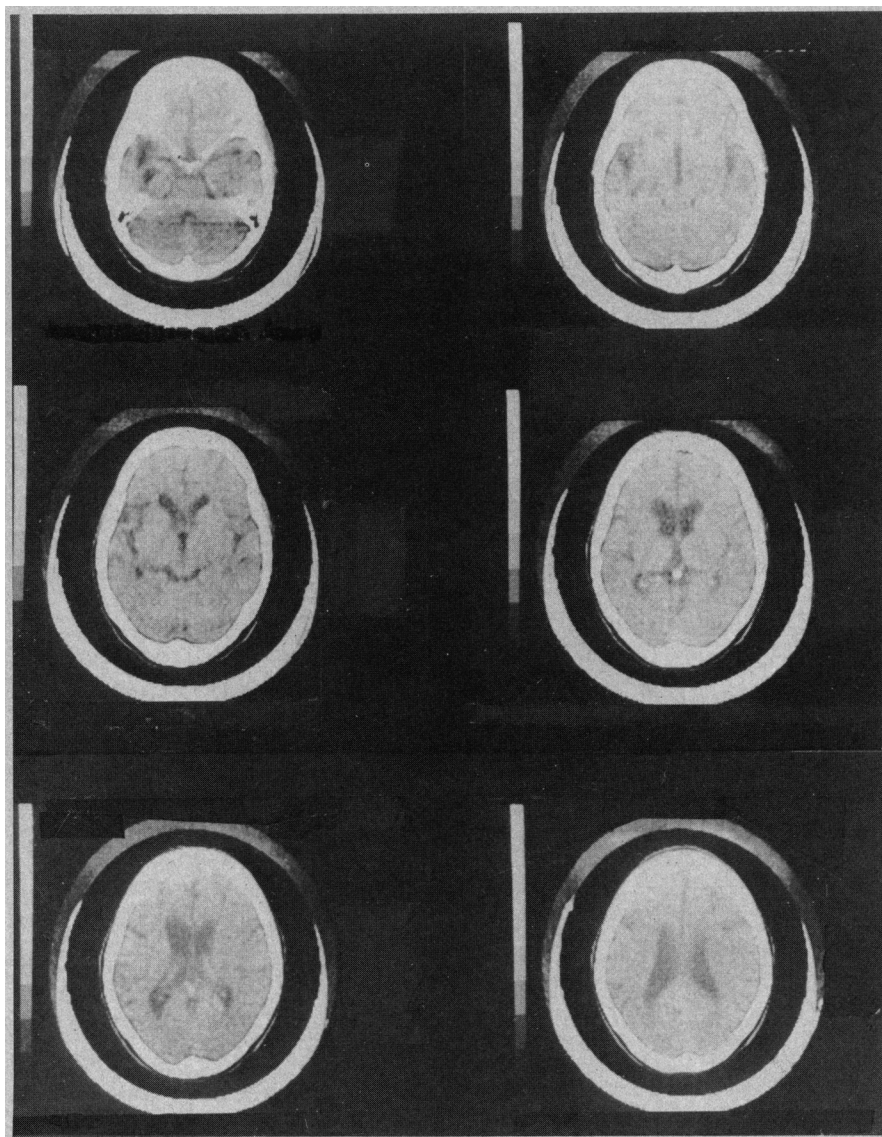


Fig 3.—Case 3. Computed tomographic scan of head. Asymmetric atrophy involving focal dilatation of left sylvian fissure is present.

Visual Retention Test and the Wells-Ruesch Memory for Objects Test. Manual dexterity on the Grooved Pegboard was better for the left hand ($T = 61$) than for the right ($T = 46$). The EEG was normal, with a waking alpha rhythm of 9 to 10 Hz and no asymmetries. A CT scan showed severe but symmetrical cortical atrophy and ventricular enlargement (Fig 2).

The patient was reevaluated in detail three times over the ensuing four years. His language performance continued to deteriorate, with total unintelligibility of speech, near-total loss of auditory comprehension, and increasing difficulty with reading and writing. His wife described mild forgetfulness at home. He remained well dressed and groomed, smiled and showed recognition of the examiner, and remained able to copy figures and draw a clock. Neuropsychological testing again showed normal performance on the Raven's Matrices, Bender gestalt drawings, and the Benton Judgment of Line Orientation Test. He now manifested impaired visual memory and learning on the Benton Visual Retention and Wells-Ruesch Memo-

ry for Objects tests. Two later CT scans and another EEG were unchanged.

CASE 3.—A 68-year-old woman had noted speech difficulty approximately two years before admission. Her husband first noted that she mixed up the names of family members and interchanged words like "he" and "she." In early 1980, she was admitted to a local hospital for an extensive evaluation; CT scan reportedly showed only cortical atrophy and enlarged ventricles. Her language difficulty gradually worsened over the ensuing 18 months, during which time she appeared to understand conversations, kept house, shopped, cooked, and did not seem forgetful. Her mood appeared to be happy, although with frustration over her inability to communicate. Her motor speech deteriorated to the point of stereotyped, repetitive phrases, with only occasionally meaningful single words. Her medical history was notable only for mild hypertension, which was under good control, and a prior hysterectomy.

The physical and neurological findings were remarkable only for cognitive deficits. The patient was well dressed and

groomed, smiled appropriately, and shook the examiner's hand. Testing of verbal memory and fund of information was not possible, but she recalled the locations of three hidden coins at five minutes. She copied a star and a clock accurately, but not a cube. She could not perform simple calculations aloud or on paper. Her behavior on the ward was described as appropriate, and she was fully independent in activities of daily living.

Severe aphasic deficits were evident on the BDAE and bedside examinations. Most of her speech consisted of stereotyped phrases such as "yes, right here, yes." She occasionally answered a question with a single word, such as her home town, "Florence," but she first said "Florida." Often, she misnamed the word, perseverated on an earlier word, or reverted to verbal stereotypies. She was unable to name objects, but frequently showed recognition by demonstrating their use or by pointing to other, similar objects. She followed only very simple one-step commands, either spoken or printed, usually carrying out only the first step of a dictated, complex command.

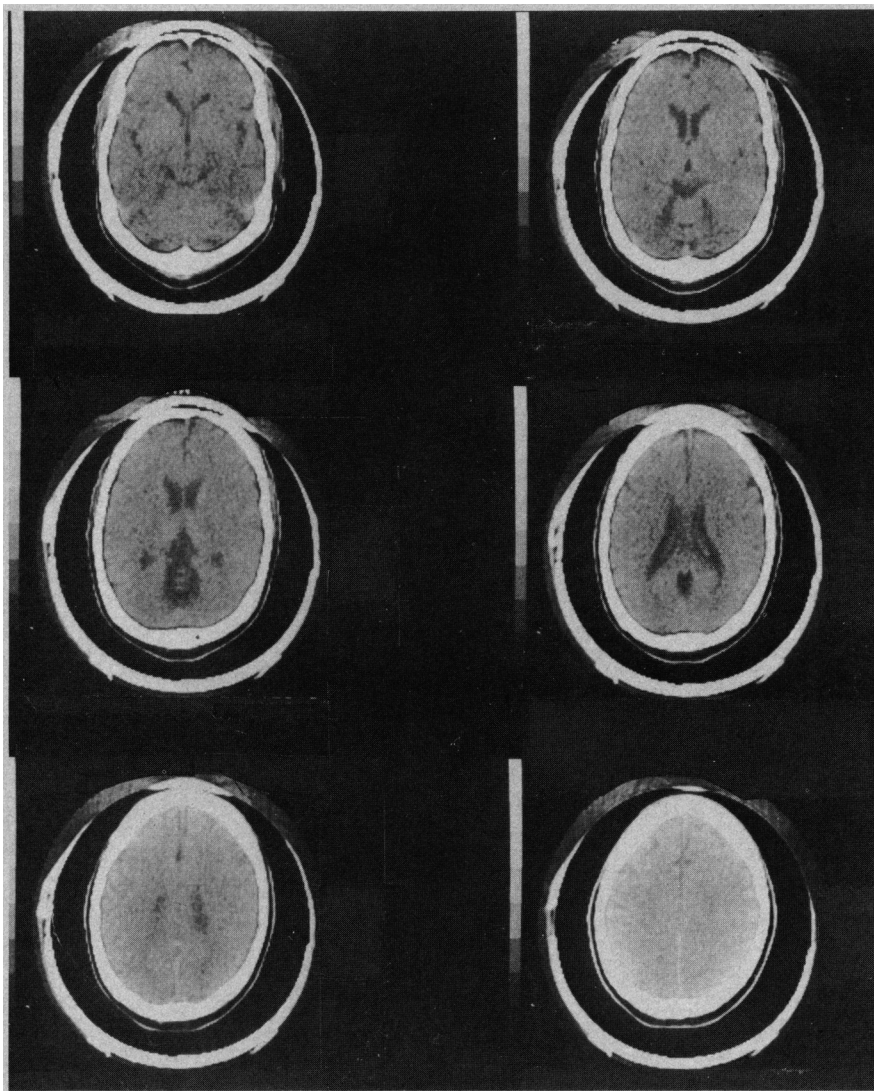


Fig 4.—Case 4. Computed tomographic scan of head. Mild cortical atrophy is evident. Dilatation of superior cerebellar cistern also suggests midline cerebellar atrophy.

She could not distinguish left from right. Attempts at reading aloud usually resulted in only one or two correct words. She could repeat only single words. She signed her name, but failed to write words to dictation.

Neuropsychological testing was attempted, but the patient was unable to comprehend or follow instructions not only for the WAIS, but also for the Benton Judgment of Line Orientation Test, the Benton Facial Recognition Test, the Benton Visual Retention Test, and the Raven's Progressive Matrices. The inability to comprehend or perform these tests indicated that the patient's deficit involved more than just language, yet her behavior suggested that extralinguistic deficits were considerably less severe than linguistic ones.

The CT scan showed mild, diffuse cortical atrophy, more pronounced in the area of the left sylvian fissure, with some dilatation of the left temporal horn and low temporal sulci (Fig 3). The EEG was within normal limits, without obvious asym-

metries. An audiogram demonstrated mild, bilateral, high-frequency sensorineural hearing loss. The laboratory evaluation was relevant only for a low serum vitamin B₁₂ level (170 and 201 pg/mL; normal, 200 to 900 pg/mL) and folate level (1.6 and 2.4 ng/mL; normal, 4 to 20 pg/mL). A Schilling test showed normal vitamin B₁₂ absorption and excretion, both with and without intrinsic factor.

CASE 4.—A 61-year-old male educator complained of difficulty with comprehension of written and spoken language. He claimed only a five-month history of this problem, but his wife described a more slowly progressive disorder over the previous two to three years. His supervisor had noted the patient's poverty of expression and reduced ability to explain himself or respond to questions at work. His medical history was negative for any serious illnesses. He did admit to moderate alcohol intake (two to four cocktails per day), but none in the preceding six months. The family history was material for a report of similar difficulty with memory and lan-

guage in his mother at about the same age. A brother was unaffected. The patient had been evaluated by two neurologists and a neurosurgeon before his initial visit, and two CT scans and a digital venous angiogram of the carotid arteries were reportedly normal.

The patient appeared to be healthy. General physical and neurological examinations disclosed only a question of mild weakness in the right leg, with symmetrical reflexes, flexor plantar responses, and no detectable sensory deficits. He was oriented to the date and place and showed good insight into his situation, although he appeared to be suspicious of physicians. He named the past three US Presidents, but recalled only two of three memory items at two minutes. Serial sevens and simple calculations were performed quickly and accurately. He copied figures well and constructed a clock.

The patient's speech was hesitant, but without paraphasic errors. Naming was deficient even for some common objects and for object parts. Repetition was accurate for familiar but not unfamiliar phrases. He followed two- and three-step commands, but required a slow speaking rate and repeated presentations. Comprehension and response to questions on dictated paragraphs on the BDAE were poor. Reading was slow, and performance of written commands and response to questions on paragraph reading were severely deficient. Writing and penmanship were preserved except for spelling errors.

Neuropsychological testing demonstrated a Wechsler full-scale IQ of 86, with verbal IQ of 69 and performance IQ of 110. Subtest results were strikingly split; verbal tests showed severe impairment, while nonverbal tests such as Block Design allowed normal performance. The Wechsler Memory Scale Memory Quotient (MQ) was 96, but memory for geometric figures was normal. Bender gestalt figures showed no constructional apraxia. Manual dexterity, tested by finger tapping, was mildly and symmetrically slowed.

A CT scan was within normal limits except for minimal enlargement of the frontal sulci, without gross ventricular enlargement, and disproportionate enlargement of the superior cerebellar cistern (Fig 4). A waking EEG was normal. The patient continued to progress in his cognitive deficits over the next six months. A repeated CT scan was unchanged.

CASE 5.—A 74-year-old woman was admitted for abnormal speech and forgetfulness of approximately eight years' duration, but more noticeable over the two years since her husband's death. Her daughter noted "nonsensical" speech, with frequent repetitions, and also a loss of interest in customary activities, failure to manage financial affairs, and, most recently, increasing difficulty with cooking and personal hygiene. Her medical history was relevant only for hypertension and cholelithiasis.

Physical and neurological findings were remarkable only for abnormal cognitive functions. She was well dressed, appropriate, and oriented to place and month, but

she had to consult a datebook for the date, year, name of her physician, her own address, and her telephone number. She failed to name the President or mayor, but described characteristics of each. Asked about Iran, she replied, "What's Iran?" She recalled none of three object names but three of three locations of hidden coins at five minutes. She could not perform such simple calculations as "10 minus 5." She repeated eight digits forward, two backward. She was able to copy simple geometric figures but not a cube, and she was inaccurate at locating cities on a map.

On language testing, the patient's speech was characterized by hesitations, circumlocutions, perseverations, and numerous paraphasic errors ("heavy" for "loud," "daughter" for "sister," "department" for "business"). She manifested a remarkably severe anomia, failing to name such common objects as watch, glasses, keys, and thumb. She often failed to choose the correct name from a group and occasionally asked for definitions of common words such as "envelope" and "hammer." She was totally unable to perform series naming (eg, animal names). She followed simple commands, but usually performed only the first step of a multistep command and frequently asked for repetitions and explanations. Some apraxia was evident, but she performed well to imitation or using the actual object. Repetition was adequate for common phrases only. She read aloud accurately, but could follow only the simplest printed commands. Writing was accurate only for copying and transcribing short, dictated phrases.

Neuropsychological testing confirmed a dementia, but with severe aphasic deficits. Full-scale IQ was 71; verbal, 68; performance, 78; and Wechsler Memory Scale MQ, 69. Bender gestalt drawings failed to show constructional apraxia. Manual dexterity on the Grooved Pegboard was severely impaired bilaterally. A CT scan showed mild, diffuse atrophy. The EEG was within normal limits.

CASE 6.—A 74-year-old woman was admitted for increasing difficulty with speech, first noted after a stressful altercation with her husband. She had a five-year history of mild forgetfulness and decreased attention to outside events and personal hygiene.

Her medical history included a motor vehicle accident 15 years earlier, with a right supraorbital skull fracture and development of minor seizures, for which she was treated with phenytoin, 300 mg/day, without recurrence. She was also under treatment with propranolol hydrochloride for a cardiac arrhythmia, but she had no history of myocardial infarction or hypertension.

The neurological findings were remarkable only for a moderate bilateral hearing loss and a snout response. She appeared to be well groomed, pleasant, and was oriented to the approximate date, but not to the name of the hospital. She recalled none of three objects at five minutes and repeated only three digits forward, one backward.

She could not recall the names of recent US Presidents, but related details about each. She was unable to perform simple calculations or serial subtractions. She appeared to have little insight into her deficits.

On bedside and BDAE language testing, the patient's speech was rambling, with frequent perseverations, abrupt changes of topic, and underrepresentation of meaningful nouns, often to the point of incoherence. She named several common objects but not parts of objects ("watchband," "shoelace"). She was totally unable to perform series naming; asked to produce a list of girls' names, she gave only the names of a sister, a cousin, and herself. She followed simple but not multistep commands. Repetition was intact for common phrases. She read aloud well, but followed only two of five printed commands, of which she had performed four to dictation. Her writing was full of misspellings.

The language and hearing deficits prevented most neuropsychological testing. Bender gestalt drawings showed a mild to moderate constructional apraxia. Testing of recent memory was attempted with the Benton Visual Retention Test, but she was unable to reproduce any of the figures.

The CT scan showed mild, generalized cortical atrophy. The EEG showed bilateral frontotemporal slowing, in the range of 4 to 6/s. Audiometry disclosed a bilateral high-frequency hearing loss.

COMMENT

All seven patients described herein manifested clinically important language disturbance as an isolated or prominent early symptom of a progressive neurological impairment. Language deficits seemed out of proportion to the level of generalized cognitive impairment in all patients. Patients 1 and 2 initially showed only language deficits; evidence of a more generalized disturbance developed only years later, and then only to a mild degree. Patient 3 showed progressive language dysfunction so severe that other cognitive functions could not be adequately assessed. In case 4, only language and verbal memory appeared to be affected. In cases 5 and 6, some degree of generalized dementia was demonstrated in the initial evaluation. Progression in all cases except possibly case 4 appeared to be leading toward a generalized dementia, but patients 1 and 4 would not have met clinical criteria for dementia at the time of their evaluation. All but patients 5 and 6 were functioning independently in a home setting and had no major difficulties with normal activities other than communication. In all cases, extensive clinical and laboratory evaluations failed to disclose either a focal lesion or a specific cause of dementia.

Language impairment has not been

widely recognized as an initial symptom of dementia. Horenstein¹¹ mentioned focal presentations of dementia, including aphasia, but did not provide detailed descriptions. Wechsler¹² described a 67-year-old man whose first symptoms were an apparently isolated aphasia with paraphasic speech, impaired repetition, and reduced comprehension. Only over the subsequent two years did personality changes, memory loss, stereotyped behavior, and evidence of a generalized dementia develop. A CT scan showed diffuse cortical atrophy, but also a more striking, focal dilatation of the left sylvian fissure, similar to that seen in our case 3. Recently, a postmortem examination was performed on this patient; the brain showed selective degeneration of the frontal and temporal lobes, the left more than the right, with microscopic changes consistent with Pick's disease.¹³ Wechsler et al¹³ suggested that an early presentation of language disturbance in dementia, particularly in the presence of intact parietal lobe functions, should raise the suspicion of Pick's disease, as should a focal left temporal atrophy on CT scan. While earlier studies of Pick's disease have described aphasic disturbances, and particularly anomia,^{14,15} isolated aphasia without other cognitive deficits has not been reported, to our knowledge. A possible exception is the family, described in an abstract by Cole et al¹⁶ in whom aphasia was the initial complaint in ten members of three generations with a dementia syndrome in which the pathological findings suggested Pick's disease, although Pick's bodies were not found.

Mesulam¹⁷ recently reported six cases of progressive aphasia without dementia, in five of which asymmetric left perisylvian atrophy was seen on CT scan. A biopsy specimen of the left superior temporal gyrus in one patient showed no diagnostic changes of either Alzheimer's or Pick's disease. Only two patients became demented, both seven or more years after the onset of aphasia. Mesulam suggested that this syndrome might represent a unique pathological entity of cortical degeneration with predilection for the left perisylvian region. One of his patients resembled our patients 1 and 2 in manifesting an almost pure word deafness.

Our patients suggest a spectrum from cases of isolated aphasia, such as those of Wechsler¹² and Mesulam,¹⁷ to more typical cases of dementia in which language disturbances parallel or follow other cognitive deficits. Sev-

eral descriptions have been reported of the more typical language disturbances seen in dementing illnesses. Alzheimer¹⁸ described paraphasic errors and disturbances of language in his original case report of the disease that now bears his name. Critchley,¹⁹ Stengel,²⁰ and Irigaray²¹ provided more detailed studies of language in dementia, and several recent reports^{6,22-24} have outlined the findings of standard language test batteries in demented patients. From these and other studies, a general picture of language dysfunction in dementia has emerged. Spontaneous speech typically remains fluent and composed of normal grammatical structure, although the content of speech becomes devoid of abstract content. In the words of Schwartz et al,²⁵ "The instrumentalities of language may remain intact, though no longer in the service of cognition." Naming becomes progressively impoverished, especially series naming. Repetition and reading aloud tend to remain preserved late into the illness, while reading comprehension and writing are usually affected early.

Our cases, along with those of Wechsler,¹² Cole et al,¹⁶ and Mesulam,¹⁷ indicate the variability of the type and degree of language disturbance seen in demented patients. The apparently isolated or prominent aphasia seen early in some patients may reflect focal atrophy of the left perisylvian language cortex, while the

more diffuse cognitive deficits seen in other patients may reflect a more diffuse anatomic involvement. When focal, the presentation may affect language, visuospatial function, or memory, depending on whether the process is localized to the left hemisphere, right hemisphere, or bilateral medial temporal regions. The exact type of pathological disorder that produces focal v diffuse brain degeneration, whether Alzheimer's disease, Pick's disease, or some heretofore unrecognized focal cortical degeneration, can only be speculated on from present evidence. Crystal et al²⁶ have recently reported a biopsy-proved case of Alzheimer's disease in which the initial symptoms were an isolated right parietal lobe syndrome, followed two years later by more diffuse cognitive dysfunction. Newer imaging techniques, such as cerebral blood flow or positron emission tomography (PET) studies, should be useful in outlining the anatomic areas affected. Gustafson et al²⁷ reported that demented patients with predominantly nonfluent speech had left frontal blood flow reductions, while those with more severe comprehension difficulty had left temporoparietal hypoperfusion. Foster et al²⁸ described decreased glucose metabolic activity in the right hemisphere by PET scanning in three patients with dementia and "disproportionately severe constructional apraxia," while one patient with a severe aphasic deficit showed de-

creased activity in the left temporoparietal area.

The patients described in this report underline the importance of language deficits in dementia and confirm that language disturbance can be an initial symptom. Patients who consult physicians for progressive language disturbance should be evaluated not only for focal lesions but also for more diffuse cognitive dysfunction, and they should be followed up carefully for the development of dementia.

Since this manuscript was submitted, patient 2 was admitted to the Nashville Veterans Administration Medical Center. His condition was unchanged, but a CT scan appeared to show more prominent atrophy around the left than the right sylvian fissure. Patient 4, when last examined, manifested generalized amyotrophy, with findings suggestive of motor neuron disease, in addition to worsening of his language deficits. He was admitted for evaluation but died the next day. At postmortem examination only mild, diffuse cerebral and cerebellar atrophy was evident. Microscopic studies of the brain revealed no specific changes of Alzheimer's disease, Pick's disease, or spongiform degeneration.

This research was supported in part by Teacher Investigator Development Award 5 K07NS00429-04 to Dr Kirshner from the National Institute of Neurological and Communicative Disorders and Stroke.

Gary Duncan, MD, referred patients 1 and 2. Jane S. Smith prepared the manuscript.

References

1. Wells CE: Dementia: Definition and description, in Wells CE (ed): *Dementia*, ed 2. Philadelphia, FA Davis Co, 1977, pp 1-14.
2. Felm L: Behavioral activities in demented geriatric patients. *Gerontol Clin* 1974;16:185-194.
3. Sim M, Sussman I: Alzheimer's disease: Its natural history and differential diagnosis. *J Nerv Ment Dis* 1962;135:489-499.
4. Sjögren T, Sjögren H, Lindgren AGH: Morbus Alzheimer and Morbus Pick: A genetic, clinical, and pathoanatomic study. *Acta Psychiatr Neurol Scand* 1974;82(suppl):185-194.
5. Kaszniak AW, Fox J, Gandell DL, et al: Predictors of mortality in presenile and senile dementia. *Ann Neurol* 1978;3:246-252.
6. Bayles KA, Boone DR: The potential of language tasks for identifying senile dementia. *J Speech Hear Disord* 1982;47:210-217.
7. Goodglass H, Kaplan E: *The Assessment of Aphasia*. Philadelphia, Lea & Febiger, 1972.
8. Kaszniak AW, Kelly M, Schneider A: Reliability and validity of a neuropsychological screening battery for older adults. *Exp Aging Res*, in press.
9. Lezak MD: *Neuropsychological Assessment*, ed 2. New York, Oxford University Press, 1983.
10. Kirshner HS, Webb WG, Duncan GW: Word deafness in Wernicke's aphasia. *J Neurol Neurosurg Psychiatry* 1981;44:197-201.
11. Horenstein S: Amnesic, agnosic, apractic, and aphasic features in dementing illness, in Wells CE (ed): *Dementia*, ed 1. Philadelphia, FA Davis Co, 1971, pp 43-54.
12. Wechsler AF: Presenile dementia presenting as aphasia. *J Neurol Neurosurg Psychiatry* 1977;40:303-305.
13. Wechsler AF, Verity MA, Rosenschein S, et al: Pick's disease: A clinical, computed tomographic, and histologic study with Golgi impregnation observations. *Arch Neurol* 1982;39:287-290.
14. Pick A: On the relation between aphasia and senile atrophy of the brain, in Rottenberg DA, Hochberg FG (eds): *Neurological Classics in Modern Translation*. New York, Hafner Press, 1977, pp 35-40.
15. Malamud N, Boyd DA: Pick's disease with atrophy of the temporal lobes. *Arch Neurol Psychiatry* 1940;43:212-222.
16. Cole M, Wright D, Banker BQ: Familial aphasia due to Pick's disease, abstracted. *Ann Neurol* 1979;6:158.
17. Mesulam M-M: Slowly progressive aphasia without generalized dementia. *Ann Neurol* 1982;11:592-598.
18. Alzheimer A: A unique illness involving the cerebral cortex, in Rottenberg DA, Hochberg FH (eds): *Neurological Classics in Modern Translation*. New York, Hafner Press, 1977, pp 35-40.
19. Critchley M: The neurology of psychotic speech. *Br J Psychiatry* 1964;110:353-364.
20. Stengel E: Psychopathology of dementia. *Proc R Soc Med* 1964;57:911-914.
21. Irigaray L: Approche psycholinguistique du langage des déments. *Neuropsychologia* 1967;5:25-52.
22. Albert ML: Language in normal and dementing elderly, in Obler LK, Albert ML (eds): *Language and Communication in the Elderly: Clinical, Therapeutic, and Experimental Issues*. Lexington, Mass, DC Health & Co, 1980, pp 145-150.
23. Appell J, Kertesz A, Fisman M: Language functioning in Alzheimer's disease. *Brain Lang* 1982;17:73-91.
24. Kirshner HS: Language disorders in dementia, in Kirshner HS, Freeman FR (eds): *The Neurology of Aphasia*. Amsterdam, Swets Publishing Co, 1982, pp 187-196.
25. Schwartz MF, Marin OS, Saffran EM: Dissociations of language function in dementia: A case study. *Brain Lang* 1979;7:277-306.
26. Crystal HA, Horoupian DS, Katzman R, et al: Biopsy-proved Alzheimer disease presenting as a right parietal lobe syndrome. *Ann Neurol* 1982;12:186-188.
27. Gustafson L, Hagberg B, Ingvar D: Speech disturbances in presenile dementia related to local cerebral blood flow abnormalities in the dominant hemisphere. *Brain Lang* 1978;5:103-118.
28. Foster NL, Patronas NJ, De La Paz R, et al: PET studies of Alzheimer disease, abstracted. *Neurology* 1982;32:167.