

## NOTE

# ASSOCIATIVE VISUAL AGNOSIA: A CASE STUDY

**José M. Ferro and Maria Emilia Santos**

(Neurobehavioral Unit, Centro de Estudos Egas Moniz, INIC, Department of Neurology, Hospital de Santa Maria, Lisboa)

## INTRODUCTION

Visual object agnosia is a rather rare neuropsychological syndrome defined as a failure of visual recognition or as a "normal percept that has somehow been stripped of its meaning" (Teuber, 1965). Lissauer's (1889) classic dichotomical classification of visual agnosia has survived almost 100 years of behavioral research and is still generally accepted. When a patient is able to copy and match-to-sample objects that he fails to name or recognize visually, his agnosia is termed associative, but if he fails on these tasks or demonstrates perceptual abnormalities, his agnosia is called aperceptive. The relatively rarity of pure forms of associative visual agnosia casts doubt on its reality. Several authorities (Bay, 1953; Critchley, 1964; Bender and Feldman, 1972) denied its existence, reducing it to defects of elementary perception, sometimes associated with general intellectual impairment. In the past few years a number of reports (Rubens and Benson 1971; Taylor and Warrington, 1971; Lhermitte, Chain, Escourrolle, Ducarne and Pillon, 1972; Lhermitte, Chedru and Chain, 1973; Hécaen, Goldblum, Masure and Ramier, 1974; Albert, Reches and Silverberg, 1975; Mack and Boller, 1977; Pillon, Signoret and Lhermitte, 1981), including three with post-mortem study (Lhermitte et al., 1972; Benson, Segarra and Albert, 1974; Albert, Soffer, Silverberg and Reches, 1979) in whom no dementia was present and whose visual perception was adequate, have firmly established the behavioral reality of associative visual agnosia.

There are however several unsettled points in this syndrome. First, the anatomical basis of visual agnosia is not completely established, as it has been associated with either bilateral temporo-occipital lesions (Lhermitte et al., 1972; Benson et al., 1974; Albert et al., 1979) or unilateral left occipital lesions (Nielsen, 1946; Hécaen et al., 1974). Are bilateral lesions really necessary to produce a stable agnosic defect or do they merely augment the scope of the agnosic defects, causing the appearance of prosopagnosia?

Second, the nature of the agnosic defect remains controversial. One of the most favored explanations is a disconnection between the associative visual areas and the language areas, leading to an inability to match perceived objects with their names (Geschwind, 1965). However, Taylor and Warrington (1971) stated that a visuo-verbal disconnection was not a sufficient explanation, because in their patient "all links or associations were lost, not merely the verbal". Hécaen et al. (1974) were the first authors to call attention to the visual categorization

defect present in these patients. Similar observations were made by Albert et al. (1975), who postulated that two mechanisms were necessary to produce this disorder: a visuo-verbal disconnection and a categorization defect for visual, non verbal, meaningful stimuli. Based on the necropsy findings of their patient, who presented bilateral occipito-temporal lesions, they (Albert et al., 1979) concluded that bilateral loss of visual-limbic connections may underlie associative visual agnosia and that bilateral lesions of the inferior longitudinal fasciculi may be the necessary and sufficient anatomical substrate for this syndrome. Ross (1980), commenting on this case, speculated that visual agnosia may be viewed as a total loss of all visual memories and that the lesions causing it probably destroy the cortical areas in which visual memories are actually stored.

### CASE REPORT

A 58 year-old right-handed male designer, C.A.R.J., was referred to our Laboratory for evaluation of his naming and reading difficulties. A month before, he had come to the emergency room of our hospital because of a sudden onset of visual and speech disturbances. Neurological examination demonstrated a mild fluent aphasia with good repetition, alexia and a right homonymous hemianopia. He was diabetic and hypertensive; five years before he had an hospital admission because of myocardial infarction. He was admitted to an internal medicine ward and discharged 12 days later recovered from his aphasia.

Neuropsychological examinations were carried out between the first and second month of disease. At that time a right homonymous hemianopia was still detected on confrontation testing and confirmed by several tangent-screen examinations; it showed macular and partial inferior quadrant sparing.

#### *Language*

Language was evaluated with a comprehensive aphasia battery (Castro-Caldas, 1979; Ferro, Santos, Castro-Caldas and Mariano, 1980). Spontaneous speech was fluent, without paraphasia, articulatory or syntactic errors, but with word-finding pauses. Serial and automatic speech were normal. Aural comprehension was normal, if the order to be followed did not involve object manipulation. Token test could not be given because of colour identification disturbance. Repetition of words, sentences and digits was normal. Visual naming and object identification by name were severely disturbed, demonstrating classical agnosic defects and are described in detail below. On the contrary, naming in pure verbal tasks such as answering to questions or sentence completion was 100% adequate and rapid. Dichotic listening test (pairs of words and pairs of digits) performance was normal.

#### *Reading and writing*

Reading aloud was severely impaired: he could read only 4 out of 10 letters, none of 16 words and was unable to read aloud any sentence or grasp the meaning of a short newspaper story. Identification of letters and written words was also disturbed. Tactual reading was better and reading performance was much improved if the patient was allowed to follow with his right finger the letters, if he

could “trace in the air” the seen letters, or if he copied them. Reading of letters “traced in the air” by the examiner was normal. Spelling and recognition of spelled words were excellent. Writing spontaneously and to dictation was normal. Copying was very laborious and showed minor errors. Summarizing, C.A.R.J.’s performance on reading and writing tests displayed a typical alexia without agraphia.

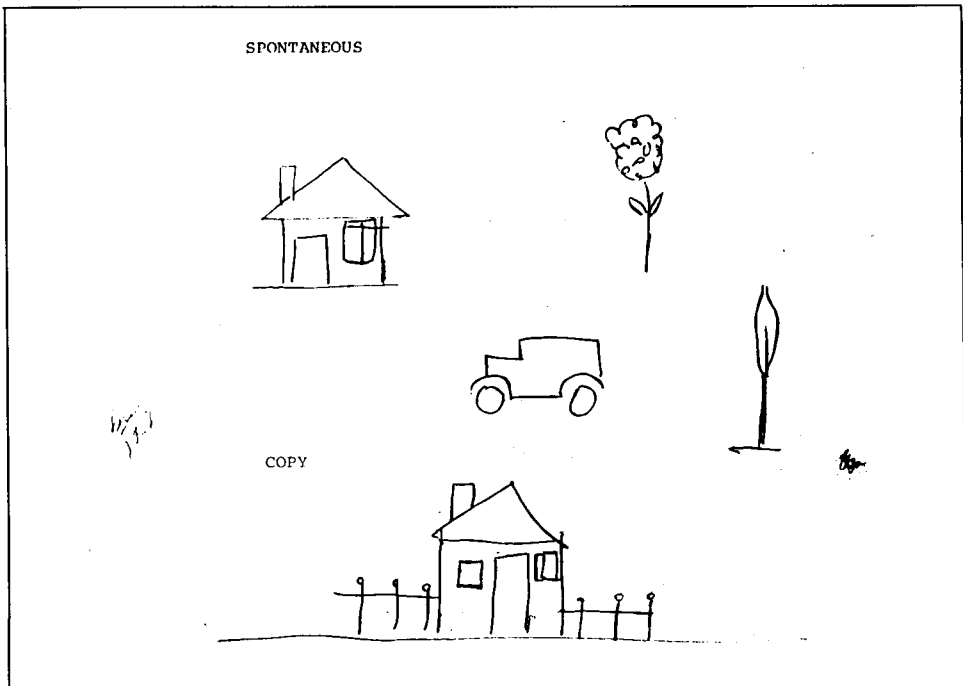
*Memory*

The patient showed a defect of recent verbal memory, when tested with the Wechsler Memory Scale. His MQ was 76. Scores in information (5), orientation (5), mental control (7), visual reproduction (8) subtests were within normal limits for his age. Digit span was four forward and three backward. Scores on logical memory (1) and associative learning (4,5) were very low. Recall of remote events was normal, while memory for recent facts was very poor. In fact, the patient often complained that this was his most troubling defect.

*Praxis, visuo-constructive and visuo-spatial abilities*

There was no bucco-facial or limb apraxia. Spontaneous drawing of a car, house and flower were correct although somewhat crude, if we consider the patient’s job (Figure 1). Drawing by copy was normal (Figure 1), even when the

Fig. 1 — Top: sample of C.A.R.J.’S spontaneous drawing (flower, car, house). Bottom: copy of a house.



patient did not recognize the stimuli. C.A.R.J.'s performance on the Benton-Fogel test of three-dimensional constructional praxis was normal. Visual Retention Test (form C) was given for copy: with either the right or the left hand there were only occasional omissions of the small figures on the right. Although this could be due to right hemispatial inattention, no evidence of right visual neglect was detected on a cancellation test. There was no direct or crossed visuomotor ataxia or topographical disorientation. Visual maze tests (Talland, 1965) and map localization were easily solved.

### *Visuo-perceptive assessment*

Visual acuity (with correction) was 9/10 bilaterally. When presented with several lines of different length and width, C.A.R.J. could promptly rank them accordingly to length or width. On a visuo-perceptual stimulus-multiple choice matching task (Newcombe, 1969) he had an errorless performance. In a stimulus-multiple choice test of non-sense figures using the Kimura's amoeba-like drawings (Kimura, 1966) he also made no errors. Matching pairs of real objects, even presenting some differences in size or color, was 100% correct. However, matching objects with their black and white drawings was slow and only 70% accurate.

### *Colors*

Ten strips of different colors were presented for naming (8 failures), identification (3 failures) and visual matching (100% correct). No defects in color perception were detected with the Ishihara plates, when grading colors by hue or on a visual-sorting task. Pure verbal questions such as naming the color of a named object were easily answered. He failed (3 out of 8), when he had to point to the color of named objects. He succeeded when asked to separate dark from light colors, or joyful from sad ones, but failed when asked to sort the blues ones, the red ones, etc. Summarizing, C.A.R.J. showed a visuo-verbal disconnection behavior, that could be circumvented when the verbal label had a large semantic field (dark, sad). Moreover his visual memory for colors of common objects was also poor, as demonstrated by several mistakes when coloring drawings (a brown sea...) or identifying wrongly colored drawings (he accepted as correct a blue baby or a red elephant).

### *Faces*

There was no prosopagnosia. Recognition of relatives and friends was always correct. For "recent" familiar faces, such as physicians or therapists, there was occasional misnaming but recognition was otherwise correct. Faced with photographs of political leaders and although he could not name them, he could recognize their faces, as he was able to describe verbally their functions, speak about their careers or name the political party they belonged to. For president Carter he said: "this is a foreign one. English or American..." For a past Portuguese prime-minister, a lady called Pintassilgo (goldfinch) he said: "I know her. This is the lady that was in the power. She has the name of a bird". Pointing to the photographs whose names were spoken aloud was quick and 100% correct.

Perception of unfamiliar faces tested with the Benton-Van Allen Facial Recognition Test (form SL) was somewhat disturbed (corrected LF score = 34), but he could recognize 12 unknown woman faces in a card where they were presented among 30 female faces.

Judgement of emotional facial expressions was normal.

## SPECIAL STUDIES

### *Influence of mode of presentation on naming and recognition*

Naming of real objects visually presented one by one in front of the patient was clearly inferior (7 correct answers in 30 presentations) to when the same objects were named tactually in the right (24 out of 30 objects) or the left hand (26/30). Errors in tactile naming were anomic and consisted of description of use. Naming under auditory presentation was tested with the Benton's Sound Recognition Test, where his performance was normal as he named 23 out of 26 of the common sounds presented. His performance on the Gesture Recognition Test (Ferro et al., 1980), where he had to name pantomimes, was normal (12/12).

For visual recognition by name, real objects were presented in sets of eight. His performance was disturbed, although better than on the visual naming test. He was extremely slow and failed 12 out of 30 objects. Two different forms of tactile recognition were given: visuo-tactile and verbal-tactile. On both the patient used his right hand. When the palpated object was presented visually among eight real objects, his tactile recognition was better (16/16) than when several names were spoken aloud by the examiner and the patient was requested to choose the name of the palpated object (8/16). For auditory recognition we used a multiple choice form of the Sound Recognition Test. The patient pointed correctly to 21 out of 26 drawings (presented in cards with 4 multiple-choice drawings) corresponding to the listened stimulus.

When faced with an object he could not recognize visually and asked to pantomime its use, he almost always succeeded and then, at his own surprise, could name the presented object. Drawing real objects also improved its identification. Similarly, visual naming was somewhat improved if we used the following clues: moving the object in the front of the patient or presenting it from several sides. The patient himself often rotated his head, trying to inspect the objects from various angles.

As this behavior could suggest that the patient was looking for more visual information, thus raising the question of a perceptual defect, we investigated<sup>1</sup> the influence of reducing visual input, by lessening exposure time and size of object or enlarging the angle of viewing, upon naming and matching-to-sample tests. Twenty contour drawings were exposed to the patient's left hemifield tachistoscopically (Cambridge Tachistoscope, B.R.D. Electronics, Ltd), for either 10 msec., 50 msec., 100 msec., 500 msec., 2 sec. or 10 sec., under two different viewing angles (1 cm and 3 cm). To control for learning effect due to repeated presentations, time and angle of viewing were randomly allocated.

In another session 20 size-reduced versions of the same drawings were presented tachistoscopically for 100 msec. Results of these experiments (Table I) showed that: (1) under all viewing conditions the defect was present on naming but not on matching-to-sample, (2) the agnosic defect was not significantly influenced by exposure duration, viewing angle or size of the drawing.

TABLE I  
*Tachistoscopically Presented Stimuli*

	Naming	Matching-to-sample
	Errors/presentations	Errors/presentations
Exposure time		
10 msec.	12/40	4/40
50 msec.	12/40	0/40
100 msec.	8/40	1/40
500 msec.	15/40	1/40
2 sec.	6/40	0/40
Viewing angle		
1 cm	15/60	1/60
3 cm	14/60	1/60
Reduced size (100 msec.)	5/20	0/20

His behavior during these tests suggested a disturbance of recall and not a perceptual trouble. After each stimulus presentation, the patient stared, trying to recognize it or to recall its name. If after a 10 sec. delay he was not able to name the drawing, a multiple-choice card was presented and he promptly pointed to the correct drawing, proving that his perception and visual retention of the stimuli were good.

#### *Nature of the visual naming errors*

During visual naming of objects and drawings the patient made six different kinds of errors: (1) no response: he looked at the object saying "don't know, never saw such a thing..." (objects 8/30; drawings 9/30); (2) anomic: the patient tried to describe the object or the way to use it (objects 2/30; drawings 2/30); (3) semantic errors, e.g. misnaming knife for fork (objects 1/30; drawings 1/30); (4) morphological errors, when the erroneous name given to the actual object depicted an object with a similar outline or other similar morphological features (objects 1/30; drawings 1/30); (5) perseveration, when the names given were those of objects that the patient had previously been shown or thought he had been shown, or names belonging to the same semantic category of those objects, e.g., during a naming test he correctly named the 2<sup>nd</sup> presented object "pencil". After that, during all the test all objects looked like "pencils, pens, something to write...". This was the most common type of error (objects 8/30; drawings 10/30); (6) non-classifiable (objects 3/30; drawings 3/30). In general, the patient was reluctant to accept the correct answer, e.g., after he misnamed rabbit as an elephant, the observer corrected him and he commented: "looks like a rabbit".

<sup>1</sup> Tachistoscope testing was conducted 3 months post-stroke, when C.A.R.J.'s visual naming performance was already improving.

TABLE II  
*Performance with Different Kinds of Visual Stimuli*

Stimuli	Naming	Recognition by name
Objects	7/30	12/30
Drawings	4/30	23/30
Colors	2/10	7/10
Body-parts	7/10	8/10
Animals	4/10	9/10
Geometric figures	2/6	5/6
Horoscope signs	1/4	—
Traffic signs	1/4	0/4
Playing-cards: colors	2/4	—
figures	3/3	—
Arithmetic signs	3/6	3/6
Digits: arabic	3/5	—
roman	5/6	—
Numbers: arabic	1/7	—
roman	1/7	—
Letters: print	4/10	7/10
Public faces	0/8	8/8
Lisbon postcards	1/8	8/8

#### *Influence of type of visual stimuli*

Several kinds of visual stimuli were given for naming and recognition (Table II). As for public faces, C.A.R.J.'s behavior for views of Lisbon was somewhat peculiar and different from other visual stimuli: (1) although naming was disturbed, the patient could describe verbally the presented stimuli, (2) naming errors were almost exclusively anomie in nature, (3) identification by name was normal and easily performed, (4) these stimuli looked familiar to the patient. When shown a picture of a downtown square in Lisbon (The "Rossio"), he correctly answered "this is where the Avenida da Liberdade" begins. He was unable to produce the name of a riverside square (Terreiro do Paço) but could describe it accurately "This square has a lot of governmental buildings, on this side ends Rua da Prata..." and he named the streets ending on that square.

### CATEGORIZATION TASKS

#### *A. Verbal tests*

1. *Naming a category.* The observer enumerated several elements belonging to the same semantic category, e.g., orange, banana, apple..., and asked the patient to name the category (they are all...). For 7 categories, performance was 100% correct.

2. *Naming the elements of a category.* The observer named a category, e.g., flowers, and the patient was asked to enumerate words of this category. For 10 trials he had an errorless performance.

3. *Odd word out.* Four words were spoken to the patient. Three words belonged to the same category and one did not. The patient had to indicate the odd word. He succeeded in 9 out of 10 presentations.

4. *Verbal classification.* Four words belonging to two different semantic categories were spoken to the patient. The patient had to indicate the two pairs of semantically similar words. In 10 presentations, response was prompt and correct for 8, delayed in one and wrong in another one.

### B. Verbo-visual tests

1. *Objects-to-semantic field matching.* The patient was shown several objects belonging to the same semantic field and then was asked to name it. Responses were correct in 3 out of 10 series of objects. In three series responses were approximated (scissors, knife, razor: to cut food) and in four completely wrong.

2. *Choosing elements of a category.* Twenty contour drawings belonging to several categories were displayed in front of the patient. The observer asked the patient to pick up drawings of a spoken category, e.g., clothes. C.A.R.J. was correct in 5 out of 6 spoken categories.

3. *Letters and digits.* When an array of  $4 \times 4$  letters and digits was presented, the patient said "there are vowels and consonants (but he was not able to point to them)... there is a capital letter (he pointed to it). There are also digits (he pointed to them)".

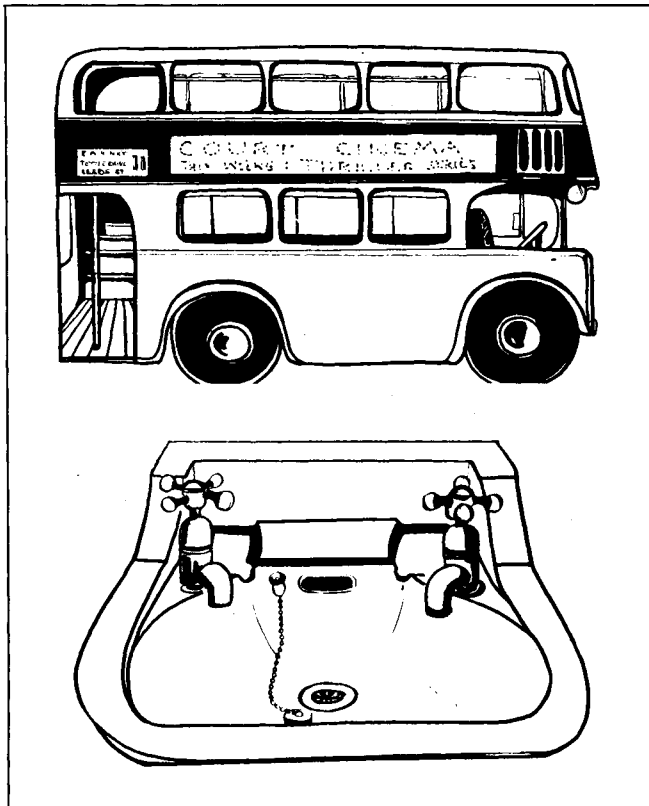


Fig. 2 — Example of a foul association on the visual classification test.



### C. Visual tests

To diminish the possible negative influence of naming, the patient was requested not to speak during these tasks. We noticed that, in general, when the patient failed, verbal explanation of his performance was also incorrect. On the contrary, the patient could always draw the objects he did not succeed in classifying.

1. *Odd object out.* Similar to the odd word out, four objects or four drawings being presented instead of words. The task was to select the odd object. With real objects, performance, although slow, was 80% correct, but dropped to 60% with drawings.

2. *Visual classification.* Twenty contour drawings (two per category) were placed on the table in front of the patient and he was requested to select ten pairs of semantically related drawings. His performance was very poor: he failed 9 out of 10 pairings and made silly associations such as a bus with a wash-stand (Figure 2).

3. *Identification of semantic fields.* Thirty objects were placed before the patient. The observer pointed to one object and the patient had to choose other objects belonging to the same semantic field. His failure rate was 50%. When we pointed to a match, he chose a candle, but then a comb, a coin and a cigarette. Summarizing the performance on categorization tests, C.A.R.J. was normal on verbal ones and disturbed on verbo-visual or visual tests, more severely when he had to proceed from the visual elements to the category.

### LESION LOCALIZATION

A cerebral scan with  $^{99m}\text{Tc}$  revealed a left occipito-temporal area of increased uptake, corresponding to the territory of the left posterior cerebral artery. Visual evoked responses were abnormal only on left occipital leads. CT-scan also showed a left unilateral occipito-temporal well-limited area of decreased density, showing no mass effect or contrast enhancement (Figure 3). Based on Damásio and Damásio (1979) and Matsui and Hirano atlas (1978) the lesion was mapped more precisely: it involved part of the calcarine cortex, the hippocampus, the parahippocampal and fusiform gyrus, subcortical white matter of the temporo-occipital junction and the inferior part of the forceps major as it courses medial and ventral to the occipital horn of the lateral ventricle.

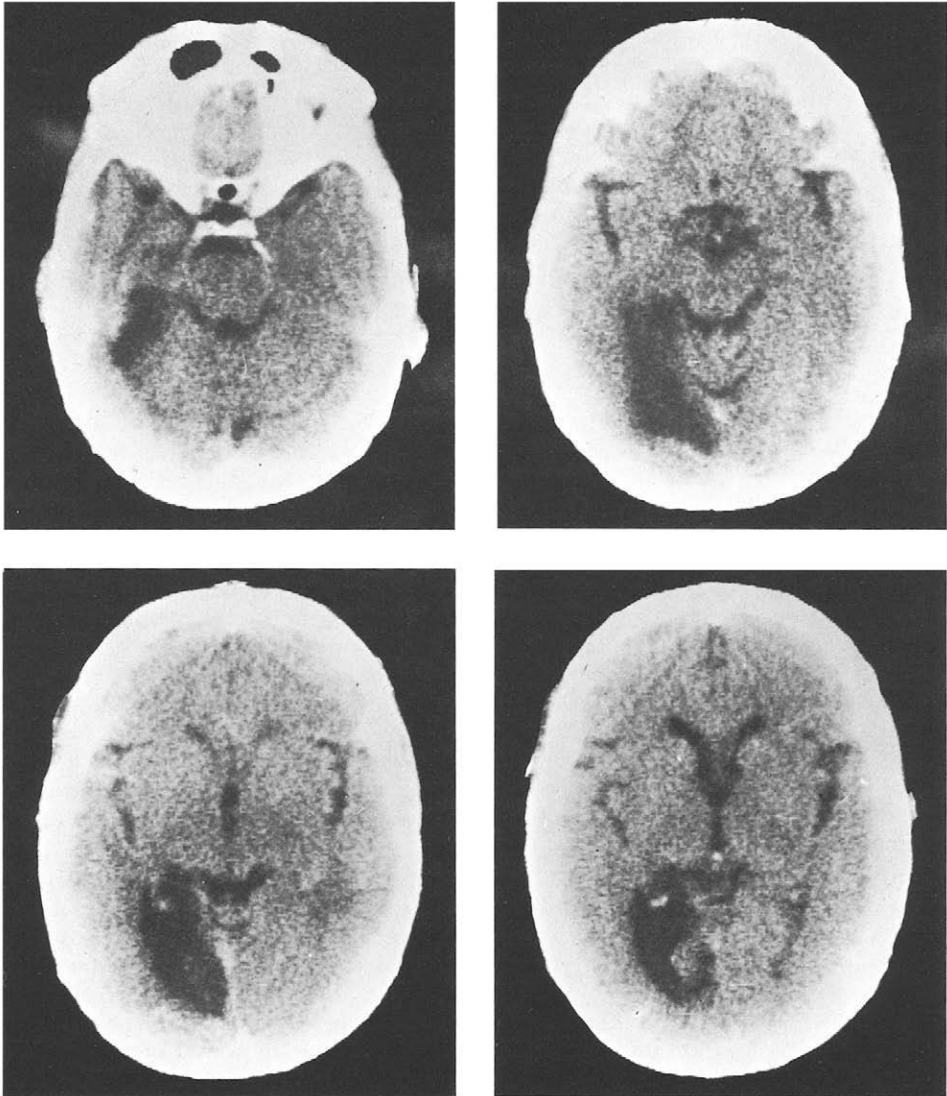
### DISCUSSION

This patient fulfills the criteria for the diagnosis of associative visual agnosia: he had a disturbance of both visual naming and visual recognition, but demonstrated good perceptual skills, could match-to-sample and copy the objects he failed to recognize visually. The patient made a few errors in tactile naming, such as describing the use instead of naming an object. Tactile recognition was normal. The poor performance of the patient in matching tactile stimuli to a verbal multiple-choice contrasted with his normal scores in visuo-tactile matching. This appears paradoxical at first glance because one would expect the visual task to be affected more severely. However, this can be explained by the preserved visual-tactile connections, as evidenced by his tactile self-cuing and an overall improve-

ment of performance when the haptic modality was engaged. On the other hand, the verbal task evoked visual images which may have interfered with the actual haptic stimuli.

Our patient also presented with right homonymous hemianopia, alexia without agraphia, color agnosia and recent memory impairment. These signs are commonly (cf. Rubens, 1979, for review) associated with visual agnosia. The memory defect is rarely emphasized in the literature, although it may be long-lasting (Kertesz, 1979). In fact, in our case it was one of the patient's major complaints.

Fig. 3 — CT scan showing a left occipital-inferior temporal infarction.



Levine (1978) suggested that a deficit in visual perception characterized by insufficient feature analysis of visual stimuli was the basis of visual agnosia in his case. In our patient, perceptual abilities were normal and tachistoscope testing showed that his naming and matching performances were not affected by stimulus size, viewing angle or exposure duration. A disturbance at the perceptual level can be excluded as the source of his agnosia. The patient's performance was somewhat improved if the objects were moved or rotated, a behavior described by Botez et al. (1964) as static visual agnosia. This improvement was probably due to kinesthetic clues provided by head, neck and eye movements, as suggested by Kertesz (1979). Another possibility could be that moving the object or inspecting it from various sides activated a right-hemispheric strategy in order to overcome the agnostic defect. Indeed, the right parietal lobe contributes to the judgement of the physical identity of objects, since it has been shown that patients with right-parietal lobe damage are impaired in visual recognition of objects presented from unusual angles (Warrington and Taylor, 1973).

This patient presented a "two-way" visual-speech disconnection (Geschwind, 1965), that can explain why the patient had a visuo-modality-specific naming disorder and why he could not point to a named object. It can also account for his alexia without agraphia and his color naming defect. But it cannot explain why the patient failed to associate a "seen color" with a "seen object" (in coloring and identifying wrongly colored drawings), or to categorize visually presented stimuli.

The same holds for the fact that objects no longer looked familiar to the patient. These findings could be due, as suggested by Ross (1980), to loss of all visual memories of seen objects. However, this explanation must be ruled out because our patient could draw objects spontaneously from memory. The inability to categorize visual stimuli according to their functional attributes, while verbal categorization is intact, was noticed by Hécaen et al. (1974), who considered this to be the fundamental problem in associative visual agnosia. Albert, Reches and Silverberg (1975) believed that both a categorization deficit for visually meaningful stimuli and a visual-verbal disconnection should be present in order to produce visual agnosia. Our case supports this interpretation, as visual stimuli could neither be matched with their names nor be classified visually.

The inferior temporal area may be the crucial one involved in visual classification processes and in the activation of multimodal memories permitting both the recognition and experience of familiarity with a given visual stimulus. It can trigger the left hippocampus and other limbic structures through the inferior longitudinal fasciculus and other occipito-temporal connections (Kuypers et al., 1965; Jones and Powell, 1970). In primates, lesions of the inferior-temporal cortex disrupt the categorial perception of visual stimuli (Wilson and Debauche, 1981). Single unit studies revealed that inferior temporal cells have very large receptive fields and very selective reactivity (Gross, Rocha-Miranda and Bender, 1972). These neurons can also distinguish and retain behaviorally relevant features of visual stimuli (Fuster and Jervey, 1981).

In fact, our patient presented a well localized left temporo-occipital infarct, involving the hippocampus, parahippocampal and fusiform gyri, part of the calcarine cortex and temporo-occipital white-matter (posterior part of inferior longitudinal fasciculus and inferior part of forceps major). Although we had no histological confirmation, there was no evidence of right hemispheric damage either on isotope or C.T. scans or visual evoked potentials. In Nielsen's (1946) review, the center for object recognition was localized in the left occipital lobe (area 18). However, most of his data are not reliable, because of inadequate

testing, failure to separate naming from recognition defects and apperceptive from associative forms of visual agnosia. Alexander and Albert (1983) recently reviewed the anatomical basis of associative visual agnosia based on three post-mortem studies (Lhermitte et al., 1972; Benson et al., 1974; Albert et al., 1979). They concluded that bilateral damage to temporo-occipital association pathways was the pathological substrate for his type of agnosia. However, the cases reported by Hahn (1895) (autopsy of Lissauer's case), Hécaen et al. (1974), Pillon et al. (1981) and the present case had unilateral left lesions.

We conclude that a left temporo-occipital lesion plus damage to the ventral callosal outflow are sufficient to produce the syndrome of associative visual agnosia. In our case this lesion prevented access of visual information from the right hemisphere to the speech areas producing the "two-way" visual-verbal disconnection. Visual matching could be accomplished either by the right hemisphere or by the spared left associative visual areas. Pantomime could be recognized and objects could arouse pantomime and could be drawn because visuo-tactile connections were intact. Indeed, visuo-verbal and visuo-tactile disconnections (visual apraxia) were reported by Assal and Regli (1980) in association with two combined left lesions: temporo-occipital and parietal. The parietal lesion prevented visual arousal of kinesthetic-motor engrams of pantomime.

The absence of right hemispheric damage explains why familiar faces and scenes of Lisbon could be recognized. Although he could not always name faces, he could give a verbal description of their past (for faces) or of their history and location (for views of Lisbon) and recognize them by name. Anomia for these stimuli could again be due to the inability of visual information from the right hemisphere to reach speech areas, because of the lesion of the callosal outflow. However, full recognition of these types of stimuli could be achieved through the intact right temporo-occipital areas. Two arguments favor this interpretation: (1) familiar faces and familiar places are more personal-linked and emotional-loaded stimuli than common objects and the right hemisphere is known to have a relevant role in emotional processes (Kolb and Whishaw, 1980); (2) familiar faces are unique individual stimuli, whose recognition occurs through contextual evocation. The same holds for familiar places. Damásio, Damásio and Van Hoesen (1982) proposed that visual perception of faces fits a stored visual template, i.e., a learned record of its past visual perceptions, which arouses multimodal information, previously stored in the context of perceiving each of those specific stimuli.

We propose that common objects have to go through a process of visual classification before the categorical-semantic arousal of its multimodal memories takes place. This visual classification is necessary because it is unlikely that the brain stores a record of past visual perception for each individual common stimuli within a category. The present case points out that the process of categorization of meaningful, common visual stimuli is a left occipito-temporal function. A review of available anatomical and C.T. data indicates that prosopagnosia is caused by bilateral mesial occipito-temporal lesions (Damásio et al., 1982). Also, associative visual agnosia was associated with prosopagnosia in cases with bilateral lesions (Lhermitte et al., 1972; Benson et al., 1974). Lhermitte's patients also had a trouble in recognizing Paris monuments. Hécaen et al. (1974) patient and our case who had unilateral lesions did not present prosopagnosia. It is conceivable that a right hemispheric lesion merely augments the scope of associative visual agnosia causing the appearance of prosopagnosia and visual memory defects, and probably increasing the severity of the agnosic defect while decreasing the likelihood of recovery.

## ABSTRACT

This report describes a case of associative visual agnosia caused by a left sided, cortico-subcortical, inferior temporo-occipital infarction. Performance on visual perceptual tests was normal, while it was defective on visual classification tasks.

Visual agnosia was interpreted as a visuo-verbal disconnection plus a categorization deficit for visual meaningful common stimuli. The left occipito-temporal lesion disrupted the visual classification process and prevented access of visual information to language areas and limbic system. The absence of right hemispheric lesion accounted for the normal recognition of familiar faces and other unique individual stimuli such as familiar places, whose recognition occurs through contextual evocation.

*Acknowledgments.* This study was supported by grants from the INIC (Instituto Nacional de Investigação Científica) and the Gulbenkian Foundation. We thank Dr. Andrew Kertesz for his critical review of the English version of this paper.

## REFERENCES

- ALBERT, M.L., RECHES, A., and SILVERBERG, R. Associative visual agnosia without alexia. *Neurology* 25: 322-326, 1975.
- ALBERT, M.L., SOFFER, D., SILVERBERG, R., and RECHES, A. The anatomical basis of visual agnosia. *Neurology* 29: 876-879, 1979
- ALEXANDER, M.P., and ALBERT, M.L. The anatomical basis of visual agnosias. In A. Kertesz (Ed.) *Localization in Neuropsychology*. New York: Academic Press, 1983 (In press).
- ASSAL, G., and REGLI, F. Syndrome de disconnexion visuo-verbale ed visuo-gestuelle. Aphasie optique et apraxie optique. *Revue Neurologique* 136: 365-376, 1980.
- BAY É. (1953) Disturbances of visual perception and their examination. *Brain* 76: 515-550, 1953.
- BENDER, M.B., and FELDMAN, M. (1972) The so-called "visual agnosias". *Brain* 9: 173-196.
- BENSON D.F., SEGARRA, H., and ALBERT, M.L. Visual agnosia-prosopagnosia. A clinicopathological correlation. *Archives of Neurology* 30: 307-310, 1974.
- BOTEZ, M.I., SERBANESCU, T., and VERNEA, I. Visual static agnosia with special reference to literal agnosic alexia. *Neurology* 14, 1101-1111, 1964.
- CASTRO-CALDAS, A. Diagnóstico e Evolução das Afasias de Causa Vascular. Lisboa: Faculdade de Medicina de Lisboa, 1979.
- CRITCHLEY, M.M. The problem of visual agnosia. *Journal of Neurological Sciences* 1: 274-290, 1964.
- DAMASIO, A. R., DAMASIO, H., and VAN HOESEN, G.W. Prosopagnosia: anatomic basis and behavioral mechanisms. *Neurology* 32: 331-341, 1982.
- DAMASIO, H., and DAMASIO, A.R. *A Computerized Tomography Guide to the Identification of Cerebral Structures*. Iowa City: Department of Neurology, University of Iowa, College of Medicine, 1979.
- FERRO, J.M., SANTOS, M.E., CASTRO-CALDAS, A., and MARIANO, M.G. Gesture recognition in aphasia. *Journal of Clinical Neuropsychology* 2: 277-292, 1980.
- FUSTER, J.M., and JERVEY, J.P. Inferotemporal neurons distinguish and retain behaviorally relevant features of visual stimuli. *Science* 212: 952-954, 1981.
- GESCHWIND, N. Disconnexion syndromes in animals and man. *Brain* 88: 237-294, 585-644, 1965.

- GROSS, C.G., ROCHA-MIRANDA, C.E., and BENDER D.B. Visual properties of neurons in inferotemporal cortex of the macaque. *Journal of Neurophysiology* 35: 96-111, 1972.
- HAHN, E. (1895) Pathologische-anatomische Untersuchung en de Lissauer'schen Falles von Seelenblindheit. *Arbeiten aus dem Psychiatrischen Klinik in Breslau*, 1895.
- HÉCAEN, H., GOLDBLUM, M.C., MASURE, M.C., and RAMIER, A.M. Une nouvelle observation d'agnosie d'object. Déficit de l'association ou de la categorization spécifique de la modalité visuelle? *Neuropsychologia* 12: 447-464, 1974.
- JONES, E.G., and POWELL, T.P.S. An anatomical study of converging sensory pathways within the cerebral cortex of the monkey. *Brain* 93: 793-820, 1970.
- KERTESZ, A. Visual agnosia: the dual deficit of perception and recognition. *Cortex* 15: 403-419, 1979.
- KIMURA, D. Dual functional asymmetry of the brain in visual perception. *Neuropsychologia* 4: 275-285, 1966.
- KOLB, B., and WHISHAW, I.Q. *Fundamentals of Human Neuropsychology*. San Francisco: W. H. Freeman and Company, 1980, pp. 367-386.
- KUYPERS, H.G.J.M., SZWARCBART, M.D., MISHKIN, M., and ROSVOLD, H. E. Occipito-temporal cortico-cortical connections in the Rhesus monkey. *Exp. Neurol.* 11: 245-262, 1965.
- LEVINE, D.L. Prosopagnosia and visual object agnosia: a behavioral study. *Brain ad Language* 5: 341-365, 1978.
- LHERMITTE, F., CHAIN, F., ESCOUROLLE, R., DUCARNE, B., and PILLON, B. Étude anatomo-clinique d'un cas de prosopagnosie. *Revue Neurologique* 126: 329-346, 1972.
- LHERMITTE, F., CHEDRU, F., and CHAIN, F. À propos d'un cas d'agnosie visuelle. *Revue Neurologique* 128: 301-322, 1973.
- LISSAUER, H. Ein Fall von Seelenblindheit nebst Beitrage zur Theorie derselben. *Arch. f. Psychiat. u. Nervenkr.* 22: 222-270, 1889.
- MACK, J.L., and BOLLER, F. Associative visual agnosia and its related deficits: the role of the minor hemisphere in assigning meaning to visual perceptions. *Neuropsychologia* 15: 345-349, 1977.
- MATSUI, T., and HIRANO, A. *An Atlas of Human Brain for Computerized Tomography*: Tokyo: Igaku-Schoin, 1978.
- NEWCOMBE, F. *Missile Wounds of the Brain. A Study of Psychological Deficits*. London: Oxford University Press, 1969.
- NIELSEN, J.M. *Agnosia, Apraxia and Aphasia: Their Value in Cerebral Localization*. New York: Paul Hoeber, 1946.
- PILLON, B., SIGNORET, J.L., and LHERMITTE, F. Agnosie visuelle associative. Rôle de l'hémisphere gauche dans la perception visuelle. *Revue Neurologique* 137: 831-842, 1981.
- ROSS, E. The anatomical basis of visual agnosia. *Neurology* 30: 109-110, 1980.
- RUBENS, A.B., AGNOSIA. In K.M. Heilman and E. Valenstein (Eds). *Clinical Neuropsychology*. Nex York: Oxford Univarsity Press, 1979.
- RUBENS, A.B., and BENSON, D.F. Associative visual agnosia. *Archives of Neurology* 24: 305-316, 1971.
- TALLAND, G.A. *Deranged Memory*. New York: Academic Press, 1965.
- TAYLOR, A., and WARRINGTON, E.K. Visual agnosia: a single case report. *Cortex* 7: 152-161, 1971.
- TEUBER, H.L. Somatosensory disorders due to cortical lesions. *Neuropsychologia* 3: 287, 294, 1965.
- WARRINGTON, E.K., and TAYLOR, A.M. The contribution of the right parietal lobe to object recognition. *Cortex* 9: 152-164, 1973
- WILSON, M., and DEBAUCHE, B.A. Inferotemporal cortex and categorial perception of visual stimuli by monkeys. *Neuropsychologia* 19: 29-41, 1981.