

Child's Brain 10: 1–15 (1983)

### Treatment of Moyamoya Disease by Temporal Muscle Graft 'Encephalo-Myo-Synangiosis'

*Shigekazu Takeuchi, Tadashi Tsuchida, Keishi Kobayashi,  
Mitsunori Fukuda, Ryoji Ishii, Ryuichi Tanaka, Jusuke Ito*

Department of Neurosurgery, Brain Research Institute, and Department of Radiology,  
School of Dentistry, Niigata University, Niigata, Japan

**Key Words.** Moyamoya disease · Cerebral ischemia · Surgical treatment ·  
Temporal muscle graft · Encephalo-myo-synangiosis · Cerebral blood flow

**Abstract.** 10 young patients from 7 to 16 years of age with moyamoya disease were treated by temporal muscle graft (encephalo-myo-synangiosis: EMS) for the purpose of increasing extracranial and intracranial collateral circulation. Ischemic cerebrovascular symptoms and signs were encountered in all of them without intracranial hemorrhage.

The patients were observed for 6–26 months after the first operation. Transient ischemic attacks disappeared in 4 out of 7 patients, and improved in frequency and duration in the remaining 3. Paresis of the limbs disappeared in 1 patient and improved in 2. In 2 patients, facial palsy disappeared and dysarthria improved as well. Ataxia disappeared in 2 patients, and involuntary movement of the extremities disappeared in 2. There were no ineffective cases clinically. In postoperative carotid angiography, the middle cerebral arteries were visualized clearly to the peripheral portion mainly via the thickened deep temporal arteries, and the abnormal vascular networks in the region of the basal ganglia reduced in size in most of patients. Improvements in intelligence quotient, electroencephalogram and cerebral blood flow were also obtained in several patients, respectively.

EMS seemed to be an effective surgical treatment in young patients with moyamoya disease who suffered from cerebral ischemic symptoms.

### Introduction

Moyamoya disease is an occlusive cerebrovascular disease with unknown etiology. The young patients usually show cerebral ischemic

symptoms and signs but little tendency to hemorrhagic manifestations. The study of pediatric patients reveals that this disease shows a progressive course with repeated ischemic episodes frequently resulting in permanent deficits [13, 14]. To minimize the deficits in its progressive ischemic phase, surgical treatment to increase cerebral blood flow has been undertaken [1, 6–9, 15]. The temporal muscle graft was first reported in 1942 by Kredel [10], and was called ‘Encephalo-Myo-Synangiose’ (EMS) in 1950, according to Henschen [5]. The authors performed EMS on the young patients with moyamoya disease for the purpose of increasing extra-cranial and intracranial collateral circulation, and obtained satisfactory results.

## Materials and Methods

### *Operative Technique*

Following a skin incision in the frontotemporal region, the temporal muscle was detached from the skull. After craniotomy, the dura mater was opened carefully to avoid cutting the main branches of the meningeal artery. The arachnoid membrane was neither opened nor stripped from the cerebral convexity of each gyrus. In several cases, however, the arachnoid membrane was opened carefully and cerebrospinal fluid was aspirated to obtain dry field, for serial-fluorescein angiography to investigate the epicerebral microcirculation. A part of the periosteum and fascia was stripped from the inner surface of the muscle. The temporal muscle was simply laid over the arachnoid membrane of the cortex and sutured to the adjacent dura. After rongeuering the lower part of the bone flap to prevent compression and constriction of the pedicle of the temporal muscle, the bone flap was replaced and fastened to the cranium and the scalp was closed in two layers. Since the muscle was thick enough in a few cases, only the deep layer of the muscle was used to avoid compression of the brain. This modified method was revealed to show less cosmetic disadvantage and similar effect to the method using the whole layers of the muscle.

### *Patients*

For about 2 years, we operated on 10 patients of from 7 to 16 years of age with cerebral ischemia. 5 were males and 5 were females. The clinical manifestations were various, such as transient and recurrent or prolonged paresis of the limbs, facial palsy, dysarthria, headache, mental retardation, convulsion, ataxia or involuntary movement of the extremities, with frequent alternation of the affected side. No intracranial hemorrhage had been encountered in their courses (table I). A diagnosis was established in all patients with bilateral carotid and vertebral angiographies. Preoperative computed tomography showed low-density lesions which, in all patients, varied in size except 1 (case 5). EMS was performed at 15 operations in 8 patients, and both EMS and superficial temporal-middle cerebral artery (STA-MCA) anastomosis was performed simultaneously at three operations in 2 patients (table II). Cerebral blood flow (CBF) was measured pre- and postoperatively by the  $^{133}\text{Xe}$  inhalation method and was evaluated by using an initial slope index [19].

**Table I.** Clinical summary of the cases

Case No.	Name	Sex	Age on admission	Age at onset	Clinical course	Signs and symptoms on first admission
1	MI	M	7y 2m	4y 9m	CS(R)→TIA(R)→RIND(L)	left hemiparesis
2	HM	M	8y 2m	3y 5m	TIA(R→L)	no abnormal findings
3	TN	M	8y 2m	6y 1m	TIA(R)→CS(L)→TIA(R&L) →CS(R) [→TIA(L)]	ataxia, dysarthria, dysphagia, right facial palsy
4	HK	M	8y 8m	5y 7m	RIND(R)→CS(R)→CS(L) →RIND(R&L)	ataxia, dysarthria, right facial palsy, involuntary movement
5	NT	F	9y 6m	9y 0m	TIA(R) [→TIA(R&L)]	no abnormal findings
6	SN	F	10y 11m	5y ?m	TIA(L)→CS(L)→TIA(R)	weakness of left hand
7	KS	M	12y 0m	10y 0m	TIA(R→L)	no abnormal findings
8	MK	F	13y 4m	2y ?m	TIA(L→R)→CS(R)→TIA(R)	weakness of right arm, aphasia, mental retardation
9	RT	F	13y 4m	11y 4m	TIA(L) [→TIA(R&L)]	no abnormal findings
10	MT	F	16y 6m	4y ?m	TIA(R→L)→CS(L)	involuntary movement, sensory disturbance of left arm and upper half of trunk, mental retardation

TIA = Transient ischemic attack; RIND = reversible ischemic neurological deficit; CS = completed stroke; R&L = affected side of the limbs; [ ] = after first operation.

Table II. Postoperative results in clinical findings and angiography

Case No.	Operation 1st, 2nd	Follow-up periods, months	Results	Clinical status at present	Postoperative angiography		
					periods after operation	visualization of MCA via EMS	basal moyo-moya vessels
1	R EMS	16	excellent	hemiparesis (-)	3m	marked	reduced
	L EMS	12			7m	marked	unchanged
2	R EMS	14	excellent	TIA(-)	9m	marked	unchanged
	L EMS	4				not performed	
3	L EMS	26	good	ataxia(-), dysarthria↓, dysphagia(-), facial palsy(-), TIA(-)	10m	marked	unchanged
					16m	marked	unchanged
4	R EMS	9	good	ataxia(-), dysarthria↓, facial palsy(-), involuntary movement(-)	9m	faint	unchanged
	R EMS, ST-MC	25			1m 3w	marked <sup>1</sup>	reduced
	L EMS, ST-MC	23			7m	marked <sup>1</sup>	unchanged
5	L EMS	6	good	TIA↓		not performed	
	R EMS	2				not performed	
6	R EMS	15	good	TIA(-), weakness↓	13m	marked	unchanged
	L EMS	2				not performed	
7	R EMS, ST-MC	24	excellent	TIA(-)	7m	faint <sup>2</sup>	reduced
8	L EMS	26	good	TIA↓, weakness↓, aphasia(-), mental ability↑	4m	faint	reduced
9	R EMS	21	good	TIA↓	4m	marked	reduced
	L EMS	16			4m	marked	reduced
10	R EMS	21	good	involuntary movement(-), sensory disturbance(-), mental ability↑	2w	faint	unchanged
					5 m	marked	reduced
	L EMS	20			9m	marked	reduced

EMS = Encephalo-myo-synangiosis; ST-MC = superficial temporal-middle cerebral artery anastomosis; TIA = transient ischemic attack; (-) = disappeared; ↑ and ↓ = improved.

<sup>1</sup> No patency of ST-MC. <sup>2</sup> Good patency of ST-MC.

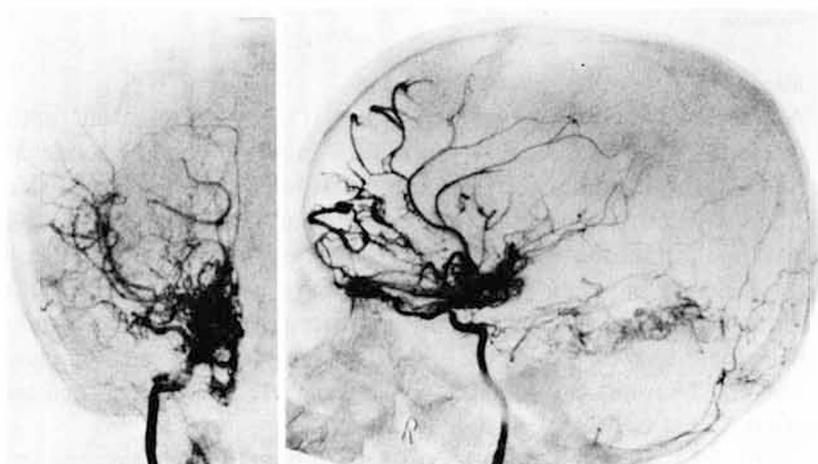
## Results

### *Report of a Representative Case*

A 7-year-old right-handed boy (case 1) had been well until November 23, 1977, the age of 4 years and 9 months, when he suddenly complained of right hemiparesis and aphasia which lasted for 1 month. He was admitted to the Department of Pediatrics of the Niigata University Hospital on the day following the attack. A diagnosis of moyamoya disease was established, by using cerebral angiography. Although the patient showed a gradual recovery, he experienced transient weakness of the right limbs and aphasia on January 28, 1978. The patient was discharged without any neurological deficits on February 11, 1978, after medical treatment.

On May 14, 1979, he suddenly suffered from hemiparesis on the left side which was cleared up in a few days. He was then admitted to the Department of Neurosurgery of the Niigata University Hospital on March 25, 1980. Neurological examination disclosed slight hemiparesis on the left side. The carotid angiography on the right side showed typical findings of moyamoya disease (fig. 1). On April 10, 1980, EMS was performed on the right side. The immediate postoperative course was uneventful, and he was discharged 9 days later. The patient showed gradual improvement of left hemiparesis from 1 month after the operation. In the postoperative carotid angiography on the right side performed 3 months after EMS, almost all branches of the middle cerebral artery were visualized clearly to the peripheral portion through the thickened deep temporal, the middle meningeal, the superficial temporal and the posterior auricular arteries (fig. 2a, b). The abnormal vascular network in the region of the basal ganglia (basal moyamoya vessels) reduced in size as well (fig. 3). Then he began to notice weakness in the right arm. He was readmitted to our department for the left-sided operation on July 27, 1980. On neurological examination, slight weakness of the right arm, and slight dysmetria on the left side were shown. Left-sided EMS was performed on August 7, 1980. Postoperative course was uneventful, and he was discharged 9 days after the operation.

During the next 2–3 months he showed improvement in all of the neurological impairments. He went to school vigorously without any neurological deficits during the time of follow-up, 16 months after the first operation. The postoperative external carotid angiography on the left side performed 7 months after EMS showed similar findings to that on the right



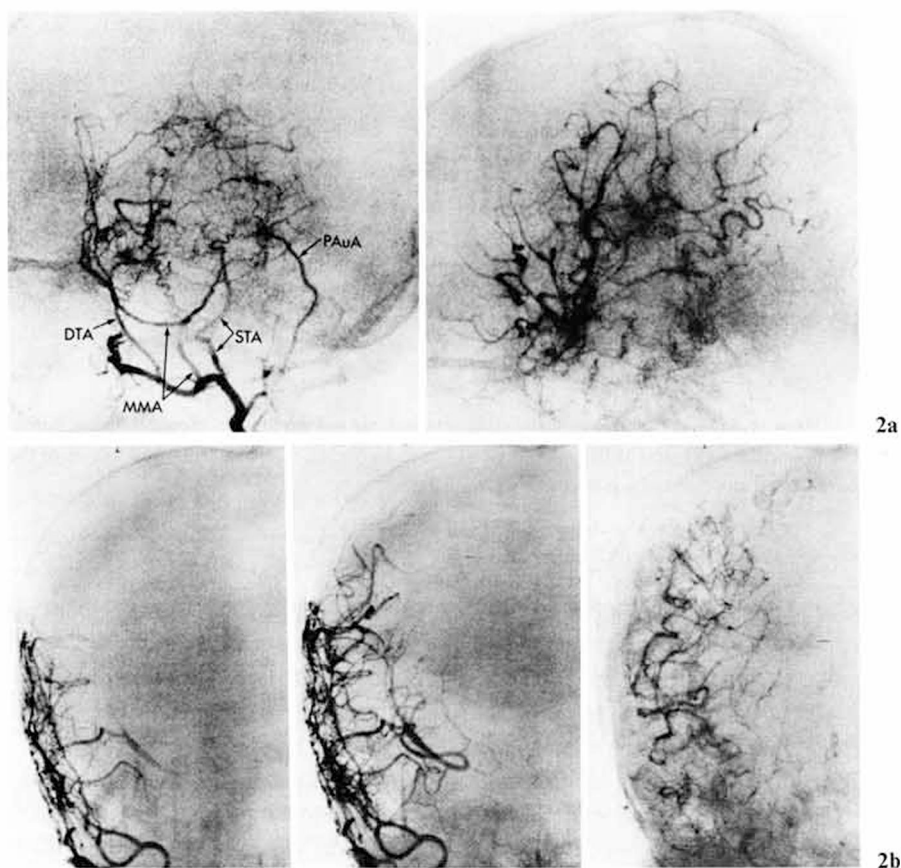
**Fig. 1.** Anteroposterior (left) and lateral (right) projections of the right internal carotid angiogram of case 1 showing occlusion of the carotid bifurcation with the extensive abnormal vascular network in the region of the basal ganglia (basal moyamoya vessels). The anterior and middle cerebral arteries are attenuated but reconstituted through the basal moyamoya vessels. An enlarged ophthalmic artery and a tentorial branch of the internal carotid artery provide transdural anastomotic pathways.

side. Postoperative examination by using the Wechsler intelligence scale for children, 10 months after the first operation, revealed slight improvement in full-scale intelligence quotient (IQ) and remarkable improvement in performance IQ, but slight deterioration in verbal IQ. An awake electroencephalogram (EEG) at rest performed 10 months after the first EMS, showed an improvement such as a decrease of slow waves and an increase of alpha activity (fig. 4). Mean hemispheric value of CBF gradually increased in the postoperative course (fig. 5).

#### *Results in 10 cases*

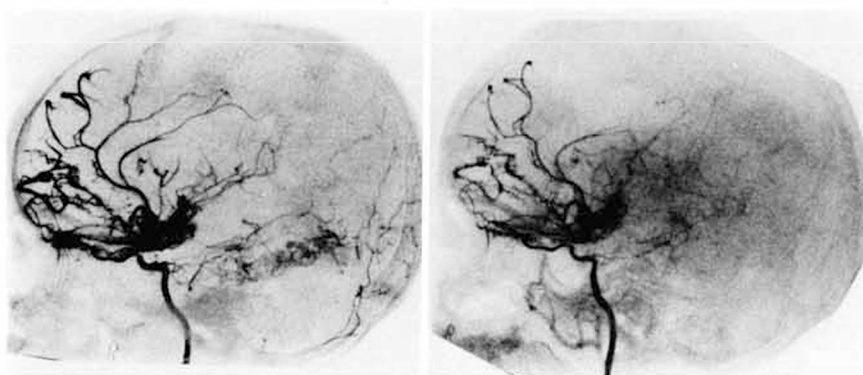
The patients were observed in clinical findings, angiogram, IQ, EEG, and CBF, for from 6 to 26 months (table II).

Transient ischemic attacks (TIA's) which had occurred frequently before the operation, disappeared in 4 out of 7 patients, and improved in frequency and duration in the remaining 3. Paresis of the limbs disappeared in 1 patient and improved in 2. In 2 patients, facial palsy disappeared and dysarthria improved as well. Ataxia disappeared in 2 patients.

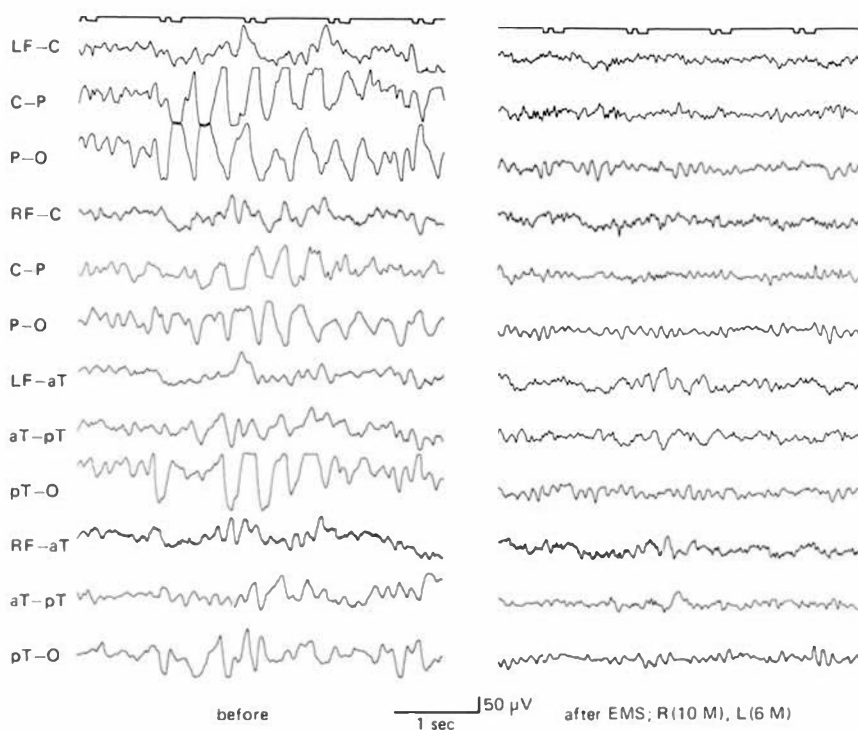


**Fig. 2.** a Lateral projection, in early arterial phase (left), and late arterial phase (right), of the right external carotid angiogram of case 1, 3 months after EMS, showing almost all branches of the middle cerebral artery via the thickened deep temporal (DTA), the middle meningeal (MMA), the superficial temporal (STA), and the posterior auricular (PAuA) arteries. b Anteroposterior projection of the same angiogram as figure 2a showing the bifurcation of the middle cerebral artery in retrograde fashion.

and involuntary movement of the extremities disappeared in 2. Clinically, there were no ineffective cases. Postoperative results were excellent in 3 patients who had neither neurological deficits nor TIA's, and good in 7 patients having slight neurological deficits or less frequent TIA's. At the time of follow-up, 8 patients attended regular school, and only 1 patient



**Fig. 3.** Lateral projection of the right internal carotid angiogram of case 1, taken before the operation (left), and at the same time as figure 2a (right), showing reduction in size of the basal moyamoya vessels, postoperatively.



**Fig. 4.** Awake electroencephalogram of case 1 recorded at rest, before (left), and 10 months after the first operation (right), showing a decrease of slow waves as well as an increase of alpha activity, postoperatively.



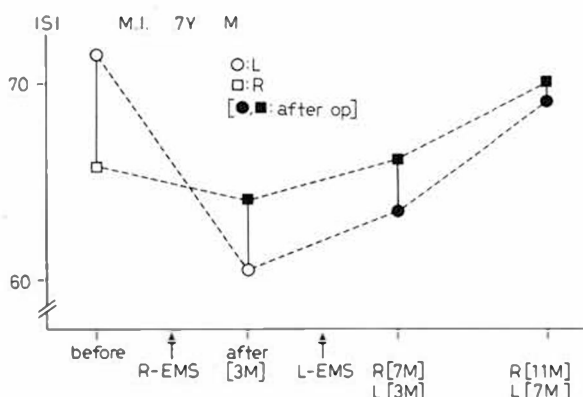
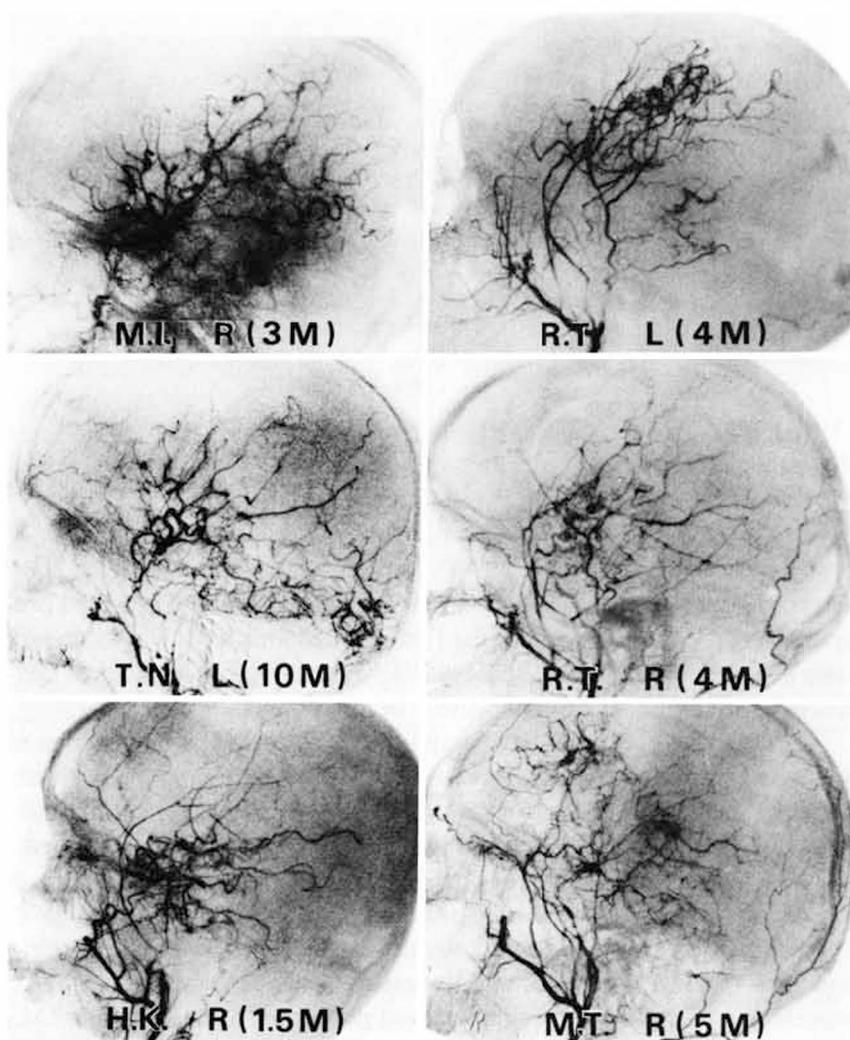


Fig. 5. Repeated measurements of cerebral blood flow (ISI: initial slope index) of case 1 showing preoperative decrease of mean hemispheric value on the left side, and gradual increasing on both sides, postoperatively.

attended a special class for poor learners which she had also attended pre-operatively (case 8). The remaining 1 patient had finished lower secondary class before surgical treatment (case 10). No prolonged neurological deficits were encountered postoperatively in all patients.

Postoperative carotid angiography was performed on 14 sides of 9 patients between 1 month, 3 weeks and 16 months after each operation (table II). Remarkable filling of the middle cerebral arteries mainly via the thickened deep temporal arteries was obtained in eleven sides of 7 patients (fig. 6), but faint filling of the arteries was obtained in three sides of 3 patients. Although external carotid angiography on the left side of 1 patient (case 10) showed only a slightly thickened deep temporal artery and faint visualization of the middle cerebral arteries 2 weeks after EMS, repeated angiography of the same patient performed 5 months after EMS showed marked filling of the middle cerebral arteries. In eight sides of 5 patients, the middle cerebral arteries were filled via not only the deep temporal artery but also the middle meningeal, the superficial temporal and posterior auricular arteries (fig. 2a). The basal moyamoya vessels reduced in size in eight sides of 6 patients (fig. 3), and remained unchanged in six sides of 5 patients.

Full-scale IQ examined between 3 and 21 months after the first operation was improved significantly in 2 patients, remained unchanged in 7, and deteriorated in 1. Performance IQ was improved in 5 patients, and



**Fig. 6.** Lateral projections of the postoperative external carotid angiograms on the right side of case 1 (MI), the left side of case 3 (TN), the right side of case 4 (HK), both sides of case 9 (RT) and the right side of case 10 (MT), showing remarkable visualization of the middle cerebral arteries, respectively. Each numeral indicates number of months after the operation.

remained unchanged in 5. Verbal IQ was improved in 1, remained unchanged in 7, and deteriorated in 2.

Among 15 hemispheres of 10 patients in which postoperative EEG was examined between 2 and 24 months after each operation, improvements in EEG such as increase of alpha activity, decrease of slow waves and disappearance of build up were obtained in ten hemispheres of 7 patients. Postoperative EEG remained unchanged in four hemispheres of 3 patients and revealed an increase of slow waves in only one hemisphere of 1 patient.

Postoperative CBF was measured in 16 hemispheres of all patients 1–4 times between 2 weeks and 24 months after each operation. The mean hemispheric value of CBF increased significantly in eight hemispheres of 5 patients, remained unchanged in six hemispheres of 6 patients, and decreased in two hemispheres of 2 patients. It seemed that postoperative CBF did not increase in the hemispheres with moderate or large low-density lesions in the preoperative computed tomographic scans.

There were complications postoperatively, such as sensory aphasia lasting for 8 months (case 4), dysphagia and dysarthria lasting for 1 week (case 10), motor aphasia lasting for 3 days (case 6), and subcutaneous abscess (case 2). Sensory aphasia was considered to be caused by unsuccessful establishment of STA-MCA anastomosis on the left side. Dysphagia and dysarthria seemed to be caused by hypocapnia during the anesthesia. The cause of the motor aphasia after left EMS might be attributable to minimal compression of the brain by the grafted muscle which was observed in the postoperative computed tomographic scans. Although the verbal IQ deteriorated in the patient complicated by sensory aphasia, the other 3 patients recovered without any neurological deficits.

## Discussion

Moyamoya disease is a cerebrovascular disease consisting of progressive narrowing or occlusion of the internal carotid arteries starting at the site of the carotid siphon, bilateral abnormal vascular networks in the region of the basal ganglia, leptomeningeal anastomoses and multiple transdural external-internal carotid anastomoses. The disorder may occur at any age, but more frequently in the juvenile age-group than in adults. The clinical manifestations in children are cerebral ischemic symptoms and signs, including hemi- and monoparesis, mental retardation, involun-

tary movement of the limbs, and epileptic seizure and headache. It is well known that progression of the disease process with time occurs in clinical [3, 13, 14, 18], angiographic [4, 16, 18, 20], electroencephalographic [2, 3, 12], and computed tomographic findings [22].

Since the pathogenesis of moyamoya disease is still unknown, no effective treatment has been found for this disease. Medical treatment with steroids, vasodilators, and low molecular weight dextran has been disappointing. Superior cervical ganglionectomy and cervical perivascular sympathectomy have been reported to improve the clinical symptoms [21], but are unable to prevent the progression of the disease. The most reasonable approach to the treatment of this chronic multiple-occlusive cerebrovascular disease appears to be construction of anastomotic channels to increase blood supply to the brain.

Several surgical attempts have been made in the past for increasing collateral channels. They are STA-MCA anastomosis [1, 7, 9], EMS [6], encephalo-duro-arterio-synangiosis [15], and omental transplantation [8]. Among these procedures, STA-MCA anastomosis has been performed in most patients with this disease, and reported to be effective in improvement of the cerebral circulation. However, as stated by *Amine et al.* [1], STA-MCA anastomosis is not easily applicable in small children because of the size of their cerebral and superficial temporal vessels. Besides our case (case 4), several cases which worsened after STA-MCA anastomosis in this disease have been reported [17, 24]. Furthermore, moyamoya disease is characterized by not only occlusions of the circle of Willis but also multiple stenotic and/or occlusive lesions of cortical arteries as demonstrated by pre- and postoperative angiography [4, 11]. For this reason, the selection of the arterial branch for anastomosis is very important, and double or triple anastomoses, if feasible, are recommended.

On the other hand, EMS, which is placing of the temporal muscle on the surface of the brain, seems to be easier and safer than STA-MCA anastomosis. Moreover, visualization of the middle cerebral arteries in the postoperative external carotid angiography seems to be shown more widely by EMS than by single STA-MCA anastomosis, in some cases. Although there were cases in which it was possible to perform STA-MCA anastomosis in this series, we performed EMS alone and obtained a satisfactory effect similar to that of STA-MCA anastomosis. However, the effects of EMS alone in clinical findings seem to appear 2–3 months after the operation, more slowly than those of STA-MCA anastomosis.

In three sides of 3 patients (cases 3, 7 and 8), only faint filling of the

middle cerebral arteries in the postoperative external carotid angiography was shown (table II). Among the 3 patients, STA-MCA anastomosis had also been performed on 1 patient (case 7). In this patient, the middle cerebral arteries were visualized markedly via the thickened superficial temporal artery but faintly through the deep temporal artery. In the other 2 patients, large low-density lesions had been present in the temporo-parietal region on the preoperative computed tomographic scans. Furthermore, only a small part of the temporal muscle had been used for EMS to preserve the spontaneous multiple transdural cortical anastomoses in 1 patient (case 8).

There was no complication which seemed to be attributable to EMS in this series except for the motor aphasia in 1 patient. *Matsushima et al.* [15] described that 1 patient experienced focal seizures after EMS which necessitated an increase in anticonvulsants. But we experienced no cases with epileptic seizures postoperatively in this series.

We performed serial fluorescein angiography in several cases, in order to know the epicocerebral microcirculation of this disease [23]. The time intervals from carotid injection of fluorescein dye to the first filling of the cortical arteries were various in each gyrus, and were delayed in most gyri. Moreover, the vessels of some cortical surfaces were not filled even in the last frame at 26.9 s after carotid injection of the dye. Arteriovenous transit-times of the dye were also prolonged in most of the cases. From these fluorescein angiographic findings, the epicerebral microcirculation in moyamoya disease seemed to be isolated in each gyrus or part, and to be various and prolonged in circulation time in most cases.

It is necessary to know the natural history of moyamoya disease for evaluation of the operative results. The study of pediatric patients revealed that this disease showed a progressive course for about 2–3 years, with repeated cerebral ischemic episodes frequently resulting in permanent deficits [13]. *Maki et al.* [14] reported the results of clinical follow-up studies of 24 cases with onset below the age of 13, which had average follow-up periods of 5 years and 9 months. They suggested that the prognoses of moyamoya disease were good in about one third, poor in one third, and somewhere between these two (borderline), in the other third. Furthermore, they pointed out that the factors causing a poor prognosis for mental function were early onset, repeated TIA's followed by residual neurological deficits, symptoms suggesting bilateral or dominant hemispheric lesions, and angiographically widespread occlusion. In our series, 6 patients had both TIA's and completed stroke, and 4 patients had TIA's

only, involving bilateral hemispheres in the courses of all 10 patients. 2 patients (cases 8 and 10) who had had mental retardation before the surgical treatment, improved slightly in mental function postoperatively, but 1 of them attended special classes for poor learners, pre- and postoperatively. None of the patients had poor prognosis for motor function. Although it is not so easy to compare our operative results with natural history, the surgical treatment of moyamoya disease including EMS seems to be effective procedure for preventing the progression of clinical findings caused by cerebral ischemia and increasing CBF.

Because of a small number of cases, and short follow-up periods in this report, further studies and long-term follow-up are required. On the basis of the results in this series, including fluorescein angiographic findings, we believe that EMS is a reasonable and adequate procedure for the purpose of increasing extracranial and intracranial collateral circulation in children with moyamoya disease.

## References

- 1 Amine, A.R.C.; Moody, R.A.; Meeks, W.: Bilateral temporal-middle cerebral artery anastomosis for moyamoya syndrome. *Surg. Neurol.* 8: 3–6 (1977).
- 2 Aoki, Y.; Hiraga, H.; Ichijo, S.: EEG of moyamoya disease. *Electroenceph. clin. Neurophysiol.* 43: 490 (1977).
- 3 Carlson, C.B.; Harvey, F.H.; Loop, J.: Progressive alternating hemiplegia in early childhood with basal arterial stenosis and telangiectasia (moyamoya syndrome). *Neurology, Minneap.* 23: 734–744 (1973).
- 4 Handa, J.; Handa, H.: Progressive cerebral arterial occlusive disease : analysis of 27 cases. *Neuroradiology* 3: 119–133 (1972).
- 5 Henschen, C.: Operative Revaskularisation des zirkulatorisch geschädigten Gehirns durch Auflage gestielter Muskellappen (Encephalo-Myo-Synangiose). *Arch. klin. Chir.* 264: 392–401 (1950).
- 6 Karasawa, J.; Kikuchi, H.; Furuse, S.; Sakaki, T.; Yoshida, Y.; Ohnishi, H.; Taki, W.: A surgical treatment of 'moyamoya' disease. 'Encephalo-myo-synangiosis'. *Neurol. med. chir., Tokyo* 17: 29–37 (1977).
- 7 Karasawa, J.; Kikuchi, H.; Furuse, S.; Kawamura, J.; Sakaki, T.: Treatment of moyamoya disease with STA-MCA anastomosis. *J. Neurosurg.* 49: 679–688 (1978).
- 8 Karasawa, J.; Kikuchi, H.; Kawamura, J.; Sakaki, T.: Intracranial transplantation of the omentum for cerebrovascular moyamoya disease: a two-year follow-up study. *Surg. Neurol.* 14: 444–449 (1980).
- 9 Krayenbühl, H.A.: The moyamoya syndrome and the neurosurgeon. *Surg. Neurol.* 4: 353–360 (1975).
- 10 Kredel, F.E.: Collateral cerebral circulation by muscle graft. Technic of operation with report of 3 cases. *Sth. Surg.* 11: 235–244 (1942).

- 11 Kobayashi, K.; Takeuchi, S.; Tsuchida, T.; Ito, J.: Encephalo-myo-synangiosis (EMS) to moyamoya disease – with special reference to postoperative angiography (Japanese). *Neurol. med. chir., Tokyo* 21: 1229–1238 (1981).
- 12 Kodama, N.; Aoki, Y.; Hiraga, H.; Wada, T.; Suzuki, J.: Electroencephalographic findings in children with moyamoya disease. *Archs Neurol., Chicago* 36: 16–19 (1979).
- 13 Kudo, T.; Fukuda, S.: Spontaneous occlusion of the circle of Willis: a disease entity, its pathology and clinical features (Japanese). *Adv. neurol. Sci.* 20: 750–757 (1976).
- 14 Maki, Y.; Nakada, Y.; Nose, T.; Yoshii, Y.: Clinical and radioisotopic follow-up study of 'moyamoya'. *Child's Brain* 2: 257–271 (1976).
- 15 Matsushima, Y.; Fukai, N.; Tanaka, K.; Tsuruoka, S.; Inaba, Y.; Aoyagi, M.; Ohno, K.: A new surgical treatment of moyamoya disease in children: a preliminary report. *Surg. Neurol.* 15: 313–320 (1981).
- 16 Murphy, M.J.: Progressive vascular changes in moyamoya syndrome. *Stroke* 11: 656–658 (1980).
- 17 Nakagawa, Y.; Shimoyama, M.; Kashiwaba, T.; Suzuki, Y.; Gotoh, S.; Miysaka, K.; Takei, H.; Gotoh, S.; Ohtsuka, K.; Abe, H.; Tsuru, M.: Reconstructive operation of moyamoya disease and its problems (Japanese). *Neurol. Surg.* 9: 305–314 (1981).
- 18 Nishimoto, A.; Takeuchi, S.: Abnormal cerebrovascular network related to the internal carotid arteries. *J. Neurosurg.* 29: 255–260 (1968).
- 19 Risberg, J.; Ali, Z.; Wilson, E.M.; Wills, E.L.; Halsey, J.H., Jr.: Regional cerebral blood flow by <sup>133</sup>Xenon inhalation. Preliminary evaluation of an initial slope index in patients with unstable flow compartments. *Stroke* 6: 142–148 (1975).
- 20 Suzuki, J.; Takaku, A.: Cerebrovascular 'moyamoya' disease. Disease showing abnormal net-like vessels in base of brain. *Archs Neurol., Chicago* 20: 288–299 (1969).
- 21 Suzuki, J.; Takaku, A.; Kodama, N.; Sato, S.: An attempt to treat cerebrovascular 'moyamoya' disease in children. *Child's Brain* 1: 193–206 (1975).
- 22 Takeuchi, S.; Kobayashi, K.; Tsuchida, T.; Imamura, H.; Tanaka, R.; Ito, J.: Computed tomography in moyamoya disease. *J. Comput. assist. Tomogr.* 6: 24–32 (1982).
- 23 Takeuchi, S.; Kobayashi, K.; Tsuchida, T.; Ishii, R.; Tanaka, R.; Ito, J.: Cerebral hemodynamics in patients with moyamoya disease. A study of the epicerebral microcirculation by fluorescein angiography (submitted).
- 24 Yonekawa, Y.; Handa, H.: Surgical treatment of occlusive cerebrovascular diseases (Japanese). *Brain Nerve, Tokyo* 32: 239–255 (1980).