

## Case Report

# The Operculum Syndrome

R. Sandyk and M. J. W. Brennan

---

**Abstract:** A 48-year-old man presented with signs of pseudobulbar palsy. On computed tomography (CT) he was found to have extensive tissue loss in the region of the sylvian fissure and insula bilaterally. This appearance on CT represents the radiological correlate to anatomic descriptions of the operculum syndrome, and is useful in distinguishing the condition from pseudobulbar palsy. **Index Terms:** Operculum syndrome—Pseudobulbar palsy—Computed tomography.

---

The term operculum denotes the small region of the telencephalic mantle covering the insula Reili, and is comprised of contributions from the frontal, temporal, and parietal gyri. Opercular lesions produce a clinical picture similar to pseudobulbar palsy from which differentiation may be difficult. Such differentiation is necessary because the operculum syndrome is not associated with mental impairment or sphincteric incontinence, in contrast to pseu-

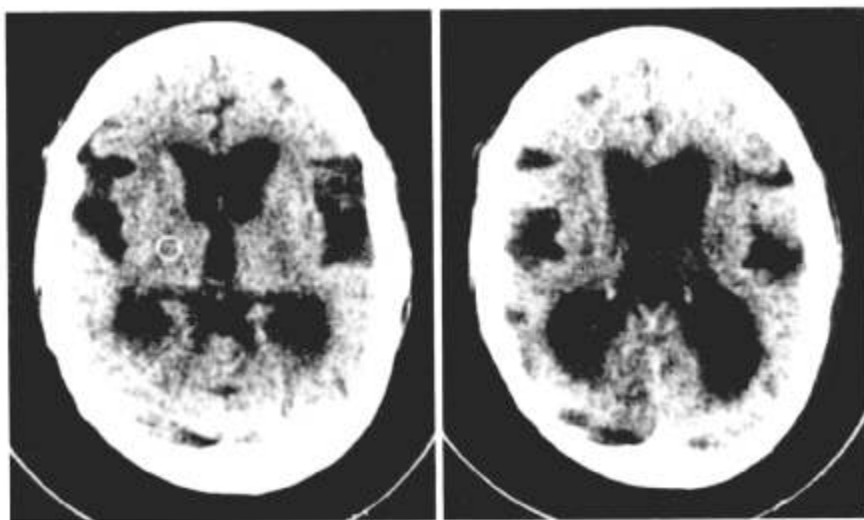
dobulbar palsy, and thus has a better prognosis. We have seen a man who presented with signs suggestive of pseudobulbar palsy in whom computed tomography (CT) scan revealed extensive tissue loss in the region of the sylvian fissure and insula bilaterally. On the basis of this appearance a definitive diagnosis of operculum syndrome could be made.

---

From the Department of Medicine, Hillbrow Hospital, Johannesburg, South Africa (R. Sandyk) and Neurological Unit, Boston City Hospital, Boston, MA (M. J. W. Brennan). Address correspondence and reprint requests to Dr. Sandyk at Department of Medicine, Hillbrow Hospital, Johannesburg 2001, South Africa.

### CASE REPORT

A 48-year-old man presented with a 1 year history of dysphagia, dysarthria, and dysphonia. He was known to be hypertensive and had been on a variety of antihypertensive agents for many years. Two years pre-



**FIG. 1.** CT scan without contrast showing extensive loss of tissue in the region of the sylvian fissures involving the opercula and insulae bilaterally, multiple small infarcts in the frontal, temporal, parietal, and occipital lobes, and dilatation of the ventricular system.

viously he had suffered a cerebrovascular accident which left him with a mild right-sided hemiparesis.

He had left ventricular hypertrophy on chest roentgenogram and on electrocardiographic criteria and had moderate hypertensive changes in the fundi. There was pseudobulbar paralysis of the 5th, 7th, and 9th through 12th cranial nerves in association with marked automato-voluntary dissociation. Muscle tone was increased on the right with brisk deep tendon reflexes and Babinski sign in keeping with an old cerebrovascular accident. No dementia or sphincteric dysfunction were found, but frontal lobe release signs were present bilaterally. Pathological crying or laughing were not observed.

Routine laboratory determinations and cerebrospinal fluid analysis were normal. Computed tomography revealed prominent basal cisterns, extensive tissue loss in the region of the sylvian fissure involving the opercula and insulae bilaterally and approximately symmetrically, several small lucencies in the frontal, temporal, parietal, and occipital regions, and moderate dilatation of the entire ventricular system (Fig. 1).

### DISCUSSION

The operculum syndrome is quite uncommon—there are only about 30 cases on record—and the

only known cause is cerebrovascular accident (1). This may be of embolic or thrombotic nature and is usually related to hypertension. The arteries are all branches of the medial cerebral artery, the orbito-frontal, prerolandic, rolandic, and anterior parietal branches (1). The clinical picture may resemble pseudobulbar palsy to the extent that differentiation may be very difficult. Since the symptoms of impaired deglutition (salivation, difficulty with eating) tend to regress rapidly in operculum syndrome, in contrast with pseudobulbar palsy, and since mental changes and sphincteric dysfunction do not develop, it is important from a prognostic aspect that the distinction be made (1). The appearance noted on CT in this patient makes the diagnosis of operculum syndrome inescapable.

### REFERENCE

1. Bruyn GW, Gathier JC. The operculum syndrome. In: Vinken PJ, Bruyn GW, eds. *Handbook of clinical neurology*, vol 2. Amsterdam: North-Holland Publishing Co, 1969:776–83.