

ders in Children. Philadelphia, WB Saunders Co, 1972, pp 401-402.

3. Canter GJ: Observations on neurogenic stuttering: A contribution to differential diagnosis. *Br J Disord Commun* 1971;12:139-148.

4. Farmer A: Stuttering repetitions in aphasic and nonaphasic brain damaged adults. *Cortex* 1975;11:391-396.

5. Helm NA, Butler RB, Benson DF: Acquired stuttering. *Neurology* 1978;28:1159-1165.

6. Rosenfield DB: Stuttering and cerebral ischemia. *N Engl J Med* 1972;287:991.

7. Logemann JA, Fischer HB, Boshes B, et al: Frequency and co-occurrence of vocal tract dysfunction in the speech of a large sample of parkinsonian patients. *J Speech Hear Disord*

1978;53:47-57.

8. Nakano KK, Zubeixh H, Tyler HR: Speech defects of parkinsonian patients. *Neurology* 1973;23:865-870.

9. Netsell R, Daniel B, Celesia GC: Acceleration and weakness in parkinsonian dysarthria. *J Speech Hear Disord* 1975;50:170-178.

10. Canter GJ: Speech characteristic of patients with Parkinson's disease. *J Speech Hear Disord* 1963;28(pt 1):221-229.

11. Espir MLE, Rose FC: *The Basic Neurology of Speech*. Oxford, England, Blackwell Scientific Publications, 1970.

12. Bloodstein O: *A Handbook on Stuttering*. National Easter Seal Society for Crippled Children and Adults, 1969.

13. Rosenbek JC, Collins M, Massert B: Cortical stuttering. Read before the American Speech and Hearing Association, Washington, DC, Nov, 1975.

14. Rigrinsky S, Morrison EB: Speech changes in parkinsonism during L-dopa therapy. *J Am Geriatr Soc* 1971;18:142-151.

15. Perry AR, Dast PK: Speech assessment in Parkinson's disease, in Rose FC, Capildeo R (eds): *Research in Parkinson's Disease*. London, Pitman Publisher Ltd, 1980, pp 373-384.

16. Sarno M: Speech impairment in Parkinson's disease. *Arch Phys Med Rehabil* 1968;49:269-273.

Aphasia in Subdural Hematoma

Stephen O. Dell, MD; Ramon Batson, MD; David L. Kasdon, MD; Thomas Peterson, MD

● The occurrence of aphasia as the only or dominant symptom of subdural hematoma (SDH) has not been emphasized in the literature. The possible confusion of traumatic aphasia with transient ischemic attacks or stroke has been the object of most recent investigations. Four patients with subacute SDH had aphasia as an initial symptom; the relevant pathophysiologic characteristics were noted in each. These patients had a rapid response to decompression with marked resolution of the aphasia irrespective of immediate or delayed drainage.

(*Arch Neurol* 1983;40:177-179)

Aphasia is known to occur with subdural hematoma (SDH), usually as part of a hemispheric syndrome.^{1,2} Several case reports have dealt with intermittent deficits in SDH that mimic stroke or transient ischemic attacks.^{3,4} We have recently treated four patients in whom language impairment was the predominant aspect of their occurrence; all of these patients suffered from subacute SDH.

REPORT OF CASES

CASE 1.—A 52-year-old left-handed man fell, striking his right shoulder (a hyperabduction injury) and face. There was no loss of consciousness at the time, but a minimal dysnomic deficit was present. His right upper extremity, however, was immediately rendered flaccid and areflexive, with severely impaired sensation. While hospitalized for this presumed brachial plexus

lesion, his aphasia cleared entirely. Twelve days after the injury, a sudden, severe aphasia was noted without other new neurologic deficits. His speech was nonfluent, comprehension was preserved only for the simplest commands, naming and repetition were absent, and he was able to write only his name. A computed tomographic (CT) scan showed a 15-mm, right-sided frontoparietal SDH with a 12-mm right-to-left shift of the midline. On drainage of a 60-mL acute collection of blood from the perisylvian region, no contusion of brain was noted.

The patient's condition then improved dramatically. Within several days, his language deficits fully resolved, and CT demonstrated no residual collection or shift. Function of the right arm was not improved.

CASE 2.—A 58-year-old right-handed diabetic man fell, striking his left hip and head, without loss of consciousness. He suffered headache and neck ache without meningism for three days, when on the following day, an aphasia suddenly developed. His speech was nonfluent, with occasional stereotypy ("yes . . . yes"). He could not comprehend, repeat, name, or write. There was no papilledema. Minimal right hemiparesis was present. A CT scan showed a left-sided subdural collection, with a shift of the frontal horn of that ventricle and obliteration of its occipital horn.

At operation, a thick perisylvian SDH (2 cm) was removed, as well as a similar frontal collection (0.5 cm). His deficits resolved in six days. A CT scan then disclosed a small residual hematoma and a mild left-to-right shift, thought to be secondary to cerebral edema. Aphasia did not recur.

CASE 3.—A 66-year-old right-handed man fell without loss of consciousness but manifested slurred speech, retrograde amnesia for 30 minutes, and a right-sided facial paresis. A CT scan demonstrated a small bilateral almost isodense SDH, without shift. During the following two

months, he demonstrated increasing forgetfulness, gross swings of mood and affect, intermittent slurring of speech, and a persistent mild right hemiparesis. A second scan demonstrated the right-sided SDH to be unchanged, while that on the left side had enlarged. He was alert but confused. Speech was fluent and dysnomic, with gross impairment of comprehension but relative sparing of repetition. There was minimal right hemiparesis and a slightly hemiparetic gait, with inconstant sensory extinction to double simultaneous stimulation.

After drainage of the left-sided collection, the patient demonstrated a dramatic resolution of all language, motor, and sensory deficits.

CASE 4.—A 74-year-old right-handed man fell, striking his head without immediate symptoms. Five weeks later, he suffered the abrupt onset of confusion, aphasia, and a right spastic hemiparesis that spared the face. His aphasia was fluent with perseveration and paraphasic errors. He was severely dysnomic and demonstrated moderate impairment of comprehension and repetition.

A CT scan showed a left-sided temporo-parietal collection (20 mm), with a shift to the right side of 15 mm. The patient underwent craniotomy with evacuation of a large chronic SDH, with an acute component beneath the inner membrane. There was significant cerebral atrophy. The post-operative course was complicated. The hematoma required re-drainage, but ultimately, he made a dramatic recovery from his aphasia. A mild right hemiparesis remained, and there were now newer or unmasked parietal deficits (Gerstmann's syndrome). At that time, a CT scan disclosed a small, resolving residual SDH. The course was marked by worsening confusion, recurrent episodes of dysphasia similar to that originally described, and a persistent mild hemiparesis and parietal deficits. Serial CT scans showed a reaccumulated SDH. The patient's speech disturbance was similar to that of his initial condition but with worsened comprehension and repetition.

Dramatic recovery of language function occurred after a second drainage procedure. Ultimately, full recovery occurred with the exception of a minimal right arm pronation.

Accepted for publication May 8, 1982.

From the Department of Neurosurgery, Tufts-New England Medical Center, Boston. Dr Dell is now with the Seacoast Neurosurgical Group, Dover, NH.

Reprint requests to Seacoast Neurosurgical Group, Rollins Building, 787 Central Ave, Dover, NH 03820 (Dr Dell).

Aphasia Typology							
Patient	Dominant Hemisphere Lesion Location	Fluency	Comprehension	Repetition	Naming	Aphasia Type	Comment
1	R side, frontoparietal	No	Partial	No	No	Broca's	50- to 60-mL collection, associated brachial plexus injury
2	L side, perisylvian	No	No	No	No	Global	Minimal associated R hemiparesis
3	Bilateral temporoparietal	Yes	No	Partial	Partial	Isolation	Bilateral chronic subdural hematoma, chronic cognitive and mood changes
4	L side, temporoparietal	Yes	No	No	Partial	Wernicke's	Intermittent course, episodes of mild hemiparesis and parietal deficit

COMMENT

Of the major clinical reports concerning SDH, many include no mention of language dysfunction in detailed descriptions of clinical appearance.¹⁰⁻²⁶ (In total, these represent more than 1,434 consecutive patients.) Other studies refer to dysphasia in SDH as a rarity.²⁷⁻²⁹

Only two large studies report aphasia in a significant percentage of SDH. McKissock³⁰ described 389 patients, of whom 26 (7%) had unspecified speech symptoms and 39 (10%) had signs. These were approximately equally distributed between acute, subacute, and chronic cases. Few further details are given. Jamieson and Yelland³¹ classified their data as simple or complicated SDH according to whether a surface lesion (contusion or laceration) was present. Aphasia (type undescribed) was seen in 10% (24/249) of the former and 6% (14/224) of the latter groups, although language function often was difficult to evaluate among the more severely injured patients. Eight of these patients had coexistent seizures, making the cause of the dysphasia unclear. No patient in either series had an isolated language deficit.

Isolated speech deficits have been reported in several reviews of SDH.^{4,6,27,32,33} The incidence of aphasia in these more recent studies is considerably less (approximately 1%), but this may reflect different patient populations or attention to the problem. There have been eight patients described with symptoms similar to transient ischemic attacks, secondary to SDH.^{1,5,7,9} Of these, only one patient demonstrated an isolated language deficit. In all, to our knowledge, only three cases of isolated language deficits secondary to SDH (two permanent and one transient) have been reported.^{4,27,32}

Perlmutter²² has suggested several

possible pathophysiologic theories for the effects of SDH that may relate to dysphasia. These include (1) large but reversible local pressure gradients,³⁴ (2) secondary local tissue hypoperfusion as with mass lesions,^{35,36} (3) alterations in oxygen availability in the face of normal partial pressure for oxygen (PaO₂) (R. Morowitz, MD, oral communication, February 1982), and (4) irritative (epileptiform) discharges (more dubious).

Types of aphasia varied in our small series, as they were both fluent and nonfluent in type. One example each was noted of Broca's, global, isolation, and Wernicke's aphasia (Table). This dispersion is similar to that in the literature of closed or missile head injury.³⁷⁻⁴³ A variety of dysarthrias and sensory and motor dysphasias have also been described, reflecting the direction of the compressive or destructive vector. By contrast, ischemic aphasias of thrombotic or embolic origin are far more stereotyped in appearance and evaluation.¹⁻³

The conclusions that emerge from this study are largely clinical. Aphasia in SDH appears from hours to weeks after injury or bleeding. This subacute period may be analogous to the "lucid interval" that is more frequently ascribed to epidural hematomas. When deterioration in language function occurs, it proceeds rapidly; there seems to be a critical threshold for compression of cortical speech areas.

Such aphasias are probably more common than usually recognized. Global deterioration in mental state or frank herniation may easily mask them. Unlike other deficits of SDH, there is dramatic resolution functionally with decompression. Thus, remarkable results are seen even when treatment is delayed as long as two weeks. Nonetheless, prompt treatment is obviously indicated when the

problem is recognized. To our knowledge, the rapid deterioration and equally dramatic response to decompression have not previously been reported in the literature. Because aphasia of sudden onset (either as a reversible neurologic deficit or fixed deficit) is usually ascribed to ischemic vascular disease and an adequate history of trauma may not be forthcoming, such a reversible condition deserves consideration in the examination of the patient with transient ischemic attacks or stroke.

References

1. Benson DF, Geschwind NN: The aphasias and related disturbances, in Baker AB, Baker LH: *Clinical Neurology*. Hagerstown, Md, Harper & Row Publishers Inc, 1976, vol 1, pp 1-28.
2. Geschwind N: Current concepts: Aphasia. *N Engl J Med* 1971;284:654-656.
3. Lhermitte F, Gautier JC: Aphasia, in Vinken PJ, Bruyn GW, Braakman R (eds): *Handbook of Clinical Neurology*. New York, Elsevier North Holland Inc, 1969, vol 4: *Disorders of Speech, Perception, and Symbolic Behavior*, pp 84-104.
4. Groch SN, Hurwitz LJ, Wright IS: Intracranial lesion simulating cerebral thrombosis. *JAMA* 1960;172:1469-1472.
5. Melamed E, Lavy S, Reches A, et al: Chronic subdural hematoma stimulating transient cerebral ischemic attacks: Case report. *J Neurosurg* 1975;42:101-103.
6. Okihito MM, Daly D, Yoss RE: Intermittent aphasia due to mass intracranial lesions. *Mayo Clinic Proc* 1961;36:525-529.
7. Plenge KL, Sonntag VKH: Chronic subdural hematoma causing 'transient ischemic attacks' in a young woman. *Ann Neurol* 1979;6:279.
8. Robin JJ, Maxwell JA, Pirkethly DT: Chronic subdural hematoma simulating transient ischemic attacks. *Ann Neurol* 1978;4:154.
9. Welsh JE, Tyson GW, Winn HR, et al: Chronic subdural hematoma presenting as transient neurologic deficits. *Stroke* 1979;10:564-567.
10. Arseni C, Stanciu M: Particular clinical aspects of chronic subdural hematoma in adults. *Eur Neurol* 1969;2:109-122.
11. Davies FL: Mental abnormalities following subdural hematoma. *Lancet* 1960;1:1369-1370.
12. Echlin F: Traumatic subdural hematoma—acute, subacute and chronic: An analysis of 70 operated cases. *J Neurosurg* 1949;6:294-303.
13. Fell DA, Fitzgerald S, Moiel RH, et al: Acute subdural hematomas: Review of 144 cases. *J Neurosurg* 1975;42:37-42.
14. Fogelholm R, Heiskanen O, Waltimo O: Chronic subdural hematoma in adults: Influence of patient's age on symptoms, signs, and thick-

ness of hematoma. *J Neurosurg* 1975;42:43-46.

15. Gardner WJ: Traumatic subdural hematoma with particular reference to the latent interval. *Arch Neurol* 1932;27:847-858.

16. Kretschmer H: Subdurale Hämatome, in Kretschmer H (ed): *Neurotraumatologie*. Stuttgart, West Germany, Georg Thieme Verlag, 1978, pp 71-75.

17. Laudig GH, Browder EJ, Watson RA: Subdural hematoma: A study of 143 cases encountered during a five-year period. *Ann Surg* 1941;113:170-191.

18. McLaurin RL, Tutor FT: Acute subdural hematoma: Review of 90 cases. *J Neurosurg* 1961;18:61-67.

19. Miller D, Bleasel KF: Study of subdural haematoma. *Med J Aust* 1960;47:1034-1037.

20. Moiel RH, Caram PC: Acute subdural hematomas: A review of 84 cases, a six-year evaluation. *J Trauma* 1967;7:660-666.

21. Northcroft GB: Some experiences in the management of subdural hematoma and spontaneous intracerebral hemorrhage. *Postgrad Med J* 1962;38:409-416.

22. Perlmuter I: Subdural hematoma in older patients. *JAMA* 1961;176:212-214.

23. Ramamurthi B: Acute subdural haematoma, in Vinken PJ, Bruyn GW, Braakman R (eds): *Handbook of Clinical Neurology*. New York, Elsevier North Holland Inc, 1976, vol 24: *Injuries of the Brain and Skull*, pp 275-296.

24. Rosenbluth PR, Arias B, Quartetti EV, et al: Current management of subdural hematoma: An analysis of 100 consecutive cases. *JAMA* 1962;179:759-762.

25. Schisano G, Bruzaco J: Acute and subacute subdural hematomas. *Acta Chir Scand* 1964;128:471-482.

26. Talalla A, Morin MA: Acute traumatic subdural hematoma: A review of 100 consecutive cases. *J Trauma* 1971;11:771-777.

27. Bender MB, Christoff N: Nonsurgical treatment of subdural hematomas. *Arch Neurol* 1974;31:73-79.

28. Endtz LJ: Historical article: Posttraumatic hygroma in the 18th century. *Surg Neurol* 1978;10:305-307.

29. Loew F, Kivelitz R: Chronic subdural haematomas, in Vinken PJ, Bruyn GW, Braakman R (eds): *Handbook of Clinical Neurology*. New York, Elsevier North Holland Inc, 1976, vol 24: *Injuries of the Brain and Skull*, pp 297-328.

30. McKissock W: Subdural hematoma: A review of 389 cases. *Lancet* 1960;1:1365-1369.

31. Jamieson KG, Yelland JDN: Surgically traumatic subdural hematomas. *J Neurosurg* 1972;37:137-149.

32. Cameron MM: Chronic subdural haematoma: A review of 114 cases. *J Neurol Neurosurg Psychiatry* 1978;41:834-839.

33. Heilman KM, Safran A, Geschwind N: Closed head trauma and aphasia. *J Neurol Neurosurg Psychiatry* 1971;34:265-269.

34. Symon L, Pasztor E, Dorsch NWC, et al: Differential pressures recorded in acute epidural expanding lesions: Correlation with local cerebral blood flow by hydrogen clearance in baboons, in Langfitt TW, McHenry LC Jr, Reivich M, et al (eds): *Cerebral Circulation and Metabolism*. New York, Springer-Verlag, 1975, pp

235-237.

35. Daly DD, Svien HJ, Yoss RE: Intermittent cerebral symptoms with meningiomas. *Arch Neurol* 1961;5:287-293.

36. Weisberg LA, Nice CN: Intracranial tumors simulating the presentation of cerebrovascular syndromes: Early detection with cerebral computed tomography. *Am J Med* 1977;63:517-524.

37. Groher M: Language and memory disorders following closed head trauma. *J Speech Hear Res* 1977;20:212-223.

38. Levin HS, Grossman RG, Kelly PJ: Aphasic disorder in patients with closed head injury. *J Neurol Neurosurg Psychiatry* 1976;39:1062-1070.

39. Levin HS, Grossman RG: Behavioral sequelae of closed head injury: A quantitative study. *Arch Neurol* 1978;35:720-727.

40. Mohr JP, Weiss GH, Caveness WF, et al: Language and motor disorders after penetrating head injury in Vietnam. *Neurology* 1980;30:1273-1279.

41. Sarno MT: The nature of verbal impairment after closed head injury. *J Nerv Ment Dis* 1980;168:685-692.

42. Thomsen IV: Evaluation and outcome of aphasia in patients with severe closed head injury. *J Neurol Neurosurg Psychiatry* 1975;38:713-718.

43. Thomsen IV, Skinhoj E: Regressive language and severe head injury. *Acta Neurol Scand* 1976;54:219-226.

Meningeal Sarcomatosis and Multiple Astrocytomas

Steven A. Lukes, MD; Robert Wollmann, MD, PhD; Kari Stefansson, MD

• We report the clinical course and the pathological findings in a 28-year-old woman in whom a chronic, progressive "meningitis" was caused by extensive invasion of the meninges by a primary sarcoma. The patient was also found to have two anatomically and histologically distinct astrocytomas.

(*Arch Neurol* 1983;40:179-182)

Meningeal sarcomatosis is a rare condition in which the meninges and Virchow-Robin spaces are diffusely invaded by sarcoma, with little or no invasion of the parenchyma of the CNS. The tumor may encase the CNS, producing the clinical picture of chronic meningitis. We report a case

in which a primary sarcoma invaded the meninges of the brain stem and spinal cord, manifesting as a progressive meningitis resembling invasion of the meninges by metastatic cancer. In addition, the patient was found to have two anatomically and histologically distinct astrocytomas.

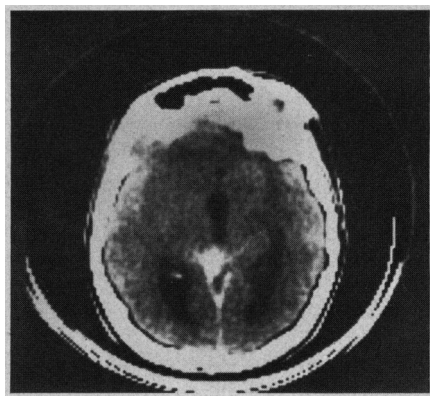
REPORT OF A CASE

A 28-year-old woman was admitted to the University of Chicago Hospital in December 1977 with a two-month history of increasingly severe generalized headache and diplopia on left lateral gaze. During the month before admission, she had had photophobia and a stiff neck. On admission, she was drowsy and appeared to be chronically ill. The vital signs and physical findings were normal. There were no stigmata of phakomatosis. There were striking Kernig's and Brudzinski's signs. Visual fields were full and the acuity was normal. Both pupils were 4 mm in diameter, but the left reacted sluggishly to light. The ocular fundi were normal. There was weakness of abduction of the left eye and bilateral facial weakness, with modest sensorineural hearing loss on the right. The

gag reflex was diminished on the left, and the tongue protruded to the left. The gait was broad based and unsteady. There was modest weakness of the right leg. There was no limb ataxia. Sensation was normal. Tendon reflexes were brisk bilaterally, and sustained clonus was present at the right ankle. The right plantar response was extensor.

A lumbar puncture disclosed an opening pressure of 170 mm of water. There were no cells in the fluid. The protein concentration was 117 mg/dL, and the glucose concentration 24 mg/dL. Cultures were sterile, and cryptococcal antigen was not found. A computed tomographic (CT) scan demonstrated an enhancing density in the left quadrigeminal cistern and enlargement of

Fig 1.—Computed tomographic scan demonstrates density in left quadrigeminal cistern and enlargement of third and lateral ventricles.



Accepted for publication May 20, 1982.

From the Departments of Neurology (Dr Lukes) and Pathology (Neuropathology) (Drs Wollmann and Stefansson), University of Chicago Hospitals. Dr Lukes is now with the Department of Neurology, Memorial Sloan-Kettering Cancer Center, New York.

Reprint requests to Department of Neurology, Memorial Sloan-Kettering Cancer Center, 1275 York Ave, New York, NY 10021 (Dr Lukes).