

## Stroke in neonates

*Five neonates with large cerebral infarctions of arterial origin are presented. Four had severe focal seizures on the first day of life. The fifth, a premature infant, was asymptomatic. The diagnoses were made by computed tomography (CT) scans between 5 and 12 days of life; CT scans obtained in the first few days of life were normal. In the fifth infant, the infarct was hemorrhagic and was also noted by cranial ultrasound. Three of the infants had a history of trauma to the head or neck during labor and birth. Only one was severely asphyxiated at birth. Two apparently are doing well at 1 year of age. Cerebral infarcts of arterial origin in neonates probably have been missed in living patients in the past, but now are recognized in the newborn period by properly timed CT examination. (J PEDIATR 102:605, 1983))*

**Frank L. Mannino, M.D., and Doris A. Trauner, M.D. San Diego, Calif.**

CEREBRAL INFARCTS OF ARTERIAL ORIGIN are rarely documented in the neonatal period, and then usually at autopsy,<sup>1,2</sup> because of the frequent lack of specific clinical signs such as hemiparesis and, in the past, the difficulty and danger of making the diagnosis by arteriogram. In a recent large neonatal autopsy series,<sup>3</sup> the incidence of cerebral infarcts with arterial occlusion was 5.4% (17% in term infants); a quarter of the infarcts involved a major vessel thrombosis. This incidence indicates that many focal cerebrovascular ischemic events are being missed in surviving infants.<sup>2,3</sup>

The cause of such infarcts is frequently unclear and usually inferred. Clinical and pathologic sequelae of presumed neonatal cerebral infarction may be noted later in infancy or childhood, but an etiologic diagnosis is even more difficult to make at that time.<sup>4</sup> The recent availability of noninvasive diagnostic techniques, such as computed tomography (CT) and cranial ultrasound, have made it possible to make this diagnosis safely. We present five neonates with localized cerebral infarction diagnosed over the last year in our Infant Special Care Center. A summary and follow-up of the five patients is given in Table I.

*From the Departments of Pediatrics and Neurosciences, University of California Medical Center, San Diego.*

*Reprint requests: Frank L. Mannino, M.D., Department of Pediatrics/H638A, University Hospital, 225 Dickinson St., San Diego, CA 92103.*

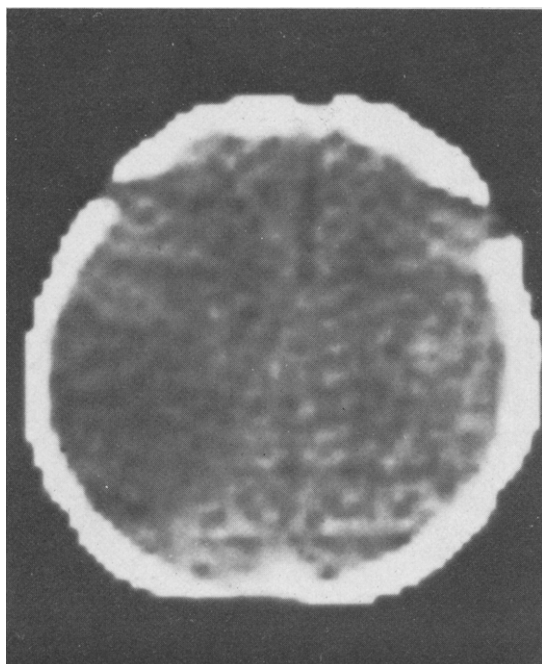
### CASE REPORTS

**Patient 1.** The patient was a 3.0 kg term boy. Late in labor a prolonged variable deceleration in fetal heart rate occurred, and a low/mid forceps delivery was attempted unsuccessfully. A cesarean section was performed. Extraction of the infant was difficult and required traction on the body with manual, upward pushing through the vaginal canal to disengage the head. Apgar scores were 8 and 9 at one and five minutes, respectively.

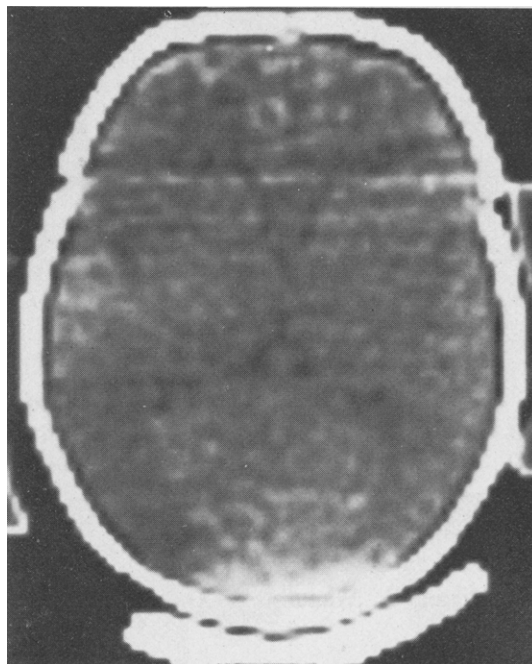
The infant was noted initially to have a right cephalohematoma and a left peripheral facial weakness. At 18 hours of life he had a generalized tonic-clonic seizure, followed by frequent focal right-sided seizures over the next 12 hours. Occasional clinical and electrographic seizure activity persisted for the first four days of life, despite treatment with phenobarbital, phenytoin, and amobarbital. A CT scan at 32 hours showed small ventricles and a minimally depressed skull fracture in the right parietal region. Cranial ultrasound examination was normal. An electroencephalogram on day 4 was abnormal over the left hemisphere. A CT scan on day 5 showed a large area of low density in the left parietotemporal area (Fig. 1).

**Patient 2.** The patient was a term, 3.1 kg boy. During labor thick meconium was noted and late fetal heart rate decelerations were detected. Fetal scalp pH was 7.17, and an emergency cesarean section was performed. The infant had a tight nuchal cord (×4). Apgar scores at one and five minutes were 6 and 8; umbilical artery pH was 7.16. A large succenturiate lobe was present in the placenta. Microscopically, there were severe focal proliferative villitis and chorioamnionitis with fetal capillary occlusions.

The infant appeared normal until 4 hours of age, when he developed focal right-sided tonic-clonic seizures, which recurred over the next 18 hours despite treatment with phenobarbital,



**Fig. 1.** Patient 1. Ct scan without contrast on day 5 of life. Note wedge-shaped left parietotemporal low-density region.



**Fig. 2.** Patient 2. CT scan without contrast on day 7 of life. Note left parietooccipital area of low density.

**Table I.** Summary of clinical findings in five patients with neonatal stroke

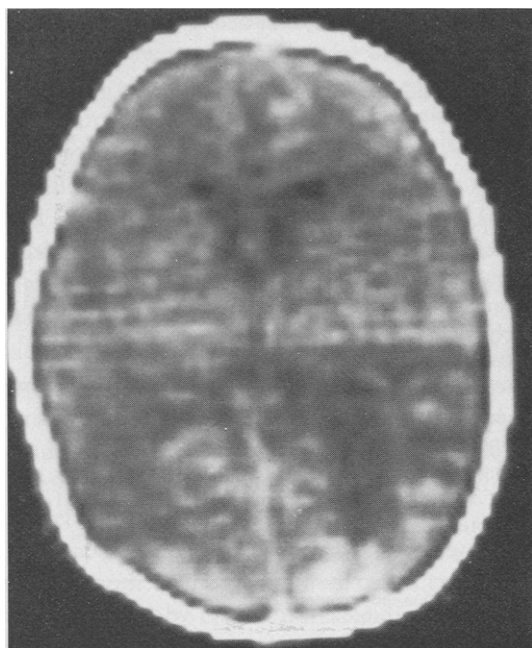
Patient	Apgar Scores	Seizures	EEG	CT diagnosis	Follow-up
1	8/9	18 hr → 4 days; right focal, general	Left hemisphere spikes and sharp waves	Day 5: Left parietotemporal infarct (left middle cerebral artery)	12 mo: Normal physical and developmental* exam; seizure free without anticonvulsants
2	6/8	4 hr → 18 hr; Right focal, general	Bilateral spikes and sharp waves, maximal left central area	Day 7: Left parietooccipital infarct (left middle cerebral artery)	15 mo: Normal physical and developmental* exam; seizure free without anticonvulsants
3	2/7	5 hr → 12 days; Left focal	Bilateral temporal spikes; less activity over right hemisphere	Day 12: Right posterior parietal infarct (right middle cerebral artery)	21 mo: Microcephalic with generalized hypotonia and developmental* delay; recurrent seizures
4	7/8	8 hr → 2 days; Right focal	Left temporal and central spikes	Day 5: Left midparietal infarct (left middle cerebral artery)	Newborn
5	5/6 (Premature infant)	None	Normal	Day 10: Left occipital hemorrhagic infarct. (left posterior cerebral artery); no intraventricular hemorrhage (day 6: Ultrasound)	15 mo: Minimal right shoulder hypotonia; normal development†

\*Revised Developmental Screening Interview, 1980.

†Bayley Scales of Infant Development.

phenytoin, paraldehyde, and diazepam. The EEG on day 2 demonstrated multifocal epileptiform activity. A CT scan on day 1 demonstrated only a subarachnoid hemorrhage, but on day 7 demonstrated a low-density area in the left parietooccipital region (Fig. 2).

**Patient 3.** This was a 2.9 kg postterm girl, delivered of a mother with a history of mitral valve replacement for acute rheumatic fever. Maternal medications included quinidine (first trimester), coumadin (changed to heparin two months prior to delivery), persantine, and bicillin. A prolonged labor was complicated by



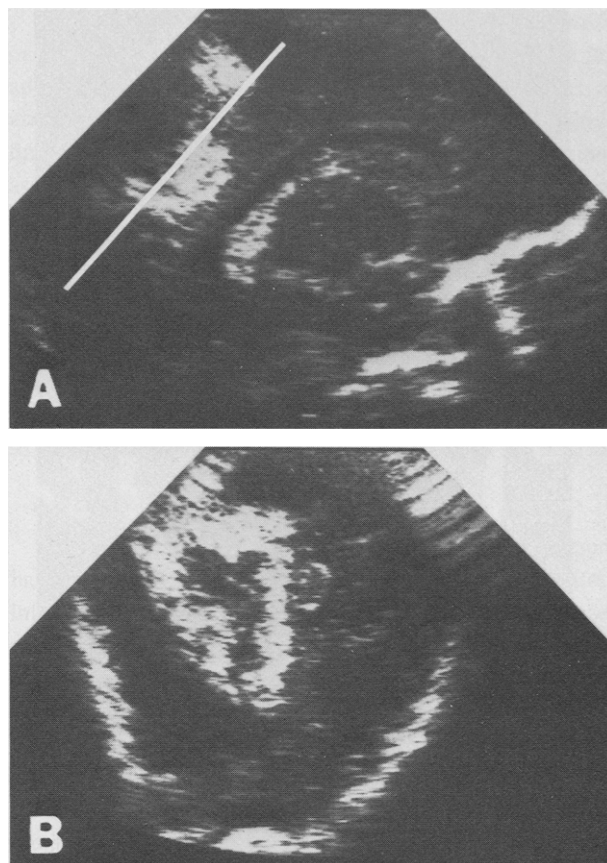
**Fig. 3.** Patient 3. CT scan with contrast at 12 days of life. Note enlarged right occipital horn and right posterior parietal, peripheral low-density area with small regions of contrast enhancement.

preeclampsia and maternal fever. Ten hours prior to delivery a severe late deceleration of four minutes' duration occurred, but heart rate normalized and scalp pH was 7.33. The infant was delivered with the aid of a Malmstrom vacuum extractor. Meconium-stained amniotic fluid was present. Apgar scores at one and five minutes were 2 and 7; umbilical venous pH was 7.26. Mechanical ventilation was necessary for the first 30 minutes of life, after which the infant did well. There was evidence of chorioamnionitis and umbilical vasculitis on examination of the placenta.

At 5 hours the infant developed focal, left-sided tonic-clonic seizures, which recurred frequently for the first 2½ days of life and persisted until day 12 despite treatment with phenobarbital, phenytoin, and paraldehyde. The CT scans on days 1 and 3 were unremarkable. A scan at 12 days revealed a right posterior parietal low-density region (Fig. 3). Cranial ultrasound examination on days 2 and 3 revealed only a small right choroid plexus hemorrhage. An EEG on day 2 was severely abnormal.

**Patient 4.** This was a 3.8 kg term girl. Meconium-stained amniotic fluid was noted. A loose nuchal cord was cut during the vaginal vertex delivery. Apgar scores at one and five minutes were 7 and 8. The placenta was meconium stained.

At 8 hours the infant had tonic-clonic seizure activity of the right arm, which recurred over the next 1½ days despite treatment with phenobarbital and phenytoin. An EEG at 14 hours of age revealed left focal epileptiform discharges. The CT scan on day 1 was normal but on day 5 revealed a localized left midparietal low-density area extending through the gray matter.



**Fig. 4.** Patient 5. **A**, Cranial ultrasound on day 6 of life, left sagittal section (anterior cranium oriented to right). Note echodense area in posterior parietooccipital region, indicative of intracerebral blood. There is no evidence of intraventricular or subarachnoid hemorrhage. (Line represents orientation of "coronal" section in **B**.) **B**, Forty-five degree "coronal" section in same patient, with echodense material in left occipital region.

**Patient 5.** The patient was a 1.1 kg boy of 30 weeks' gestation who was small for gestational age. The mother had severe preeclampsia (BP 200/110), necessitating premature delivery of the infant by cesarean section with epidural anesthesia. Apgar scores at one and five minutes were 5 and 6; umbilical arterial pH was 7.29. The placenta was circumvallate with many infarcts and a small, old abruptio.

The first few days of life were complicated by severe respiratory distress syndrome, interstitial emphysema, and a patent ductus arteriosus. The infant required mechanical ventilation for seven days. Cranial ultrasound examination on day 3 revealed no intraventricular hemorrhage but on day 6 revealed a left parietooccipital echodensity compatible with an isolated intracerebral hemorrhage (Fig. 4). A CT scan on day 10 demonstrated an area of increased density in the same area (Fig. 5) with no contrast enhancement. The EEGs at 6 and 22 days of life were normal. At 1½ months of age, repeat ultrasound examination revealed reabsorption of the blood and an early cystic lesion. At 7 months of age, the area of the lesion could not be approached by ultrasound,

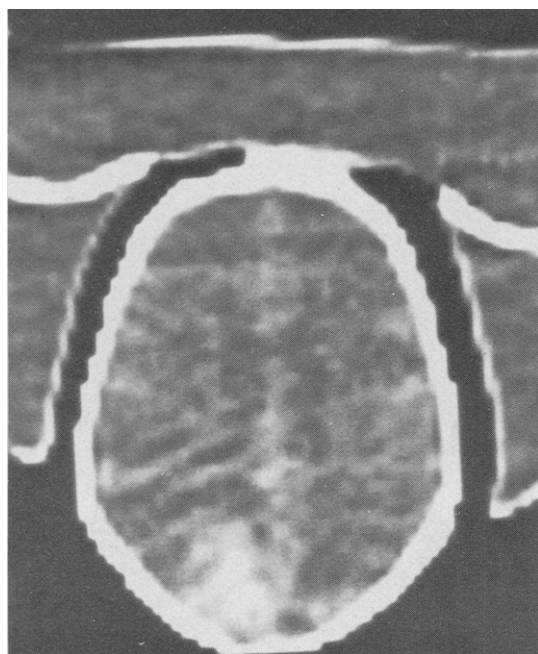


Fig. 5. Patient 5. CT scan without contrast on day 10 of life. Note wedge-shaped left occipital area of increased density, indicative of a hemorrhagic infarct.

but a CT scan revealed an area of porencephaly in the left parietooccipital region, with slightly prominent ventricles.

## DISCUSSION

Cerebral arterial vascular disease with infarction is well documented in older infants and children.<sup>5,6</sup> In neonates, only about 50 cases of cerebral infarction of vascular origin have been reported in the English literature (excluding those resulting from meningitis).<sup>1-4,6-14</sup> All but five<sup>9,10,12,14</sup> of the diagnoses were made at autopsy; most have involved infarcts of the middle cerebral circulation. The high incidence of cerebral infarction in the autopsy series by Barmada et al.<sup>3</sup> suggests underdiagnosis or a change in the occurrence rate. With the advent of neonatal intensive care, neonates who might previously have died are kept alive longer, perhaps allowing time for the infarcts to become apparent.

In our series all five infants survived and the infarcts were diagnosed during the acute episode by CT scan. The four term infants with ischemic infarcts had severe focal seizures in the first day of life, and had localizing features on EEG. Initial CT scans were negative, but became positive for infarction at 5 to 12 days of age.

Information on the appearance and evolution of localized ischemic infarcts by CT exists mainly for adults.<sup>15-17</sup> Initially the scans are normal, but by two days after the ictus, the ischemic area appears as a homogenous, low-

Table II. Causes of stroke in neonates

	Reference
Embolization	
Placental tissue/vessel thrombus	2, 6, 8
Twin-to-twin transfusion syndrome	35
Patent ductus arteriosus	7
Congenital heart disease	2, 3
Sepsis	10, 12
Thrombosis	
Traumatic vascular damage	2, 13, 32
Polycythemia*	33
Stasis/shock	
Meningitis/encephalitis*	36, 37, 38
Tumors	
Consumption coagulopathy	
Ischemia	
Postintraventricular hemorrhage	14
Hypotension/shock	
Hypoxia	

\*Venous circulation more commonly affected.

density (low attenuation coefficient), usually wedge-shaped region, with irregularly defined borders. By four to 10 days, the lesion reaches maximum size; a mass effect may be noted. With small lesions, by three to four weeks the CT scan may return to normal. Larger lesions may progress to cavity formation and cystic degeneration. A variety of enhancement patterns occur with contrast in up to 65% of ischemic infarcts, between one and four weeks after the event<sup>18</sup>; 11% may be appreciated only with contrast.<sup>19</sup> Noncontrast studies are required to avoid obscuring a lesion with minimal hypodensity.<sup>19</sup> The diagnostic accuracy of CT in supratentorial ischemic infarcts is about 90% in adults, if the scan is done at the appropriate time, with and without contrast.<sup>17</sup>

Hemorrhagic infarcts are seen as wedge-shaped areas of high-density, sometimes surrounded by a low-density rim; there is usually no contrast enhancement. Intracerebral bleeds are usually more dense, have a greater mass effect, and do not have the characteristic shape or location of hemorrhagic infarcts. Although neither will be missed on CT, a distinction between the two cannot always be made.<sup>16</sup>

Recent autopsy and clinical correlation of CT head studies in term neonates with severe perinatal asphyxia revealed that a diffuse pattern of low-density areas with gray matter involvement may represent brain ischemia or infarction.<sup>20-22</sup> These changes are thought to result from a general hypoxic-ischemic encephalopathy. Diffuse low-density areas on CT of premature infant brains and periventricular low density in both term and premature infants may be normal findings and are difficult to interpret.<sup>22,23</sup> However, four of our infants had large

localized hypodensities with shapes and locations suggestive of cerebral infarction of vascular origin.

Cranial ultrasound may aid in the diagnosis of hemorrhagic infarction, as in patient 5. The nonhemorrhagic infarcts in our other patients were not appreciated with cranial ultrasound. Ultrasound has been used to diagnose isolated intracerebral hemorrhage in neonates. However, some of the recently reported cases of intracerebral hemorrhages in term infants may in fact represent hemorrhagic infarcts.<sup>25-28</sup>

Radionuclide brain scans can be used to diagnose cerebral infarcts, but the scans also are usually negative in the first week after the infarct.<sup>9</sup> The resolution of newer CT scanners may be greater than that of radionuclide scans, making CT the diagnostic test of choice for detection of cerebral infarction. However, the timing of the CT scan is important. Two scans may be necessary, one early to rule out other disease in need of acute treatment (perhaps obviated by cranial ultrasound), and the second seven days later to document infarction. The presence of an early, normal CT scan in term neonates with severe focal seizures clinically and on EEG should suggest infarction and the need for a repeat CT scan.

Possible causes of stroke in neonates are listed in Table II. Our first two patients (and perhaps the fourth) had direct trauma to the head and neck. Traumatic occlusion of the internal carotid and middle cerebral arteries in older children with nonpenetrating head injuries has been documented.<sup>29,30</sup> The mechanism of occlusion is thought to be stretching of the vessel wall or emboli from the internal carotid artery. Haas<sup>31</sup> described middle cerebral artery occlusion in children with migraine headaches after head trauma. Traumatic injury to cerebral vessels during the birth process has been documented in vertebral vessels<sup>32</sup> and in the internal carotid artery, with intimal damage and thrombus formation.<sup>13</sup>

The cause in patient 3 is less clear, but could relate to trauma and stretching of the neck secondary to use of the Malmstrom vacuum extractor. Some in utero asphyxia also occurred. In utero hypotension, stasis, and vessel thromboses (systemic or placental) may have occurred secondary to the severe bradycardia. In this infant a dysplastic left kidney was diagnosed later, indicating the possibility of multiple embolic phenomena at some time, resulting in damage to more than one organ system. Maternal medications may also have had some effect.

Patient 5 differed from the others in that he was premature and had no obvious birth trauma. The infarct could have been secondary to a placental thromboembolus at the time of birth (with secondary hemorrhage later), as there were many placental infarcts and an old abruption present.

Many instances of older infants with mild hemiparesis or focal seizures are seen with no apparent cause. With the advent of the CT scan, porencephaly or focal areas of atrophy can be demonstrated. At least some of these findings may result from cerebral vascular occlusions associated with difficult deliveries and other perinatal factors.<sup>33,34</sup> It is encouraging that two of our five patients are normal on brief follow-up. Three have no significant evidence of hemiparesis, indicating that many infarcts may not only be missed in the neonatal period, but also may not be detected clinically later in infancy. The possibility exists, however, that neurologic deficits will become apparent later in childhood; long-term follow-up will be needed to determine the prognosis of neonatal stroke.

#### ADDENDUM:

Since submission of this article, left cerebral infarctions have been diagnosed in two additional term infants. Both infants had good Apgar scores (8/9, 7/8) and appeared well until right-sided seizures occurred at 10 and 18 hours of age. The infants continued to do well generally, but seizures persisted (10 and 2 days, respectively) despite anticonvulsant medication. The infarcts were diagnosed with CT scans done at 30 hours of age. A large left hemisphere infarction encompassing most of the left middle cerebral artery circulation was present in one infant, and a high left parietal lobe infarction in the other. The CT scans were done on a fourth-generation scanner (Deltascan 2020, Johnson & Johnson) and may account for the early appreciation of the infarcts.

#### REFERENCES

1. Harvey FH, Alvord EC: Juvenile cerebral arteriosclerosis and other cerebral arteriopathies of childhood: Six autopsied cases. *Acta Neurol Scand* 48:479, 1972.
2. Friede RL: *Developmental neuropathology*. New York, 1975, Springer-Verlag, pp 122-149.
3. Barmada MA, Moosy J, Shuman RM: Cerebral infarcts with arterial occlusion in neonates. *Ann Neurol* 6:495, 1979.
4. Cocker J, George SW, Yates PO: Perinatal occlusion of the middle cerebral artery. *Dev Med Child Neurol* 7:235, 1965.
5. Davie JC, Coxe W: Occlusive disease of the carotid artery in children. *Arch Neurol* 17:313, 1967.
6. Banker BQ: Cerebral vascular disease in infancy and childhood. *J Neuropathol Exp Neurol* 20:127, 1961.
7. Gross RE: Arterial embolism and thrombosis in infancy. *Am J Dis Child* 70:61, 1945.
8. Clark RM, Linell EA: Case report: Prenatal occlusion of the internal carotid artery. *J Neurol Neurosurg Psychiatr* 17:295, 1954.
9. Harwood-Nash DC, Fitz CR: *Neuroradiology in infants and children*. St. Louis, 1976, CV Mosby, p 568.
10. Prian GW, Wright GB, Rumack CM, O'Meara OP: Apparent cerebral embolization after temporal artery catheterization. *J PEDIATR* 93:115, 1978.
11. Ruff RL, Shaw CM, Beckwith JB, Iozzo RV: Cerebral

- infarction complicating umbilical vein catheterization. *Ann Neurol* 6:85, 1979.
12. Schrumph JD, Sehring S, Killpack S, Brady JP, Hirata T, Mednick JP: Correlation of early neurologic outcome and CT findings in neonatal brain hypoxia and injury. *J Comput Assist Tomogr* 4:445, 1980.
  13. Roessmann U, Miller RT: Thrombosis of the middle cerebral artery associated with birth trauma. *Neurology* 30:889, 1980.
  14. Volpe JJ: *Neurology of the newborn*. Philadelphia, 1981, WB Saunders, ch 8, 9, 19.
  15. Davis KR, Taveras JM, New PF, Schnur JA, Roberson GH: Cerebral infarction diagnosis by computerized tomography. *Am J Roentgenol* 124:643, 1975.
  16. Weisberg LA, Nice C, Katz M: *Cerebral computed tomography: A text-atlas*. Philadelphia, 1978, WB Saunders, pp 53-86.
  17. Inoue Y, Takemoto K, Miyamoto T, Yoshikawa N, Taniguchi S, Saiwai S, Nishimura Y, Komatsu T: Sequential computed tomography scans in acute cerebral infarction. *Radiology* 135:655, 1980.
  18. Weisberg LA: Computerized tomographic enhancement patterns in cerebral infarction. *Arch Neurol* 37:21, 1980.
  19. Wing SD, Norman D, Pollock JA, Newton TH: Contrast enhancement of cerebral infarcts in computed tomography. *Radiology* 121:89, 1976.
  20. Flodmark O, Becker LE, Harwood-Nash DC, Fitzhardinge PM, Fitz C, Chuang SH: Correlation between computed tomography and autopsy in premature and full term neonates that have suffered perinatal asphyxia. *Radiology* 137:93, 1980.
  21. Flodmark O, Fitz CR, Harwood-Nash DC: CT diagnosis and short term prognosis of intracranial hemorrhage and hypoxic/ischemic brain damage in neonates. *J Comput Assist Tomogr* 4:775, 1980.
  22. Fitzhardinge PM, Fitz CR, Ashby S: The prognostic value of computed tomography as an adjunct to assessment of the term infant with postasphyxial encephalopathy. *J PEDIATR* 99:777, 1981.
  23. Estrada M, El Gammal T, Dyken P: Periventricular low attenuations: A normal finding in computerized tomographic scans of neonates? *Arch Neurol* 37:754, 1980.
  24. Fitzhardinge PM, Flodmark O, Ashby S: The prognostic value of computed tomography of the brain in asphyxiated premature infants. *J PEDIATR* 100:476, 1982.
  25. Grant EG, Borts F, Schellenger D, McCullough DC, Smith Y: Cerebral intraparenchymal hemorrhage in neonates: Sonographic appearance. *Am J Neuroradiol* 2:129, 1981.
  26. Cartwright GW, Culbertson K, Schreiner RL, Garg BP: Changes in clinical presentation of term infants with intracranial hemorrhage. *Dev Med Child Neurol* 21:730, 1979.
  27. Chaplin ER, Goldstein GW, Norman P: Neonatal seizures, intracerebral hematoma and subarachnoid hemorrhage. *Pediatrics* 63:812, 1979.
  28. Miller GM, Block VD, Lubchenco LO: Intracerebral hemorrhage in a term newborn with hyperviscosity. *Am J Dis Child* 135:377, 1981.
  29. Frantzen E, Jacobsen HH, Therkelsen J: Cerebral artery occlusions in children due to trauma to the head and neck. *Neurology* 11:695, 1962.
  30. Zimmerman AW, Kumar AJ, Gadoth N, Hodges FJ: Traumatic cerebrobasilar occlusive disease in childhood. *Neurology* 28:185, 1978.
  31. Haas DC, Pineda GS, Lourie H: Juvenile head trauma syndromes and their relationship to migraine. *Arch Neurol* 32:727, 1975.
  32. Yates PO: Birth trauma to the vertebral arteries. *Arch Dis Child* 34:436, 1959.
  33. Amit M, Camfield P: Neonatal polycythemia causing multiple cerebral infarcts. *Arch Neurol* 37:109, 1980.
  34. Simmons MA, Levine RL, Lubchenco LO, Guggenheim MA: Clinical note: Serious sequelae of temporal artery catheterization. *J PEDIATR* 92:284, 1978.
  35. Benirschke K, Driscoll SG: *The pathology of the human placenta*. New York, 1974, Springer-Verlag.
  36. Berman PH, Banker BQ: Neonatal meningitis: A clinical and pathological study of 29 cases. *Pediatrics* 38:6, 1965.
  37. Friede RL: Cerebral infarcts complicating neonatal leptomenigitis: Acute and residual lesions. *Acta Neuropathol (Berlin)* 23:245, 1973.
  38. Brown LW, Zimmerman RA, Bilaniuk LT: Polycystic brain disease complicating neonatal meningitis: Documentation of evolution by computed tomography. *J PEDIATR* 94:757, 1979.