

criteria for ventricular parasystole, an infrequently recognized arrhythmia pattern in children.

References

- Schwartz NL, Marriott HJL: Unusual dysrhythmia in a normal child. *Am J Cardiol* 10:302, 1962
- Heinz RE, Eldridge FL: Ventricular parasystole in a 5-year-old child. *Am Heart J* 53:624, 1957
- Rossi P, Motolese M, Passaro G: Idioventricular parasystole with exit block in a subject with complete atrioventricular dissociation. *Am Heart J* 57:775, 1959
- Vedoya R, Battini AR: Un caso de pararritmia mostrando el mecanismo que conduce al bigeminismo extrasistólico. *Rev Argent Cardiol* 6:313, 1959
- Scherf D, Schott A: *Extrasystoles and Allied Arrhythmias*. New York, Grune and Stratton, 1953, p 158
- Fleming GB: Triple rhythm of the heart due to ventricular extrasystoles. *Q J Med* 5:318, 1911
- Chung EKY: Parasystole. *Prog Cardiovasc Dis* 11:64, 1968

Iron Deficiency Anemia, Thrombocytosis, and Cerebrovascular Accident

MICHAEL B. ALEXANDER, MD, Atlanta, Ga

THE MECHANISM of thrombocytosis in iron deficiency anemia is poorly understood. The increase in platelet number may be secondary to an increased thrombopoietic substance, a low level of circulating hemoglobin, a low level of serum or tissue iron, or a combination of these factors.¹ Neurologic sequelae including transient hemiparesis and papilledema have been reported.² Cerebrovascular events in the presence of thrombocytosis may be the result of thrombosis, platelet emboli, or vasospasm.³ In the following case, a patient had a cerebrovascular accident as a result of thrombocytosis related to iron deficiency anemia due to menorrhagia. Treatment with intramuscular and oral iron resulted in a reduction in platelet number. Neurologic deficits improved in one month with speech and physical therapy.

CASE REPORT

A 42-year-old woman was admitted to Grady Memorial Hospital on Jan 20, 1980, because of right hemiparesis and aphasia. She had been in good health except for heavy menses, and there was no history of stroke, hypertension, head trauma, seizures, intravenous drug use, heart disease, or oral contraceptive use. On the day of admission, she had had acute onset of right-sided face and arm weakness. After brief resolution, the weakness returned and, in addition, aphasia was noticed.

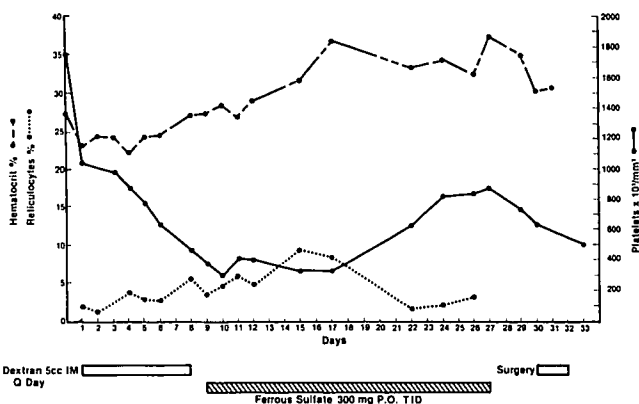
On examination the patient was a well developed, well nourished woman, who was obtunded and unable to answer questions. Her temperature was 36.7 C, pulse 96/min and regular, and blood pressure 165/90 mm Hg. Her pupils measured 5 mm, the disk margins were sharp, and there were no hypertensive changes. Carotid pulses were 2/4 without bruits. There was a grade 2/6 systolic ejection murmur heard throughout the precordium, radiating to the carotids. The spleen was not palpable. Pelvic examination revealed a 20-week-sized firm, movable central pelvic mass. No external hemorrhoids were found. The stool was negative for occult blood. Peripheral pulses were 3/4 in the radial and the right femoral arteries. The rest of the pulses were unobtainable. There was a right central facial weakness with 2/5 strength in the right upper and

lower extremities and 5/5 strength on the left. Biceps, brachioradialis, and knee jerk reflexes were 3/4. Right ankle jerk was 1/4. Triceps and left ankle jerk reflexes were absent. A right Babinski sign was present. Sensation to pinprick was decreased on the right.

Hematocrit was 27.4% with mean corpuscular volume (MCV) of 62 cu μ and mean corpuscular hemoglobin (MCH) of 28.4%. White blood cell count was 11,800/cu mm with 88% segmented neutrophils, 8% lymphocytes, 3% monocytes, and 1% basophils. Platelet count was 1,736,000/cu mm. Peripheral blood smear showed hypochromic, microcytic red cells with schistocytes and basophilic stippling. Serum iron was 19 μ g/dl with total iron binding capacity of 595 μ g/dl and a percent saturation of 3. Serum ferritin was 8 ng/ml. The tube test for hemoglobin S (Sicklelex) was negative. Broad spectrum Coombs' and indirect Coombs' tests were negative. The relative reticulocyte count was 1.9%, fibrinogen level was 301 mg/dl (normal, 200 to 400 mg/dl), and fibrin split products, less than 10 μ g/ml. Prothrombin time was 10.2 sec (control 10.2 sec) and partial thromboplastin time (PTT) 29.4 sec (control 29.5 sec). Template bleeding time was 3.5 min. The SMA-18 examination showed a decreased serum sodium of 131 mEq/L. The urine was negative for HCG. Results of urinalysis, chest x-ray film, and ECG were negative.

Computerized tomography (CT) of the head was negative. Lumbar puncture showed an opening pressure of 255 mm water. The CSF glucose was 59 mg/dl; the VDRL and Gram stain were negative. Culture of CSF and culture of blood on two occasions were negative.

The patient was treated briefly with intravenous heparin, and later with dextran infusion, aspirin 700 mg by mouth every four



Hematocrit (broken line), platelet count (unbroken line), and reticulocyte count (dotted line) in a patient with iron deficiency anemia receiving intramuscular and oral iron therapy.

From the Departments of Medicine, Emory University School of Medicine, and Grady Memorial Hospital, Atlanta, Ga.

Reprint requests to Michael B. Alexander, MD, 2803 Evelyn Court, Vienna, VA 22180.

hours, and dipyridamole (Persantine) 50 mg by mouth every six hours. After a 0.5 ml test dose of intramuscular iron dextran, the patient was given 5 ml daily (Figure). After eight days, iron was replaced with ferrous sulfate, 300 mg by mouth three times a day. Bone marrow aspirate showed increased cellularity with increased megakaryocytes, and an M:E ratio of 1:1. A normal maturation sequence was found with prominent erythrophagocytosis. Iron stores were absent. Bone marrow biopsy showed one small lymphoid aggregate with no evidence of tumor. Antinuclear antibody determination was negative and the sedimentation rate was 50 mm/hr Westergren.

Pelvic CT showed a vascular mass extending from the level of the lower poles of the kidneys to the level of the uterus. Dilatation and curettage revealed tissue consistent with submucosal myomas. Excretory urography showed hydronephrosis of the right kidney with renal function intact. Upper gastrointestinal series and barium enema examination were negative.

On the 30th hospital day, a total abdominal hysterectomy was performed with removal of a right ovarian tumor. Many leiomyomas were found with a heavily calcified benign adenofibroma of the right ovary. At discharge the patient had good use of the right upper extremity, could walk with a cane, and the aphasia had resolved.

COMMENT

Thrombocytosis is a well known complication of iron deficiency anemia.¹ Schloesser et al¹ studied 46 patients with iron deficiency anemia. The mean platelet count was 499,000/cu mm or about twice that of controls. Of these 46, 27 had menorrhagia as a contributing factor. In 21, it was the only attributable factor.

Karpatkin et al² postulate a two-compartment system of thrombopoiesis, regulated to some extent by iron, which may be required for inhibition of a platelet-producing factor called thrombopoietin. This is the "inhibitor compartment." In the absence of iron, thrombocyte function is raised above steady state levels. In addition, iron is required for synthesis of an essential component of the platelet, such that some iron must be present to sustain thrombopoiesis. This is the "essential component compartment."²

In several reported series of patients with iron deficiency anemia, platelet counts returned to normal with iron therapy.⁴ Gross et al⁴ studied iron-deficient infants and children. Replacement with intramuscular or intravenous iron resulted in peak reticulocytosis after about five days. Platelet counts, after an initial increase, returned to normal about ten days after initiation of therapy. Peak reticulocytosis corresponded to peak thrombocytosis.⁴ This patient did not show an

initial rise in platelet count, and reduction to normal platelet count took roughly the same amount of time as reported in other studies.^{4,5} If one follows the course of the patient from the initiation of oral iron therapy, then the response is similar to those of iron-deficient patients who have replacement therapy with oral iron alone.⁴ The platelet count initially drops; the peak reticulocyte count corresponds to the lowest, rather than the highest, platelet count; and a secondary peak platelet count occurs.

A completed cerebrovascular accident in a patient with thrombocytosis secondary to iron deficiency anemia has not been previously reported. Knizley and Noyes⁵ reported a patient with iron deficiency anemia and transient weakness of the right upper extremity, preceded by headache, giddiness, and blurring of vision. Platelet count was 1,015,000/cu mm and responded well to oral iron replacement. Treatment, as it did in this patient, causes a rapid decrease in the number of platelets in the circulating pool. The decline in platelet number after initiation of iron therapy closely matches the normal half-life of platelets tagged with diisopropyl fluorophosphate.^{5,6}

SUMMARY

A patient who would otherwise be at low risk for cerebrovascular accident had a right hemiparesis and aphasia. Evaluation revealed iron deficiency anemia secondary to menorrhagia and marked thrombocytosis, which responded to intramuscular and, later, oral iron replacement. Hemiparesis and aphasia resolved after a month.

Acknowledgment. I thank James R. Eckman, MD, for his consultation.

References

1. Schloesser LL, Kipp MA, Wenzel FJ: Thrombocytosis in iron deficiency anemia. *J Lab Clin Med* 66:107-114, 1965
2. Karpatkin S, Garg SK, Freedman ML: Role of iron as a regulator of thrombopoiesis, editorial. *Am J Med* 57:521-525, 1974
3. Olivarius BF: Cerebral manifestations in thrombocythemia. *Acta Psychiatr Scand* 32:77-82, 1957
4. Gross S, Keefer V, Newman AJ: The platelets in iron deficiency. I. The response to oral and parenteral iron. *Pediatrics* 34:315-323, 1964
5. Knizley H, Noyes WD: Iron deficiency anemia, papilledema, thrombocytosis and transient hemiparesis. *Arch Intern Med* 129:483-486, 1972
6. Mustard JF, Rowsell HC, Murphy EA: Platelet economy (platelet survival and turnover). *Br J Haematol* 12:1-24, 1966