

vasculitis has been pathologically confirmed<sup>5,6</sup> in two cases of intracranial hemorrhage related to amphetamine abuse. Narrowing or beading of cerebral vessels has been observed angiographically in a number of amphetamine abusers studied for various reasons,<sup>7</sup> including six patients with intracranial hemorrhage.<sup>1,8,9</sup> However, vasculitis was confirmed pathologically in only one of these cases.<sup>6</sup> In other cases, the radiologic appearance of arterial narrowing may have been related to arterial spasm caused by subarachnoid hemorrhage<sup>8</sup> or by a direct action of the drug on arterial smooth muscle.<sup>4</sup>

The role of hypertension in precipitating hemorrhage from AVMs remains uncertain.<sup>10</sup> In the present case, however, hemorrhage from an AVM occurred within minutes of an

IV injection of methamphetamine, suggesting the possibility that hypertension induced by the noradrenergic stimulation associated with amphetamine injection<sup>11</sup> contributed to the rupture of a preexisting AVM. Radiologic evaluation of similar cases may provide further documentation of this association.

Michael J. Aminoff, MD, provided editorial assistance.

#### References

1. Delaney P, Estes E: Intracranial hemorrhage with amphetamine abuse. *Neurology* 1980; 30:1125-1128.
2. Margolis MT, Newton TH: Methamphetamine arteritis. *Neuroradiology* 1971;2:179-182.
3. Citron BP, Halpern M, McCarron M, et al: Necrotizing angitis associated with drug abuse. *N Engl J Med* 1970;283:1003-1011.

4. Rumbaugh CL, Bergeron RT, Scanlan RL, et al: Cerebral vascular changes secondary to amphetamine abuse in the experimental animal. *Radiology* 1971;101:345-351.

5. Weiss SR, Raskind R, Morganstern NL, et al: Intracerebral and subarachnoid hemorrhage following the use of amphetamine. *Int Surg* 1970;53:123-127.

6. Kessler JT, Jortner BS, Adapan BD: Cerebral vasculitis in a drug abuser. *J Clin Psychiatry* 1978;39:559-564.

7. Rumbaugh CL, Bergeron RT, Fang HCH, et al: Cerebral angiographic changes in the drug abuse patient. *Radiology* 1971;101:335-344.

8. Cahill DW, Knipp H, Mosser J: Intracranial hemorrhage with amphetamine abuse. *Neurology* 1981;31:1058-1059.

9. Edwards KR: Hemorrhagic complications of cerebral arteritis. *Arch Neurol* 1977;34:549-552.

10. Perret G, Nishioka H: Report on the cooperative study of intracranial aneurysms and subarachnoid hemorrhage. *J Neurosurg* 1966; 25:467-490.

11. Goodman AG, Goodman RS, Gilman A (eds): *The Pharmacologic Basis of Therapeutics*. New York, Macmillan Publishing Co Inc, 1980, pp 80-81, 160-162.

## Focal Dystonia and Lacunar Infarction of the Basal Ganglia

### A Case Report

Louis S. Russo, Jr, MD

Dystonia, a movement disorder first described by Oppenheim in 1911,<sup>1</sup> is most often of idiopathic origin. Although symptomatic dystonia related to specific pathologic processes does occur,<sup>2</sup> persistent focal dystonia secondary to a vascular lesion is uncommon.<sup>3</sup> We report a case of focal dystonia associated with a lacunar infarction in the contralateral basal ganglia.

#### REPORT OF A CASE

A 56-year-old hypertensive man had a seven-month history of involuntary movement of his left upper extremity. The condition had begun abruptly and was not associated with weakness or sensory disturbance in the affected limb. The movements were slow and caused the patient's fingers to assume unusual positions. Activity exacerbated the movements. No other part of the body was affected.

Hearing loss, vertigo, tinnitus, and mild incoordination in the left upper extremity had begun abruptly two months before the onset of the movement disorder. An audiogram confirmed a sensorineural hearing loss in the left ear. Computed tomographic (CT) scan of the brain and cerebral angiogram were normal. The diagnosis was a

limited brainstem infarction on the left. Symptoms gradually cleared, and he had been neurologically asymptomatic for several weeks before the onset of the movement disorder.

Examination results were normal, except for the condition in the left upper extremity. The left hand and forearm showed involuntary movements that produced an unusual posture, with hyperpronation and flexion at the wrist, extension of the fingers, and opposition of the thumb. There was an evident increase in tone in the affected muscle groups. There was no weakness, reflex abnormality, or sensory dysfunction. No carotid bruits were heard.

A CT scan of the brain disclosed two small, low-density areas in the region of the right lenticular nucleus. These areas did not enhance with contrast (Figure).

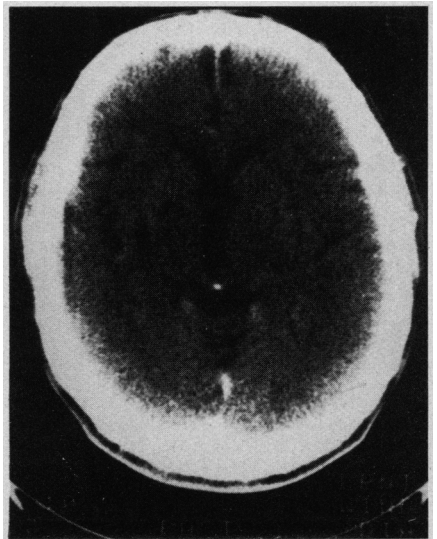
The patient was treated with haloperidol. The dosage was gradually increased to 2 mg three times a day. A substantial decrease in dystonic movements occurred. He has now been observed for an additional eight months. An attempt to discontinue the haloperidol therapy after six months produced an increase in the dystonia. He is presently well, is being maintained on 1-mg regimen three times a day, and has not experienced dystonic movements in any other body part.

#### COMMENT

The abnormal movements of this man's left hand were slow, sustained,

and twisting. They produced an unusual posture in which the wrist was flexed and pronated, the fingers extended, and the thumb moderately opposed. Lacunar infarcts affecting the basal ganglia are common, but clinically evident movement disorders attributable to them are uncommon.<sup>4</sup> However, a recent report of hemicho-

Unenhanced computed tomographic scan demonstrating two lacunar infarctions in right corpus striatum.



Accepted for publication Dec 18, 1981.

From the Department of Neurology, University Hospital of Jacksonville (Fla).

Reprint requests to University Hospital, 655 W Eighth St, Jacksonville, FL 32209 (Dr Russo).

rea-hemiballismus associated with a lacunar infarction has appeared,<sup>5</sup> and the authors offered possible explanations for the rarity of an associated disorder of movements. Folstein et al<sup>6</sup> reported a case resembling Huntington's disease associated with multiple bilateral lacunar infarcts in the corpus striatum. Although the association is tenuous, it is tempting to ascribe the dystonia of our patient to the lesions of the contralateral basal ganglia.

The literature on the association between focal dystonia and vascular lesions is limited. In 1929<sup>7</sup> Sterling described two patients. One, however, showed generalized involvement of the trunk muscles, and the second also had choreoathetotic movements of the legs. Neither was subjected to autopsy studies. Subsequent reports have described an association with an angiomatous condition in the putamen and état criblé,<sup>8</sup> striatal ischemic necrosis,<sup>9</sup> and arteriovenous malformation of the basal ganglia.<sup>10</sup> Zeman and Whitlock<sup>3</sup> briefly mentioned five patients who had a restricted form of dystonia affecting the facial and lingual muscles and hands. Although they suspected cerebral arteriosclerosis as the cause, no report of pathologic findings was given. The authors reviewed the literature and concluded,

"We have been unable to find recorded instances in which discrete focal vascular lesions of any localization have produced predominantly dystonic manifestations." More recently, Burke et al,<sup>11</sup> in a report of delayed-onset dystonia associated with static encephalopathy, described two cases presumably related to cerebral infarction. In neither case was the dystonia truly focal, however. One case with dystonia affecting the face and upper extremity was associated with CT evidence of infarction in the distribution of the contralateral middle cerebral artery. No reference was made to abnormality in the basal ganglia. The second case with dystonia affecting the face, arm, and leg had no confirmatory evidence of infarction.

Our case does provide clinical evidence that a focal vascular lesion of the corpus striatum may produce focal dystonia. Although this man did have a transient episode of presumed brainstem dysfunction two months before the onset of the dystonia, one can only speculate on the importance of this condition relative to the present symptoms. It is possible that the dystonia developed because of the combined effect of the basal ganglia lesion and some persistent, subclinical brainstem dysfunction. It seems more likely, however, to be related to the

lesion in the contralateral corpus striatum alone.

#### References

1. Oppenheim H: Uber eine eigenartige Drampfkrankeheit des Kindlichen Alters (Dysbasia lordotica progressiva, Dystonia musculorum deformans). *Neurol Centralbl* 1911;30:1090-1107.
2. Fahn S, Eldridge R: Definition of dystonia and classification of dystonic states, in Eldridge R, Fahn S (eds): *Advances in Neurology*. New York, Raven Press, 1976, vol 14: *Dystonia*, pp 1-5.
3. Zeman W, Whitlock CC: Symptomatic Dystonias, in Vinken PJ, Bruyn GW (eds): *Handbook of Neurology*, ed 1. New York, Elsevier North Holland Inc, 1968, vol 6: *Diseases of the Basal Ganglia*, pp 544-566.
4. Mohr JP, Caplan LR, Melsk JW, et al: The Harvard cooperative stroke registry: A prospective registry. *Neurology* 1978;28:754-762.
5. Kase CS, Maulsby GO, deJuan E, et al: Hemichorea-hemiballismus and lacunar infarction in the basal ganglia. *Neurology* 1981;31:452-455.
6. Folstein S, Abbott M, Moser R, et al: Hereditary disorders of dystonic movement. *Johns Hopkins Med J* 1981;148:104-113.
7. Sterling MV: Le syndrome dystonique de la vieillesse. *Rev Neurol* 1929;1:937-941.
8. Foerster O: Mobile spasm of the neck muscles and its pathologic basis. *J Comp Neurol* 1933;58:725-735.
9. Lopez Aydillo NR, Sanz Ibanaz J: A proposito de un caso de distonia de torsion (variante miostatice o paralitica) en una diabetica glucosurica. *Trab Inst Cajal Invest Biol* 1956;48:81-108.
10. Markham CH, Rand RW: Physiological and anatomical influences on dystonia. *Trans Am Neurol Assoc* 1961;86:135-137.
11. Burke RE, Stanley F, Gold AP: Delayed-onset dystonia in patients with 'static' encephalopathy. *J Neurol Neurosurg Psychiatry* 1980;43:789-797.

## Traction Injury of Peroneal Nerve Caused by Minor Athletic Trauma Electromyographic Studies

Erich W. Streib, MD

Adduction injuries of the knee joint with rupture of the lateral ligaments may lead to a severe traction injury of the peroneal nerve.<sup>1,2</sup> Less well-known injuries include minor traction or stretch injuries of the peroneal nerve, as may be caused by slipping or turning of the leg or sud-

den stretching while serving in tennis.<sup>3</sup> These injuries may or may not be associated with musculoskeletal trauma, such as ankle sprains or fractures.

I describe a patient with such a traction injury of the peroneal nerve. The electromyographic (EMG) findings shed additional light on the pathogenetic mechanisms of such injuries.

to avoid the racquet of his opponent. He sustained an eye injury; while hospitalized for this injury, he noticed that he could not extend his left great toe. He denied pain in the leg, ankle, or back, or abnormal sensation. There was no early improvement, but six months after the injury, only weakness of extension of the great toe was evident. One year after the injury, strength was almost normal.

#### EMG FINDINGS

The initial study was performed six months after the injury. Results of nerve conduction studies of the right

Accepted for publication April 1, 1982.  
From the Department of Neurology, University of Nebraska Medical Center, Omaha.  
Reprint requests to Department of Neurology, University of Nebraska Medical Center, 42nd Street and Dewey Avenue, Omaha, NE 68105 (Dr Streib).

#### REPORT OF A CASE

During a racquetball game, a 25-year-old man suddenly turned on his left leg, trying