

ASTEREOGNOSIS AND DISSOCIATED LOSS OF FRONTAL OR PARIETAL COMPONENTS OF SOMATOSENSORY EVOKED POTENTIALS IN HEMISPHERIC LESIONS

DETAILED CORRELATIONS WITH CLINICAL SIGNS AND COMPUTERIZED TOMOGRAPHIC SCANNING

by F. MAUGUIÈRE, J. E. DESMEDT *and* J. COURJON

(From the EEG Department, Hôpital Neurologique, Faculté de Médecine Lyon Nord, 69394 Lyon Cedex 3, France, and the Brain Research Unit, University of Brussels, Brussels 1000, Belgium)

SUMMARY

Detailed clinical sensory and motor signs were correlated case by case with somatosensory evoked potentials (SEP) in 22 selected patients with a single circumscribed hemisphere lesion. The lesions collectively mapped out a variety of cerebral sites from the anterior frontal to the posterior parietal regions. SEPs were averaged from 8 standard scalp sites with an earlobe reference electrode, so that parietal N20-P27-P45 were differentiated from prerolandic P22-N30 SEP components. SEP wave forms to stimulation on the unaffected side served as the patient's own control.

A complete parietal lesion produced contralateral hemianaesthesia without upper motor neuron signs and eliminated the parietal N20-P27-P45 while the prerolandic P22-N30 persisted at usual latencies. The neural generators for the N20 and the P22 components are thus distinct. It is also proposed that direct, short latency pathways convey somatosensory inputs to the motor cortex, independently of connections *via* parietal areas 2 and 5. Enhancement of P22-N30 after chronic parietal lesions suggests collateral reinnervation by residual inputs after partial deafferentiation of prerolandic cortex.

Small postcentral lesions produced astereognosis (with preserved tactile and deep sensation) and reduced or eliminated the N20 and P27 SEP components, but did not affect the P22-N30 components. Precentral lesions with severe hemiplegia (but not prefrontal lesions) eliminated the prerolandic P22-N30 SEP components and did not alter the parietal N20-P27-P45 components. The data are pertinent to the understanding of the pathophysiology of somatosensory deficits and for the diagnostic use of SEPs in cerebral lesions.

INTRODUCTION

The upper motor neuron signs and somatosensory deficits resulting from cortical lesions in the rolandic region can be dissociated to various extents in patients with more restricted lesions involving appropriate subregions. Sensory deficits of the

Request for reprints to Professor J. E. Desmedt, Brain Research Unit, 115 Boulevard de Waterloo, 1000 Brussels, Belgium.

cortical type generally involve spatial and discriminative aspects which are at least in part expressed in the term stereognosis. Loss of this capacity or astereognosis is the failure to identify objects by active palpation, in the absence of visual or auditory information. Astereognosis of the hand opposite to a central lesion implies that the inability to name the object is unrelated to an aphasic or disconnection syndrome. Besides the tactile discrimination of shape and texture, the sense of joint position and movement plays a significant role in object identification since the shape of an object cannot be detected by active touch if the position of the fingers is not perceived. The known superiority of active exploration over passive tactile impression of a pattern must reflect in part the contribution of kinaesthesia (Gibson, 1962). The necessity for integration of several primary somatic inputs for stereognosis was expressed by Denny-Brown *et al.* (1952) when they used the term morphosynthesis.

Impaired recognition of objects can be the result of a loss of the primary somatic sensations in a number of patients with peripheral or central lesions of the afferent pathways. For Dejerine (1914), astereognosis would always be associated with some deficit in the tactile and deep sensations and it was thought to result from deprivation of adequate information through sensory defect (*see* Kennedy, 1924). Wernicke (1895), however, had proposed a different view based on two patients with focal cortical lesions in whom the contralateral astereognosis (*Tastlähmung* or tactile agnosia) occurred in the absence of any significant deficit of primary sensation. Astereognosis without any loss of tactile and deep sensation is usually related to damage to the parietal region (Guillain and Bize, 1932; Lange, 1936; Critchley, 1953; Denny-Brown *et al.*, 1952), but the extent and location of the critical cortical areas involved is still far from clear. Because stereognosis implies higher order integration, the associative cortex of the superior parietal lobule has been implicated (Evans, 1936; Semmes *et al.*, 1954; Nielsen, 1962). Evidence has also been presented that lesions of the postcentral gyrus may be necessary to produce astereognosis (Corkin *et al.*, 1970; Roland, 1976).

These and other issues about the functional organization of cortical areas subserving specific somatosensory functions in man can be addressed anew by combining detailed clinical studies of patients with the analysis of scalp-recorded averaged somatosensory evoked potentials (SEP). The SEPs to electrical stimulation of fingers or median nerve on one side consistently present characteristic component potentials that reflect the serial activation of distinct neural generators by the afferent volley. SEP components are conveniently labelled from their polarity (N for negative, P for positive) and modal peak latency in normal subjects of standard body size (*see* Donchin *et al.*, 1977). The standard SEP components recorded from the scalp with a noncephalic reference electrode include the short latency positive far field P9-P11-P14 potentials that reflect the volume conducted input volley ascending from brachial plexus (P9) through the dorsal columns (P11) and medial lemniscus (P14); these far field potentials are followed by a widespread N18 and by the cortical SEP components (*see* Cracco and Cracco, 1976;

Kritchevsky and Wiederholt, 1978; Kimura *et al.*, 1978; Chiappa *et al.*, 1980; Wiederholt, 1980; Desmedt and Cheron, 1980*a, b*, 1981*a, b*; Anziska and Cracco, 1980; Mauguière and Courjon, 1981).

Many previous SEP studies involved recording montages in which a frontal scalp electrode served as reference (connected to grid 2 of the amplifiers) while the active electrodes over the parietal scalp were connected to grid 1 of the amplifier. Under these conditions, the cerebral potentials picked up over the front are algebraically subtracted from the parietal scalp potentials, while the far field potentials with widespread scalp distribution tend to cancel out (*see* Desmedt and Cheron, 1980*a*, 1981*b*, 1982). Such recording conditions are not acceptable if the aim of the study is to identify any specific alterations of SEP components that may result from focal cortical lesions. For example, if a set of postcentral SEP components recorded *via* grid 1 of an amplifier was genuinely eliminated or enhanced as a result of a given cortical lesion, this change would easily either be overlooked or misinterpreted in the (parietal to front) recorded trace since the latter would include any concomitant potential recorded *via* grid 2 of the same amplifier by the 'reference' electrode placed on the front. Much of the current confusion in the SEP discussions can be traced to the unfortunate use of such electrode montages. The difficulties can be avoided by using a noncephalic electrode as reference whereby the actual SEP components picked up at any scalp site are genuinely displayed in the trace (Desmedt and Cheron, 1982). In noncephalic reference montages, the two electrodes are further apart and this can make the recording more vulnerable to interference from ECG or unwanted muscle potentials when conditions are suboptimal in certain patients. As a compromise, we used recording montages with an earlobe reference electrode which is less susceptible to such interference, but allows adequate differentiation of the genuinely distinct potentials which have been shown to be generated either in front or behind the rolandic fissure (Desmedt and Cheron, 1981*b*). The N20-P27-P45 SEP components recorded over the parietal scalp (contralateral to the hand stimulated) are to be distinguished from the P22-N30 SEP components simultaneously recorded over the prerolandic scalp and they show different onset and peak latencies as well as independent changes in the course of ageing (Desmedt and Cheron, 1980*b*, 1981*b*). In normals, the frontal N30 SEP component is usually bilateral (fig. 1, B7, B8)), while the contralateral parietal N20 is not present ipsilaterally (Desmedt and Robertson, 1977; Desmedt and Cheron, 1981*b*).

The present study examines how distinct clinical (motor and/or sensory) deficits correlate with specific changes of the different cortical SEP components in selected patients with a clearly defined, single uncomplicated hemisphere lesion. The changes of either the parietal or the prerolandic SEP components were separated and correlated case by case with the pattern of clinical signs. The results provide new evidence on the pathophysiology of astereognosis. They also substantiate the view that the parietal or prerolandic SEP components in man have separate neural generators and must involve distinct anatomical pathways from thalamus.

MATERIAL AND METHODS

Twenty-two patients (11 males) with single circumscribed hemisphere lesions outside the basal ganglia were selected from a much larger group. The median age was 53 years. The youngest patient was 10 and the oldest 75 years. Four were older than 65 years. All were right-handed by the Edinburgh inventory criteria (Oldfield, 1971).

Unambiguous evidence for location and extent of the lesion was secured in each patient. CT scans were available for all patients except cases 8 and 12. They were taken in the usual oblique plane at 15 to 20 deg to the canthomeatal line, with slices of 10 mm thickness. Pixel (picture elements) was 1×1 mm. The figures present for each patient accurate drawings of all the CT scan sections that included the lesion, thereby providing a fair display of the true three dimensional extent of the lesion. Carotid angiography was performed in 7 patients and a radionuclide scan in one. There were 8 ischaemic lesions or cerebral infarcts, 6 intracerebral haemorrhages, 2 angiomas, 1 prefrontal leucotomy, 1 head injury and 4 tumours. None of the patients had a history of epilepsy, cerebrovascular accident or cranial trauma prior to the present illness. Patients with diffuse cortical atrophy, marked enlargement of the cerebral ventricles or systemic disease were also excluded.

On the day of SEP study, a repeat clinical examination documented in detail the motor and sensory deficits. The following features were tested in each patient. (1) Tactile sensitivity for smooth objects or cotton mesh, and to nonpainful pinprick; the latter were repeated at easy intervals to check for any progressive hyperpathic reaction. (2) Pain and temperature sensation. (3) Two-point discrimination on the finger tip, palm and dorsum of either hand. (4) Vibration sense at knuckles, wrists, iliac crests and malleoli. (5) Joint position sense, tested by the ability of the patient to identify flexion or extension of fingers or toes with closed eyes, to reproduce passive finger movements with the control limb, and to mimic with the affected hand any position imposed on the control finger. (6) Graphaesthesia, assessed by the recognition of capital letters or figures drawn with a smooth object on the palm or dorsum of each hand, and on the dorsal aspect of each forearm. (7) Stereognosis, tested by the recognition of familiar objects by palpation with eyes closed; aphasic patients answered by pointing to the palpated object exposed among others on a table. (8) Unilateral tactile extinction to bilateral simultaneous stimulation with smooth contact (or with nonpainful pinprick in cases with tactile loss) on symmetrical fingers or on the dorsum of both hands. (9) Constructional apraxia, assessed by the ability to draw familiar objects (bicycle, cube, flower or house) on paper, with or without a model. (10) Ideomotor apraxia, tested by mimicking symbolic gestures (military salute, sign of the cross) or implement manipulation (hammer, screwdriver, corkscrew).

For SEP recording, the subject lay supine on a couch in a warm, quiet, semidarkened room. He was relaxed with closed eyes. The stimuli were 0.2 ms square wave electrical pulses delivered either to the median nerve at wrist (cathode proximal; intensity just above thumb twitch threshold), or to fingers II and III (usually 3 times subjective threshold). Several runs of 500 or 1000 trials each were performed by stimulating successively either the left or the right side. The intervals between stimuli varied at random between 500 and 600 ms. The SEPs were recorded with 8 electrodes placed on each side of the head at parietal, central and frontal sites (*see* figurines in each figure). The parietal electrodes were located 3 cm behind the vertex Cz and at 7 cm from the midline. The prerolandic electrodes were placed 2 cm in front of the vertex Cz and at 5 cm from the midline. The standard frontal electrodes were at 7 cm in front of Cz and at 6 cm from the midline. In certain patients, additional anterior frontal or posterior parietal sites were recorded to document further the scalp extension of some components or to check for an apparent absence or abnormality of some SEP components (*see* figs.). The earlobe of the same side served as reference. The EEG was monitored throughout the recording session. All channels were simultaneously averaged, each with 512 or 1024 points of $136 \mu\text{s}$ bin width. The overall bandpass extended from 1 to 3000 Hz. Samples with excessive EMG interference were automatically rejected (*see* Desmedt, 1977, for details of the techniques).

The averaged SEPs recorded over the affected and control hemispheres were illustrated as unsmoothed traces drawn by the computer, with negativity of the active scalp electrode producing an

upward movement of the trace. Records to either right or left stimulation were compared to facilitate assessment of abnormal components. Thus each subject was used as his or her own control. This was important to validate changes of SEP components due to the unilateral lesion since it is now well known that SEP wave forms present a wider range of intersubject variations than previously recognized (*see* Desmedt and Cheron, 1980*b*, 1981*b*). Highly consistent waveforms were obtained in repeat runs on the same patient, but these were usually not illustrated to avoid overloading the figures.

RESULTS

Unilateral Prefrontal Lesions

The 5 patients of this subgroup had a lesion rostral to the frontal horn of the lateral ventricle and to premotor area 6. All patients gave normal results in all the tests of somatic sensation described in Methods. The clinical signs in this subgroup were characteristic of the frontal syndrome, and included emotional indifference, reduced spontaneous speech (smiling mutism in Case 4), slowing of intellect, reduced initiative and slight hypokinesia (but with no extrapyramidal signs).

Case 1, a female aged 18 years, developed over six months adverse seizures to the right with vocalization and secondary generalization. Nine days after a fairly extensive left frontal lobectomy documented by CT scan (fig. 1A), the patient had recovered well and normal SEPs were recorded for stimulation of the right (fig. 1B) or left (fig. 1C) median nerve: the widespread far field P14 was followed by standard contralateral parietal N20-P27-P45 components, and by prerolandic P22-N30 potentials. The latter were recorded at central, frontal and even anterior frontal sites bilaterally (*cf.* electrodes 7 and 8). The lack of anomaly of size or latency of the P22-N30 SEP components suggested that they must be generated more posteriorly than at the prefrontal region. In contrast, the EEG showed left frontal slowing at 3 to 4 Hz and isolated spike-wave complexes.

Prerolandic P22-N30 components were also present in the 4 other patients with prefrontal lesions. Case 2, a female aged 63 years, developed over two years progressive behavioural indifference and then presented an episode of temporospatial disorientation with formed visual hallucinations. The CT scan showed a large parasagittal meningioma extending vertically from the ethmoid ridge to the upper third of the frontal lobe (fig. 2A). The SEPs recorded before operation, at the time of the CT scan examination, were normal, as was the EEG. Cases 3, 4 and 5 had presented one to three years before the SEP study with an intracerebral haemorrhage located dorsolaterally in the right frontal lobe (fig. 2B) or medially in the left frontal lobe (fig. 2C, D). These CT scans document the lesion size shortly after the vascular accident, whereas the SEP study was performed several months later when the lesion had stabilized. The SEPs were similar to controls, except in Case 5 in whom N30 was significantly enhanced in voltage on the side of the lesion. The EEG showed intermittent frontal slowing to 4 to 7 Hz on the side of the lesion in all patients.

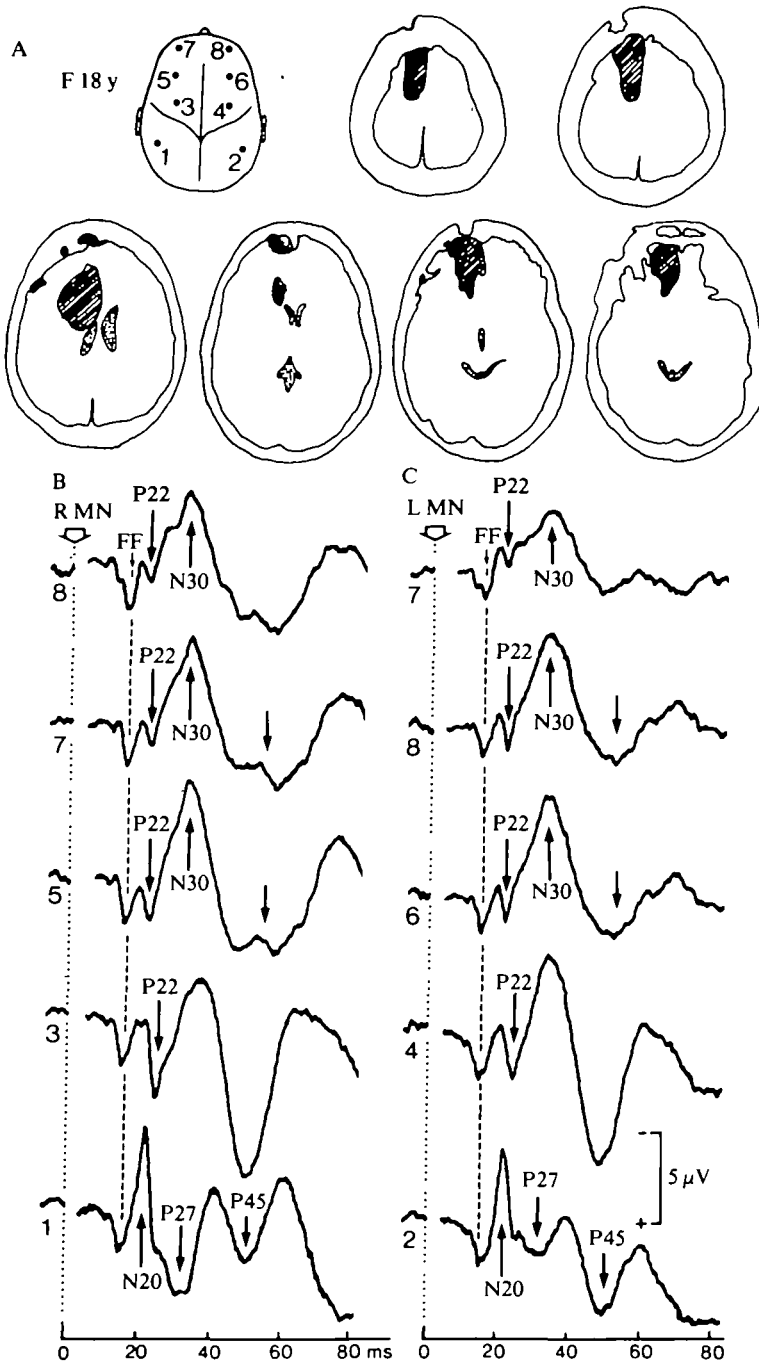


FIG. 1. Case 1, female aged 18 years, nine days after left prefrontal lobectomy. A, figurine with recording electrodes sites (earlobe reference) and the CT scan sections that included the lesion (right hemisphere presented on the right side of all drawings). B, SEPs to right median nerve (MN) stimulation. C, SEPs to left median nerve stimulation. The numbers before each averaged trace refer to the corresponding scalp site of the electrode on the figurine. The vertical interrupted line identifies the widespread far field P14 (FF).

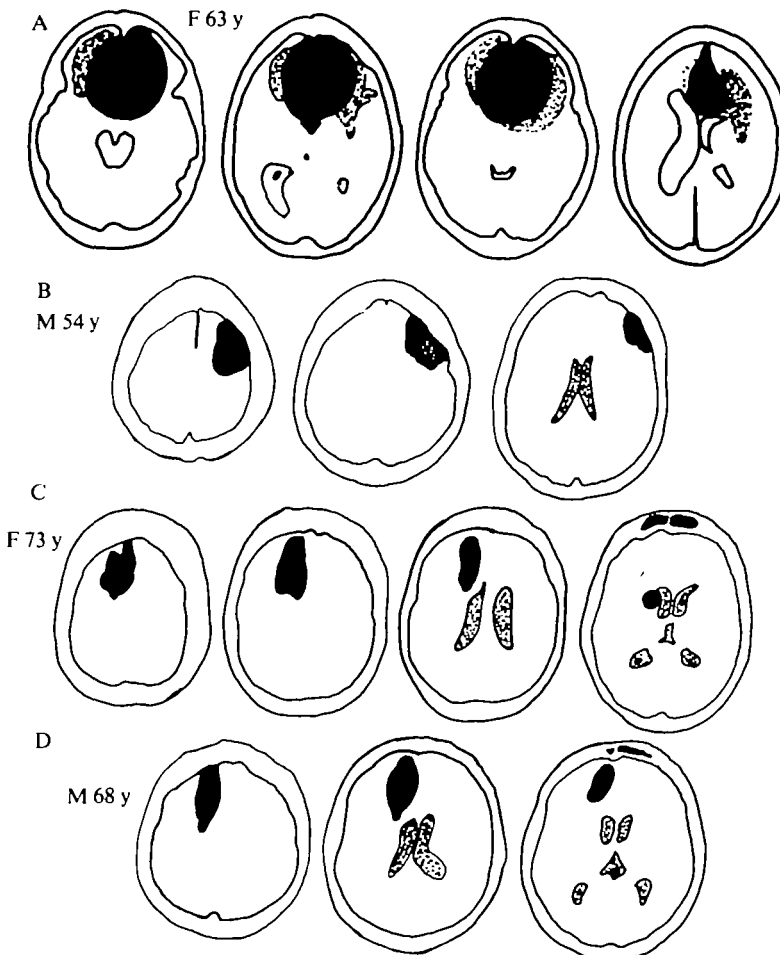


FIG. 2. Drawings of CT scan sections depicting the prefrontal lesions in Cases 2 (A), 3(B), 4(C) and 5 (D). *See text.*

Thus the patients of this subgroup had no somatosensory deficit and preserved prerolandic P22-N30 SEP components. The extensive recent and well-delineated surgical lesion in Case 1 is particularly conclusive.

Unilateral Prefrontal Lesions

The 4 patients of this subgroup displayed clear abnormalities in the prerolandic SEP components (Table 1). Case 6, a male aged 59 years, developed in 1976 partial Bravais-Jacksonian epilepsy with clonic seizures of left foot or hand, sometimes extending to the left half of the body but sparing the face. The CT scan showed a right rolandic-parietal mass (fig. 3A) which proved to be a grade I astrocytoma when removed surgically in May, 1981. Seven days later, the patient presented with a

TABLE 1 CORRELATIONS BETWEEN CLINICAL SIGNS AND LOSS OF DIFFERENT 'SEP' COMPONENTS IN PATIENTS WITH FOCAL UNILATERAL CNS LESIONS

<i>Stereognosis</i>	<i>Position</i>	<i>Tact</i>	<i>Upper motor neuron</i>	<i>Far field P14</i>	<i>P22-N30</i>	<i>N20</i>	<i>P27-P45</i>	<i>Case No</i>	<i>Lesion site</i>
0	0	0	0	++	0	0	0	21	Capsulothalamic
0	0	0	0	++	0	0	0	19, 20	Pre- and postcentral cortical lesion
0	0	0	++	++	++	0	0	10, 14	Complete parietal cortical lesion
0	0	++	++	++	++	0	0	11	Parietal cortical lesion
0	++	++	++	++	++	+	+	12, (15), (17), 18	lesion
++	++	++	0	++	0	++	++	6, 7	Precentral cortical lesion

For patients (15) and (17) the prerolandic SEP was not recorded. 0 = loss of function (or component), ++ = normal, + = reduced or altered. An example of patient with all columns at '0' (with loss of far field P14) after high cervical spinal cord lesion is described by Mauguère and Courjon, 1981.

The Table does not include the patients with a prefrontal lesion (Cases 1 to 5) or the few cases in whom stereognosis could not be tested (Case 9) or in which the lesion was extensive (Case 22).

complete flaccid hemiplegia involving the left hemiface, arm and leg: this suggested a large precentral lesion. However, tactile (two-point discrimination), and pain, temperature, and vibration sense were preserved. Position sense was slightly impaired in the fingers on the left. Stereognosis tests were performed more slowly by the left hand, but the answers were correct. It was uncertain whether this slowing without any actual error was related to the clinically evident central paresis of the left hand or to some surgical damage to the parietal region during removal of the large tumour, or both. There was also extinction on the left on bilateral stimulation of the hands and feet. The CT scan was performed at the time of the SEP study (fig. 3A). The control SEPs on stimulation of the median nerve (fig. 3B) or fingers (E) on the normal side presented all the usual components after the widespread far field P14. However, stimulation of the left median nerve (C) or fingers (F) on the affected side elicited no perolantic P22 or N30 component either contralaterally (fig. 3, C6, F6) or ipsilaterally (C5). The parietal N20 had normal size and latency (fig. 3, C4, C2, F4), but increased duration, and the subsequent parietal positivity was reduced on the side of the lesion. The EEG showed only occasional right parietocentral slowing at 3 to 4 Hz.

SEPs were again recorded when this patient had improved, four months after operation. He then presented a much less severe spastic hemiplegia, more severe in the upper limb. He was able to walk with a stick or to drink from a glass with his left hand. Stereognosis, position sense, two-point discrimination and graphaesthesia were normal on the left. The left tactile extinction on bilateral stimulation was still present. In the SEP with stimulation on the affected side, the parietal N20 was still delayed and the frontal N30 remained virtually absent, but a small P22 could now be identified.

Case 7, a girl aged 10 years, suddenly developed an upper motor neuron disorder with Broca's motor aphasia, but no detectable sensory loss, from an intracerebral haemorrhage in the left prerolandic region. Carotid angiography showed a localized arteriovenous malformation and surgery was performed. When SEPs were studied

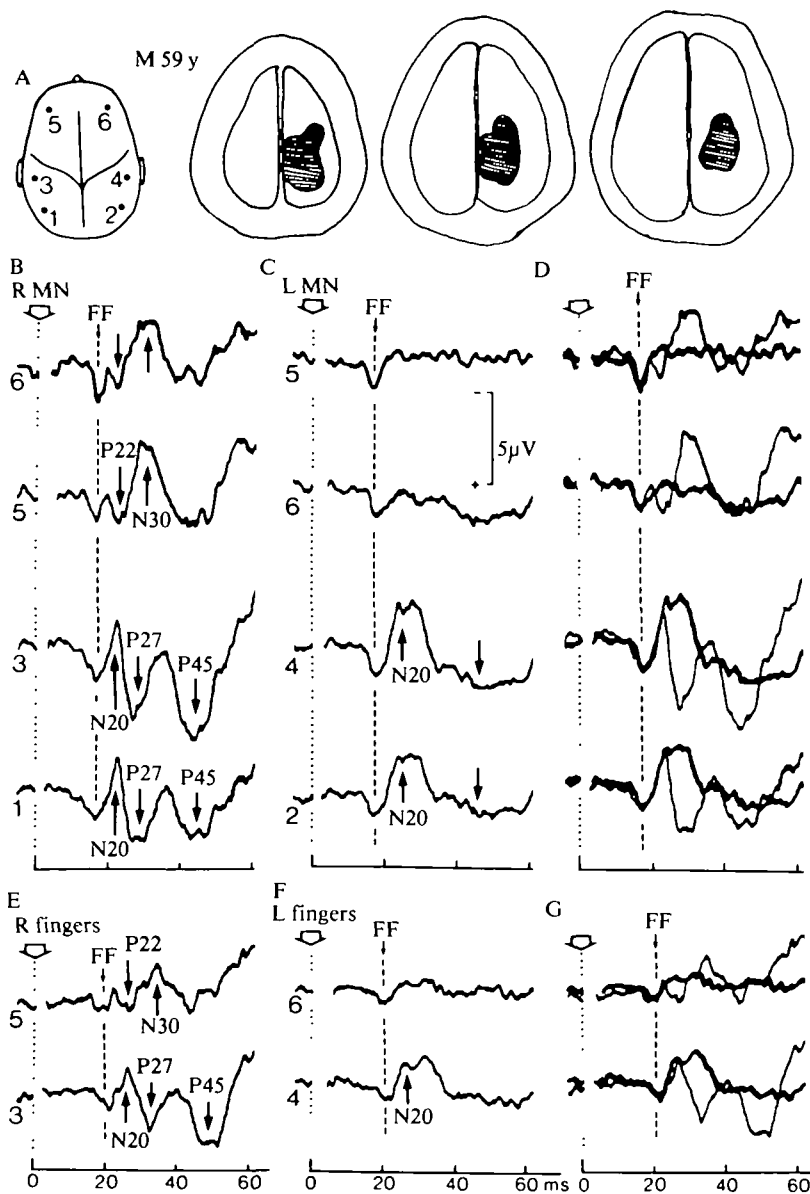


FIG. 3. Case 6, male aged 59 years, with hemiplegia and massive cortical and subcortical precentral lesion. Same presentation of the data. Electrical stimulation of the median nerve (B, C) or of fingers II-III (E, F) either on the affected side (C, F) or on the normal side (B, E). D and G show the same superimposed SEPs, the thicker trace corresponding to stimulation on the affected side.

one year later, the patient still had a severe right spastic hemiplegia and a left rolandic lesion in a CT scan (fig. 4A). A moderate dysphasia with dysarthria persisted, but did not interfere with sensory testing which disclosed normal stereognosis and somatic sensation in the right arm. The parietal N20-P27-P45 complex was present with stimulation on either side, but with a somewhat smaller voltage on the affected side (fig. 4B1). However, the prerolandic P22 and N30 were absent on the side of the lesion (B3). The EEG showed intermittent left frontal and anterior temporal slowing at 4 Hz.

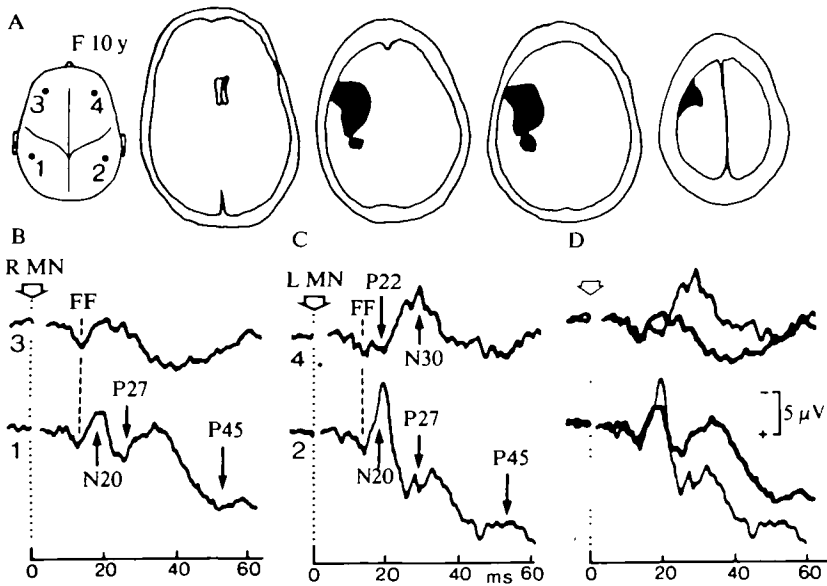


FIG. 4. Case 7, female aged 10 years, one year after operation for intracerebral haemorrhage. Stimulation of the median nerve on the affected (b) and on the normal (c) side. Superimposed traces shown in D, as in fig. 3.

Case 8, a female aged 23 years, had a history of recurrent transient ischaemic attacks with hemiparesis and tingling paraesthesiae on the left side since the age of 12 years. A CT scan was not performed, but right carotid angiography showed a large precentral arteriovenous malformation (fig. 5A). At the time of the SEP study one week later, upper motor neuron signs were absent, while stereognosis and somatic sensations were normal. The parietal N20 and P27 were present, but with slightly different profiles with stimulation on either side (fig. 5, B1, C2). No useful statement can be made about possible changes of the prerolandic P22 component (C4) since the control P22 in the SEP to stimulation on the normal side was poorly delineated in this patient (B3). However, the frontal N30 was clearly reduced on the side of the lesion, where the upward (negative) displacement of the trace (arrow in C4) is probably to be interpreted as a widespread N18 potential which recent evidence shows to be generated subcortically (Mauguière *et al.*, 1983). The SEP

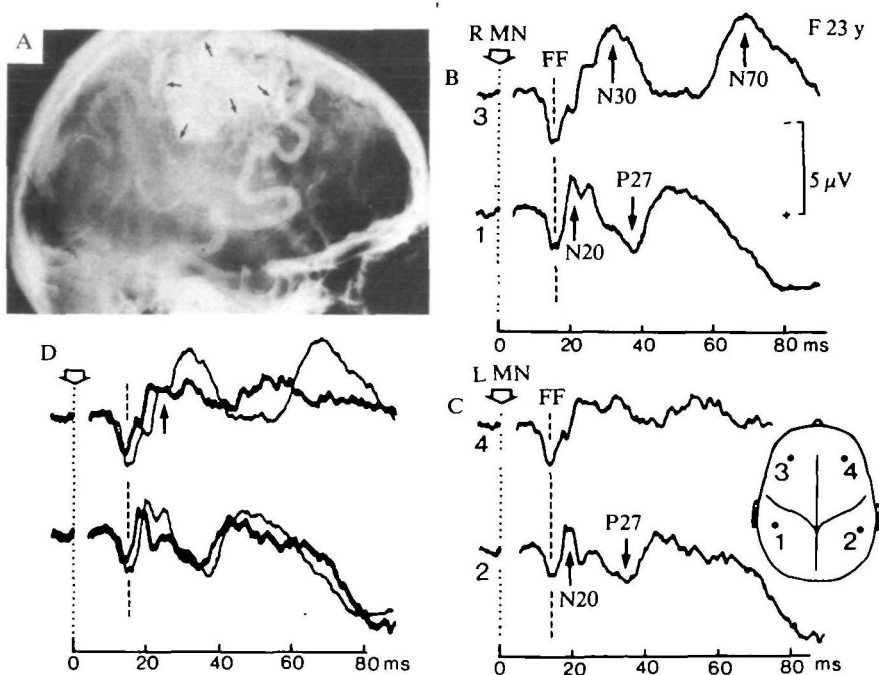


FIG. 5. Case 8, female aged 23 years, with a precentral arteriovenous malformation shown by carotid angiography (A). Stimulation of the median nerve on the normal B and C on the affected side. D, Superimposition of the same traces to compare SEPs to stimulation on the affected side (thicker traces) with SEPs to stimulation on the normal side at the frontal (above) and parietal (below) recording sites.

traces from either side were superimposed in D in order to demonstrate better the virtual lack of a well-delineated precentral N30 on the side of the lesion. The patient unfortunately did not survive operation which confirmed an extensive vascular lesion in the precentral region.

Case 9, a male aged 63 years, presented with a sudden left hemiplegia due to occlusion of the right internal carotid artery (arteriography). The CT scan showed a right frontal low density lesion (fig. 6A). At the SEP study three weeks later, there was a left Babinski sign with a complete flaccid hemiplegia, but no asomatognosia. Tactile and position sense were preserved in the left hand. Severe central paralysis on the left side prevented testing for stereognosis. Left-sided extinction was observed for bilateral tactile, auditory and visual stimulation. On stimulation of the fingers on the affected side, the parietal N20 (fig. 6C2) was similar to control (B1) while the P27 and P45 presented a similar profile but with a somewhat larger amplitude. At the prerolandic site, the control hemisphere (B3) presented a normal pattern with a P22 and an N30. On the other side (C4), P22 and N30 seemed to be missing and a 'postcentral pattern' appeared instead with a slightly attenuated N20 but quite large P27 and P45. At the more anterior frontal site (C6) the far field P14 appeared to be

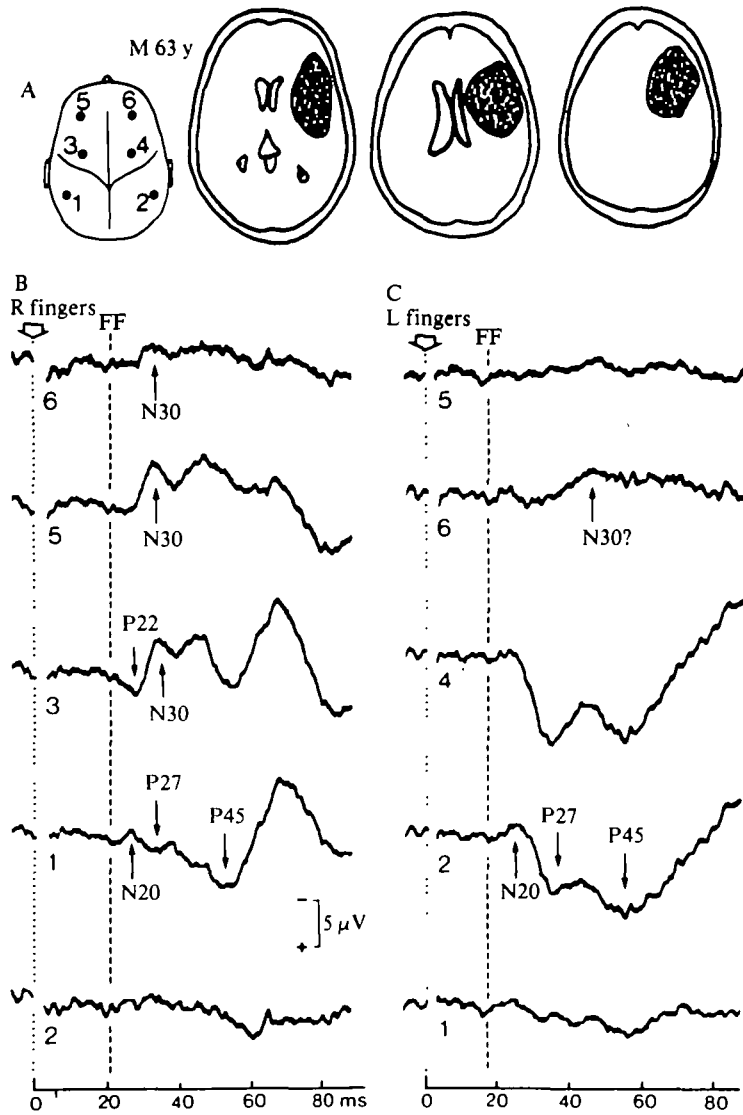


FIG. 6. Case 9, male aged 63 years, three weeks after occlusion of the right internal carotid artery. Electrical stimulation of fingers II-III on the affected side elicits doubtful frontal N30 (c6) and no P22. The precentral trace shows normal parietal components that are conducted forwards by volume conduction on the scalp (c4). Parietal components are present contralateral to the stimulus (b1, c2), and absent ipsilaterally (b2, c1). The far field P14 (vertical interrupted line) is rather small and ill-defined in this patient.

followed only by a small and delayed negativity which may or may not represent a true N30. In any case, the contrast with the symmetrical control side (B5) is striking. At the ipsilateral anterior frontal site (C5) no SEP component can be identified.

The possibility of picking up sizeable parietal SEP components at a scalp electrode placed in front of the rolandic sulcus has been documented for senile SEPs, in conjunction with the presence of rather small frontal components (Desmedt and Cheron, 1980*b*, fig. 6D; 1981*b*). The parietal positivities indeed appear to be generated rather close to the rolandic sulcus and they can apparently be volume-conducted rather efficiently towards the prerolandic electrode when N30 is reduced, as is the case of this patient. The EEG showed slow bursts at 4 Hz at the right frontal leads.

Thus the prerolandic P22-N30 SEP components were reduced or abolished in this subgroup, in conjunction with a precentral lesion and upper motor neuron signs, but in the absence of clear somatosensory deficit (Table 1).

Unilateral Parietal Lesions

Opposite dissociations between pre- and postrolandic SEP components were found in this subgroup of 7 patients (Table 1). Case 10, a female aged 53 years, suddenly developed a right hemianaesthesia and hemianopia, with bilateral apraxia and severe Wernicke's aphasia with agraphia, due to a left middle cerebral artery embolism in the course of carotid surgery. Five years later, a severe right hemianaesthesia was still present with complete astereognosis and loss of tactile, pain, temperature, vibration and joint position sense. The remarkably clear cut postcentral location of this lesion was evidenced clinically by the absence of a Babinski sign and of a central motor deficit, and by normal tendon reflexes. Several CT scans at yearly intervals showed a consistent and stable parietal lesion (fig. 7A). With finger stimulation on the affected side, the contralateral SEP showed a giant prerolandic P22 followed by large negative components (fig. 7, B3, B5) which also appeared ipsilaterally (B6). These prerolandic SEP components were unexpectedly picked up with identical latencies, but smaller size, at the postcentral electrode (B1) where no N20 was identified. The maximum amplitude of the P22 and N30 occurred at the prerolandic site (B3). For these SEP components to be correctly interpreted, it should be mentioned that the peak latency of the N22 (actually 26 ms) corresponds to that of the P22 recorded on the control side (C4) and is in line with the latencies for stimulation of fingers which are longer than for stimulation of the median nerve. Actually the superimposition of the traces recorded from symmetrical scalp sites in D shows clearly that the P22 presents an identical onset latency for stimulation of either the lesion or the control sides (*see* second and third frames in D). We interpret the early positivity recorded at the left parietal site (C1) as a P22 conducted backwards by volume conduction because this component has an onset latency that is clearly shorter than that of the parietal P27 recorded on the control side (C2), as better demonstrated in the fourth frame of superimposed traces in D.

The remarkable finding of an absent early parietal response in conjunction with enhanced prerolandic P22-N30 potentials was validated in other runs with electrical stimulation of the same fingers at lower intensity (that is, near the threshold for subjective sensation on the normal side). This control was important to document the consistency of the finding irrespective of the chosen intensity of the evoking stimulus. For this near-threshold stimulation, the P22 was somewhat smaller precentrally ($\epsilon 3$) and it no longer diffused backwards to the parietal site ($\epsilon 1$) where the SEP trace only showed residual noise without identifiable parietal N20-P27 SEP components. These data provide strong evidence that large P22-N30 prerolandic

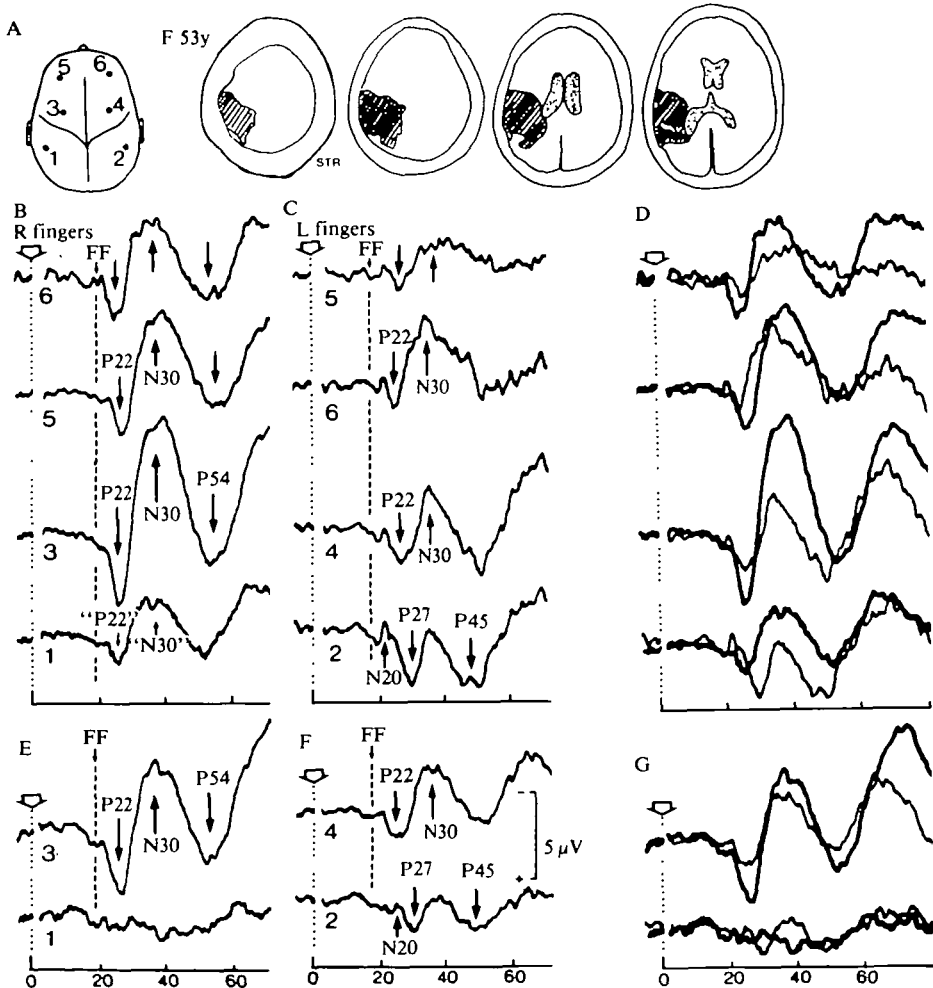


FIG. 7. Case 10, female aged 53 years, with a complete lesion of the left parietal region since the age of 5 years and a complete contralateral hemianaesthesia. Electrical stimulation of fingers II-III at intensities three times threshold (B, C) or near threshold (D, E) of the normal side. Notice the conduction backwards by volume conduction of the enhanced prerolandic P22-N30 to the parietal scalp recording site ($\epsilon 1$). The same records are superimposed in D and G, with the thicker trace corresponding to the SEPs to stimulation on the affected side.

components can be recorded in the absence of any early parietal components, which is in line with the hypothesis that early N20 and P22 cortical components are related to separate generators (Desmedt and Cheron, 1981*b*), but falsifies the alternative hypothesis of their being related to a single dipole generator (Broughton, 1969). The EEG showed occasional left temporoparietal slowing at 3 to 4 Hz.

Case 11, a male aged 44 years, presented a left middle cerebral artery embolism with the Gertsmann syndrome, right hypoesthesia and a defect of visual guidance of movements (without hemianopia) in the right visual hemifield. The CT scan (fig. 8A) was performed two weeks before the SEP study which was validated at a repeat

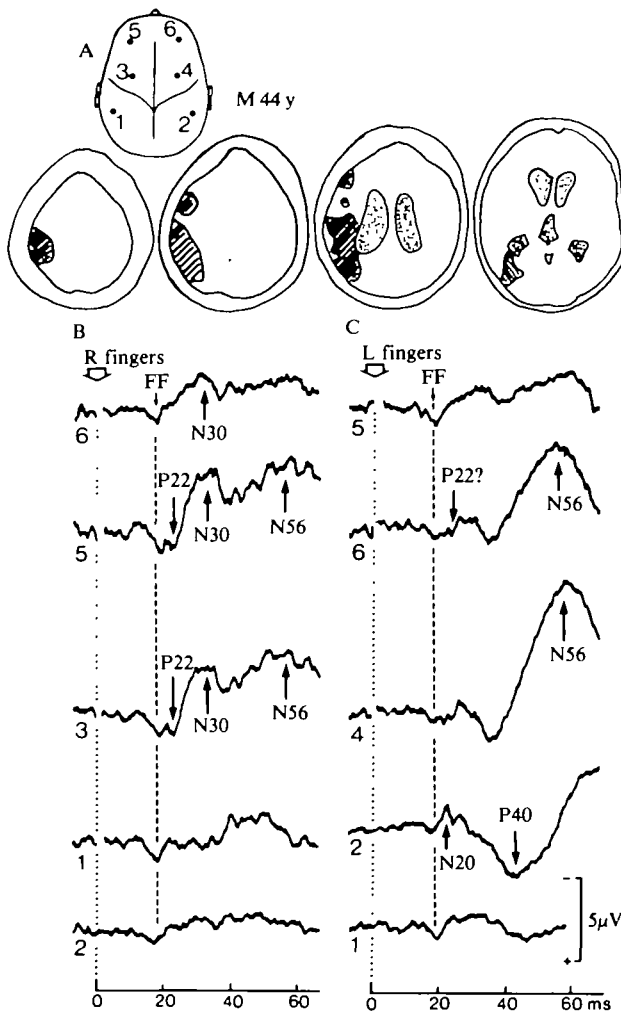


FIG. 8. Case 11, male aged 44 years, six months after a left middle cerebral artery embolism with a fairly extensive parietal lesion. Electrical stimulation of fingers II-III on the affected (B) or normal (C) side. Notice the absence of parietal N20-P27 on the lesion side (B1). On the normal side, the prerolandic P22 is not well delineated and the N30 is rather small while a later frontal negativity (N56) is recorded.

recording six months later. The patient had complete astereognosis, impaired joint position sense, absent graphaesthesia and tactile extinction in the right hand. Tactile, pain, temperature and vibration sense were present. There was no Babinski sign or any upper motor neuron deficit. Left finger stimulation elicited a normal N20 parietal response (fig. 8c2), followed by only one clear positive peak P40 instead of the more common 'W' pattern with the P27-P45 (see Desmedt and Cheron, 1981b). The prerolandic P22 was barely identifiable (c6) and the N30 unusually small for a patient of only 44 years. An N30 nevertheless appeared on the ipsilateral side (c5). A later frontal negativity N56 was recorded. These features can be considered within the range of normal control SEPs in the series studied in Lyons and in Brussels. They emphasize that interpretations of SEPs in patients with unilateral lesion should indeed rely on the comparison with the normal side in the same individual. Right finger stimulation on the affected side elicited no parietal N20 or any early positivity (B1). However, the prerolandic P22 could be more reliably identified on this side (B3, B5) and it was followed by a rather large N30 that also occurred ipsilaterally (B6). Other runs with stronger median nerve stimulation on the affected side (not illustrated) only evoked a miniscule parietal N20 that was much smaller than control, the parietal positivity remaining absent. The EEG showed intermittent bursts of slowing at 3 to 4 Hz over the left temporoparietal region.

Case 12, a female aged 75 years, developed clumsiness of the left hand without weakness in March, 1979 ('main instable ataxique' of Alajouanine *et al.*, 1934). A radionuclide scan disclosed a right posterior parietal infarct with increased uptake (fig. 9A). No CT scan was undertaken. At the time of the SEP study three months later, the left hand showed complete astereognosis, tactile extinction and loss of graphaesthesia. Tactile, pain, temperature, vibration and joint position sense were preserved. There was a Babinski sign and rather brisk tendon reflexes on the left, but no detectable weakness. Stimulation of the fingers on the left elicited SEPs with a relatively normal parietal N20 and P27 components at this three time threshold intensity (fig. 9B2). In fact these parietal responses cannot be considered as significantly different from those on the control side (C1) as further shown in superimposed traces (third frame in D). The prerolandic P22 and N30 were again markedly enhanced (B4) and offered a sharp contrast to the control responses for stimulation on the normal side (C3). The P22 and N30 responses in the latter can be considered within the normal range in view of the age of this patient (75 years). It has been recently shown that the frontal N30 tends to be reduced in ageing human subjects (Desmedt and Cheron, 1981b, Table 1). The superimposed traces indicate that these components were markedly enhanced on the affected side, without significant changes in their latencies (second frame in D). The study of ipsilateral frontal responses further indicates that none was present for stimulation on the control side (c4), in keeping with the patient's age, while a large N30 was recorded for stimulation on the affected side (B3). This indirectly substantiates the interpretation of an abnormal potentiation of the prerolandic responses on the side of the lesion. Repeat tests with near-threshold stimuli delivered to the same fingers

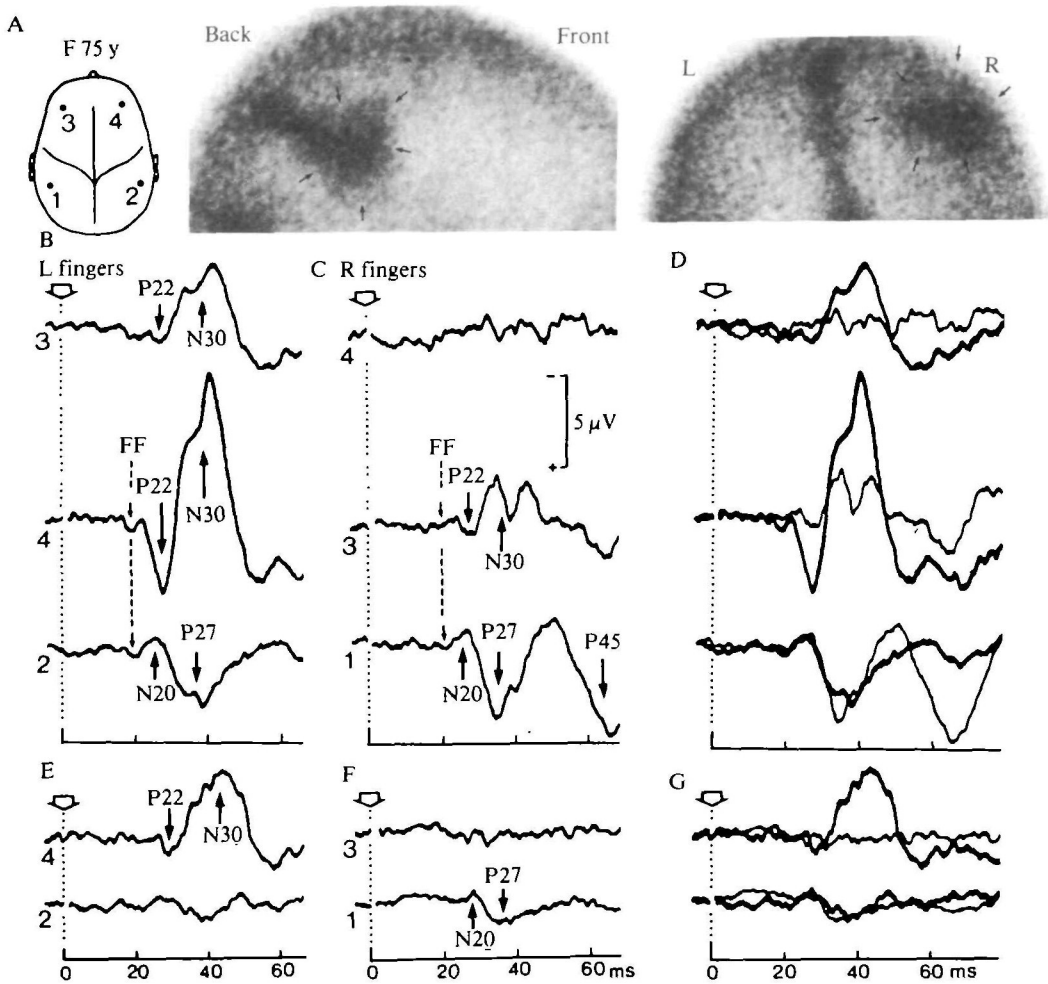


FIG. 9. Case 12, female aged 75 years, three months after a right posterior parietal infarct shown in the radionuclide scan (A). Electrical stimulation of fingers II-III at usual (B, C) or lower near-threshold (D, E) intensities. Note the absence of parietal N20-P27 in E2. The frontal negativity on the normal side is small (C3), and virtually absent for near-threshold stimulation (F3) in this old patient. The same records are superimposed in D and G, with the thicker trace corresponding to the SEPs to stimulation on the affected side.

disclosed an even greater contrast: the parietal SEP components were virtually absent on the affected side (fig. 9, E2) but present on the control side (F1), while the prerolandic P22-N30 were still quite large on the affected side (E4) but absent in the control trace (F3). These findings are in line with the hypothesis of an abnormal cerebral hyperreactivity that reflects plastic changes following chronic loss of neural connections normally received from another brain region that has been destroyed by a focal lesion (see Discussion). The EEG was normal in Case 12.

Case 13, a female aged 67 years, developed partial motor seizures affecting the left side. She was not aphasic, had no abnormal motor signs and the plantar responses were flexor. Tactile, temperature, and pain sensation was intact. A severe ideomotor apraxia was evident for the left hand, with complete inability to name palpated objects even though correct tactovisual matching was possible with this hand (*main gauche anomique* of Schott *et al.*, 1969, or 'tactile aphasia' of Geschwind and Kaplan, 1962). There was complete astereognosis in the right hand and some apraxia for bimanual activities. There was no left hemianopia. At the time of the SEP study, the CT scan showed a large bilobed tumour invading the splenium of corpus callosum, the left parietal white matter and the left posterior parietal cortex (fig. 10A). The frontal SEPs to median nerve stimulation on either side had similarly delayed negativities (fig. 10, B5, C4) which may have been related to brain distortion by the large tumour. The parietal SEP to right median nerve stimulation showed a large N20 followed by reduced and delayed positivity (B1).

When using finger stimulation that produced a smaller input volley, the alterations in the response from that side were more clearly revealed, with a much delayed parietal N20 (peak at 31 ms, D1) and an absence of parietal positivities P27-P45. This absence of positive components on the affected side is significant in view of the large P27 and P45 components recorded on the control side (E2). The N30 was virtually absent (D5), although this patient was only 67 years old, but a clearly delineated prerolandic P22 was recorded (D3, D5). The EEG showed rather frequent asynchronous bursts of slowing at 3 to 4 Hz which predominated over the frontoparietal regions of both hemispheres. Thus this patient featured preserved SEPs on the side exhibiting tactile anomia, but distorted or absent parietal positivities (and a preserved prerolandic P22) on the other side where there was complete astereognosis.

Case 14, a male aged 47 years, presented in 1976 with a sudden cerebral vascular lesion that gave rise to left hemianaesthesia and a left upper quadrantanopia which were still present at the time of the SEP study in 1981. The CT scan then showed an area of reduced density in the right parieto-occipital and posterior thalamic regions (fig. 11A). There was complete astereognosis in the left hand, with loss of position sense and of graphaesthesia, and considerably reduced tactile sensation (absent two-point discrimination). There was no tactile extinction. Pain, temperature and vibration sense were preserved. Exposure of the left hand to heat or cold was described as unpleasant. The tendon reflexes were brisk on the left, but the plantar responses were flexor. Left fingers showed a slight motor deficit only for skilled movements. Electrical stimulation of the left median nerve on the affected side elicited fairly normal prerolandic P22-N30 SEP components (fig. 11C4), but virtually no parietal SEP components after the far field P14 (C2). Stimulation on the normal side evoked well-delineated parietal N20 and P45 (B1), as well as prerolandic P22-N30 components serving as control. The EEG showed intermittent right parietal slowing at 4 Hz.

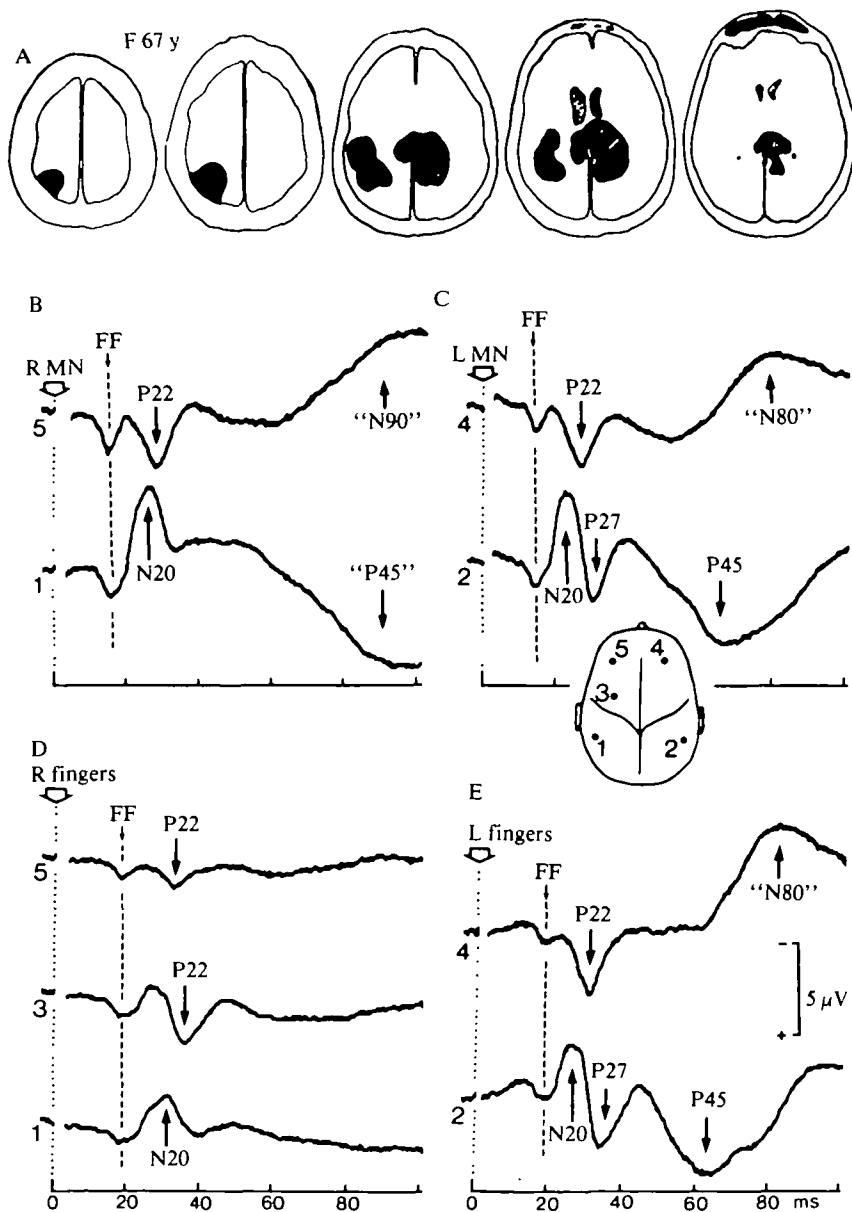


FIG. 10. Case 13, female aged 67 years, with a large cerebral tumour (A). Electrical stimulation of the median nerve (B, C) or of fingers II-III (D, E) on the right side (B, D) or on the left (C, E).

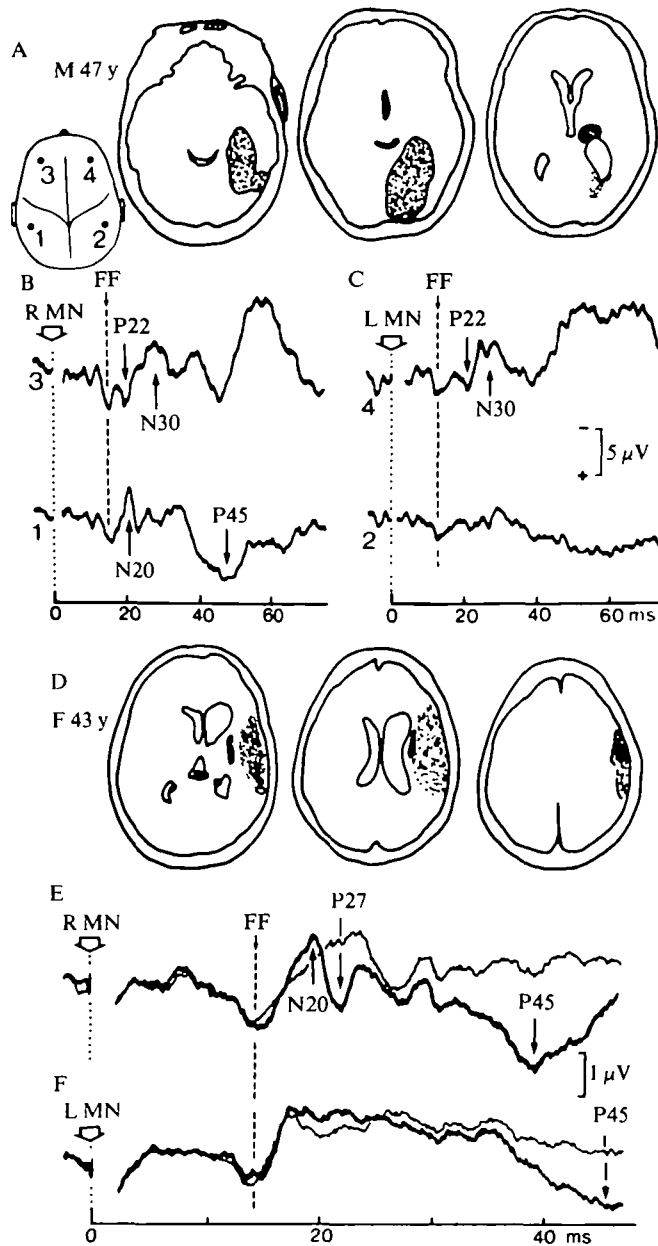


FIG. 11A-C, *Case 14*, male aged 47 years; five years after a right cerebrovascular lesion (A). D-F, *Case 15*, female of 43 years, six years after operation for an intracerebral haematoma. In E and F, the parietal SEP contralateral to the stimulus (thicker trace) is superimposed on the SEP simultaneously recorded ipsilaterally.

Case 15, a female aged 43 years, presented in 1973 with a sudden left hemiplegia with transient anosognosia due to a frontoparietal intracerebral haematoma which was treated surgically. At the time of the SEP study in 1979, a CT scan showed right temporoparietal atrophy with dilatation of the lateral ventricle (fig. 11D). There was complete astereognosis in the left hand and loss of graphaesthesia, but no tactile extinction; tactile, pain, temperature and vibration sense were normal. The tendon reflexes were brisk on the left, but there was no Babinski sign nor any motor deficit. Electrical stimulation of the median nerve on the affected side elicited a normal far field P14, but no early parietal N20-P27 and a reduced and delayed P45 (fig. 11F). Similar stimulation on the normal side evoked normal N20-P27-P45 responses which happened to be rather small in this subject (E). The superimposition of the contralateral and the ipsilateral parietal records was suggested by Desmedt and Cheron (1981*b*) as an efficient means for revealing the true difference between the contralateral N20 cortical response and the underlying (widespread) N18 negativity. In this method the parietal ipsilateral trace is used in fact as a baseline from which the N20 and P27 components diverge and can be more reliably estimated. For stimulation on the affected side, a prolonged N18 extending from about 18 to 38 ms is observed for both parietal sides which is taken to mean that no early parietal cortical response occurs at the affected hemisphere. This rather long duration of the N18 phenomenon has recently been documented in patients with thalamic lesions by Mauguière *et al.* (1983). The somewhat small N20 rising over the N18 'baseline' on the control side (E) is by no means unusual in normal adult subjects and this can be considered within the normal range (*see* Desmedt and Cheron, 1981*b*). Pre-central SEPs were not studied in this patient. The EEG was normal.

Case 16, a male aged 58 years, suddenly developed clumsiness and transient tingling paraesthesiae in the right hand. There was defective visual guidance for both hands in the right visual hemifield which suggested a left posterior parietal lesion. Carotid angiography showed a completely occluded left internal carotid artery. At the time of the SEP study, four months later, the CT scan showed an area of reduced density in the left posterior parietal region (fig. 12A). There was clear astereognosis in the right hand and a loss of graphaesthesia, but no tactile extinction, and the primary somatic sensations were all normal. On stimulation of the right median nerve on the affected side, all parietal components were reduced in voltage but none was selectively lost (fig. 12B). The prerolandic responses were normal, as was the EEG.

Astereognosis with Small Parietal Lesions

Two patients served to document unilateral astereognosis and SEP changes in association with minimal cortical lesions. Case 17, a male aged 31 years, sustained a head injury with a left parietal skull fracture in 1978. At the time of the SEP study eighteen months later, the CT scan showed a small area of reduced density in the left parietal region (fig. 12D). There was complete astereognosis and loss of graphaesthesia in the right hand, while touch, pain, temperature, position and

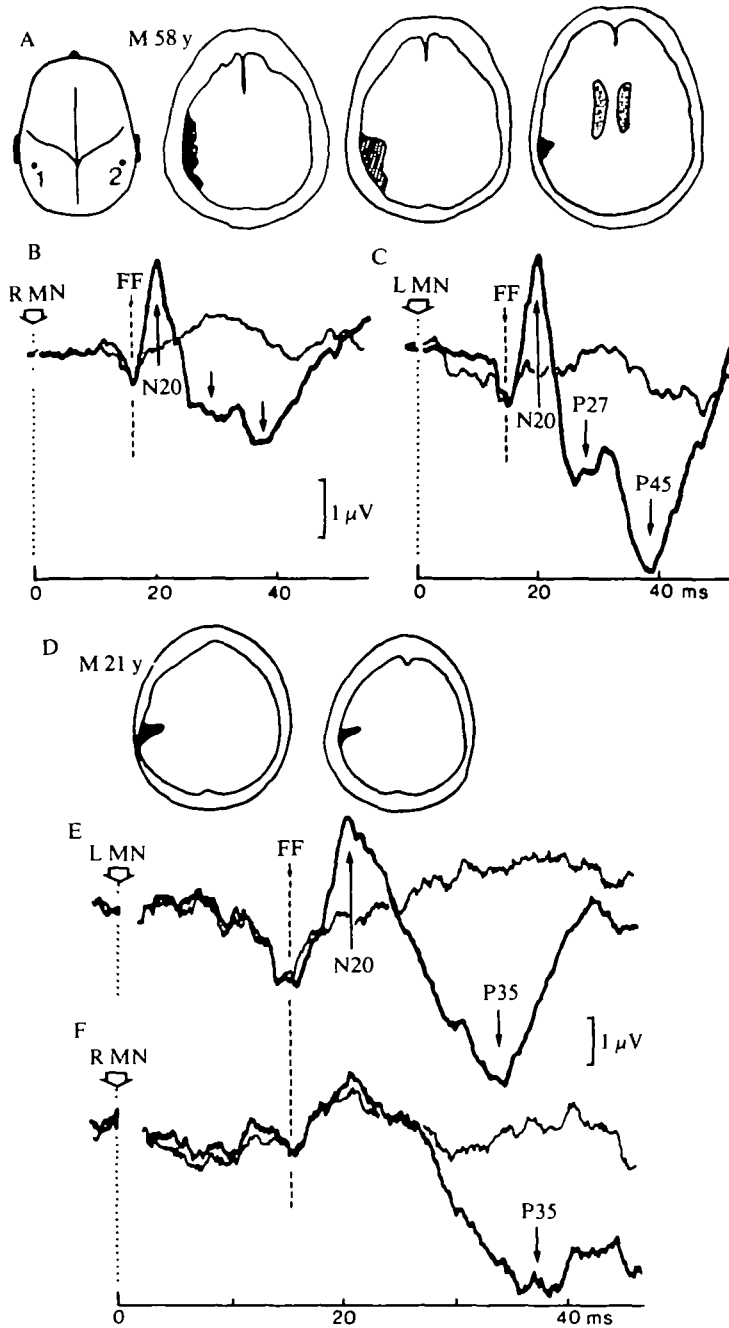


FIG. 12A-C, *Case 16*, male aged 58 years, four months after occlusion of the left internal carotid artery. D-F, *Case 17*, male aged 21 years, eighteen months after head injury with a fracture of the left parietal bone. Stimulation of median nerve. Parietal SEP contralateral to stimulus (thicker trace) superimposed on ipsilateral response.

vibration, sense were normal. There were no abnormal motor signs and no Babinski sign. On stimulation of the median nerve on the affected side, virtually no parietal N20 was detected in comparison with the ipsilateral trace, while the subsequent positivity was delayed and reduced in amplitude (fig. 12F). Stimulation on the normal side elicited a large parietal N20 that was clearly seen on top of the superimposed (ipsilateral) N18 and a P35 (E). The fact that the parietal positivity had a single (P35) peak instead of a 'W' pattern with P27-P45 is not unusual in young adults where it was found to occur in about 50 per cent of normals (Desmedt and Cheron, 1980*b*, p. 418). The EEG was normal.

Case 18, a female aged 36 years, presented in 1979 with a transient right hemiparesis related to an occlusion of the left internal carotid artery (shown by arteriography). At the time of the SEP study, two months later, the CT scan showed a very small left parietal infarct (fig. 13A). There was no Babinski sign and no motor deficit, but brisk tendon reflexes on the right. There was complete astereognosis and a loss of graphaesthesia in the right hand, while tactile two-point discrimination (5 mm) at finger tip and position sense were virtually normal. Vibration, pain and temperature sense were normal. There was no tactile extinction. Stimulation of the second and third fingers on the affected side elicited normal prerolandic P22-N30 responses (fig. 13D3), while the parietal P27 was abolished and the P45 reduced (B). However, the contralateral N20 appeared only slightly reduced with respect to control (C) when closely examined in several trials with the superimposed ipsilateral trace serving as 'baseline'. Here again, the identification of changes in SEP components is obviously assisted by the superimposition of contralateral and ipsilateral traces, and by the consideration of the component's features for stimulation on the control side in the same patient. For example, the parietal P27 can be missing in quite a few normal adult subjects who lack the usual 'W' pattern (Desmedt and Cheron, 1981*b*). Therefore one can only consider that P27 has been lost in conjunction with a parietal lesion (fig. 13B) if it is shown that the patient indeed has a clear P27 on the control side, as in the present case (fig. 13C). The EEG was normal in this patient.

Extensive Unilateral Cortical Lesions

Cases 19 and 20 presented with an acute left hemiplegia with a persistent upper motor neuron deficit, astereognosis, and a complete loss of touch, pain, vibration and position sense. Anosognosia and asomatognosia of the left half of the body occurred transiently in the acute stage. At the time of the SEP study, a CT scan showed an extensive area of reduced density in the territory of the middle cerebral artery related to the ischaemic lesion (fig. 14A, B). On stimulation of the left median nerve, all SEP components were lost after the far field P14 (fig. 13D). Stimulation on the normal side (C) elicited SEPs with a large prerolandic P22 (much larger than the parietal N20 in C1) and a N30 that extended to the ipsilateral front (C6). The cortical auditory potentials studied with the method of Peronnet *et al.* (1974) and Peronnet

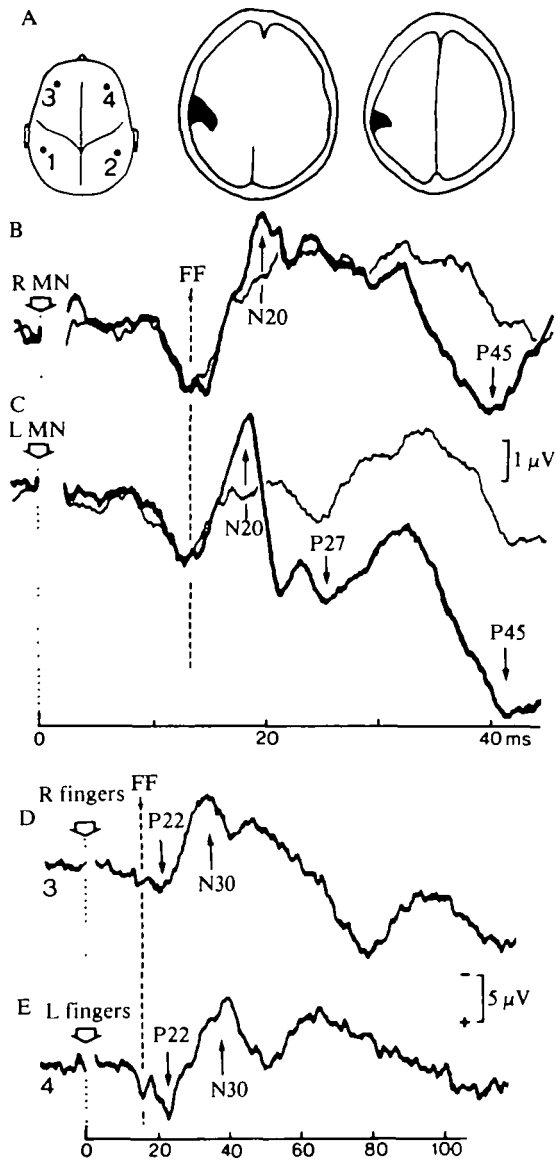


FIG. 13. *Case 18*, female aged 36 years, two months after occlusion of the left internal carotid artery. B-C, electrical stimulation of right (B) or left (C) median nerve. The parietal SEP contralateral to stimulus (thicker trace) is superimposed on the ipsilateral response. D-E, prerolandic responses to stimulation of fingers II-III on right (D) or left (E) side.

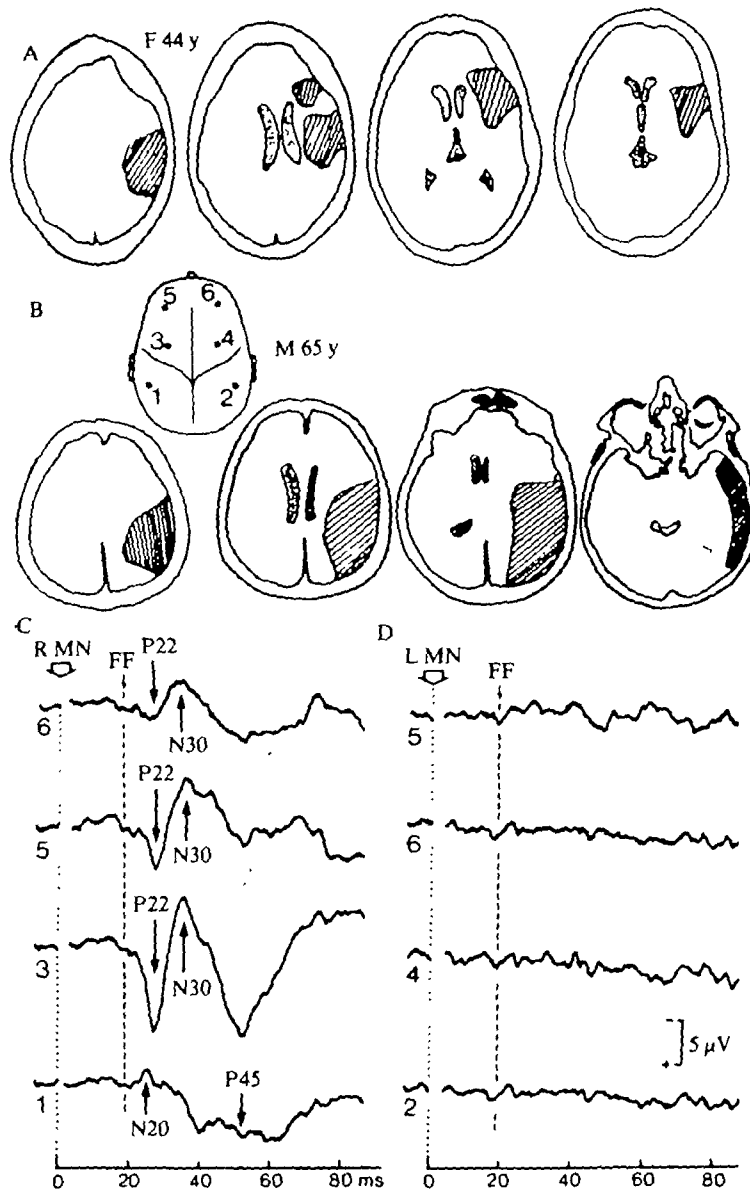


FIG. 14A, CT scan of Case 19, female aged 44 years, three years after a right frontoparietal infarct due to occlusion of the middle cerebral artery. B-D, Case 20, male aged 65 years, three months after a right parietotemporal vascular lesion. Stimulation of the median nerve on the normal (C) and on the affected (D) side.

and Michel (1977) were absent over the right hemisphere in Case 19, and on both sides in Case 20. The right temporoparietal EEG showed bursts at 3 to 4 Hz in Case 19, and a reduced amplitude without slowing in Case 20.

Unilateral Subcortical Lesions

Case 21, a male aged 60 years, suddenly developed a left hemiplegia with anosognosia and complete sensory loss on the left side. The CT scan showed an extensive subcortical haemorrhage with bleeding into the ventricles (fig. 15A). Two months later, stimulation of the median nerve on the normal side evoked the usual

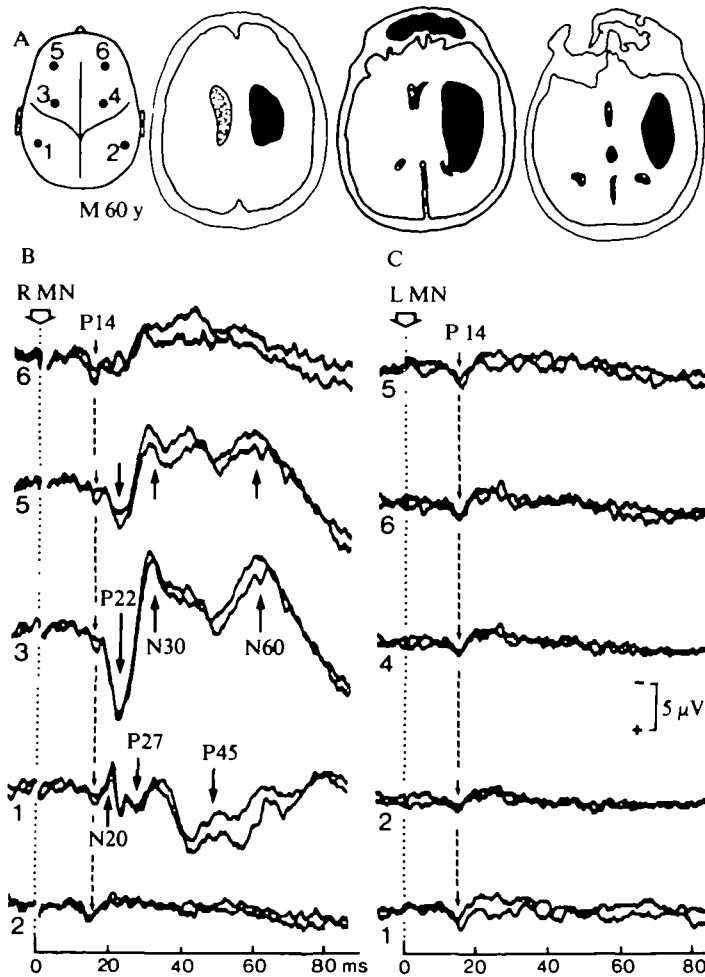


FIG. 15. Case 21, male aged 60 years, two months after an extensive right subcortical haemorrhage. Stimulation of the median nerve on the normal (B) and on the affected (C) side. Two independent averages are superimposed for each site in order to show the consistency of waveforms.

SEP components (B1, B3, B5), including an ipsilateral frontal N30 (B6). Similar stimulation on the affected side elicited no response after the far field P14 (fig. 15C). The EEG showed frequent slow bursts at 3 to 4 Hz over the right hemisphere. The statement that *late* ipsilateral SEPs disappear together with contralateral responses after severe unilateral lesions (Liberson, 1966; Williamson *et al.*, 1970; Tsumoto *et al.*, 1973) can thus be applied to the *early frontal* ipsilateral component (*see details* in Desmedt and Cheron, 1981*b*) in our patients (figs 1, c7; 3, c5; 6, c5; 14, d5; 15, c5). This point deserves to be made even though we do not wish to take issue with the problem as to whether the N30 recorded over the front ipsilateral to the side stimulated may be mediated either *via* callosal connections from the contralateral hemisphere, or through volume conduction of the contralateral N30, or both.

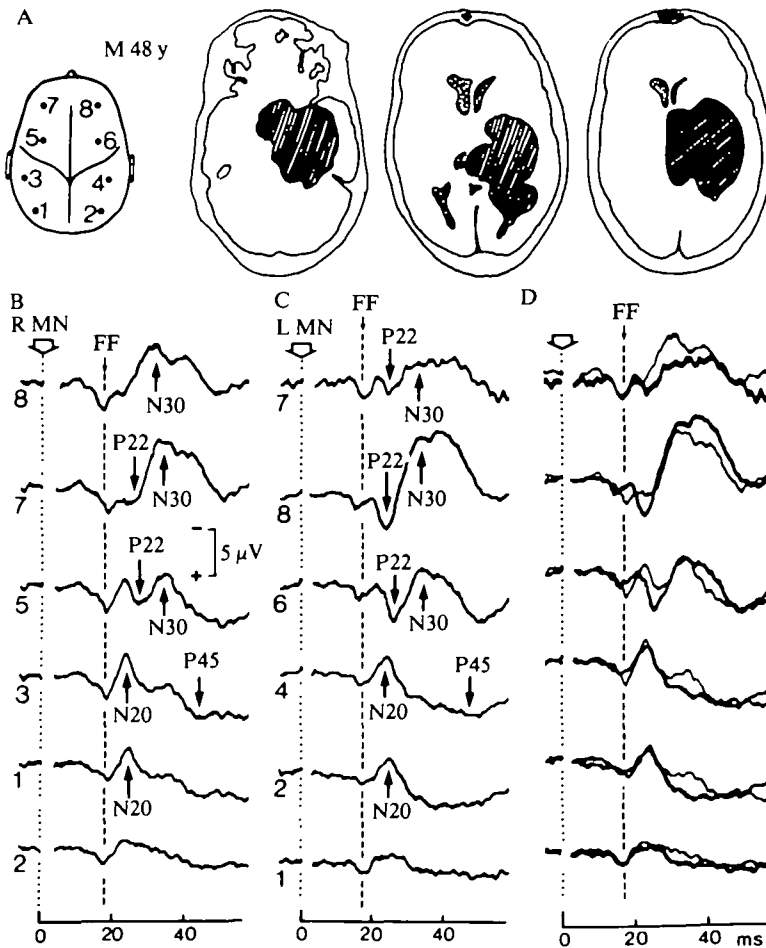


FIG. 16. Case 22, male aged 48 years, with a slowly growing epidermoid cyst. Stimulation of the median nerve on the right (b) and on the left (c) side. The traces are superimposed in d, as in fig. 3.

The question as to whether a subcortical lesion might affect the prerolandic or parietal SEP components differentially is important, but it will not be considered in this paper. We have, however, studied patients with subcortical vascular lesions and clinical astereognosis whose SEPs showed loss of the parietal components, but preservation of the prerolandic P22 component. This suggests that the thalamo-cortical pathways to areas behind or in front of the central sulcus are anatomically distinct and can be differentially affected by a subcortical lesion.

Slowly Progressive Lesions

Case 22, a male aged 48 years, demonstrated that SEP changes correlate better with the clinical signs than with the CT scan in slowly progressive lesions. He had developed over about four years motor clumsiness of the left arm and leg with a mild left hemiparesis. At the time of the SEP study, the CT scan showed an extensive area of reduced density (fig. 16A) that was later identified at operation as an epidermoid cyst communicating with the lateral ventricle. Stereognosis was good and there was no tactile extinction in the left hand. Touch, pain, temperature, vibration and joint position sense were normal. SEP components were similar with stimulation on either side (fig. 16B, C), but the prerolandic P22-N30 were somewhat larger on the affected side (C6, C8). The good SEP responses contrasted with the extensive CT scan abnormalities, but correlated well with the virtually normal sensation found clinically. The EEG showed occasional right temporal slowing at 6 to 7 Hz.

DISCUSSION

Each of the 24 patients selected for this study presented one stable unilateral lesion and, collectively, the lesions mapped out a variety of cerebral sites from the anterior frontal to the posterior parietal regions. The data provide the first detailed case by case analysis of dissociated somatic sensory loss in conjunction with the dissociated enhancement or loss of single SEP components and with evidence as to the anatomical location and extent of a single circumscribed cerebral lesion.

Besides documenting the physiological correlates of astereognosis and other clinical signs, the results substantiate the view that the P22-N30 SEP components recorded from the scalp in front of the rolandic fissure and the N20-P27-P45 components recorded from behind the fissure do indeed involve separate neural generators. These SEP components were analysed in detail with a noncephalic reference electrode (Desmedt and Cheron, 1981*b*), but they can also be studied with an earlobe reference electrode which is more convenient to use in some of the patients in whom recording conditions may be suboptimal. The frontal SEP components could not be dissociated from the parietal SEP components in previous studies using electrode montages with a frontal scalp reference in which case the two sets of SEP components are concurrently injected into grids 1 and 2 of

the same amplifiers. A complete loss of either the parietal or the prerolandic early cortical components in focal lesions (as in figs. 3, 7 and 8) would not have been revealed by a frontal reference montage since the SEP components remaining at the unaffected scalp site then appear (with inverted polarity) in the composite trace and the loss of one set of cerebral SEP generators is overlooked. This issue in relation to recording methods has frequently been neglected, yet it is essential for correctly interpreting SEP data in patients with focal cerebral lesions.

Early Cortical SEP Components

In this discussion, the N20 SEP component recorded from the parietal scalp contralateral to the hand stimulated is considered to be the earliest cortical response of the somatosensory receiving cortex. The prerolandic P22 is also a rather early cortical response which is considered to be generated in the motor cortex (*see below*). However, the onset latency of P22 significantly exceeds that of N20 by a mean of 0.75 ms (Desmedt and Cheron, 1981*b*, Table 3; this paper, Table 2).

TABLE 2. LATENCIES OF SEP COMPONENTS IN PATIENTS WITH CIRCUMSCRIBED LESIONS

Component of SEP	Normal side (ms)	Difference of lesion side (ms)	(Paired <i>t</i> -test)
Onset of P14	12.13 ± 1.77 (n = 18)	+0.103 ± 1.02 (n = 18)	0.673 (n.s.)
Peak of P14	15.6 ± 1.45 (n = 18)	+0.18 ± 0.6 (n = 18)	0.249 (n.s.)
Onset of N20	17.97 ± 1.56 (n = 18)	+0.11 ± 0.668 (n = 14)	0.564 (n.s.)
Peak of N20	21.3 ± 1.48 (n = 18)	+1.1 ± 1.8 (n = 14)	0.040
Onset of P22	18.73 ± 1.50 (n = 18)	+0.152 ± 0.53 (n = 12)	0.343 (n.s.)
Peak of P22	21.2 ± 1.6 (n = 18)	+1.1 ± 1.8 (n = 12)	0.040
Peak of N30	31.47 ± 3.97 (n = 18)	+1.4 ± 2.28 (n = 11)	0.056

All SEP data for median nerve stimulation at the wrist.

Kritchevsky and Wiederholt (1978), using a noncephalic reference, drew attention to the apparently bilateral distribution of the early SEP negativity, while Chiappa *et al.* (1980, p. 270) found persistence of early negative SEP deflection (with loss of the subsequent P27) in a patient with extensive radiolucent lesions of the centrum semiovale white matter in the CT scan. The latter data suggested that the early SEP negativity was generated in the thalamus or in thalamocortical radiation fibres rather than in the cortex as previously believed (Giblin, 1964; Desmedt and Manil, 1970; Desmedt and Robertson, 1977; Small *et al.*, 1980). A way out of this dilemma was proposed by Desmedt and Cheron (1981*b*) who emphasized the dual nature of the early SEP negativities: they differentiated an N18 component of widespread symmetrical scalp distribution from the classical N20 component which is only recorded over the contralateral postrolandic scalp. Mauguière *et al.* (1983) further showed that the generators of the widespread N18 must be subcortical, since N18 persists in patients with an extensive thalamic or supratheralamic lesion eliminating both the postcentral N20-P27-P45 and the prerolandic P22-N30 SEP components.

Detailed scalp mapping documents the genuine difference of SEP waveforms on either sides of the rolandic sulcus (Desmedt and Cheron, 1980*b*). The restricted distribution of N20 over the contralateral postrolandic scalp and the occurrence of SEP components with different latencies and polarities over the prerolandic scalp support the view that N20 and P22 are generated in the cortex rather than subcortically. All SEP components shown so far to be generated subcortically (P9, P11, P14, N18) present a widespread distribution over the scalp. Furthermore, studies of neuromagnetic fields in adult man suggest that the activity picked up around 20 ms after electrical stimulation of the contralateral median nerve is generated at a depth of about 3 cm from the scalp surface (Kaufman and Williamson, 1982), which implies that the corresponding generators are cortical rather than subcortical. Nevertheless, it must be recognized that such magnetic gradiometer evidence cannot yet answer the question critically as to whether one or more cortical generators may be activated in this time slot. In fact, at the present stage of technical development, such a question can be discussed more critically on the basis of electrical recordings in patients with focal cortical lesions, as reported in the present paper.

Reliability of SEP Features

On electrical stimulation of the median nerve on the *unaffected side* of our patients, the latencies of the SEP components (Table 2) were consistent with another series of normals (Desmedt and Cheron, 1980*b*, 1981*b*). It is well known that the intersubject differences in arm length influence the onset latency of the parietal N20 SEP component (*see* Hume and Cant, 1978; Small *et al.*, 1980). The arm lengths were rather homogeneous in our material and the means showed a reasonably small scatter. We did not include in Table 2 the data for finger stimulation which involve an additional finger-to-wrist conduction time of about 3 ms. The mean interval of 0.76 ms from onset of the parietal N20 to onset of the prerolandic P22 (at frontal recording sites) compares remarkably well with the means of 0.62 ms in young adults and 0.95 ms in healthy octogenarians recorded for the same measure by Desmedt and Cheron (1981*b*, Table 3).

The SEP changes with stimulation on the affected side were unrelated to any peripheral or central conduction disorder up to the thalamus since the far field P14, now considered to be generated in the medial lemniscus (Nakanishi *et al.*, 1978; Arezzo *et al.*, 1979; Desmedt and Cheron, 1980*a*, 1981*a*, 1982; Anziska and Cracco, 1980; Mauguère and Courjon, 1981) presented no significant latency difference with the control side (Table 2). Various lesions involving peripheral nerves or the subcortical pathway are known to increase the SEP onset latencies (Desmedt, 1971; Noel and Desmedt, 1975, 1980; Colon *et al.*, 1977; Mastaglia *et al.*, 1979; El-Negamy and Sedgwick, 1979; Anziska and Cracco, 1980; Eisen and Odusote, 1980; Chiappa *et al.*, 1980; Jones and Halliday, 1982).

The characteristic feature in patients with cortical lesions, however, is that the onset latency is either equal to control or only slightly increased (Table 2), while the

changes in amplitude or duration of cortical SEP components may be rather marked (see Shibasaki *et al.*, 1978; Halliday and Halliday, 1980; Noel and Desmedt, 1980; Mauguière *et al.*, 1982).

In the present study, the normal side of each patient served as his or her own control so as to detect small abnormalities and to minimize the problems associated with the rather wide intersubject variations in the amplitude of SEP components. Superimposition of the contralateral parietal SEP response on the ipsilateral parietal trace sometimes proved essential for a critical assessment of changes affecting the contralateral N20-P27 (see discussion of this method in Desmedt and Cheron, 1981*b*), especially in conjunction with 'pure' astereognosis with small postcentral lesions (figs. 11, 12, 13).

SEP differences on stimulation of either the affected or the normal side, respectively, were genuine and unrelated to experimental conditions. For example, the size of the afferent peripheral volleys were presumably comparable on both sides since the median nerve stimuli were adjusted in relation to thumb twitch threshold, and were thus independent of the sensory changes on the affected side. When using finger stimulation, we compared different intensities in independent runs on either side so as to assess whether the changes in SEP responses occurred consistently, irrespective of the use of any particular intensity (figs. 3, 7).

In patients with vascular lesions, the time interval between the initial lesion and the SEP study (two months to five years) was sufficient to exclude acute local changes and oedema. The SEP and clinical data were always compared after the lesion had stabilized. Distant distortions from a large space occupying lesion may have affected SEPs in Case 13 (fig. 10). On the other hand, a large slowly expanding tumour was found to have little effect on the SEPs in Case 22 (fig. 16).

In Cases 1 and 6, who had had recent craniotomies, the recording electrodes were placed at a distance of over 5 cm from bone flap in order to avoid effects related to the skull defect. The focal EEG slowing recorded in several patients would presumably influence the later components of the averaged responses, but in the present study this did not affect evaluation of changes in the *early* SEP components. These are usually not susceptible to slow EEG waves, especially when a sufficient number of trials (at least 500) are averaged.

Prerolandic and parietal SEP generators. Cerebral lesions destroying the anterior parietal cortex resulted in contralateral hemianaesthesia without hemiplegia and eliminated the N20-P27-P45 SEP components recorded over the parietal scalp; they did not reduce the prerolandic P22-N30 SEP components which unexpectedly tended to increase in voltage with respect to the control responses (figs. 7, 8, 9). On the other hand, the P22-N30 components must be generated in the more posterior part of the frontal cortex (see below) since they were not reduced nor eliminated by anterior frontal lesions rostral to the anterior horn of the lateral ventricle (figs. 1, 2). These data raise important issues as to the functional significance of the short latency prerolandic SEP generators for somatic sensation and for motor control.

In awake monkeys performing voluntary movements, the pyramidal tract

neurons of motor area 4 are controlled by feedback through sensory inputs from the moving arm (Evarts and Tanji, 1976; Evarts and Fromm, 1978; Conrad, 1978) (*via* the dorsal column pathway (*see* Marsden *et al.*, 1978)). These data are in line with the concept of momentary motor control through a transcortical servo loop (*see* Phillips, 1969) involving computation of mismatch between actual and intended movement (Evarts and Fromm, 1978). Besides proprioceptive inputs from active muscles, the inputs from skin and joints are important for finger and hand movements. The finding that electrical stimulation of fingers (thus excluding group I afferents) elicits large prerolandic responses (Desmedt and Cheron, 1980*b*, 1981*b*) (figs. 7D; 8, 9D, 15B) is in line with the presence in the motor area 4 of the monkey of a sizeable population of neurons that respond with very short latency either to skin or joint inputs from the contralateral hand (Rosen and Asanuma, 1972; Lemon and Porter, 1976; Wong *et al.*, 1978; Strick and Preston, 1978; Lemon, 1981; Tanji and Wise, 1981). Activities of the hand-input neurons are modulated during fractionated digit movements rather than during power grip (Lemon, 1981).

Direct anatomical projections reach the motor cortex from thalamic ventro-posterolateralis pars oralis (VPLo) neurons which in turn receive short latency inputs from nerves of the arm and thus transmit these signals to the cortical motor area of the arm (Lemon and van der Burg, 1979; Horne and Tracey, 1979; Asanuma *et al.*, 1980). The response of the motor cortex neurons can be eliminated by section of the dorsal columns (Brinkman *et al.*, 1978). However, tracer studies involving concurrent HRP and tritiated amino acid injections into VPLo showed that the VPLo neurons projecting to the motor cortex fail to receive direct inputs from the dorsal column nuclei (Tracey *et al.*, 1980). It is uncertain whether spinothalamic inputs could arrive in time in VPLo to account for the early VPLo responses; in any case, the experimental transection of the dorsal columns which abolishes these responses could not interfere with the spinothalamic route (Brinkman *et al.*, 1978). The deep cerebellar nuclei project heavily on to VPLo (Tracey *et al.*, 1980), but the neurons of these nuclei show long latency and uncertain responses to peripheral stimuli (Allen *et al.*, 1977; Harvey *et al.*, 1979). Furthermore, cerebellar ablations do not appear to reduce the area 4 responses (Malis *et al.*, 1953). Further anatomical studies may elucidate how dorsal column inputs reach VPLo neurons to be rapidly projected to motor area 4 (*see* Jones, 1983).

An alternative explanation would be that short latency lemniscal inputs reach the motor cortex, not *via* the motor thalamic relay in VPLo, but indirectly *via* the parietal cortex. The lemniscal somatosensory relay through the pars caudalis of VPL (VPLc) projects to areas 3-1-2 in the postcentral gyrus (Jones and Powell, 1970; Jones *et al.*, 1979). Neurons of areas 3 and 1 project backwards to area 2 which in turn sends direct projections to neurons of motor area 4 (Jones *et al.*, 1978; Strick and Kim, 1978; Jones, 1983). In the monkey, the motor cortex responses to somatic inputs may be supported at least in part through this route.

The SEP data in our patients are pertinent to these current issues. The prerolandic P22 SEP component persisted with its usual short latency (Table 2) in postcentral

cortical lesions that eliminated the early parietal responses (Cases 10, 14). Therefore P22 cannot be interpreted as a mirror image (phase reversal) of the parietal N20 (as suggested by Broughton, 1969), and it must involve a separate precentral generator (Papakostopoulos and Crow, 1980; Desmedt and Cheron, 1980*b*, 1981*b*). Moreover, these results appear to establish that the prerolandic P22 generators can be activated in man through a direct thalamocortical pathway, independently of the corticocortical pathways from parietal area 2 (and 5; *see* Jones and Powell, 1970) to area 4. The fact that the latter corticocortical connections are evidenced by robust anatomical data (*see* Jones, 1983) does not imply that a direct thalamocortical route to the motor cortex is not present. Another point is that the interval between onset latencies of N20 and P22 is only 0.6 ms (Desmedt and Cheron, 1981*b*; *see also* Table 2). This significant, but brief, interval barely provides enough time for conduction along the less direct route *via* the parietal cortex (N20 onset latency indicates the arrival time at the parietal receiving areas) (Desmedt and Cheron, 1981*b*). We do not exclude the indirect corticocortical route as contributing to the prerolandic response in the intact brain. The relative functional roles of the two pathways to the motor cortex are still uncertain.

In Cases 10 and 14 with a fairly complete longstanding parietal cortical lesion, it is possible that the corresponding thalamic projection nucleus VPLc has undergone alterations such as retrograde degeneration. The recording of large prerolandic SEP components in these patients is therefore all the more significant for suggesting that a separate thalamocortical pathway from VPLo to the motor cortex must be involved to subserve these responses under such conditions (figs. 7, 11).

In the premotor agranular cortex of area 6 (including the supplementary motor area), few movement-related neurons seem to have clear peripheral receptive fields (Brinkman and Porter, 1979, 1983; Wise and Tanji, 1981; Jones, 1983). Short latency responses to somatosensory inputs would indeed appear as a feature of some of the motor area 4 neurons, but not of the premotor area 6 neurons. It is thus proposed that the prerolandic P22 of the human SEP is generated in area 4, at least for its initial part. This correlates with the fact that the precentral lesions eliminating P22 are usually associated with a severe hemiplegia (figs. 3, 4, 6; Table 2). Moreover P22 reappeared in conjunction with the clinical regression of the motor deficit after surgical excision of the tumour in Case 6. Thus the prerolandic SEP undergoes alterations that seem to parallel impairment of central motor control.

Changes of latency and/or voltage of N30 are sometimes dissociated from those of P22 (fig. 10*D*). Also N30 is more vulnerable than P22 in the course of ageing (Desmedt and Cheron, 1980*b*, fig. 4; 1981*b*). N30 generators are not clear; they may in part be in premotor areas which receive connections from area 4 and also from parietal areas (Jones and Powell, 1970; Chavis and Pandya, 1976; Jones, 1983). No firm statement should be made at this stage except that N30 generators do not seem to be located in prefrontal cortex (fig. 1). An N30 is usually seen at the ipsilateral scalp (fig. 1, B8) which disappears along with the contralateral N30 in patients with a severe prerolandic lesion (figs. 3, c5; 6, c5; 14, D5; 15, c5). The ipsilateral N30 may

thus be elicited through callosal connections from the side opposite to the hand stimulated.

The N20 and P27 generators in the anterior parietal cortex can be eliminated separately or together by very small cortical lesions (figs. 12D; 13).

Enhancement of SEP components. The remarkable increase in voltage of the prerolandic P22-N30 components in patients with chronic (nine months to five years) parietal lesions (figs. 7, 8, 9) may be related to a phenomenon of 'sensitization' by chronic deafferentation of the motor cortex through degeneration of the corticocortical connections from areas 2 and 5. An additional possibility is that the postcentral cortical lesion would result in changes of the functional organization in the VPLo relay neurons projecting to the motor area. The P22-N30 components may also be enhanced after a chronic prefrontal lesion. They were similar to control in Case 1 with a very recent prefrontal lobectomy (fig. 1), but were enhanced in Case 5 who was studied three years after a prefrontal vascular lesion (fig. 2D).

In cats with experimental chronic partial cortical deafferentation, the cortical responses to residual inputs were only enhanced with respect to control after a delay of two to three months (Franken and Desmedt, 1957; Desmedt and Franken, 1963). A possible mechanism is that the synaptic sites vacated by the degeneration of, say, corticocortical connections, are reinnervated collaterally by intact afferent fibres, but other mechanisms may also be involved (Bach-y-Rita, 1972, 1983; Guth, 1974; Cotman and Lynch 1976; Raisman, 1978; Tsukahara, 1981). For example, neurons of motor area 4 deprived of corticocortical connections through a lesion destroying parietal cortex might receive an additional innervation through newly formed collaterals of the thalamocortical VPLo axons. This is one mechanism whereby a reinforcement of the response to somatosensory inputs could be achieved. The enhanced prerolandic responses do not appear to subservise any conscious somatosensory experience in the patients (such as Case 10) with an absent parietal SEP and hemianaesthesia. Their functional significance is still unclear.

Enhanced prerolandic SEPs can sometimes be conducted backwards by volume conduction along the scalp to be picked up at electrodes over the (inactive) parietal cortex (fig. 7, B1). Reciprocally, when the prerolandic responses are removed by a cerebral lesion, the parietal SEP components can be conducted forwards by volume conduction (fig. 6, C4). These effects need to be considered when interpreting average SEPs, and the use of a number of scalp derivations as in the present study is helpful for resolving such issues.

SEP and primary somatic sensation. The present data agree with previous reports (Halliday and Wakefield, 1963; Giblin, 1964; Noel and Desmedt, 1975) that the parietal N20-P27-P45 SEP components are unchanged in patients with loss of pain and temperature sensation. Conversely, these components may be lost in patients with cerebral lesions that do not give rise to any clinically demonstrable loss of pain and temperature sensation (Cases 11 and 14). The sensory input *via* the lemniscal pathway thus appears essential for generating parietal SEPs.

In a study of subcortical lesions, Tsumoto *et al.* (1973) suggested that the N20-P27

parietal components were related to position and vibration sense, but their material did not include patients with isolated loss of position sense or patients with lesions restricted to the cerebral cortex. We must disagree with their conclusion since the parietal N20-P27 responses were absent in Case 11 with loss of position sense but preserved vibration sense. Our data concur with Roland and Nielsen (1980) who noted that lesions of the postcentral gyrus did not alter the vibration sense threshold (Cases 11 to 18). Indeed, a loss of vibration sense was only found in Case 10 with an unusually complete parietal cortical lesion. We thus agree with the general statement of Holmes (1919) that 'tuning fork tests are among the least useful in cases of cortical disease'.

However, we disagree with Roland and Nielsen's suggestion that vibration sense is subserved by frontal cortex since the prerolandic P22-N30 SEP components were not only preserved but even enhanced in our Case 10 with a complete loss of vibration sense. This rare case of a complete parietal cortical lesion (with loss of vibration and the other primary somatic sensations) without any central paresis or motor signs (fig. 7) provides critical evidence that the lemniscal projections to prerolandic cortex do not subserve any of the conscious somatic sensations.

Astereognosis. Whereas the primary somatic sensations imply detection of mere presence of a single submodality input, the tactile recognition of objects or stereognosis involves the processing of spatial somatosensory inputs over time. Astereognosis in the hand has been associated clinically with direct damage or undercutting of the anterior part of the middle third of the contralateral postcentral gyrus (Roland, 1976), or with surgical excision of the postcentral gyrus (Corkin *et al.*, 1970). Stereognosis was of course abolished in patients with reduced or absent tactile sensation due to massive lesions (Cases 10, 21) (*see* Dejerine, 1914; Kennedy, 1924; Lange, 1936; Nielsen, 1962). Genuine astereognosis, however, implies a loss of tactile recognition of objects in spite of preserved tactile and joint position sense. Graphaesthesia also involves pattern recognition but without active touch, and it was lost in all our patients with astereognosis.

Case 15 presented fairly pure astereognosis after an intracerebral haemorrhage. The CT scan provided no indication as to the precise anatomical subregion involved (fig. 11D), but the parietal N20-P27 SEP components were virtually abolished (fig. 11F). In Case 16 with astereognosis and a somewhat extensive lesion, the postcentral SEP components were not abolished and only showed a reduction in voltage (fig. 12B). More critical evidence is provided by Cases 17 and 18 in whom a very small postcentral lesion produced a lasting pure astereognosis and loss of graphaesthesia in conjunction with a clear reduction or abolition of the N20-P27 components (figs. 12F, 13B). The parietal P45 was less critically involved in these cases with astereognosis. It was delayed in the recordings shown in figs. 10, B1-D1, 11F and 12F, but not in figs. 12B and 13B.

Thus genuine astereognosis appears to be associated with characteristic changes of the parietal SEP components. It correlates with a reduction or abolition of the early N20 cortical response and with a reduction or delay of the early parietal

positivities. These SEP changes may not permit any precise delimitation of the critical cortical lesion, but at least they suggest a disorder in the cortical transmission of excitation within the primary receiving areas 3-1-2 of Brodmann and/or from there towards higher order parietal areas. The parietal N20 SEP component representing the earliest cortical response to the afferent lemniscal volley (*see* Desmedt and Cheron, 1981*b*) has not been related to any single cytoarchitectonic area of the postcentral gyrus. Furthermore, small inflections of the N20 profile may suggest that more than one postcentral generator is actually involved. If the latter were to be related to different subareas of the postcentral cortex, the alterations of N20 recorded in patients with astereognosis might well reflect disorders of corticocortical conduction between areas 3, 1 and 2. Alterations of SEP component P27 which is also generated in the parietal cortex might also be suggestive of defective transmission between areas. Thus the range of N20-P27 changes recorded in our patients with pure astereognosis may be conceived as electrical evidence that transactions between parietal areas would be impaired in one or several of their critical components. On the other hand, we have not yet seen any evidence that astereognosis is related to selective alterations of the later SEP components in the presence of normal N20-P27 responses. Thus we can suggest that the critical lesion must involve connections within and/or from the receiving areas. It is interesting that astereognosis is produced by such lesions without loss of tactile and deep sensation. The latter appear less critically dependent on the detailed connections between the parietal cortical areas. In fact, a quite extensive parietal lesion (Case 10) is required to eliminate tactile, vibration and other primary sensations. On the other hand, we have not seen any patient with loss of tactile and deep sensation due to a cortical lesion in whom stereognosis was preserved. Finally, the prerolandic SEP components are neither delayed nor reduced in patients with astereognosis.

Clinical diagnostic uses of the SEP evidence. The averaging of SEPs assisted the clinical interpretation of lateralized deficits of object naming through palpation. For example, Case 13 had impaired tactile recognition in both hands. The parietal N20-P27-P45 to right sided stimulation showed abnormalities that were in line with the pattern seen in astereognosis due to a parietal lesion (fig. 10B, D). By contrast, the normal parietal SEP components to left sided stimulation was taken to indicate that the right hemisphere could process somatic sensory inputs in order to acquire stereognostic information and that the clinical deficit for object naming in the left hand was related to a disconnection (Geschwind and Kaplan, 1962; Schott *et al.*, 1969), preventing transfer of stereognostic information to the left (language) hemisphere (fig. 10A). This is one example of diagnostic uses of the observed relations between changes of parietal or prerolandic SEP components to definite clinical signs in patients with focal lesions.

ACKNOWLEDGEMENT

This work was supported in part by the Fonds de la Recherche Scientifique Médicale (Belgium).

REFERENCES

- ALAJOUANINE T, THUREL R, OMBREDANE A (1934) Somatognosie et apraxie du membre supérieur gauche. *Revue Neurologique*, **41**, 695-703.
- ALLEN G I, GILBERT P F, MARINI R, SCHULTZ W, YIN T C (1977) Integration of cerebral and peripheral inputs by interpositus neurons in monkey. *Experimental Brain Research*, **27**, 81-99.
- ANZISKA B, CRACCO R Q (1980) Short latency somatosensory evoked potentials: studies in patients with focal neurological disease. *Electroencephalography and Clinical Neurophysiology*, **49**, 227-239.
- AREZZO J, LEGATT A D, VAUGHAN H G (1979) Topography and intracranial sources of somatosensory evoked potentials in the monkey: early components. *Electroencephalography and Clinical Neurophysiology*, **46**, 155-172.
- ASANUMA H, LARSEN K D, YUMIYA H (1980) Peripheral input pathways to the monkey motor cortex. *Experimental Brain Research*, **38**, 349-355.
- BACH-Y-RITA P (1972) *Brain Mechanisms in Sensory Substitution*. New York: Academic Press.
- BACH-Y-RITA P (1983) Rehabilitation versus passive recovery of motor control following central nervous system lesions. In: *Motor Control in Health and Disease*. Edited by J. E. Desmedt. New York: Raven Press.
- BRINKMAN C, BUSH B. M., PORTER R (1978) Deficient influence of peripheral stimuli on precentral neurones in monkeys with dorsal column lesions. *Journal of Physiology, London*, **276**, 27-48.
- BRINKMAN C, PORTER R (1979) Supplementary motor area in the monkey: activity of neurons during performance of a learned motor task. *Journal of Neurophysiology*, **42**, 681-709.
- BRINKMAN C, PORTER R (1983) Supplementary motor area and premotor area of the monkey cerebral cortex: organization and activation of single neurons during performance of a learned movement. In: *Motor Control in Health and Disease*. Edited by J. E. Desmedt. New York: Raven Press.
- BROUGHTON R J (1969) Discussion. In: *Average Evoked Potentials*. Edited by E. Donchin and D. B. Lindsley. Washington: US Government Printing Office, NASA SP-191, pp. 79-84.
- CHAVIS D A, PANDYA D N (1976) Further observations on corticofrontal connections in the Rhesus monkey. *Brain Research, Amsterdam*, **117**, 369-386.
- CHIAPPA K H, CHOI S K, YOUNG R R (1980) Short-latency somatosensory evoked potentials following median nerve stimulation in patients with neurological lesions. In: *Clinical Uses of Cerebral, Brainstem and Spinal Somatosensory Evoked Potentials*. Edited by J. E. Desmedt. *Progress in Clinical Neurophysiology*, Volume 7. Basel: Karger, pp. 264-281.
- COLON E J, NOTERMANS S. L., VINGERHOETS H. M., KAP J, DEWEERD J (1977) Cortical and cervical somatosensory evoked responses in demyelinating diseases. *European Neurology*, **15**, 124-130.
- CONRAD B (1978) The motor cortex as a primary device for fast adjustment of programmed motor patterns to afferent signals. In: *Cerebral Motor Control in Man: Long Loop Mechanisms*. Edited by J. E. Desmedt. *Progress in Clinical Neurophysiology*, Volume 4. Basel: Karger, pp. 123-140.
- CORKIN S, MILNER B, RASMUSSEN T (1970) Somatosensory thresholds: contrasting effects of postcentral gyrus and posterior parietal lobe excisions. *Archives of Neurology, Chicago*, **23**, 41-58.
- COTMAN C W, LYNCH G S (1976) Reactive synaptogenesis in the adult nervous system. In: *Neuronal Recognition*. Edited by S. H. Barondes. New York: Plenum, pp. 69-108.
- CRACCO R Q, CRACCO J B (1976) Somatosensory evoked potential in man: far-field potentials. *Electroencephalography and Clinical Neurophysiology*, **41**, 460-466.
- CRITCHLEY M (1953) *The Parietal Lobes*. London: Arnold.
- DEJERINE J (1914) *Sémiologie des Affections du Système Nerveux*. Paris: Masson.
- DENNY-BROWN D, MEYER J S, HORENSTEIN S (1952) The significance of perceptual rivalry resulting from parietal lesion. *Brain*, **75**, 433-471.
- DESMEDT J E (1971) Somatosensory cerebral evoked potentials in man. In: *Handbook of Electroencephalography and Clinical Neurophysiology*. Edited by A. Rémond, Volume 9. Amsterdam: Elsevier, pp. 55-82.

- DESMEDT J E (1977) Some observations on the methodology of cerebral evoked potentials in man. In: *Attention, Voluntary Contraction and Event-Related Cerebral Potentials*. Edited by J. E. Desmedt. *Progress in Clinical Neurophysiology*, Volume 1. Basel: Karger, pp. 12–29.
- DESMEDT J E, CHERON G (1980a) Central somatosensory conduction in man: neural generators and interpeak latencies of farfield components recorded from neck and right or left scalp and earlobes. *Electroencephalography and Clinical Neurophysiology*, **50**, 382–403.
- DESMEDT J E, CHERON G (1980b) Somatosensory evoked potentials to finger stimulation in healthy octogenarians and in young adults: wave forms, scalp topography and transit times of parietal and frontal components. *Electroencephalography and Clinical Neurophysiology*, **50**, 404–425.
- DESMEDT J E, CHERON G (1981a) Prevertebral (oesophageal) recording of subcortical somatosensory evoked potentials in man: the spinal P13 component and the dual nature of the spinal generators. *Electroencephalography and Clinical Neurophysiology*, **52**, 257–275.
- DESMEDT J E, CHERON G (1981b) Non-cephalic reference recording of early somatosensory potentials to finger stimulation in adult or aging normal man: differentiation of widespread N18 and contralateral N20 from the prerolandic P22 and N30 components. *Electroencephalography and Clinical Neurophysiology*, **52**, 553–570.
- DESMEDT J E, CHERON G (1982) Somatosensory evoked potentials in man: subcortical and cortical components and their neural basis. *Annals of the New York Academy of Science*, **388**, 388–411.
- DESMEDT J E, FRANKEN, L (1963) Long-term physiological changes in auditory cortex following partial deafferentation. In: *The Effects of Use and Disuse on Neuromuscular Function*. Edited by L. Gutmann and P. Hnik. Amsterdam: Elsevier, pp. 264–276.
- DESMEDT J E, MANIL J (1970) Somatosensory evoked potentials of the normal human neonate in REM sleep, in slow wave sleep and in waking. *Electroencephalography and Clinical Neurophysiology*, **29**, 113–126.
- DESMEDT J E, ROBERTSON D (1977) Differential enhancement of early and late components of the cerebral somatosensory evoked potentials during force-paced cognitive tasks in man. *Journal of Physiology, London*, **271**, 761–782.
- DONCHIN E, CALLAWAY E, COOPER R, DESMEDT J E, GOFF W R, HILLYARD S A, SUTTON S (1977) Publication criteria for studies of evoked potentials: report of a Committee. In: *Attention, Voluntary Contraction and Event-Related Cerebral Potentials*. Edited by J. E. Desmedt. *Progress in Clinical Neurophysiology*, Volume 1. Basel: Karger, pp. 1–11.
- EISEN A, ODUSOTE K (1980) Central and peripheral conduction times in multiple sclerosis. *Electroencephalography and Clinical Neurophysiology*, **48**, 253–265.
- EL-NEGAMY E, SEDGWICK E M (1979) Delayed cervical somatosensory potentials in cervical spondylosis. *Journal of Neurology, Neurosurgery and Psychiatry*, **42**, 238–241.
- EVANS J P (1936) A study of the sensory defects resulting from excision of cerebral substance in humans. *Research Publications of the Association for Nervous and Mental Diseases*, **15**, 331–370.
- EVARTS E V, FROMM C (1978) The pyramidal tract neuron as summing point in a closed-loop control system in the monkey. In: *Cerebral Motor Control in Man: Long Loop Mechanisms*. Edited by J. E. Desmedt. *Progress in Clinical Neurophysiology*, Volume 4. Basel: Karger, pp. 56–69.
- EVARTS E V, TANJI J (1976) Reflex and intended responses in motor cortex pyramidal tract neurons of monkey. *Journal of Neurophysiology*, **39**, 1069–1080.
- FRANKEN L, DESMEDT J E (1957) Sensibilisation progressive d'une aire corticale partiellement dénervée à ses afférences résiduelles. *Comptes Rendus de la Société de Biologie, Paris*, **151**, 2204–2208.
- GESCHWIND N, KAPLAN E (1962) A human cerebral disconnection syndrome. A preliminary report. *Neurology, Minneapolis*, **12**, 675–685.
- GIBLIN D R (1964) Somatosensory evoked potentials in healthy subjects and in patients with lesions of the nervous system. *Annals of the New York Academy of Science*, **112**, 93–142.
- GIBSON J J (1962) Observations on active touch. *Psychological Reviews*, **69**, 477–491.

- GUILLAIN G, BIZE P R (1932) Astéréognosie pure par lésion corticale pariétale traumatique. *Revue Neurologique*, **39**, 502-509.
- GUTH L (1974) Axonal regeneration and functional plasticity in the central nervous system. *Experimental Neurology*, **45**, 606-654.
- HALLIDAY A M, HALLIDAY E (1980) Cerebral somatosensory and visual evoked potentials in different clinical forms of myoclonus. In: *Clinical Uses of Cerebral, Brainstem and Spinal Somatosensory Evoked Potentials*. Edited by J. E. Desmedt. *Progress in Clinical Neurophysiology*, Volume 7. Basel: Karger, pp. 292-310.
- HALLIDAY A M, WAKEFIELD G S (1963) Cerebral evoked potentials in patients with dissociated sensory loss. *Journal of Neurology, Neurosurgery and Psychiatry*, **26**, 211-219.
- HARVEY R J, PORTER R, RAWSON J A (1979) Discharges of intracerebellar nuclear cells in monkeys. *Journal of Physiology, London*, **297**, 559-580.
- HOLMES G (1919) Disturbances of visual space perception. *British Medical Journal*, **2**, 230-233.
- HORNE M K, TRACEY D J (1979) The afferents and projections of the ventroposterolateral thalamus in the monkey. *Experimental Brain Research*, **36**, 129-141.
- HUME A M, CANT B R (1978) Conduction time in central somatosensory pathways in man. *Electroencephalography and Clinical Neurophysiology*, **45**, 361-375.
- JONES E G (1983) The nature of the afferent pathways conveying short-latency inputs to the primate motor cortex. In: *Motor Control in Health and Disease*. Edited by J. E. Desmedt. New York: Raven Press.
- JONES E G, COULTER J D, HENDRY S H C (1978) Intracortical connectivity of architectonic fields in the somatic sensory, motor and parietal cortex of monkeys. *Journal of Comparative Neurology*, **181**, 291-348.
- JONES E G, POWELL T P S (1970) An anatomical study of converging sensory pathways within the cerebral cortex of the monkey. *Brain*, **93**, 793-820.
- JONES E G, WISE S P, COULTER J D (1979) Differential thalamic relationships of sensory-motor and parietal cortical fields in monkeys. *Journal of Comparative Neurology*, **183**, 833-882.
- JONES S J, HALLIDAY A M (1982) Subcortical and cortical somatosensory evoked potentials: characteristic waveform changes associated with disorders of the peripheral and central nervous system. In: *Clinical Applications of Evoked Potentials in Neurology. Advances in Neurology*, **32**. Edited by J. Coujon, F. Mauguière and M. Revol. New York: Raven Press, pp. 313-320.
- KAUFMAN L, WILLIAMSON S J (1982) Magnetic location of cortical activity. *Annals of the New York Academy of Science*, **388**, 197-213.
- KENNEDY F (1924) Astereognosis. *Archives of Neurology and Psychiatry, Chicago*, **12**, 305-307.
- KIMURA J, YAMADA T, KAWAMURA H (1978) Central latencies of somatosensory cerebral evoked potentials. *Archives of Neurology, Chicago*, **35**, 683-688.
- KRITCHEVSKY M, WIEDERHOLT W C (1978) Short-latency somatosensory evoked potentials. *Archives of Neurology, Chicago*, **35**, 706-711.
- LANGE J (1936) Agnosien und Apraxien. In: *Handbüch der Neurologie*. Edited by O. Bumke and O. Foerster. Berlin: Springer, Volume 6, pp. 807-960.
- LEMON R N (1981) Functional properties of monkey motor cortex neurones receiving afferent input from the hand and fingers. *Journal of Physiology, London*, **311**, 497-519.
- LEMON R N, PORTER R (1976) Afferent input to movement-related precentral neurones in conscious monkeys. *Proceedings of the Royal Society, B*, **194**, 313-339.
- LEMON R N, VAN DER BURG J (1979) Short-latency peripheral inputs to thalamic neurones projecting to the motor cortex in the monkey. *Experimental Brain Research*, **36**, 445-462.
- LIBERSON W T (1966) Study of evoked potentials in aphasics. *American Journal of Physical Medicine*, **45**, 135-142.
- MALIS L I, PRIBRAM K H, KRUGER L (1953) Action potentials in 'motor' cortex evoked by peripheral nerve stimulation. *Journal of Neurophysiology*, **16**, 161-167.
- MARSDEN C D, MERTON P A, MORTON H B, ADAM J (1978) The effect of lesions of the central nervous

- system on long-latency stretch reflexes in the human thumb. In: *Cerebral Motor Control in Man: Long Loop Mechanisms*. Edited by J. E. Desmedt. *Progress in Clinical Neurophysiology*, Volume 4. Basel: Karger, pp. 334–341.
- MASTAGLIA F L, BLACK J L, EDIS R, COLLINS D W (1979) The contribution of evoked potentials in the functional assessment of the somatosensory pathway. *Clinical and Experimental Neurology*, **15**, 279–298.
- MAUGUIÈRE F, BRUNON A M, ECHALLIER J F, COURJON J (1982) Early somatosensory evoked potentials in thalamo-cortical lesions of the lemniscal pathways in humans. In: *Clinical Applications of Evoked Potentials in Neurology. Advances in Neurology*, **32**. Edited by J. Courjon, F. Mauguière and M. Revol. New York: Raven Press, pp. 321–338.
- MAUGUIÈRE F, DESMEDT J E, COURJON J (1983) Neural generators of N18 and P14 far field somatosensory evoked potentials. *Electroencephalography and Clinical Neurophysiology*, **55** (in press).
- MAUGUIÈRE F, COURJON J (1981) The origins of short-latency somatosensory evoked potentials in humans. *Annals of Neurology*, **9**, 607–611.
- NAKANISHI T, SHIMADA Y, SAKUTA M, TOYOKURA Y (1978) The initial positive component of scalp-recorded somatosensory evoked potential in normal subjects and in patients with neurological disorders. *Electroencephalography and Clinical Neurophysiology*, **45**, 26–34.
- NIELSEN J M (1962) Agnosias, apraxias, speech and aphasia. In: *Clinical Neurology*. 2nd Volume 1. Edited by A. B. Baker. New York: Hoeber-Harper, pp. 433–459.
- NOEL P, DESMEDT J E (1975) Somatosensory cerebral evoked potentials after vascular lesions of the brain-stem and diencephalon. *Brain*, **98**, 113–128.
- NOEL P, DESMEDT J E (1980) Cerebral and far-field somatosensory evoked potentials in neurological disorders involving the cervical spinal cord, brainstem, thalamus and cortex. In: *Clinical Uses of Cerebral, Brainstem and Spinal Somatosensory Evoked Potentials*. Edited by J. E. Desmedt. *Progress in Clinical Neurophysiology*, Volume 7. Basel: Karger, pp. 205–230.
- OLDFIELD R C (1971) The assessment and analysis of handedness: the Edinburgh Inventory. *Neuropsychologia*, **9**, 97–113.
- PAPAKOSTOPOULOS D, CROW H J (1980) Direct recording of the somatosensory evoked potentials from the cerebral cortex of man and the difference between precentral and postcentral potentials. In: *Clinical Uses of Cerebral, Brainstem and Spinal Somatosensory Evoked Potentials*. Edited by J. E. Desmedt. *Progress in Clinical Neurophysiology*, Volume 7. Basel: Karger, pp. 15–26.
- PERONNET F, MICHEL F (1977) The asymmetry of the auditory evoked potentials in normal man and in patients with brain lesions. In: *Auditory Evoked Potentials in Man. Psychopharmacology Correlates of Evoked Potentials*. Edited by J. E. Desmedt. *Progress in Clinical Neurophysiology*. Volume 2. Basel: Karger, pp. 130–141.
- PERONNET F, MICHEL F, ECHALLIER J F, GIROD J (1974) Coronal topography of human auditory evoked responses. *Electroencephalography and Clinical Neurophysiology*, **37**, 225–230.
- PHILLIPS C G (1969) Motor apparatus of the baboon's hand. *Proceedings of the Royal Society, B*, **173**, 141–174.
- RAISMAN G (1978) What hope for repair of the brain? *Annals of Neurology*, **3**, 101–106.
- ROLAND P E (1976) Astereognosis. Tactile discrimination after localized hemispheric lesions in man. *Archives of Neurology, Chicago*, **33**, 543–550.
- ROLAND P E, NIELSEN V K (1980) Vibratory thresholds in the hands. Comparison of patients with supratthalamic lesions with normal subjects. *Archives of Neurology, Chicago*, **37**, 775–779.
- ROSEN I, ASANUMA H (1972) Peripheral afferent inputs to the forelimb area of the monkey motor cortex: input-output relations. *Experimental Brain Research*, **14**, 257–273.
- SCHOTT B, MICHEL F, MICHEL D, DUMAS R (1969) Apraxie idéomotrice unilatérale gauche avec main gauche anomique: syndrome de déconnexion calleuse? *Revue Neurologique*, **120**, 359–365.
- SEMMES J, WEINSTEIN S, GHENT L, TEUBER H L (1954) Performance on complex tactual tasks after brain injury in man: analyses by focus of lesion. *American Journal of Psychology*, **67**, 220–240.

- SHIBASAKI H, YAMASHITA Y, KUROIWA Y (1978) Electroencephalographic studies of myoclonus. *Brain*, **101**, 447-460.
- SMALL D G, BEAUCHAMP M, MATTHEWS W B (1980) Subcortical somatosensory evoked potentials in normal man and in patients with central nervous system lesions. In: *Clinical Uses of Cerebral, Brainstem and Spinal Somatosensory Evoked Potentials*. Edited by J. E. Desmedt. *Progress in Clinical Neurophysiology*, Volume 7. Basel: Karger, pp. 190-204.
- STRICK P L, KIM C C (1978) Input to primate motor cortex from posterior parietal cortex (area 5). I. Demonstration by retrograde transport. *Brain Research, Amsterdam*, **157**, 325-330.
- STRICK P L, PRESTON J B (1978) Sorting of somatosensory afferent information in primate motor cortex. *Brain Research, Amsterdam*, **156**, 364-368.
- TANJI J, WISE S P (1981) Submodality distribution in the sensorimotor cortex of the unanesthetized monkey. *Journal of Neurophysiology*, **45**, 467-481.
- TRACEY D J, ASANUMA C, JONES E G, PORTER R (1980) Thalamic relay to motor cortex: afferent pathways from brainstem, cerebellum and spinal cord in monkeys. *Journal of Neurophysiology*, **44**, 532-554.
- TSUKAHARA N (1981) Synaptic plasticity in the mammalian central nervous system. *Annual Review of Neuroscience*, **4**, 351-379.
- TSUMOTO T, HIROSE N, NONAKA S, TAKAHASHI M (1973) Cerebrovascular disease: changes in somatosensory evoked potentials associated with unilateral lesions. *Electroencephalography and Clinical Neurophysiology*, **35**, 463-473.
- WERNICKE C (1895) Zwei Fälle von Rindenläsion? *Arbeiten de psychiatrischen Klinik Breslau*, pp. 33-42.
- WIEDERHOLT W C (1980) Early components of somatosensory evoked potential in man, cat and rat. In: *Clinical Uses of Cerebral, Brainstem and Spinal Somatosensory Evoked Potentials*. Edited by J. E. Desmedt. *Progress in Clinical Neurophysiology*, Volume 7, Basel: Karger, pp. 105-117.
- WILLIAMSON P D, GOFF W R, ALLISON T (1970) Somatosensory evoked response in patients with unilateral cerebral lesions. *Electroencephalography and Clinical Neurophysiology*, **28**, 566-575.
- WISE S P, TANJI J (1981) Supplementary and precentral motor cortex: contrast in responsiveness to peripheral input in the hindlimb area of the unanesthetized monkey. *Journal of Comparative Neurology*, **195**, 433-451.
- WONG Y C, KWAN H C, MACKAY W A, MURPHY J T (1978) Spatial organization of precentral cortex in awake primates. I. Somatosensory inputs. *Journal of Neurophysiology*, **41**, 1107-1120.

(Received April 6, 1982. Revised November 11, 1982)