

## **Anomalous Mitral Arcade: Echocardiographic and Angiographic Recognition**

Grant V.S. Parr, Raymond R. Fripp, Victor Whitman, Saroja Bharati, Maurice Lev

Departments of Surgery and Pediatrics, The Milton S. Hershey Medical Center and School of Medicine, The Pennsylvania State University, Hershey, Pennsylvania and the Congenital Heart Disease Research and Training Center, Hektoen Institute for Medical Research, Chicago, Illinois

**SUMMARY.** A patient with sudden onset of hemiplegia was noted to have an anomalous mitral arcade at cardiac surgery. Echocardiographic and angiographic data are correlated with the anatomic findings. The clinical significance of this anomaly is discussed.

**KEY WORDS:** Mitral valve — Mitral valvular anomalies

The mitral valve apparatus is a complex anatomic structure, and congenital anomalies have been documented involving each of its components. In most instances, echocardiography together with angiography has allowed an accurate diagnosis to be made.

Anomalous mitral arcade is a rare abnormality of the mitral valve apparatus [2, 4], the echocardiographic and angiographic findings of which have not been previously reported. We present here these findings in a patient with the surgically proven diagnosis of an anomalous arcade of the mitral valve.

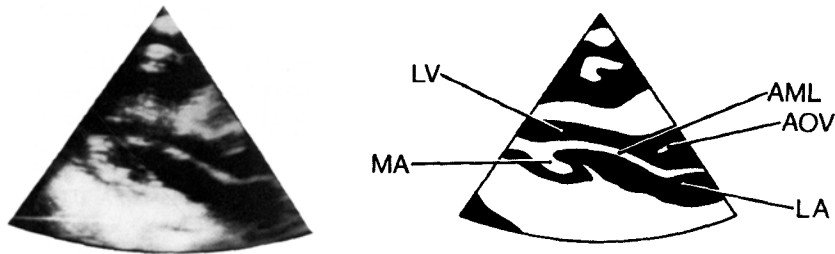
### **Case Report**

J.M., a 3-year-old male, was admitted to The Milton S. Hershey Medical Center after developing an acute right hemiparesis and aphasia 4 weeks following complete recovery from varicella. There was no history of any arrhythmias. Physical examination of the cardiac system, electrocardiogram, and chest x-ray were all normal. Specifically, there was no left atrial enlargement. Central nervous system computerized tomography scan suggested a left frontoparietal cerebral vascular accident in the distribution of the left middle cerebral artery. Hematocrit, platelet count, prothrombin time, partial thromboplastin time (PPT), and sedimentation rate were all normal. M mode echocardiography of the mitral valve was normal, with both anterior and posterior leaflets of the valve moving normally. The left atrial dimension of

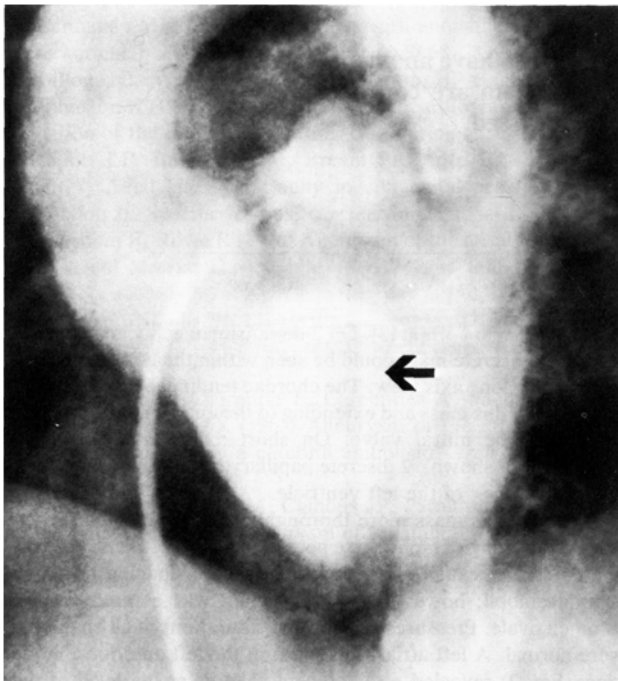
22 mm was also normal [3]. On 2-dimensional echocardiography (Fig. 1), a discrete mass could be seen within the body of the left ventricle on long axis view. The chordae tendineae could be seen arising from this mass and extending to the anterior and posterior leaflets of the mitral valve. On short axis view of the left ventricle (not shown), 2 discrete papillary muscles could be seen toward the apex of the left ventricle.

To define this mass more thoroughly, cardiac catheterization and contrast angiography were performed. The left ventricle was not entered because of the possibility of dislodging systemic arterial emboli; however, the left atrium was entered via the foramen ovale. Pressures and oxygen saturations in all chambers were normal. A left atrial angiogram in the left anterior oblique view (Fig. 2) revealed a radiolucent shadow at the level of the posterior leaflet of the mitral valve. This was thought to be a mass from which a cerebral arterial embolus had originated; therefore, surgical exploration under temporary cardiopulmonary bypass was undertaken. The left atrium was explored and no masses were found within it. The mitral valve was examined from the left atrium and was felt to be competent with no anomalies of its annulus. The anterior and posterior leaflets appeared normal in configuration. Examination through the mitral valve revealed a continuous bar of tissue arising in the anterior papillary muscle and terminating in the posterior papillary muscle (Fig. 3). From this bar several chordae originated, supporting the anterior leaflet and small commissural leaflets of the mitral valve. The posterior leaflet and its associated chordae appeared normal. The chordae were not thickened. The examination of the left ventricular cavity revealed no evidence of masses or other abnormalities. The patent foramen ovale was sutured. The patient tolerated withdrawal of the cardiopulmonary bypass well, and postoperative recovery was normal. Because the cerebral vascular accident may have been caused by a thrombus originating on the abnormal mitral valve, the patient was begun on salicylate therapy for its antithrombotic effects. The patient has continued to recover neurologic function and no further problems have occurred.

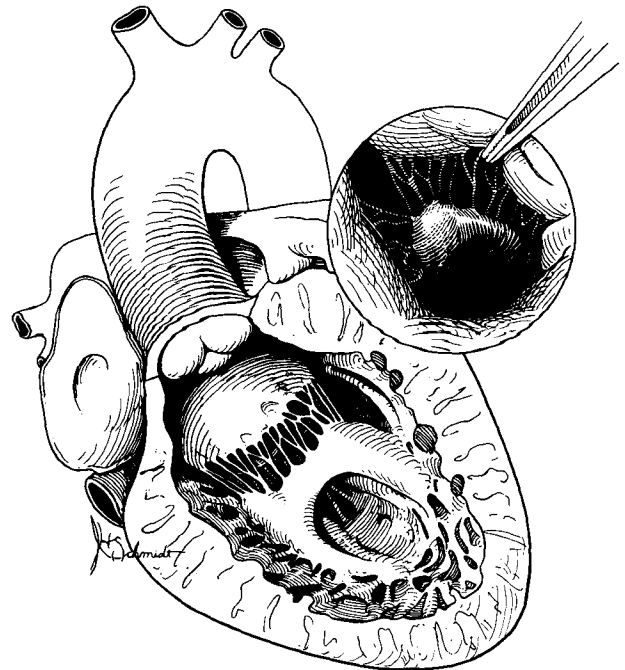
*Address reprint requests to:* Raymond R. Fripp, M.D., Room H-404A, The Milton S. Hershey Medical Center, The Pennsylvania State University, Hershey, Pennsylvania 17033



**Fig. 1.** Left: Two-dimensional echocardiogram long axis view showing mass associated with the anterior mitral leaflet. Right: Schematic diagram of 2-dimensional echocardiogram at left. AML = anterior mitral leaflet; AOV = Aortic valve; MA = mass effect caused by mitral arcade of papillary muscles; LA = Left atrium; LV = left ventricle.



**Fig. 2.** Contrast angiogram in left anterior oblique view showing left ventricular mass effect (arrow).



**Fig. 3.** Artist's concept of mitral arcade of papillary muscle. Insert shows surgeon's view through left atrium with anterior mitral leaflet retracted.

## Discussion

Congenital abnormalities of the various components of the mitral valve apparatus, such as the valvular substance, the chordae, and the papillary muscles, in infancy have been well documented by Davachi et al. [2]. Anomalous mitral arcade was first described by Layman and Edwards [4]. Davachi reported on 4 infants ranging in age from 3 weeks to 11 months, one of whom was living following surgical excision because of obstruction of the mitral valve. In 3 necropsied specimens, evidence of mitral stenosis and insufficiency was present. Casteneda et al. [1] have also reported on repair of a mitral arcade. In all these patients, the

chordae tendineae were thickened and short, but in our patient the chordae appeared normal. This may explain the normal hemodynamic status of our patient.

In the usual mitral arcade, there is a funnel-shaped structure with shortened, thickened and fused chordae, and fibrotic leaflets with fused commissures. In another type there is a parachute mitral valve complex in which the chordae tendineae of both leaflets insert on a single papillary muscle. The second type is part of a developmental complex including other malformations, such as a supra-valvular ring of the left atrium, subaortic stenosis, or coarctation.

Our case was unusual in that the chordae of the

anterior mitral leaflet suspended the arcade produced by the fused musculature of the upper part of the 2 papillary muscles of the left ventricle.

We may postulate that in an arcade mitral valve there is an abnormality in the connections between the left-sided endocardial cushions and the developing trabeculae. Collagenization of the muscular portion of the valve then takes place and the completed mitral valve arcade is formed. The length and numbers of chordae are variable, and they may be entirely absent or decreased in number and/or length. As noted above, our case of arcade mitral valve was especially peculiar in that the chordae were of normal length and thickness, allowing for normal valve function.

The relationship between the cerebral vascular accident and the mitral arcade remains unclear. It is conceivable that the transverse bar of papillary muscle was a thrombogenic site. Although the echocardiographic findings of mitral arcade have

not been previously described, we believe the diagnosis can be made echocardiographically, thus eliminating the need for exploratory surgery.

*Acknowledgments.* Aided by Grant HL-07605 from the National Institutes of Health, National Heart, Lung and Blood Institute, Bethesda, Maryland.

## References

1. Castaneda AR, Anderson RC, Edwards JE (1969) Congenital mitral stenosis resulting from anomalous arcade and obstructing papillary muscles. Report of correction by use of ball valve prosthesis. *Am J Cardiol* 24:237-240
2. Davachi F, Moller JH, Edwards JE (1971) Diseases of the mitral valve in infancy. *Circulation* 43:565-579
3. Feigenbaum H: *Echocardiography*, 3rd ed. Philadelphia, Lea & Febiger, 1981, p 551
4. Layman TE, Edwards JE (1967) Anomalous mitral arcade. A type of congenital mitral insufficiency. *Circulation* 35:389-395