

Short report

Ataxic tetraparesis from lacunar infarction in the pons

J VAN GIJN, M VERMEULEN

From the Department of Neurology, University Hospital Rotterdam (Dijkzigt), Rotterdam, The Netherlands

SUMMARY A 45-year-old woman with hypertension suffered four episodes of right hemiparesis and two attacks of left hemiparesis, within seven months. On examination she showed weakness and cerebellar ataxia of all four limbs. Computed tomography demonstrated a radiolucent area in the base of the pons, consistent with lacunar infarction.

An unusual stroke syndrome with hemiparesis and cerebellar ataxia involving the limbs of the same side was first described by Fisher and Cole in 1965.¹ Pathologic study of three later patients showed in each case a lacunar infarct in the upper base of the pons, near the midline and contralateral to the ataxic hemiparesis.² After the advent of high-resolution computed tomography (CT), however, eleven of fourteen consecutively reported patients with this clinical syndrome had a lesion in the contralateral internal capsule³⁻¹¹ (one patient had a pontine haemorrhage,³ one patient a tumour in the mid-brain,⁴ and in one case the site of the lesion could not be determined¹¹). We report a patient in whom ataxic hemiparesis occurred on both sides, with separate onset, and in whom CT showed an infarct in the pons.

Case report

A 45-year-old woman woke in the night of August 24, 1978, with tingling and weakness of the right arm and leg. The symptoms had disappeared in the morning, but came back the next day, for an hour, and again four days later, after which she dragged her right foot for more than two weeks. She was seen at another hospital; no diagnosis was made at that stage. A fourth and last attack of right hemiparesis occurred on December 3; she recovered incompletely in a few weeks, with persistent tingling in the right hand. On February 12, 1979, she suffered a sudden

weakness of the *left* arm and leg, with severe "pins and needles" in the left hand. The left hemiparesis slowly regressed, but recurred on March 27.

We first examined her on March 29. The blood pressure was 200/100 mm Hg. She was mildly dysarthric. The jaw jerk was brisk, and corneomandibular reflexes could be elicited on both sides. The muscle tone was increased on passive flexion of the knees. The muscle power was reduced on the left side, especially in the extensors of the arm and the flexors of the leg. The right arm and leg showed minimal weakness. All four limbs were ataxic, with intention tremor and dysmetria, more markedly on the left. The tendon jerks were symmetrically brisk, with bilateral patellar clonus. The plantar reflexes were extensor. Sensa-

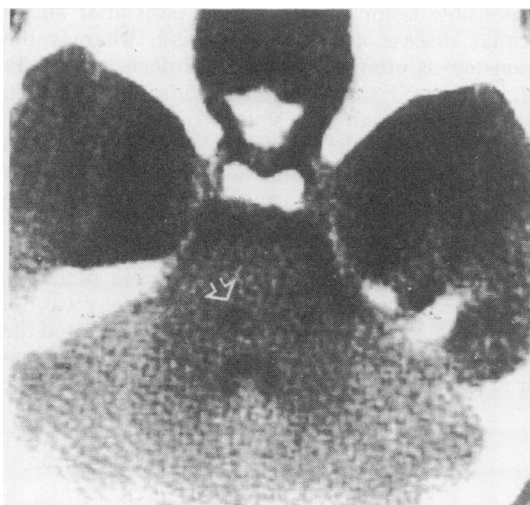


Figure CT scan showing left paramedian infarct in the basis pontis (arrow).

Address for reprint requests: Dr J van Gijn, Department of Neurology, University Hospital Rotterdam (Dijkzigt), Dr Molewaterplein 40, 3015 GD Rotterdam, The Netherlands.

Received 11 February, 1983

Accepted 12 March 1983

tion was completely normal. Her gait was broad-based, with circumduction of the left foot.

Laboratory studies of blood, serum, and cerebrospinal fluid (including IgG index) gave normal results. CT scanning (EMI 1010) showed a radiolucent area in the base of the pons on the left of the midline and bordering on the tegmentum (fig). The region of the internal capsule was normal on both sides.

After treatment with antihypertensive drugs, no further episodes of hemiparesis occurred during a follow-up period of three years. Re-examination in 1982 showed normal power of individual muscle groups, but a spastic gait with circumduction of the left leg. Rapid and alternating movements of both hands and feet were impaired, especially on the left, but without intention tremor or dysmetria. The reflex abnormalities were unchanged. Sensation was still normal, despite persistent tingling of both hands. A repeat CT scan no longer demonstrated the lesion in the pons.

Discussion

Two aspects stand out in this case history: the demonstration of a lacune in the pons by computed tomography, and the bilateral syndrome of ataxic hemiparesis, with separate onset on each side. Other features such as recurrent attacks and sensory symptoms are interesting but not uncommon in ataxic hemiparesis¹ and in other lacunar syndromes.¹⁰

Computed tomography has given a new impetus to the recognition of lacunar infarction.⁹⁻¹¹ The internal capsule is more often involved than previously suspected, not only in ataxic hemiparesis,⁵⁻¹⁰ but also in the dysarthria-clumsy hand syndrome.¹⁰⁻¹³ With capsular infarcts, contralateral cerebellar signs are difficult to understand, even more than with lesions of the basis pontis. In some of these cases the responsible lesion may be in the pons after all, as lacunar disease can be widespread, whereas the brainstem is often obscured by artifacts on CT. In our patient CT showed a small radiolucent area in the pons. Although the lesion corresponded with the less affected side, its subsequent decrease in size is compatible with recent infarction.¹⁴ One other report also demonstrated a pontine infarct on CT, in a patient with ataxic hemiparesis as well as trigeminal weakness.¹⁵

The site of the arterial lesion(s) in our patient is not precisely known. Vertebral angiography was not performed, as the results would not have altered the treatment. Occlusion of a single branch of the basilar artery may cause bilateral ischaemia in the base

of the pons,¹⁶ but alternating hemiparesis has not yet been reported in such a case. Stenosis or occlusion of paired branches of the basilar artery may result from atheroma of the parent vessel, or from intrinsic atheromatous disease (mirror lesions of this kind are at least known to occur in anterior perforating arteries),¹⁷ or finally from a combination of these two lesions.¹⁶

References

- Fisher CM, Cole M. Homolateral ataxia and crural paresis: a vascular syndrome. *J Neurol Neurosurg Psychiatry* 1965;**28**:48-55.
- Fisher CM. Ataxic hemiparesis—a pathologic study. *Arch Neurol* 1978;**35**:126-8.
- Schnapper RA. Pontine haemorrhage presenting as ataxic hemiparesis. *Stroke* 1982;**13**:518-9.
- Bendheim PE, Berg BO. Ataxic hemiparesis from a midbrain mass. *Ann Neurol* 1981;**9**:405-7.
- Perman GP, Racy A. Homolateral ataxia and crural paresis: case report. *Neurology (Minneapolis)* 1980;**30**:1013-5.
- Racy A, Perman GP. Ataxic hemiparesis. *Neurology (NY)* 1981;**31**:501.
- Iragui VJ, McCutchen CB. Capsular ataxic hemiparesis. *Arch Neurol* 1982;**39**:528-9.
- Ichikawa K, Tsutsumishihita A, Fujioka A. Capsular ataxic hemiparesis. *Arch Neurol* 1982;**39**:585-6.
- Weisberg LA. Lacunar infarcts—clinical and computed tomographic correlations. *Arch Neurol* 1982;**39**:37-40.
- Donnan GA, Tress BM, Bladin P. A prospective study of lacunar infarction using computerized tomography. *Neurology (NY)* 1982;**32**:49-56.
- Nelson RF, Pullicino P, Kendall BE *et al.* Computed tomography in patients presenting with lacunar syndromes. *Stroke* 1980;**11**:256-61.
- Spertell RB, Ransom BR. Dysarthria-clumsy hand syndrome produced by capsular infarct. *Ann Neurol* 1979;**6**:263-5.
- Rascol A, Clanet M, Manelfe C *et al.* Pure motor hemiplegia: CT study of 30 cases. *Stroke* 1982;**13**:11-7.
- Masdeu JC, Azar-Kia B, Rubino FA. Evaluation of recent cerebral infarction by computerized tomography. *Arch Neurol* 1977;**34**:417-21.
- Sakai T, Murakami S, Ito K. Ataxic hemiparesis with trigeminal weakness. *Neurology (NY)* 1981;**31**:635-6.
- Fisher CM. Bilateral occlusion of basilar artery branches. *J Neurol Neurosurg Psychiatry* 1977;**40**:1182-9.
- Fisher CM. Capsular infarcts—the underlying vascular lesions. *Arch Neurol* 1979;**36**:65-73.