

Mutism as a consequence of callosotomy

NEIL M. SUSSMAN, M.D., RUBEN C. GUR, PH.D., RAQUEL E. GUR, M.D., PH.D., AND
MICHAEL J. O'CONNOR, M.D.

*Departments of Neurology and Neurosurgery, The Graduate Hospital and the University of
Pennsylvania, Philadelphia, Pennsylvania*

✓ Transient mutism has been reported following commissurotomy and callosotomy. The cause for this mutism is unknown. A case of mutism following callosotomy is presented, and the preoperative and postoperative data on neurological, physiological, and psychological functioning are discussed. The data suggest that the mutism is not caused by general intellectual deterioration, cortical lesion, or peripheral damage affecting speech production. The syndrome may result from severing interhemispheric connections in cases where both hemispheres are required for speech production.

KEY WORDS • callosotomy • mutism • speech • hemispheric disconnection •
epilepsy • corpus callosum

COMMISSUROTOMY and callosotomy have been used in the treatment of medically intractable epilepsy that is not amenable to focal surgical excision.^{7,11,21,37,40} Sunderland³⁶ found in monkeys that the interhemispheric fibers are arranged anteriorly to posteriorly; the frontal lobes are connected via the rostrum and genu; the midtemporal, posterior temporal, and parietal lobe fibers pass through the body; and the occipital lobe fibers pass through the splenium. The mesial and anterior portions of the temporal lobes are connected via another pathway, the anterior commissure.

There are fewer than 100 reported cases of callosotomy for seizure control.^{1-7,11,12,21,31,33,37,39,40} This procedure is palliative and produces few obvious intellectual deficits.^{1-6,31,33} In addition to the "disconnection syndrome,"^{16,34} memory quotients have been reported to be lower in postcommissurotomy patients than might be expected on the basis of intelligence quotients (IQ's).⁴¹

A major consequence of this procedure is transient mutism.¹² Bogen¹⁰ reports that "in almost every case there was a time in which the patient was mute." Wilson, *et al.*,^{39,40} reported mutism in three of their first 12 cases. We present the pre- and postoperative data in a patient who suffered mutism following callosotomy. These data may be pertinent to an explanation of this phenomenon.

Case Report

This 20-year-old right-handed man had an 11-year history of seizures. He was the product of a normal pregnancy and a forceps delivery. He had delayed developmental milestones and was placed in special education classes from 6 years of age onward. His full-scale IQ at 7 years old was 73, with a verbal subscore of 91 and a performance subscore of 58.

Observed seizures began at 9 years old, with three to four episodes per week. One year later, he was noted to have one to two generalized tonic-clonic seizures per month, as well as episodes described as jerking of his head backward with momentary loss of awareness (10 to 15 per month). At the age of 12 years, he also experienced 15 epileptic drop attacks per month, requiring him to wear a helmet constantly. At 15 years of age he entered an institution for disabled children and had a normal physical and neurological examination, apart from a mild to moderate intellectual impairment. A seizure log was maintained for 3 months preoperatively by his school caretakers and revealed 94 atonic and tonic-clonic seizures. Numerous electroencephalographic (EEG) examinations showed diffuse abnormalities without a clear focus. He was admitted to our institution in August, 1980, for corpus callosotomy.

Examination. Neurological examination disclosed a cheerful cooperative boy with decreased attention

Mutism following callosotomy

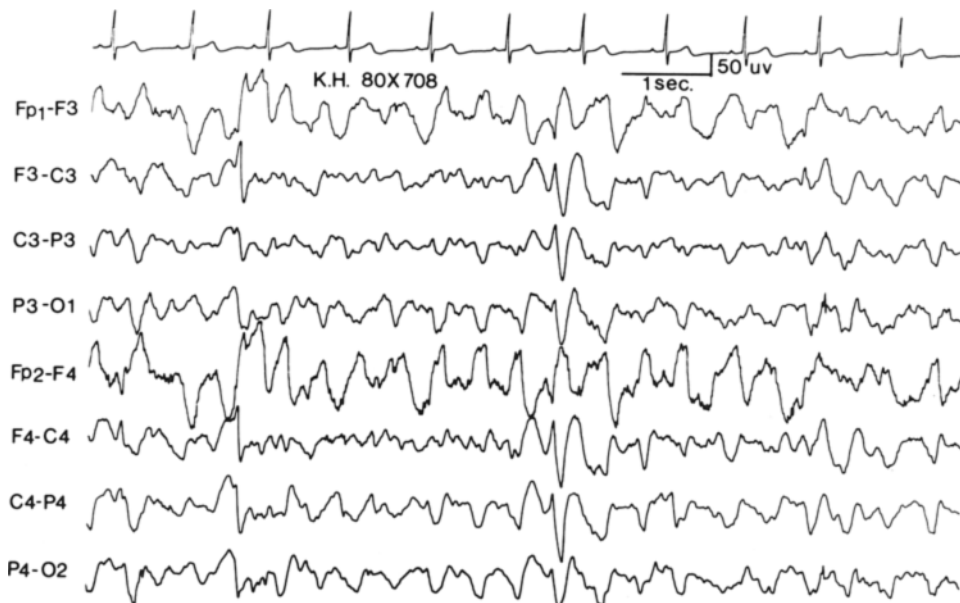

FIG. 1. Preoperative electroencephalographic tracings showing 2 to 2.5/sec slow activity (predominantly anteriorly), and generalized spike and wave activity with a phase reversal frontally. Low voltage activity (20 to 25/sec) can be seen anteriorly, and 6/sec background activity bilaterally, centrally, and parietally.

span. He was able to follow two-step commands. The first through 12th cranial nerves were intact. Sensory examination was normal except that double simultaneous stimulation resulted in left-sided extinction. Motor examination and reflexes were normal. There were mild cerebellar signs.

Intellectual functioning was within the mild to moderate mental retardation range (Wechsler Adult Intelligence Scale full-scale IQ score 59, verbal score 66, performance score 43). Neuropsychological testing indicated receptive vocabulary compatible with his verbal IQ (Peabody Picture Vocabulary Test (PPVT) score 67); and memory functioning at the level of his full-scale IQ score (memory quotient 51). Analysis of memory scale subtests revealed significantly poorer functioning in visual reproduction than logical-verbal memory. This, combined with the lower performance IQ score, was interpreted as suggesting poorer functioning of the right than the left cerebral hemisphere. However, on tasks requiring sensory perceptual integration the left hemisphere appeared more impaired. Since seizures interrupted testing, the neuropsychological test scores may underestimate his abilities. Indeed, the patient was effusive and at times witty during informal discussion. For example, when asked how he felt about the extensive preoperative testing he said, "I feel as if I am going through World War II without a gun."

Preoperative EEG showed irregular, anteriorly predominant bilateral spike and wave activity at a rate of 2 to 2½/sec. The background activity was 6/sec (Fig. 1). Computerized tomography (CT) scans showed moderate cortical atrophy, vermian atrophy, and mildly en-

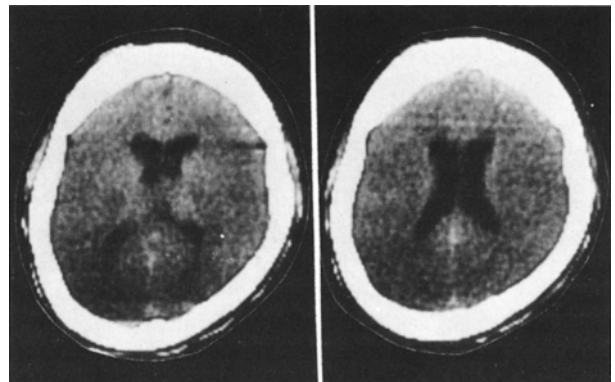


FIG. 2. Preoperative computerized tomography scans without contrast material at the level of the basal ganglia (*left*) and at a contiguous higher section at the level of the body of the lateral ventricles (*right*). Mild ventricular dilatation is apparent.

larged ventricles (Fig. 2). Positron emission tomography (PET) revealed a region of hypometabolism extending throughout the left temporal lobe.¹⁹

Pancerebral arteriography, performed in conjunction with the intracarotid amobarbital study, was normal. There was filling of both anterior cerebral arteries when each internal carotid artery was injected. Only ipsilateral middle cerebral arteries were visualized. The posterior cerebral arteries were visualized when the right vertebral artery was injected. The Mayo Clinic procedure was followed for the amobarbital study.⁹ Each

internal carotid artery was injected with amobarbital (100 mg). There was no speech or vocalization for 4 minutes 26 seconds following right hemispheric injection and for 5 minutes 56 seconds following left hemispheric injection.

Operation. Corpus callosotomy was performed when the patient was 18 years old. He was placed in the supine, semi-sitting position. The surgical technique followed the procedure described by Wilson, *et al.*,^{38,40} in which the corpus callosum is divided without entering the third ventricle. The hippocampal commissure was sectioned, but the anterior commissure was not divided. To divide the genu, rostrum, and anterior portion of the body of the callosum the neck was extended and a coronal incision was placed 9 cm posterior to the nasion, starting 3 cm to the left of midline and extending 8 cm to the right of midline. Two burr holes were placed over the sagittal sinus, 4 cm apart, with the anterior burr hole placed approximately at the intercept of a tangent of the A₂ segment of the anterior cerebral artery with the skull. A craniotomy, which extended just to the left of the sagittal sinus and 4 cm to the right, was made with the neurotome. The dura was opened and the medial aspect of the right frontal lobe was retracted laterally to expose the midportion of the body of the corpus callosum. This portion was approached first because the falx was complete posteriorly and the pericallosal arteries could be identified prior to dissecting adhesions between the cingulate gyri.

Under $\times 16$ magnification and 300 mm focal length, the corpus callosum was divided with No. 5 and No. 6 French suction devices down to, but not through the blue-appearing ependymal lining of the roof of the ventricle. Working forward between the pericallosal arteries, the genu was divided and the subarachnoid space around the A₂ segment of the anterior cerebral arteries was entered. Section was completed where the genu disappeared into the rostrum. Similar techniques were used to section the splenium and posterior body. With the patient's neck flexed, a 10 cm coronal incision was placed 4 cm behind the midpoint between the nasion and inion, permitting a 5-cm craniotomy which extended just to the left of midline. Retraction of the right parietal lobe permitted recovery of a cottonoid, which had been placed at the posterior extent of the first dissection, and continuation of the section posteriorly. Callosal fibers were then divided posteriorly until the arachnoid membrane overlying the vein of Galen and the cerebellum were seen. In this case, the cingulate gyri may have been entered and fornices may have been touched. (In more recent procedures, we have sectioned the splenium and posterior body through the anterior craniotomy.) Dexamethasone (Decadron, 10 mg) was given every 6 hours for 12 hours preoperatively and for 3 days postoperatively.

Postoperative Course. The patient was seizure-free for the first 6 postoperative months. Five nocturnal convulsions were observed at monthly intervals be-

tween the 7th and 12th postoperative months. Six diurnal seizures were seen during the 2nd postoperative year (about one every other month), characterized by shaking of the right arm and leg and stiffening of the left side.

Snout and bilateral grasp reflexes were seen only during the 1st postoperative day and Babinski signs persisted for 3 months. A disconnection syndrome was demonstrated through testing on the 8th postoperative day (the patient was not testable during the 1st postoperative week). With vision obscured, the patient was able to identify (by writing with his right hand) objects placed in his right hand, but not in his left hand. He was unable to identify by writing (with either hand) objects placed in his left hand. However, he could recognize objects through selecting them, by left-hand palpation, from an array of objects. The disconnection syndrome persists to the present time. On the 4th day, he had a buccofacial apraxia and was unable to move his mouth on command to smile, frown, whistle, stick out his tongue, or blow out his cheeks. The apraxia lasted for 16 months. An otolaryngological examination at 3 months and at 1 year showed normal hearing with normal reflex movement of palate and vocal cords. However, no voluntary movement of either was produced upon commands to gag or to pronounce "eee."

Transverse and coronal CT sections through the brain were obtained 6 weeks postoperatively without contrast administration. There was a midline lucency which extended from the genu of the corpus callosum posteriorly to the splenium, and probably represented postoperative changes resulting from sectioning the callosum. No parenchymal hemispheric abnormalities were demonstrated (see Fig. 3). Positron emission tomography showed symmetrical metabolism in the temporal lobe regions that had shown left-sided hypometabolism preoperatively.¹⁹

The EEG performed 6 weeks and 1 year postoperatively showed low- to medium-voltage 8/sec activity posteriorly and 5 to 6/sec activity centrally and parietally, with the right more predominant than the left. There were no rhythmic slow-wave bursts (Fig. 4). During sleep, spikes occurred independently on the right and the left with a frontal predominance.

The xenon-133 inhalation method for measuring regional cerebral blood flow was performed 2 weeks preoperatively and 6 weeks postoperatively.^{25,26,28} Flow was measured using 16 sodium iodide scintillation detectors placed over eight homotopic regions of each hemisphere. Preoperative flow was low in all regions. Postoperative flow was at a level comparable to age- and sex-matched normal individuals, with the exception of lower than normal flow in precentral regions.

The patient was mute for the first 16 postoperative months, except for eight brief one-sentence outbursts of speech. For example, on the 4th postoperative day, when electrode paste was placed on his head, he said "this smells like s---." On the 7th postoperative day, when a nurse commented that he was looking "good"

Mutism following callosotomy

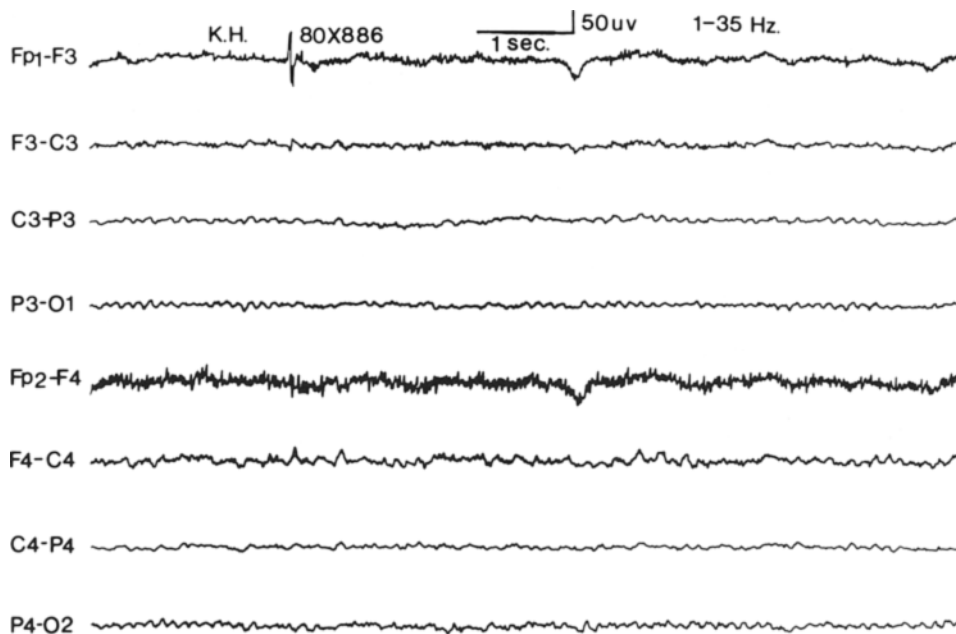


FIG. 3. Electroencephalographic tracings obtained 6 weeks postoperatively while the patient was awake, showing a background activity of 8/sec.

he responded "that's what everybody is telling me." Sixteen months postoperatively he started to whisper names of objects and his own name, and to repeat simple words. Articulation was difficult and the sound was breathy (produced with audible exhalation) without apparent paraphasias or other aphasic signs. The buccofacial apraxia improved, except for difficulties with rapid alternating lateral movements of the tongue without using lip support. Currently the patient speaks spontaneously and fluently, but his speech is somewhat pressured and choppy.

The patient received a standardized neuropsychological evaluation 4 months after surgery. Because of his mutism, only nonverbal tests were administered. The patient showed slight improvement on performance IQ (score 48) and a dramatic improvement in measures of perceptual and motor functions (although these were still impaired bilaterally relative to age-matched populations). The patient was tested again 15 months postoperatively. This time he was asked to respond to the verbal tests in writing. Results of this procedure clearly revealed retention of verbal IQ (score 64), and a substantial further improvement of performance IQ (score 58). Memory quotient was essentially unchanged (score 57).

Two years postoperatively, the patient continued to show intellectual improvement (full-scale IQ score 62, verbal IQ score 68, performance IQ score 60). His receptive vocabulary was somewhat poorer (PPVT standard score 55). Sensorimotor tasks also showed continued improvement.

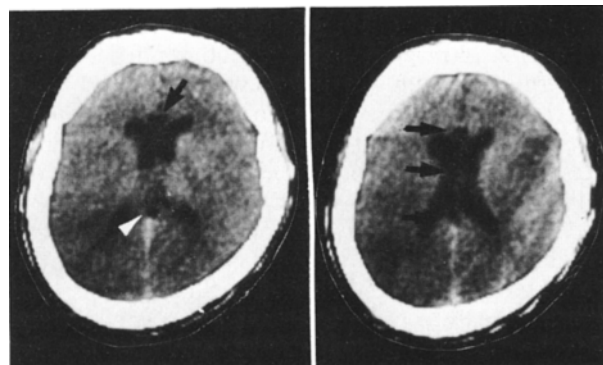


FIG. 4. Computerized tomography scans without contrast material 6 weeks postoperatively at the same levels as in Fig. 2. *Left:* A lucent defect is visualized in the genu (*arrow*) and splenium (*arrowhead*) of the corpus callosum. *Right:* A lucent defect extends through the body of the corpus callosum from the genu to the splenium (*arrows*). The frontal horn and body of the lateral ventricles are slightly smaller than preoperatively.

Discussion

Corpus callosotomy has reduced the number of seizures in this patient. It also produced transient mutism. For the first 16 postoperative months, his speech production was limited to a few sentences or statements. He comprehended written and verbal information and was able to communicate by writing and gesturing. The results of the pre- and postoperative observations and

testing may provide a step toward some understanding of possible mechanisms responsible for the postoperative mutism.

The patient's neurological and neuropsychological functioning remained the same or improved following surgery. Thus, it is unlikely that the mutism was a concomitant of general intellectual deterioration due to direct cortical damage. The syndrome does not resemble aphasias resulting from lesions in cerebral language areas,^{8,17,18,23,24,29} nor does it resemble mutism following lesions of the supplementary motor area either on the left²² or the right,¹³ where the deficit is not specific to vocalization but includes other language modalities (writing and comprehension). The syndrome does not resemble akinetic mutism,^{15,27} since the patient was unimpaired in all aspects of movement initiation except for the mutism and buccofacial apraxia. He did not exhibit speech apraxia,²⁰ because when he spoke, no articulatory defects were noted. Mutism is reported as a symptom in severe psychiatric disturbances such as schizophrenia (catatonic type) and depression.³⁵ This patient showed symptoms of depression from the 5th through the 8th postoperative days; the depression cleared but the mutism remained.

The syndrome of mutism in this patient shares some characteristics of aphemia^{8,30} as described by Benson:⁸ "Acute mutism without impairment of comprehension and writing abilities associated with buccofacial apraxia." Recovery from aphemia is frequently initiated by a period of whispering. Previous cases of aphemia have been reported following left hemispheric lesions.^{8,30} In none of the reported cases did the aphemia last more than a month, and instances of spontaneous speech as seen in this patient have not been reported. Removal of the entire left hemisphere likewise has not caused such long-term effects on speech production.^{14,32} The only cases in which mutism was reported to have lasted several months followed commissurotomy.¹² However, sectioning the corpus callosum is not in itself sufficient to produce mutism, because cases of callosotomy have been reported without mutism.^{7,11,21,37,40} Therefore, one may conclude that either a second lesion must be present, or that individual variation in organization of linguistic functions results in different responses to callosotomy. Since these patients are epileptic, it is reasonable to assume that other lesions are present. In our patient none was large enough to be visualized on preoperative computerized tomography (CT) scans.

Bilateral supplementary motor damage may have been produced intraoperatively by bilateral anterior cerebral artery spasm, or mechanical pressure secondary to retraction. Such damage would account for the snout, grasp, and Babinski reflexes. Furthermore, unilateral supplementary motor cortex damage has been reported to produce transient mutism and aphasia.^{13,22} However, on the eight occasions when the patient spoke, his sentences were clear and grammatically correct. By the time speech production had virtually

stopped (11th postoperative day), the snout and the grasp reflexes had cleared. The Babinski signs disappeared 3 months after surgery, but the mutism remained. Thus, it is unlikely that these phenomena result from a common cortical mechanism such as bilateral supplementary motor region destruction. In addition, the postoperative CT scan did not reveal edema or structural lesions except for the destruction of the corpus callosum. Finally, the EEG did not show any significant focal slowing or subclinical seizure activity. Regional cerebral blood flow improved postoperatively to normal in all regions except the frontal lobes, where it increased but did not reach normal levels. It is unclear why cutting the corpus callosum is followed by a relative decrease in blood flow in the frontal regions (both middle and anterior cerebral artery territories). However, the reduction in frontal blood flow may indicate a physiological abnormality in regions that include structures important for speech production. Apparently, the neural mechanisms subserving speech were suppressed, not destroyed.

For a full evaluation of individual differences in linguistic organization, more cases are needed, complete with sufficient preoperative data. It should be noted that in this case the intracarotid amobarbital study indicated slow return of speech following each injection. It may be that early cerebral insult or delayed language acquisition resulted in bilateral speech representation making it difficult for the left hemisphere to support speech without input from the right. Thus, in patients in whom postoperative mutism occurs, speech production may require interhemispheric interaction.

Acknowledgments

We thank this patient and his family for devoting their time and effort to this study. We also acknowledge the staff of the Comprehensive Epilepsy Center at Graduate Hospital for their cooperation, and Joseph Bogen, Norman Geschwind, Herbert Goldberg, John Gordon, Nancy Helm-Estabrooks, Jerre Levy, Martin Reivich, Andrew Saykin, and Steven Warach for their help.

References

1. Akelaitis AJ: Studies on the corpus callosum. II. The higher visual functions in each homonymous field following complete section of the corpus callosum. *Arch Neurol Psychiatry* 45:788-796, 1941
2. Akelaitis AJ: Studies on the corpus callosum. VI. Orientation (temporal-spatial gnosis) following section of the corpus callosum. *Arch Neurol Psychiatry* 48:914-937, 1942
3. Akelaitis AJ: Studies on the corpus callosum. VII. Study of language functions (tactile and visual lexia and graphia) unilaterally following section of the corpus callosum. *J Neuropathol Exp Neurol* 2:226-262, 1943
4. Akelaitis AJ: Studies on the corpus callosum. VIII. The effects of partial and complete section of the corpus callosum on psychopathic epileptics. *Am J Psychiatry* 98:409-414, 1941
5. Akelaitis AJ: A study of gnosis, praxis and language following section of the corpus callosum and anterior commissure. *J Neurosurg* 1:94-102, 1944

Mutism following callosotomy

6. Akelaitis AJ, Risteen WA, Herren RY, et al: Studies on the corpus callosum. III. A contribution to the study of dyspraxia and apraxia following partial and complete section of the corpus callosum. *Arch Neurol Psychiatry* 47:971-1008, 1942
7. Amacher AL: Midline commissurotomy for the treatment of some cases of intractable epilepsy. Preliminary report. *Childs Brain* 2:54-58, 1976
8. Benson DF: **Aphasia, Alexia, and Agraphia**. New York/Edinburgh/London: Churchill Livingstone, 1979, pp 129-131
9. Blume WT, Grabow JD, Darley FL, et al: Intracarotid amobarbital test of language and memory before temporal lobectomy for seizure control. *Neurology* 23:812-819, 1973
10. Bogen JE: Linguistic performance in the short term following cerebral commissurotomy, in Whitaker HA, Whitaker HA (eds): **Perspectives in Neurolinguistics and Psycholinguistics**, Vol 2. New York: Academic Press, 1976, pp 193-224 (see p 198)
11. Bogen JE, Vogel PJ: Cerebral commissurotomy in man. Preliminary case report. *Bull Los Angeles Neurol Soc* 27:169-172, 1962
12. Bogen JE, Vogel PJ: Neurological status in long term following complete cerebral commissurotomy, in Michel F, Schott B (eds): **Les Syndromes de Disconnexion Calleuse Chez l'Homme**. Lyon, France: Hôpital Neurologique, 1975, pp 227-251
13. Brust JCM, Plank C, Burke A, et al: Language disorder in a right-hander after occlusion of the right anterior cerebral artery. *Neurology* 32:492-497, 1982
14. Burklund CW, Smithe A: Language and the cerebral hemispheres. Observations of verbal and nonverbal responses during 18 months following left ("dominant") hemispherectomy. *Neurology* 27:627-633, 1977
15. Cairns H: Disturbances of consciousness with lesions of the brain-stem and diencephalon. *Brain* 75:109-146, 1952
16. Gazzaniga MS: **The Bisected Brain**. New York: Appleton-Century-Crofts, 1970
17. Geschwind N: Language and the brain. *Sci Am* 226 (4): 76-83, 1972
18. Geschwind N: Medical intelligence: current concepts. Aphasia. *N Engl Med J* 284:654-656, 1971
19. Gur RC, Sussman NM, Alavi A, et al: Positron emission tomography in two cases of childhood epileptic encephalopathy (Lennox-Gastaut syndrome). *Neurology* 32: 1191-1194, 1982
20. Johns DF, LaPointe LL: Neurogenic disorders of output proceedings: apraxia of speech, in Whitaker HA, Whitaker HA (eds): **Perspectives in Neurolinguistics and Psycholinguistics**. New York: Academic Press, 1976, pp 161-197
21. Luessenhop AJ, dela Cruz TC, Fenichel GM: Surgical disconnection of the cerebral hemispheres for intractable seizures. Results in infancy and childhood. *JAMA* 213: 1630-1636, 1970
22. Masdeu JC, Schoene WC, Funkenstein H: Aphasia following infarction of the left supplementary motor area. A clinicopathologic study. *Neurology* 28:1220-1223, 1978
23. Mohr JP: Rapid amelioration of motor aphasia. *Arch Neurol* 28:77-82, 1973
24. Mohr JP, Pessin MS, Finkelstein S, et al: Broca aphasia: pathologic and clinical. *Neurology* 28:311-324, 1978
25. Obrist WD, Thompson HK Jr, Wang HS, et al: Regional cerebral blood flow estimated by ¹³³Xenon inhalation. *Stroke* 6:245-256, 1975
26. Obrist WF, Wilkinson WE: The non-invasive Xe-133 method: evaluation of CBF indices, in Bes A, Geraud G (eds): **Cerebral Circulation. Proceedings of the International Congress on Cerebral Circulation**. Amsterdam/Oxford/Princeton: Excerpta Medica, 1979, pp 119-124
27. Plum F, Posner JF: **Diagnosis of Stupor and Coma**, ed 3. Contemporary Neurology Series, Vol 19. Philadelphia: FA Davis, 1980, 373 pp
28. Risberg J, Ali Z, Wilson EM, et al: Regional cerebral blood flow by ¹³³Xenon inhalation. Preliminary evaluation of an initial slope index in patients with unstable flow compartments. *Stroke* 6:142-148, 1975
29. Rubens AB: Aphasia with infarction in the territory of the anterior cerebral artery. *Cortex* 11:239-250, 1975
30. Ruff RL, Arbit E: Aphemia resulting from a left frontal hematoma. *Neurology* 31:353-356, 1981
31. Sidtis JJ, Volpe BT, Holtzman JD, et al: Cognitive interaction after staged callosal section: evidence for transfer of semantic activation. *Science* 212:344-346, 1981
32. Smith A, Oscar S: Development of above normal language and intelligence 21 years after left hemispherectomy. *Neurology* 25:813-818, 1975
33. Smith KU, Akelaitis AJ: Studies on the corpus callosum. I. Laterality in behavior and bilateral motor organization in man before and after section of the corpus callosum. *Arch Neurol Psychiatry* 47:519-543, 1942
34. Sperry RW, Gazzaniga MS, Bogen JE: Interhemispheric relationships: the neocortical commissures; syndromes of hemisphere disconnection, in Vinken PJ, Bruyn GW (eds): **Disorders of Speech, Perception, and Symbolic Behaviour. Handbook of Clinical Neurology**, Vol 4. Amsterdam: North-Holland, 1969, pp 273-290
35. Spitzer RL: **Diagnostic and Statistical Manual of Mental Disorders (DSM III)**. Washington, DC: American Psychiatric Association, 1980, 494 pp
36. Sunderland S: The distribution of commissural fibres in the corpus callosum in macaque monkey. *J Neurol Psychiatry* 2:9-18, 1940
37. Van Wagenen WP, Herren RY: Surgical division of commissural pathways in the corpus callosum. Relation to spread of an epileptic attack. *Arch Neurol Psychiatry* 44:740-759, 1940
38. Wilson DH: Limited exposure in cerebral surgery. Technical note. *J Neurosurg* 34:102-106, 1971
39. Wilson DH, Culver C, Waddington M, et al: Disconnection of the cerebral hemispheres. An alternative to hemispherectomy for the control of intractable seizures. *Neurology* 25:1149-1153, 1975
40. Wilson DH, Reeves A, Gazzaniga M: Division of the corpus callosum for uncontrollable epilepsy. *Neurology* 28:649-653, 1978
41. Zaidel D, Sperry RW: Memory impairment after commissurotomy in man. *Brain* 97:263-272, 1974

Manuscript received December 13, 1982.

Accepted in final form April 13, 1983.

This work was supported by a Spencer Foundation grant to Dr. Ruben Gur, and NIMH Grant 30456 to Dr. Raquel Gur.

Address reprint requests to: Neil M. Sussman, M.D., Department of Neurology, The Graduate Hospital, 1 Graduate Plaza, Philadelphia, Pennsylvania 19146.