

# Thrombotic and Hemorrhagic Strokes Complicating Early Therapy for Childhood Acute Lymphoblastic Leukemia

JOHN R. PRIEST, MD,\* NORMA K. C. RAMSAY, MD,\* RICHARD E. LATCHAW, MD,† LAWRENCE A. LOCKMAN, MD,§  
DUANE K. HASEGAWA, MD,\*‡ THOMAS D. COATES, MD,|| PETER F. COCCIA, MD,\* J. ROGER EDSON, MD,‡  
MARK E. NESBIT, JR., MD,\* AND WILLIAM KRIVIT, MD, PhD\*

**Sudden cerebrovascular insults occurred during or immediately following remission induction therapy in 4 children with acute lymphoblastic leukemia. In 3, cerebral infarction was due to thrombosis. In the fourth, an intracerebral hematoma developed representing either frank hemorrhagic or a hemorrhagic infarction. None of the patients had central nervous system leukemia or extreme leukocytosis at the time of diagnosis. Symptoms were obtundation, hemiparesis, seizures, and headache. The induction chemotherapy included L-asparaginase which causes deficiencies of antithrombin, plasminogen, fibrinogen, and factors IX and XI. These hemostatic abnormalities may explain the thromboses and bleeding observed in these children.**

*Cancer* 46:1548-1554, 1980.

**A**DVANCES IN THE TREATMENT of acute lymphoblastic leukemia in children have resulted in a more than 60% five-year survival rate,<sup>15</sup> and thus attention to reducing or eliminating complications has become mandatory.<sup>6,11,29</sup> Central nervous system (CNS) complications may result from CNS leukemia, from intrathecal chemotherapy and CNS radiation, or, less commonly, from systemic chemotherapy.<sup>2,5,6,26</sup> Acute intracerebral hemorrhaging may occur in patients with extremely high leukocyte counts,<sup>8</sup> severe thrombocytopenia, or disseminated intravascular coagulation. Intracerebral thrombosis has been reported as a complication of CNS leukemia.<sup>7</sup>

We have observed sudden cerebrovascular insults<sup>24</sup> (strokes) in 4 children with acute lymphoblastic leukemia who had no predisposing conditions. All 4 episodes occurred at the end of remission induction therapy or early during prophylactic CNS therapy. In 3 cases, the strokes were thrombotic, and in 1,

hemorrhagic. The marrow induction therapy for each patient consisted of vincristine, prednisone, and L-asparaginase.

L-asparaginase produces numerous hemostatic defects, probably by inhibiting synthesis of various clotting proteins. In a study of 26 children with acute lymphoblastic leukemia receiving vincristine, prednisone, and L-asparaginase, hypofibrinogenemia was found in every patient.<sup>25</sup> In addition, factor IX and XI deficiencies and prolonged plasma partial thromboplastin times occurred in most patients. Antithrombin and plasminogen deficiencies were described in the early reports of L-asparaginase.<sup>4,9</sup> We postulate that the cerebrovascular complications we have observed resulted from disturbances in the plasma coagulation, coagulation inhibiting, and fibrinolytic systems induced by L-asparaginase.

## Materials and Methods

Three of the patients were treated at the University of Minnesota Hospitals and 1 (Case 4) at the University of Indiana Hospitals. In the Minnesota patients, the one-stage prothrombin time, (PT), Kaolin-activated partial thromboplastin time (PTT), thrombin time (TT), and fibrinogen were determined sequentially during induction therapy as previously reported.<sup>25</sup>

Following bone marrow relapse in 1 patient, serial determinations of plasminogen and antithrombin were made during reinduction chemotherapy. Each was measured by means of functional<sup>1,16</sup> and immunologic<sup>20</sup> methods.

From the Departments of \*Pediatrics, †Diagnostic Radiology, and ‡Laboratory Medicine and Pathology, and the §Division of Pediatric Neurology, University of Minnesota Health Sciences Center, Minneapolis, Minnesota and the ||Department of Pediatrics, Indiana University School of Medicine, Indianapolis, Indiana.

Supported in part by USPHS Grants HL07145, CA07306, CA21737, NIH grant NO1-HB-5-3022, and American Cancer Society Clinical Fellowship 4309 (J.R.P.).

Address for reprints: J. R. Priest, MD, Box 56 Mayo Memorial Building, University of Minnesota Hospitals, Minneapolis, Minnesota 55455.

The authors thank Beverly J. Tyler, MT, ASCP, and Del Bennett, MT, ASCP, of the Coagulation Laboratory, University of Minnesota Hospitals, for expert technical assistance.

Accepted for publication November 7, 1979.

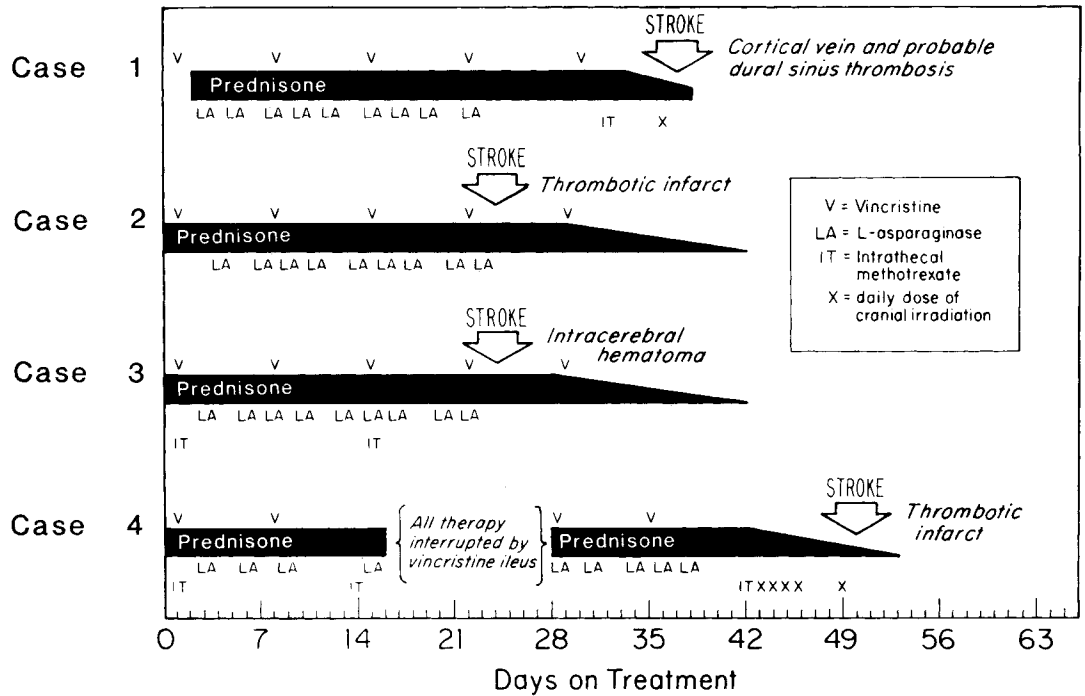


FIG. 1. Timing of remission induction chemotherapy and central nervous system prophylaxis preceding the onset of stroke symptoms.

**Case Reports**

The 4 cases of acute lymphoblastic leukemia were diagnosed during the period between 1975 and 1978. Surface marker analysis in each case revealed non-T, non-B leukemic blasts. The cases were treated on Children's Cancer Study Group protocols and each patient received: vincristine, 1.5 mg/m<sup>2</sup> (maximum, 2 mg) intravenously (IV) weekly for five doses; prednisone, 40 mg/m<sup>2</sup>/day orally for 28 days followed by a 14-day taper; and L-asparaginase, 6000 IU/m<sup>2</sup> intramuscularly (IM) three times per week beginning on day 3 or 4, for a total of nine doses. The schedule for CNS prophylaxis varied in the protocols. The specific timing of all therapy before the stroke for each patient is presented in Fig. 1. Intrathecal methotrexate (IT MTX) doses were 12 mg at a concentration of 1 mg/ml diluted in Elliot's B solution. During the period from 1972 through 1978, 301 patients with acute lymphoblastic leukemia underwent initial induction chemotherapy at the two institutions with the above schedule for vincristine, prednisone, and L-asparaginase.

In each case, cerebrospinal fluid (CSF) was examined at the time of diagnosis, when IT MTX was given (Fig. 1), and at the time of the stroke (except for Patient 3, who had a focal, space-occupying lesion). The glucose, protein, cell counts, cytocentrifuge preparations, and bacterial cultures of the CSF were normal in all samples.

*Case 1*

The patient, a 14-year-old boy, was diagnosed as having acute lymphoblastic leukemia after a three-week history of fatigue and pallor. The past medical history was unremarkable except that he had been considered mildly retarded when four and a half years old because of delayed speech,

but he had progressed well and was a B-/C+ student in high school. Laboratory data at the time of diagnosis included: hemoglobin, 4.3 g/dl; leukocyte count, 2,600/ $\mu$ l; and platelet count, 157,000/ $\mu$ l. During remission induction (Fig. 1), results of coagulation tests were most abnormal between days 20 and 25 (PT, 13.9 sec; PTT > 180 sec; TT 24.1 sec; and fibrinogen, 0.04 g/dl) and then became normal. Remission in the marrow was achieved on day 28.

On day 32, the first dose of IT MTX was given (Fig. 1). On day 35, the patient had a headache. On day 36, the first dose of cranial radiation (200 rad) was given, and immediately thereafter, he complained of numbness and clumsiness of the right arm and hand. Several hours later, aphasia, dysarthria, right hemiparesis, right homonymous hemianopsia, and focal right extremity seizures developed. Hematologic and coagulation findings at this time are presented in Table 1.

Left common carotid angiographic examination demonstrated definite left frontal and parietal cortical vein thrombosis and probable superior sagittal sinus thrombosis. The superior sagittal sinus did not fill during the dynamic phase of a technetium-99m brain scan. A computerized tomographic (CT) scan of the head was normal. Results of an electroencephalogram (EEG) were consistent with the presence of a left hemisphere structural lesion.

The patient's condition improved quickly. Treatment with IT MTX was not resumed, but craniospinal radiation (1800 rad) was given one month after the stroke without incident. Mild right hemiparesis and mild expressive aphasia persisted; seizures were controlled with phenobarbital. A CT scan two years later showed left frontoparietal encephalomalacia. The EEG demonstrated an epileptogenic lesion at this site.

Twenty-eight months after diagnosis, the patient had a

TABLE 1. Hematologic and Coagulation Findings on Day of Stroke in Childhood Acute Lymphoblastic Leukemia

Patient	Peripheral blood			Coagulation			
	Hemoglobin (g/dl)	Leukocytes (cells/ $\mu$ l)	Platelets (cells/ $\mu$ l)	PT (sec.)	PTT (sec.)	TT (sec.)	Fibrinogen (g/dl)
1	9.0	4,100	268,000	10.4	27.5	14.3	0.30
2	8.6	2,900	207,000	15.7	>180	>120	0.02
3	7.5	6,600	128,000	13.3	103.6	17.8	0.06
4	9.3	750	330,000	12.5	23		0.56

PT = prothrombin time (normal range, 10–13 sec.); PTT = partial

thromboplastin time (normal range, 35–45 sec.); TT = thrombin time (normal range, 13–20 sec.).

marrow relapse. Reinduction therapy with vindesine, prednisone, and L-asparaginase was uncomplicated.

### Case 2

The patient, a 9-year-old boy, was diagnosed as having acute lymphoblastic leukemia following a two-week history of fatigue, fever, myalgias, and sore throat. The past medical history included recurrent mild headaches and a learning disability necessitating remedial reading classes. Laboratory data at the time of diagnosis included: hemoglobin, 7.7 g/dl; leukocyte count, 7,800/ $\mu$ l; and platelet count, 58,000/ $\mu$ l.

A summary of the patient's induction therapy is presented in Fig. 1. On day 19, he began to complain of persistent headache which by day 23 was severe and localized behind the right eye; results of neurologic and fundoscopic examinations were normal. On day 24, emesis, obtundation, and left hemihypesthesia, hemiparesis, and homonymous hemianopsia developed. Hematologic and coagulation findings at that time are presented in Table 1. Because of the prolonged clotting times, intracranial hemorrhaging was assumed, and he received a platelet transfusion and cryoprecipitate; the coagulation tests became normal. A CT scan performed immediately thereafter with and without contrast enhancement was normal. One week later, CT scanning demonstrated an area of low density in the parietal and occipital regions with surrounding contrast enhancement indicative of thrombotic infarction (Fig. 2). A brain scan was normal. Results of an EEG performed on the day of the stroke were consistent with the presence of a right parietal structural lesion, and seven days later, epileptiform activity was found in this region. Seizures did not develop.

The child's condition improved rapidly. Treatment with IT MTX and cranial radiation (2400 rad) was given without incident five weeks after the infarction. In subsequent months, mild neurologic residua persisted. Subsequent CT scans revealed right parietal encephalomalacia, but EEGs were normal.

Two years later, he experienced a marrow relapse and underwent reinduction therapy with vincristine, prednisone, and L-asparaginase as before. Because of the earlier thrombosis, serial determinations of antithrombin, plasminogen, PT, PTT, TT, and fibrinogen were made during induction and are presented in Fig. 3. The PT, PTT, and TT were prolonged, and the fibrinogen, antithrombin, and plasminogen concentrations depressed. On day 26 of reinduction,

he had a brief seizure, persistent visual hallucinations, and obtundation. The EEG, which had been normal at the start of reinduction, was markedly abnormal, suggesting the presence of a right hemisphere lesion with epileptiform discharges, but no changes were detectable on several CT scans. Results of plasma coagulation tests became normal after transfusion of cryoprecipitate and fresh frozen plasma (Fig. 3). The child improved quickly. Phenobarbital was given and neither seizures nor hallucinations recurred.

### Case 3

This patient, a 6-year-old girl, was seen with a one-week history of malaise, fever, and respiratory congestion. The past medical history was unremarkable. At the time of diagnosis, hemoglobin was 4.5 g/dl; leukocyte count, 3,700/ $\mu$ l; and platelet count, 80,000/ $\mu$ l. A summary of the induction therapy is presented in Fig. 1. The PT and TT remained within normal limits, fibrinogen reached a minimum level of 0.02 g/dl on day 16, and the PTT was at a maximum of 103 seconds on day 24. On that day, left focal motor seizures and obtundation developed. A CT scan showed two small areas of high density in the right frontal lobe representing intraparenchymal hemorrhaging (Fig. 4). A brain scan revealed increased uptake in the right frontal lobe. Results of hematologic and coagulation studies at that time are presented in Table 1. In immunologic assays, the antithrombin concentration was 30.7 mg/dl (normal, 24–35 mg/dl), and the plasminogen was 9.6 mg/dl (normal, 9–17 mg/dl). The child received a transfusion with cryoprecipitate which corrected the hypofibrinogenemia, and the PTT became normal.

The seizures were controlled with phenobarbital, and the child's neurologic function improved rapidly. A CT scan three days later showed partial resolution of the hematoma. Treatment with IT MTX was resumed without incident two weeks after the stroke. The child had minimal neurologic residua. An EEG performed one year later showed no epileptiform activity and treatment with phenobarbital was stopped. The leukemia remains in remission 20 months after diagnosis.

### Case 4

This patient, an 8-year-old girl, was diagnosed as having acute lymphoblastic leukemia following a two-week history of pallor, leg pain, and weakness. The past medical history

was unremarkable. Laboratory data at the time of diagnosis included: hemoglobin, 4.6 g/dl; leukocyte count 1,650/ $\mu$ l; and platelet count, 175,000/ $\mu$ l. As summarized in Fig. 1, induction therapy was interrupted for 12 days after day 15 because of a severe ileus presumed to result from vincristine. Treatment with L-asparaginase was not completed until day 38. The marrow was in remission on day 42. Cranial radiation (200 rad/day) was given on days 43–46 and 49. On day 49, she became lethargic and was followed at a community hospital until readmitted to the University Hospital on day 52. An enhanced CT scan was normal. Three days later, a dense left hemiparesis developed. Results of hematologic and coagulation studies at this time are presented in Table 1. An enhanced CT scan suggested an area of low density (thrombotic infarction) in the right frontoparietal region. The dynamic phase of a brain scan showed decreased flow to the right hemisphere. On EEG, there was prominent right anterior temporal slowing.

The child improved slowly, but a left hemiparesis persisted. There was no intellectual impairment. A CT scan performed eight weeks later showed a large area of encephalomalacia in the right frontal and temporal lobes indicating previous infarction. Treatment with IT MTX and cranial radiation (1800 rad) were given four weeks later without difficulty. The leukemia is in remission 13 months after diagnosis.

### Discussion

These 4 children had cerebrovascular accidents during or immediately following initial remission induction chemotherapy for acute lymphoblastic leukemia (Fig. 1). Three had thrombotic infarctions; one (Case 1) was documented angiographically as venous thrombosis and two (Cases 2 and 4) were arterial thromboses based on the pattern of CT scan changes. An intracerebral hematoma which developed in Case 3 could have represented frank hemorrhaging or hemorrhagic infarction following vascular occlusion.<sup>28</sup> One patient had received only systemic chemotherapy; 1, systemic therapy and IT MTX; and 2, systemic therapy, IT MTX, and cranial radiation (Fig. 1). The symptoms of the strokes were depressed consciousness in 4 cases, hemiparesis in 3, seizures in 2, and headache in 2. Patient 2 had a similar episode when exposed to the same drugs after relapse, but radiographic change was not demonstrable. These 4 are among 301 new cases of acute lymphoblastic leukemia treated with the same induction agents at our institutions.

Similar clinical courses occurred in 2 other cases of children with acute lymphoblastic leukemia. They are not reported here in detail because the cases were too complicated by multiple marrow and CNS relapses to allow clear analysis. In 1, a thrombotic stroke with seizures occurred after the sixth dose of L-aspa-

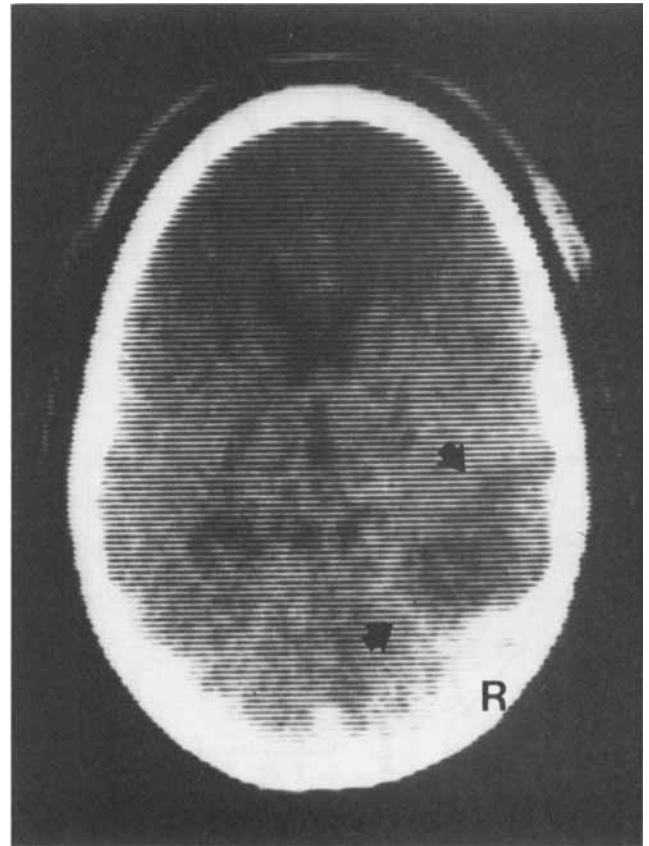


FIG. 2. Case 2. CT scan showing low density abnormality with surrounding contrast enhancement (arrows) in the right posterior temporal region. The findings are those of acute thrombotic infarction.

raginase (day 16 of reinduction); the lesion was shown to be hemorrhagic on CT scan six days later and resolved over the next two weeks. The child died several weeks later of progressive leukemia; no autopsy examination was done. In the other case, headache and lethargy proceeded to marked obtundation after the seventh dose of L-asparaginase (day 20 of reinduction). The child died one week later. Post-mortem examination, limited to the brain, revealed partially organized thrombi in the torcula, superior sagittal and left transverse sinuses, and in many of the cortical veins. There was also extensive hemorrhagic softening of the left cerebral hemisphere. There was evidence of left leptomenigeal cellular infiltration, but cellular necrosis prevented identification of this infiltration as leukemic. Ganick *et al.*<sup>13</sup> recently reported dural sinus thrombosis at the end of reinduction therapy for acute lymphoblastic leukemia in a patient who had received 15 doses of L-asparaginase and had no evidence of CNS leukemia.<sup>13</sup>

Intracranial hemorrhaging may occur in leukemic patients with extremely high leukocyte counts,<sup>8</sup> dis-

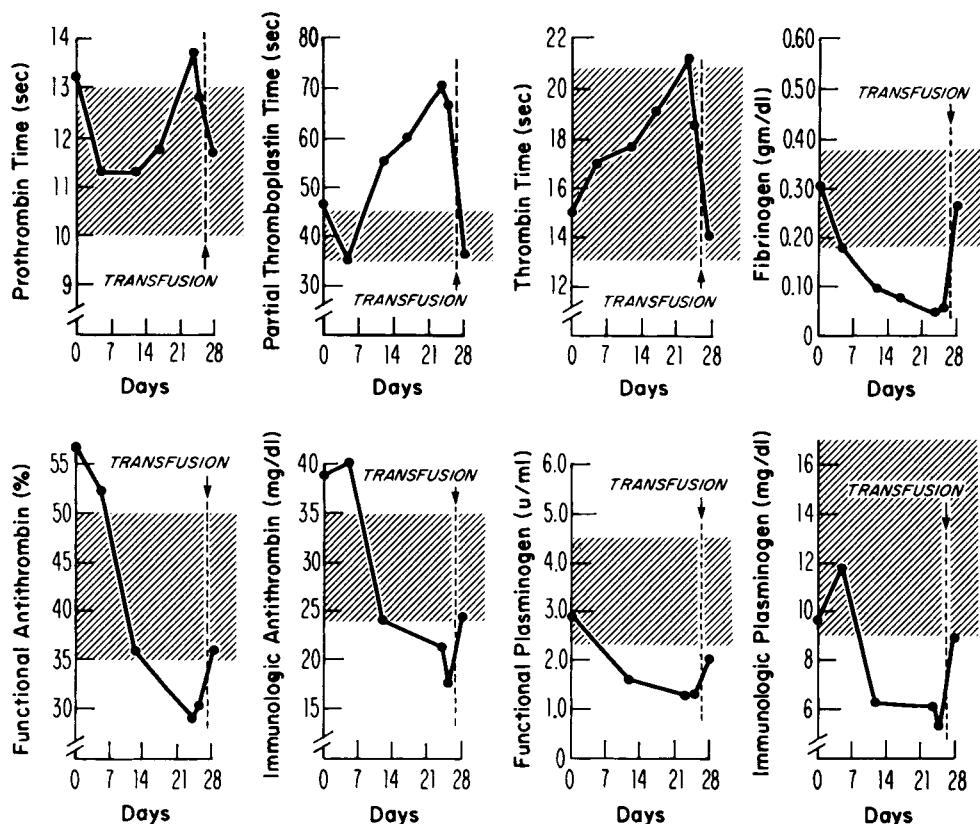


FIG. 3. Case 2. Sequential coagulation tests during reinduction with vincristine, prednisone, and L-asparaginase. The patient received transfusions of cryoprecipitate and fresh frozen plasma on the 26th day. Shaded areas indicate normal ranges for each test.

seminated intravascular coagulation, or severe thrombocytopenia. In patients with CNS leukemia, dural sinus thrombosis may occur<sup>7</sup> and a severe generalized encephalopathy has been reported to occur within hours of cranial radiation.<sup>22</sup> General conditions such as CNS infection, cardiac lesions, and dehydration are associated with cerebrovascular events in children.<sup>14</sup> The patients reported here had none of these predisposing conditions. However, coagulation abnormalities are common in children receiving L-asparaginase. In an earlier study of 26 children with acute lymphoblastic leukemia receiving L-asparaginase, all had hypofibrinogenemia, and most had prolonged plasma clotting times and low factor IX and XI concentrations.<sup>25</sup> The abnormalities were greatest between days 12 and 27 (median, day 19). Among the patients reported here, all 3 studied had this coagulopathy. Despite the hemorrhagic diathesis predicted by means of these laboratory tests, bleeding has been an infrequent problem for reasons not understood. Thrombosis, on the other hand, was entirely unexpected, particularly as it occurred in Patient 2, at a time when his fibrinogen was 0.02 g/dl, PTT > 180 sec, and TT > 120 sec (Table 1).

Antithrombin and plasminogen deficiencies were reported in early reports of L-asparaginase.<sup>4,9</sup> We confirmed this in Patient 2 during his second exposure

to the drug (Fig. 3) using both functional and immunologic assays because of a report that the results differed in patients receiving L-asparaginase.<sup>4</sup> We found no difference. In 4 subsequent cases of children with acute lymphoblastic leukemia, we have observed plasminogen and antithrombin depressions nearly identical to those seen in Patient 2. The combined effect of plasminogen and antithrombin deficiencies may lead to a thrombotic diathesis in some patients and may even protect other patients from the bleeding predicted by the usual clotting tests. Patient 3 had a markedly depressed fibrinogen level and prolonged PTT (Table 1) but normal plasminogen and antithrombin concentrations when her intracerebral hematoma developed.

Low antithrombin concentrations have been associated with thrombosis. In families with hereditary antithrombin deficiency, members with less than 50% of normal levels have an increased incidence of thrombosis.<sup>12,21</sup> Antithrombin deficiency secondary to urinary loss may contribute to the high frequency of thrombosis in the nephrotic syndrome.<sup>18,19</sup> Clear examples of thrombosis with plasminogen deficiency have not been reported, but this mechanism has also been proposed.<sup>23</sup>

Several factors may have contributed to the thromboses in Cases 1 and 4 which occurred five and ten days, respectively, after the end of induction chemo-

therapy (Fig. 1). The routine clotting tests showed these patients to be hypercoagulable (shortened PTT and/or elevated fibrinogen) at the time of the stroke (Table 1). This may represent a rebound following the induced deficiency of clotting proteins. In addition, each patient was still taking prednisone which increases factor VIII levels.<sup>3</sup> Unfortunately, plasminogen and antithrombin concentrations were not determined in these patients; our subsequent studies suggest that they return to normal levels within ten to 15 days after treatment with L-asparaginase is completed. Just after remission induction, platelet production is abundant, and large platelets are often seen.

Although hemostatic abnormalities existed, we do not understand why cerebral vessels were the site of clinical disease in these patients. In an adult patient with acute lymphoblastic leukemia, a basilic vein thrombosis developed following L-asparaginase therapy; low antithrombin concentrations were also documented (N. Anderson, J. J. Lokich, personal communication). Predisposition to the development of thrombosis in dural sinuses and cortical veins may lie, in part, in the unique anatomy and hemodynamics of these vessels. The veins enter the sinuses at oblique angles. Flow from the veins into the sinuses is directed against the direction of flow in the sinuses, and this leads to eddying and to a propensity to stasis.<sup>17</sup> This may explain the sagittal sinus and cortical vein thrombosis in patient 1. It would not explain thromboses of cerebral arteries (Patients 2 and 4). Of the 4 patients, 3 had received IT MTX, prior to the stroke (Fig. 1), but to our knowledge, thrombosis of vessels on the surface of the brain has not been reported as a complication of treatment with IT MTX, and it seems unlikely to have contributed to formation of the intraparenchymal hematoma (Patient 3) or the arterial thromboses (Patients 2 and 4). Patients 1 and 4 were receiving CNS radiation, albeit only one dose in Patient 4, in whom headache preceded the radiation. Radiation produces early<sup>10</sup> and late<sup>27</sup> effects on vessels and may create a nidus for thrombus formation. Two of the patients had a history of mild intellectual dysfunction, but that is not known to have any correlation with abnormalities of cerebral blood flow.

Both the acute and chronic complications of strokes may be devastating. Although all 4 patients recovered, 2 had persisting hemiparesis, 2 had seizures, and 1 had mild aphasia. An explanation for these strokes is not found in the results of routine coagulation tests, platelet counts, or conditions known to predispose leukemic patients to cerebrovascular disease. Plasminogen and antithrombin deficiencies accompany the clotting factor deficiencies reported earlier<sup>25</sup> and may create a thrombotic diathesis in some children. The

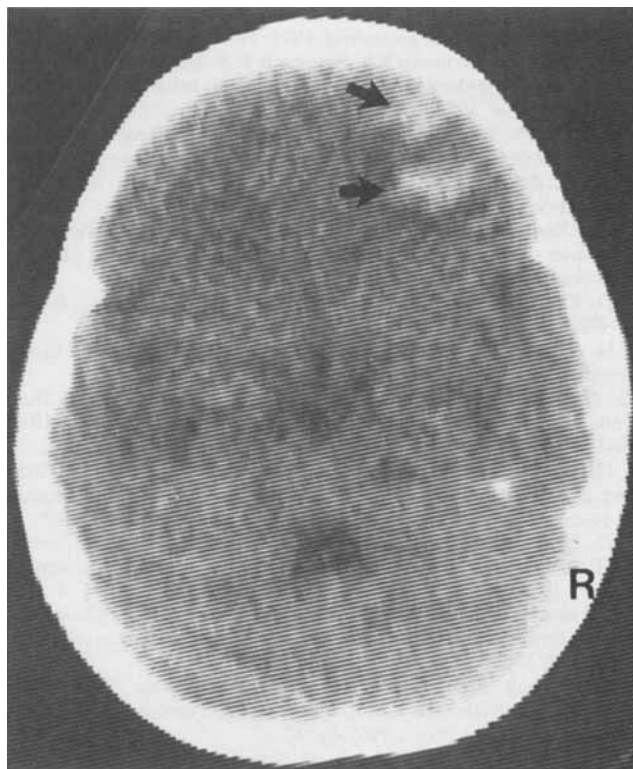


FIG. 4. Case 3. Unenhanced CT scan showing two areas of hemorrhaging in the right frontal lobe (arrows). The presence of two separate areas of hemorrhaging suggests that hemorrhagic infarction may be present.

coagulation, coagulation inhibiting, and fibrinolytic abnormalities induced by L-asparaginase should be monitored, and CNS symptoms carefully investigated. At present, we recommend serial EEGs, and CT and brain scans. Angiography is very sensitive but carries certain risks. Cryoprecipitate will correct hypofibrinogenemia, and transfusion of fresh frozen plasma will correct deficiencies of other factors, antithrombin, and plasminogen (Fig. 3). Future studies must document the incidence of this stroke syndrome and further explore its pathogenesis.

#### REFERENCES

1. Alkjaersig N, Fletcher AP, Sherry S. The mechanism of clot dissolution by plasmin. *J Clin Invest* 1959; 38:1086–1095.
2. Allen JC. The effects of cancer therapy on the nervous system. *J Pediatr* 1978; 93:903–909.
3. Brozovic M. Physiological mechanisms in coagulation and fibrinolysis. *Br Med Bull* 1977; 33:231–238.
4. Conard J, Durand J, Feger J, Samama M. Acquired abnormal antithrombin III in L-asparaginase treated patients? (Abstr. 193). In: IVth International Congress on Thrombosis and Haemostasis. Vienna, 1973:228.
5. Crosley CJ, Rorke LB, Evans A, Nigro M. Central nervous system lesions in childhood leukemia. *Neurology* 1978; 28:678–685.
6. D'Angio GJ. Complications of treatment encountered in lymphoma-leukemia long-term survivors. *Cancer* 1978; 42:1015–1025.

7. David RB, Hadfield MG, Vines FS, Maurer HM. Dural sinus occlusion in leukemia. *Pediatrics* 1975; 56:793-796.
8. Dearth JC, Fountain KS, Smithson WA, Burgert EO, Gilchrist GS. Extreme leukemic leukocytosis (blast crisis) in childhood. *Mayo Clin Proc* 1978; 53:207-211.
9. Deutsch E, Fischer M, Frischauf H, et al. Blood coagulation changes under L-asparaginase therapy. In: Grundmann E, Oettgen HF, eds. *Recent Results in Cancer Research*, vol. 33. New York: Springer-Verlag, 1970:331-341.
10. Dimitrievich GS, Hausladen SL, Kuchnir FT, Griem ML. Radiation damage and subendothelial repair to rabbit ear chamber microvasculature. *Rad Res* 1977; 69:276-292.
11. Editorial: The price of survival in childhood leukemia. *Br Med J* 1978; 1:321-322.
12. Egeberg O. Inherited antithrombin deficiency causing thrombophilia. *Thrombos Diathes Hemorrh* 1965; 13:516-530.
13. Ganick DJ, Robertson WC, Viseskul C, Lubinsky MS. Dural sinus thrombosis in leukemia. *Am J Dis Child* 1978; 132:1040-1041.
14. Golden GS, Fenichel GM. Vascular diseases of the brain and spinal cord. In: Swaiman KF, Wright FS, eds. *The Practice of Pediatric Neurology*. St. Louis: C.V. Mosby, 1975:639-665.
15. Hammond GD, Bleyer WA, Hartmann JR, Hays DM, Jenkin RDT. The team approach to the management of pediatric cancer. *Cancer* 1978; 41:29-35.
16. Hensen A, Loelinger EA. Antithrombin III: Its metabolism and its function in blood coagulation. *Thrombos Diathes Hemorrh (Suppl 10)* 1963; 9:1-84.
17. Kalbag RM, Woolf AL. *Cerebral Venous Thrombosis: With Special Reference to Primary Aseptic Thrombosis*. London: Oxford University Press, 1967:46-47.
18. Kauffmann RH, Veltkamp JJ, Van Tilburg NH, Van Es LA. Acquired antithrombin III deficiency and thrombosis in the nephrotic syndrome. *Am J Med* 1978; 65:607-613.
19. Lau SO, Hasegawa DK, Priest JR, Edson JR, Tkachuck JA. Nephrotic syndrome: sagittal sinus thrombosis, plasminogen and antithrombin deficiencies and heparinuria. (Abstr. 338.) *Blood (Suppl 1)* 1978; 52:187.
20. Mancini G, Carbonara AO, Heremans JF. Immunochemical quantitation of antigens by single radial immunodiffusion. *Immunochemistry* 1965; 2:235-254.
21. Marciniak E, Farley CH, DeSimone PA. Familial thrombosis due to antithrombin III deficiency. *Blood* 1974; 43:219-231.
22. Oliff A, Bleyer WA, Poplack DG. Acute encephalopathy after initiation of cranial irradiation for meningeal leukemia. *Lancet* 1978; 2:13-15.
23. Paton RC, Douglas AS. Mechanisms of thrombotic disease. In: Joachim HL, ed. *Pathobiology Annual*, vol. 6. New York: Appleton-Century-Crofts, 1976:59-93.
24. Priest JR, Ramsay NKC, Coates TD et al. Stroke syndrome complicating remission induction chemotherapy for acute lymphocytic leukemia. (Abstr. 392). *Proc Am Assoc Cancer Res* 1979; 20:97.
25. Ramsay NKC, Coccia PF, Krivit W, Nesbit ME, Edson JR. The effect of L-asparaginase on plasma coagulation factors in acute lymphoblastic leukemia. *Cancer* 1977; 40:1398-1401.
26. Weiss HD, Walker MD, Wiernik PH. Neurotoxicity of commonly used antineoplastic agents. *N Engl J Med* 1974; 291:75-81, 127-133.
27. Wright TL, Bresnan MJ. Radiation-induced cerebrovascular disease in children. *Neurology* 1976; 26:540-543.
28. Yates PO. Vascular disease of the central nervous system. In: Blackwood W, Corsellis JAN, eds. *Greenfield's Neuropathology*, 3rd ed. London: Edward Arnold Ltd., 1976:86-147.
29. Zuelzer WW. Childhood leukemia—a perspective. *Johns Hopkins Med J* 1978; 142:115-127.