

Migrainous Cerebral Infarction: A Tomographic Study of Cerebral Blood Flow and Oxygen Extraction Fraction with the Oxygen-15 Inhalation Technique

M. G. BOUSSER, M.D., J. C. BARON, M.D., M. T. IBA-ZIZEN, M.D.,
D. COMAR, M.D., E. CABANIS, M.D., AND P. CASTAIGNE, M.D.

SUMMARY A patient with migraine who had a permanent visual field defect was studied by angiography and CT scan. He also had a tomographic study of cerebral blood flow (CBF) and oxygen extraction fraction (EO₂) using the non-invasive continuous oxygen-15 (¹⁵O) inhalation technique. Angiography was normal. CT scan revealed an area of decreased density with contrast enhancement suggestive of a recent infarct in the left occipital lobe. The ¹⁵O inhalation technique showed a decrease in CBF and EO₂, typical of recent infarcts, in the corresponding area, an increase in CBF with normal EO₂ in the left temporal lobe, and a decrease in CBF with increased EO₂ in the right occipital cortex. These findings illustrate the unusual nature and extent of the ischemic process underlying migrainous cerebral infarction.

Stroke, Vol 11, No 2, 1980

LASTING NEUROLOGICAL DEFICITS, though infrequent, occur in migrainous subjects and are well documented by clinical,^{1,2} pathological,³ and, more recently, by computed cranial tomographic (CT) studies.⁴⁻⁶ We recently had the opportunity to study cerebral blood flow (CBF) and oxygen extraction fraction (EO₂) with the ¹⁵O inhalation technique coupled with positron emission tomography in a migrainous patient with a permanent visual field defect.

History

Clinical Summary

The patient is a 45-year-old right-handed man with a 25-year history of classical migraine. His attacks invariably began with blurring of vision, first intermittent for 2 or 3 min then stable for 10–15 min, followed by a left-sided or bi-temporal throbbing headache. The headache usually resolved in a few hours and was, on occasion, associated with photophobia and nausea. His attacks were infrequent (1 or 2 per year), generally mild, and no specific treatment was given.

One morning, without warning, he awoke with a complete loss of vision in the right visual field and a moderate left-sided headache. He had no dysphasia, paresthesia or weakness. The headache gradually worsened becoming generalized and excruciatingly painful and was accompanied by vomiting. His headache resolved over the succeeding 4 days, after which visual loss decreased.

Examination of his visual fields by confrontation 12

days later, revealed a right homonymous hemianopsia to finger movement, more dense in the upper quadrant. The left visual field was entirely normal. Blood pressure was 130/80 mm Hg. There was neither cervical nor cranial bruit.

When visual fields were studied with Amsler chart and Goldman perimetry, 20 days after the onset of symptoms, the patient had considerably improved, but there was still a right upper congruous homonymous quadrantic scotoma extending to 15° and without central sparing (fig. 1). When the patient was seen again, 6 weeks later, the visual field defect persisted unchanged.

Investigations

Normal laboratory studies included complete blood count, platelet count, serum electrolytes, sedimentation rate, blood urea nitrogen, glucose, creatinine, total protein, albumin, serum cholesterol, and triglycerides, serum glutamic oxaloacetic transaminases, alkaline phosphatases, urinalysis, and serologic tests for syphilis. His electrocardiogram, echocardiogram, chest and skull roentgenograms were also normal. His electroencephalogram showed abnormally slow activity over the posterior region of the left hemisphere.

CT scan, performed 18 days after onset, showed in the left occipital region an area of decreased density — approximately 30 mm × 60 mm in size — (fig. 2A) which markedly enhanced following the infusion of contrast material (fig. 2B). In the left temporal region, there was a large, ill-defined but definite area of decreased density (fig. 2C) with neither contrast enhancement nor mass effect.

Four vessel-angiography, 21 days after onset, was normal.

CBF and EO₂ (EO₂ is the oxygen arterio-venous difference divided by the arterial oxygen content) were measured 14 days after the onset of symptoms, with ¹⁵O₂ and C¹⁵O₂ continuous inhalation associated with

From the Clinique des Maladies du Système Nerveux. Hôpital de la Salpêtrière, Paris (Drs. Bousser, Baron and Castaigne). The Commissariat à l'Energie Atomique, Département de biologie, Service Hospitalier Frédéric Joliot, Orsay (Drs. Baron and Comar). Service de Radiologie, Centre National d'Ophtalmologie des Quinze-vingts, Paris (Drs. Iba-Zizen and Cabanis).

Reprints: Dr. Bousser, Clinique des Maladies du Système Nerveux, Hôpital de la Salpêtrière, 47, Blvd. de l'Hôpital, 75013-Paris, France.

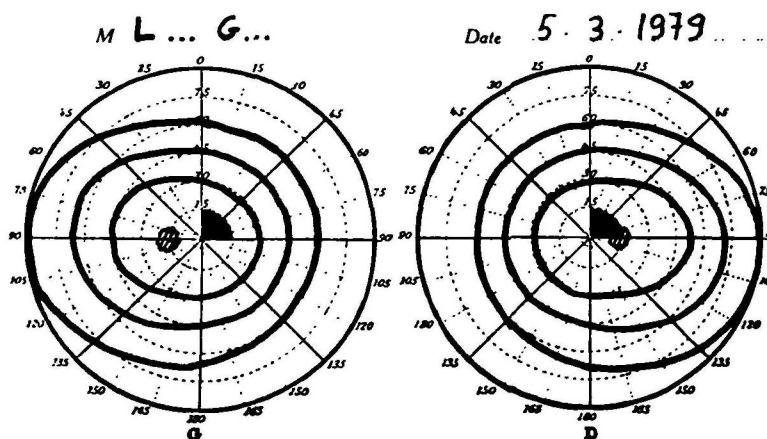


FIGURE 1. Goldman perimetry (20 days after onset): right upper homonymous quadrantic scotoma.

positron emission tomography, using the model proposed by Jones⁷ and the technique described by Baron.⁸ This method, already applied to normals⁹ and to patients with ischemic brain disorders¹⁰ will therefore not be described in detail here. For each transaxial brain level (studied at an angle of $+5^\circ$ from the orbito-meatal (OM) line), a set of 3 different images is obtained: 1) a $C^{15}O_2$ image which represents CBF, 2) a $^{15}O_2$ image which represents both oxygen metabolism and CBF, 3) a $C^{15}O_2/^{15}O_2$ ratio image which is linearly proportional to EO_2 . In the $C^{15}O_2$ and

$^{15}O_2$ images obtained in this patient, count rates per unit volume were calculated for various identical regions of interest. Each value was compared either to that of the homologous contralateral area or to that of the ipsilateral hemisphere and was considered abnormal if the difference was outside the confidence limits defined by 6 normal patients.¹¹ The same procedure was applied to the value obtained by dividing the $^{15}O_2$ count rate by the $C^{15}O_2$ count rate, i.e. a value linearly proportional to EO_2 .

On slices obtained 5.5 cm above the OM plane,

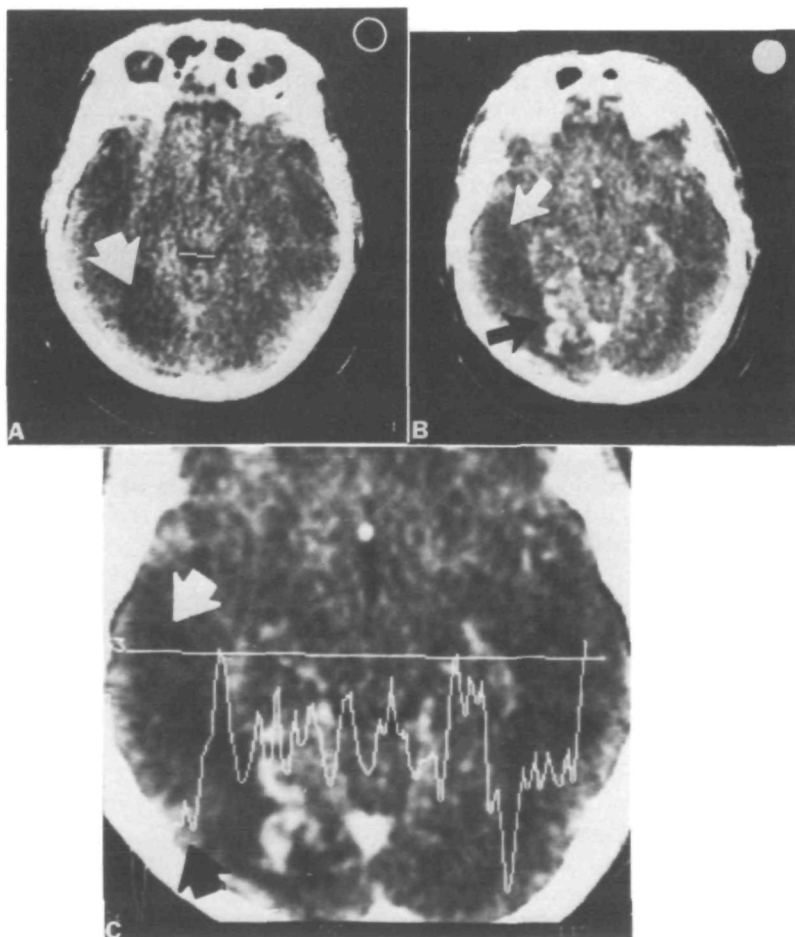


FIGURE 2. CT scan (18 days after onset). A — Focal hypodensity in the left occipital lobe. B — Contrast enhancement of the lesion. C — Hypodensity in the temporal lobe.

striking abnormalities were observed (fig. 3):

1) an increase in activity of similar magnitude ($p < 0.01$) on both the C^{15}O_2 (+15.5%) and $^{15}\text{O}_2$ images (17.2%) without significant change in the $^{15}\text{O}_2/\text{C}^{15}\text{O}_2$ ratio value in the left temporo-Sylvian area.

2) a decrease in C^{15}O_2 activity of similar magnitude ($p < 0.01$) in the left (-15.3%) and right (-14.6%) occipital regions associated with a) on the left side, a significant ($p < 0.01$) decrease in $^{15}\text{O}_2$ activity (-33.5%) and in $^{15}\text{O}_2/\text{C}^{15}\text{O}_2$ ratio value (-17.5%); b) on the right side, an unchanged $^{15}\text{O}_2$ activity (+3.4%, $p > 0.05$) but an increased $^{15}\text{O}_2/\text{C}^{15}\text{O}_2$ ratio value (+11.2% $p < 0.01$). On the slice OM + 7.5 cm, all images were normal. (fig. 3)

Discussion

This patient had typical migraine with a long past history, an acute onset of a neurological deficit during a severe attack of migraine, and the partial resolution of symptoms leaving a permanent neurological deficit. The visual field defect in our patient is similar to that reported by Mallory and shown by Polyak³ to be due to a small infarct in the lower margin of the calcarine fissure.

Angiography performed 21 days after the onset of symptoms was normal, as is often the case in migraine,^{1, 12} although in rare instances occlusion of the posterior cerebral artery or its branches has been observed.^{1, 12}

The diagnosis of cerebral infarction in our patient was made on the basis of the CT scan. Performed 18 days after the onset of symptoms, it showed an area of

decreased density with contrast enhancement in the left occipital lobe (fig. 2 A-B). This pattern of anomaly, without mass effect, is typical of recent infarcts and has already been described in complicated migraine.¹² A more common finding in this condition is, however, a region of low density without contrast enhancement, even observed occasionally in patients studied less than 10 days after onset.^{4, 5}

The other interesting finding on the CT scan was a definite decrease in density without contrast enhancement in the temporal lobe (fig. 2C) suggesting a disturbance in the territory of the middle cerebral artery with no clinical counterpart.

The main findings of interest are the tomographic studies of CBF and EO_2 with the $^{15}\text{O}_2$ continuous inhalation. Although indisputable experimental verification of the validity of the CBF and EO_2 measurements obtained with this technique has not yet been reported, there is, however, ample indirect evidence in humans that the tracer distribution in the C^{15}O_2 image is a reflection of CBF and that the $^{15}\text{O}_2/\text{C}^{15}\text{O}_2$ ratio image is a representation of the EO_2 .^{9, 10, 13, 14}

Results obtained from normal subjects and in patients with different pathological conditions suggest that the EO_2 , which is normally uniformly distributed,⁸ could be an important pathophysiologic parameter and even have a prognostic significance when studied concomitantly with CBF.^{10, 14-18}

The ^{15}O inhalation study performed 14 days after the onset of symptoms, showed 3 disturbance patterns:

1) EO_2 was decreased in the left occipital cortex strongly suggesting a focally decreased oxygen arteriovenous difference: this situation has been called "luxury perfusion" by Lassen.¹⁹ CBF, though decreased, was still over-abundant compared to the local metabolic demand since EO_2 was decreased, thus indicating a relative luxury perfusion.^{16, 19, 20} Such a focally decreased EO_2 has been observed in 82% of recent (less than 31 days) infarcts.¹⁰ This possible uncoupling of CBF and metabolism has never been reported in complicated migraine. It differs strikingly from the areas of reduced CBF usually observed during the prodromal phase of classical attacks.²¹⁻²³ It may, however, be related to the focal areas of high flow described by Marshall²⁴ in cases of migraine without headache but none of his patients had their cerebral metabolism studied. It is possible that patient 2 reported by Dorfman¹² also had a luxury perfusion since angiography showed arterio-venous shunting 4 days after the attack. Such an alteration was not seen in our patient, possibly because angiography was performed too late (3 weeks after the attack and a week after the CBF study). It should be noted that the decrease in CBF observed here was associated with CT contrast enhancement, thus illustrating that contrast enhancement does not necessarily imply increased perfusion. Other mechanisms must be involved, among them the breakdown of blood-brain barrier.²⁵

2) CBF was increased in the left temporal lobe contrasting with a normal EO_2 . This increase in CBF

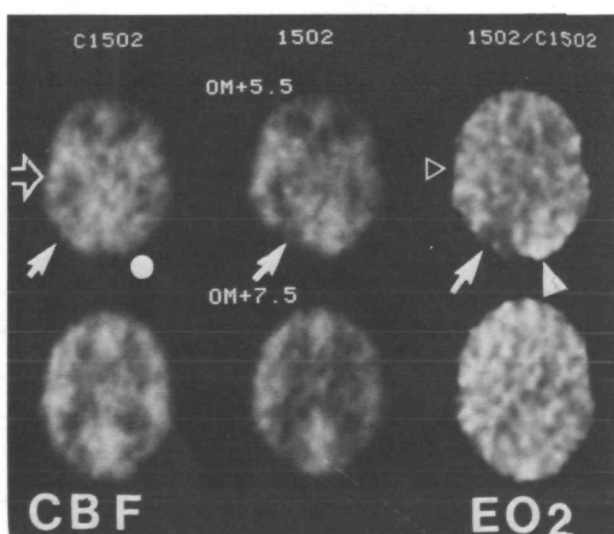


FIGURE 3. Tomographic study of CBF and EO_2 with the ^{15}O inhalation technique (14 days after onset). OM + 5.5 cm: Decrease in CBF (\rightarrow) and EO_2 (\rightarrow) in the left occipital cortex. Increase in CBF (\Rightarrow) with normal EO_2 (\triangleright) in the left temporal lobe. Increased EO_2 (\triangleright) with decreased CBF (\bullet) in the right occipital cortex. OM + 7.5 cm: all images are normal.

reflects an actual change of higher magnitude because of the underestimation of high values due to the non-linear relationship which exists between the count rate and CBF.⁷ However, such a focal hyperemia has been detected in a number of clinical situations by this technique.¹⁰ It probably corresponds to the situation described experimentally as "reactive hyperemia" or "supernormal blood flow," which is observed after acute ischemia when flow is restored.²⁸ Thus, there may have been in our patient a transient ischemia in the left middle cerebral artery territory. It is interesting to note that this hyperemic region appears hypodense on CT scan, but appears without contrast enhancement.

3) CBF was decreased but EO_2 increased in the posterior part of the right occipital cortex, indicating a situation of "supernormal oxygen extraction" for which we presently have no satisfactory explanation. Although all his previous attacks were characterized by blurring of vision in both visual fields, the patient denied any disturbance in the left visual field during the present attack of complicated migraine.

These observations show that the cerebral lesion responsible for the permanent visual loss has not only the same CT scan characteristics as an infarct, but also the same pattern of hemodynamic and metabolic disturbances, i.e. a luxury perfusion. They also show an increase in CBF and an increase in EO_2 respectively in the left temporal lobe and in the right occipital cortex suggesting an involvement, latent clinically, of the corresponding arterial territories and thus stressing the unusual nature and extent of the underlying process.

Acknowledgment

We thank most warmly for helpful advice and criticism Dr. R. W. Ross Russell (Institute of Neurology, London) who kindly revised the manuscript. The skilled technical assistance of N. Duquesnoy, J. Sastre, C. Loc'h is also gratefully acknowledged.

References

- Connor RC: Complicated migraine. *Lancet*, II: 1072-1075, 1962
- Walsh JP, Hoyt WF: Clinical neurophthalmology. 3rd ed, Williams and Wilkins, Baltimore, 1969, vol 2, 1654-1689
- Polyak S: The vertebrate visual system, University of Chicago Press, 1957, 735-747
- Cala LA, Mastaglia FL: Computerized axial tomography findings in patients with migrainous headaches. *Br Med J* II: 149-150, 1976
- Hungerford GD, Du Boulay GH, Zilkha KJ: Computerized axial tomography in patients with severe migraine: a preliminary report. *J Neurol Neurosurg Psychiatry* 39: 990-994, 1976
- Mathew NT: Computerized axial tomography in migraine. *In* Current Concepts in Migraine Research R. Greene (ed) Raven Press, New York, 1978, 63-71
- Jones T, Chesler DA, Ter Pogossian MM: The continuous inhalation of oxygen 15 for assessing regional oxygen extraction in the brain of man. *Br J Radiol* 49: 339-343, 1976
- Baron JC, Comar D, Boussier MG, Soussaline F, Crouzel C, Plummer D, Kellersohn C, Castaigne P: Etude tomographique chez l'homme, du débit sanguin et de la consommation d'oxygène du cerveau par inhalation continue d'oxygène 15. *Rev Neurol* 134: 545-556, 1978
- Baron JC, Comar D, Soussaline F, Todd-Prokopec A, Boussier MG, Castaigne P, Kellersohn C: Continuous ^{15}O inhalation technique: an attempt to quantify CBF, EO_2 and $CMRO_2$. *In* Cerebral Blood Flow and Metabolism, Gotoh F, Nagai H, Tazaki Y (eds) Munksgaard, Copenhagen. *Acta Neurol Scand* 60 (suppl 72) 194-195, 1979
- Baron JC, Comar D, Boussier MG, Plummer D, Loc'h C, Kellersohn C, Castaigne P: Patterns of CBF and oxygen extraction fraction (EO_2) in hemispheric infarcts: a tomographic study with the ^{15}O inhalation technique. *In* Cerebral Blood Flow and Metabolism, Gotoh F, Nagai H, Tazaki Y (eds), Munksgaard, Copenhagen, *Acta Neurol Scand*, 60 (suppl 72) 324-325, 1979
- Baron JC: unpublished data
- Dorfman LJ, Marshall WH, Enzmann DR: Cerebral infarction and migraine: clinical and radiologic correlations. *Neurology (Minneapolis)* 29: 317-322, 1979
- Ackerman RH, Subramanyam R, Alpert NM, Correia JA, Roberson GH, Brownell GL, Taveras JM: the $C^{15}O_2/H_2^{18}O$ static positron scintigram as a representation of blood-flow. *Stroke* 8: 10, 1977
- Ackerman RH, Alpert NM, Correia JA, Grotta JC, Fallick JT, Chang JY, Brownell GL, Taveras JM: Correlations of positron emission scans with TCT scans and clinical course. *In* Cerebral Blood Flow and Metabolism. Gotoh F, Nagai H, Tazaki Y (eds) Munksgaard, Copenhagen, *Acta Neurol Scand* 60, (suppl 72), 230-231, 1979
- Lenzi GL, Jones T, McKenzie CG, Buckingham PO, Clark JC, Moss S: Study of the regional cerebral metabolism and blood flow relationships in man using the method of continuously inhaling oxygen 15 and oxygen 15 labeled carbon dioxide. *J Neurol Neurosurg Psychiatry* 41: 1-10, 1978
- Lenzi GL, Jones T, McKenzie CG, Moss S: Non invasive regional study of chronic cerebrovascular disorders using the oxygen 15 inhalation technique. *J Neurol Neurosurg Psychiatry* 41: 11-17, 1978
- Pinching AJ, Travers RL, Hughes GRV, Jones T, Moss S: Oxygen brain scanning for detection of cerebral involvement in systemic lupus erythematosus. *Lancet* I: 898-900, 1978
- McKenzie CG, Lenzi GL, Jones T, Moss S: Radioactive oxygen ^{18}O studies in cerebral neoplasms. *J Roy Soc Med* 71: 417-425, 1978
- Lassen NA: The luxury perfusion syndrome and its possible relation to acute metabolic acidosis localised within the brain. *Lancet* 2: 1113-1115, 1966
- Waltz AG: Red venous blood: Occurrence and significance in ischemic and non-ischemic cerebral cortex. *J Neurosurg* 31: 141-147, 1969
- Norris JW, Hachinski VC, Cooper PW: Changes in cerebral blood flow during a migraine attack. *Br Med J* 3: 676-677, 1975
- Simard D, Paulson OB: Cerebral vasomotor paralysis during migraine attack. *Arch Neurol* 29: 207-209, 1973
- Skinhøj E: Hemodynamic studies with in the brain during migraine. *Arch Neurol* 26: 41-45, 1973
- Marshall J: Cerebral blood flow in migraine without headache. *Res Clin Stud Headache* 6: 1-5, 1978
- Davis KR, Ackerman RH, Kistler JP, Mohr JP: Computed tomography of cerebral infarction: hemorrhagic, contrast enhancement and time of appearance. *Comp Tomog* 1: 71-86, 1977
- Sundt TM, Waltz AG: Cerebral ischemia and reactive hyperemia. *Circ Res* 28: 426-433, 1971