

Aphasia With Nonhemorrhagic Lesions in the Basal Ganglia and Internal Capsule

Antonio R. Damasio, MD; Hanna Damasio, MD; Matthew Rizzo, MD; Nils Varney, PhD; Frank Gersh, PhD

• **Atypical aphasia syndromes were associated with circumscribed nonhemorrhagic infarctions of the anterior limb of the internal capsule and of the striatum, in the dominant hemisphere. None of the several cases could be classified in terms of the classic cortical aphasia syndromes, nor did they correspond to the description of aphasia produced by hemorrhage in the thalamus or putamen. Control subjects without aphasia had lesions in the same structures of the nondominant hemisphere, or they had comparably circumscribed damage, which was located lateral or caudal to the previously indicated locus. The findings raise the question of participation of the dominant striatum, and of the connectional systems that course in the anterior limb of the internal capsule, in language processing.**

(*Arch Neurol* 1982;39:15-20)

The most frequently encountered types of aphasia have been described in association with pathologic loci in the cerebral cortex. Despite some variability in the cortical and subcortical extension of the lesions, the association has been verified repeatedly, and the resulting anatomicoclinical correlation has been well established.^{1,2} Yet, many cases of aphasia deviate significantly from those classic types, and the manner in which the several language and motor defects combine render them virtually unclassifiable. Many such cases have

See also p 2.

been traced to hemorrhagic lesions in the thalamus or in the putamen, but the lack of autopsy studies and the nature of hemorrhagic lesions have not permitted the thorough investigation of the anatomic loci that are possibly correlated with those atypical aphasias. But now, computed tomography (CT) is permitting a more extensive, albeit preliminary, ap-

proach to the problem. We report several cases of atypical aphasia that appeared in relation to nonhemorrhagic lesions in the left basal ganglia (neostriatum) and in the left internal capsule (anterior limb), and contrast these cases with appropriate control cases.

PATIENTS AND METHODS

Six cases of atypical aphasia and five cases of speech disturbance without aphasia attracted our attention by virtue of the unusually located lesion observed in their CT scans: the lesion was located in the basal ganglia and internal capsule. The purpose of this study is to compare both the clinical characteristics and the CT scan correlates of the cases of atypical aphasia with control cases without aphasia. The six cases of atypical aphasia could not be classified according to the Boston Diagnostic Classification. Computed tomography showed lesions in the left basal ganglia and the left internal capsule in all cases. The five patients who did not have aphasia had dysarthria or dysprosody. Their CT scans showed lesions in approximately the same sites in the right hemisphere or in nearby but different sites of the left hemisphere.

The cases were studied in the Department of Neurology, University of Iowa College of Medicine, Iowa City, between 1976 and 1980. (Since the conclusion of this study, four additional cases have come to our attention with clinical characteristics and CT scan findings comparable with the ones reported here.) All patients had nonhemorrhagic infarctions. All patients received a comprehensive neuropsychologic examination, which included the Multilingual Aphasia Examination.³ Localization of lesions was obtained by plotting the pertinent CT scan cuts in templates of the appropriate cerebral sections.

REPORT OF CASES

CASE 1.—Aphasia and right hemiparesis developed suddenly in a 55-year-old right-handed man in June 1979. Speech was dysarthric, dysprosodic, effortful, and nonfluent with frequent semantic paraphasias. Articulation improved steadily and was almost normal by early 1980. Fluency improved too, and the patient became able to use four- to six-word sentences. Nevertheless, he was still nonfluent, and there were still occasional semantic paraphasias. Aural and reading comprehension were severely impaired at first but improved within a month and have been normal since September 1979. Writing with the left hand was intact. Visual naming of line

drawings was severely impaired, but performance was slightly better with three-dimensional objects. Verbal repetition was severely impaired initially but became normal within a month. Gestural praxis on verbal command was defective, while affect and nonverbal cognitive abilities were intact. Strength improved but at a slower pace than language. By April 1980, there was only moderate weakness of the right arm.

The presence of nonfluent speech, defective repetition, and a right hemiparesis suggested Broca's aphasia. Yet, the degree of defective aural comprehension and of semantic paraphasias brought to mind Wernicke's or transcortical sensory aphasia (but defective repetition would be compatible with the former and not the latter). The case did not fit any of the classic syndromes.

In the CT scan (Fig 1), there was an area of decreased density in the depth of the left hemisphere. It involved the white matter lateral to the body of the caudate nucleus (and in all likelihood part of the body itself) and extended, anteriorly and inferiorly, into the area lateral to the tip of the frontal horn of the lateral ventricle.

CASE 2.—Acute aphasia and right hemiparesis developed in a 53-year-old right-handed man in September 1979. Initially, there was fluent speech with normal articulation and semantic, phonemic, and neologistic paraphasias. Phonemic and neologistic paraphasias gradually disappeared. By April 1980, speech remained fluent with occasional semantic paraphasias and some word-finding difficulty. Aural and reading comprehension were severely defective at first but were almost normal eight months after onset. Verbal repetition was also severely impaired but improved within eight months. Writing was disturbed at the first examination, with profuse neologistic paraphasias. By April 1980, writing had improved, but spelling was poor (this had not been present before the disease). Praxis, attention, and memory were always intact. Weakness, which had been particularly severe in the upper extremity, improved but reduced swinging of the right arm remained. The patient's condition resembled Wernicke's aphasia and, for a while, as comprehension improved at a speedier rate than repetition, it suggested conduction aphasia. Yet, the presence of a severe hemiparesis is unusual in Wernicke's aphasia.

In the CT scan (Fig 2), there was an area of decreased density in the depth of the left hemisphere. It involved part of the anterior limb of the internal capsule and extended into the white matter lateral to

Accepted for publication April 20, 1981.

From the Department of Neurology (Division of Behavioral Neurology), University of Iowa College of Medicine, Iowa City.

Reprint requests to Department of Neurology, University of Iowa Hospitals and Clinics, Iowa City, IA 52242 (Dr A. R. Damasio).

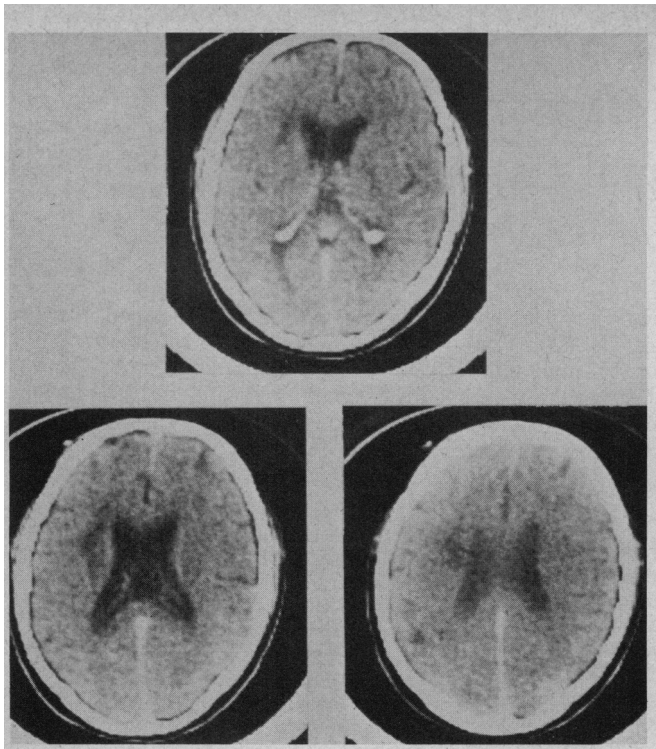


Fig 1.—Computed tomographic scan (case 1) shows area of decreased density in depth of left hemisphere.

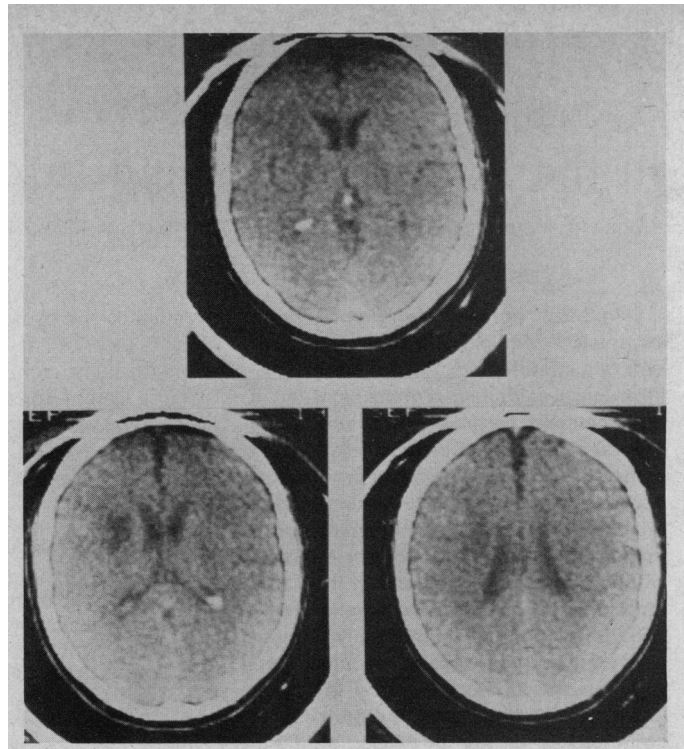


Fig 2.—Computed tomographic scan (case 2) shows area of decreased density in depth of left hemisphere.

the body of the caudate nucleus. There was involvement of the putamen and, to some extent, of the head of the caudate nucleus. In comparison with case 1, the lesion appeared to involve a lesser portion of the caudate nucleus and to extend more anteriorly in the capsule and frontal white matter. Conceivably, small anatomic differences might account for the major clinical feature that distinguishes these two cases: nonfluent speech in case 1 and fluent speech in case 2.

CASE 3.—Acute aphasia and paralysis of the right upper extremity and right side of the face developed in a 63-year-old right-handed man in March 1980. He became severely hoarse and spoke in a whisper. Speech was dysarthric and nonfluent with frequent pauses for word finding with circumlocutions. There were occasional semantic paraphasias, but the speech did not seem agrammatic. Aural and reading comprehension were normal and so was repetition. Writing was impaired with semantic paraphasias. Visual naming of drawings and objects was normal. Gestural and buccofacial praxes to verbal command were normal. Affect and nonverbal cognitive function were intact. Three months later, there was some improvement in word finding with less semantic paraphasias, but there was persistent dysarthria and hoarseness.

Nonfluent speech accompanied by right hemiparesis suggests Broca's aphasia. However, this patient's ability to repeat words was intact. Hoarseness, hypophonia, and severe dysarthria would be unusual in Broca's or transcortical motor aphasia. No classic syndrome fitted this patient's condition.

The CT scan (Fig 3) showed an area of decreased density in the depth of the left hemisphere. It involved most of the anterior limb of the internal capsule and the white matter lateral to the body of the caudate nucleus and of the head and body of the caudate nucleus. There was some involvement of the anterior and superior aspects of the putamen. The area of increased density in the anterior and superior aspects of the putamen corresponded to gray matter enhancement caused by injection of contrast material. In comparison with case 2, it seems that the involvement of the capsule was more extensive, while that of the striatum was possibly less.

CASE 4.—Acute aphasia and right hemiparesis developed in a 63-year-old right-handed woman in October 1979. The arm was completely paralyzed and flaccid. Articulation was defective, but prosody appeared normal. Speech was nonfluent with profuse phonemic paraphasias; yet, the patient spoke spontaneously and was obviously intent on communicating. Aural and reading comprehension were defective. Repetition was severely defective. The patient was unable to write. There seemed to be neglect of the right hemisphere. Yet, gestural praxis with the left hand was preserved. She was able to hum melodies in tune by following the examiner. No improvement was noted in a nursing home where the patient died six months later. An autopsy was not performed.

The patient's speech resembled that of early Broca's aphasia. Yet, the defect of comprehension and the profusion of paraphasias recalled a severe fluent aphasia. The degree of right-sided paralysis was

typical of neither and was of the kind most frequently seen in severe global aphasia, but the characteristics of speech in such cases do not resemble those of this patient.

The CT scan (Fig 4) showed a large area of decreased density in the depth of the left hemisphere. It involved the head and the anterior portion of the body of the caudate nucleus, all of the anterior limb of the internal capsule and its genu, white matter lateral to the body of the caudate nucleus, and a large amount of the anterior and superior aspects of the putamen.

CASE 5.—A 34-year-old right-handed man experienced the sudden onset of right hemiplegia and aphasia in 1976. Four years later, severe paralysis of the right upper extremity persisted, and there was mild weakness of the right lower extremity and right side of the face. Initially, there was nonfluent speech with dysarthria and both phonemic and semantic paraphasias. Gradually, fluency improved, but there was still some word-finding difficulty, both subjectively and objectively. Aural comprehension initially had been impaired and currently was normal. Yet, the patient reported serious difficulties in comprehending multiple conversations or conversations on the telephone. Background noise and accents, eg, foreign and Southern, to which he was unaccustomed, impaired his comprehension (the patient was a native English speaker and had no such difficulty before his illness). Repetition of sentences had been severely impaired but was now normal. Writing had been severely impaired with both phonemic and semantic paraphasias. Currently, there were occasional spelling mistakes that the patient

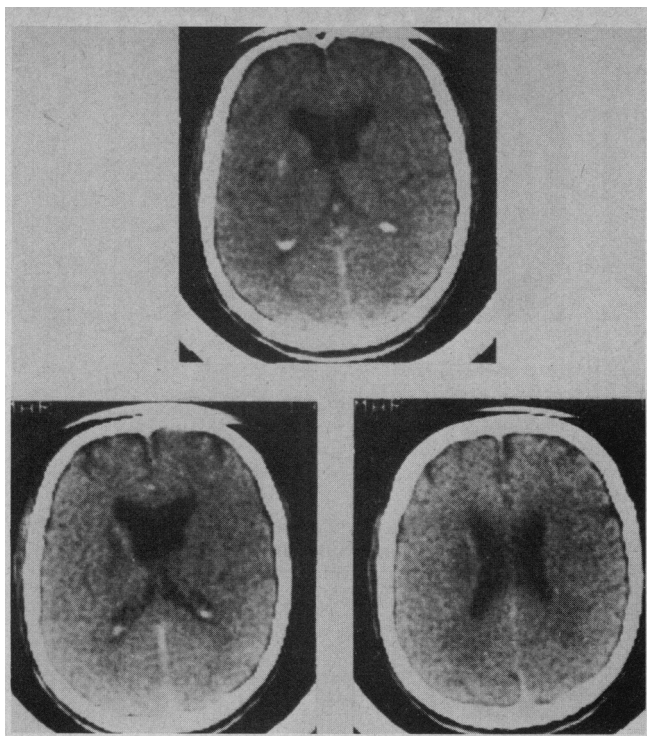


Fig 3.—Computed tomographic scan (case 3) shows area of decreased density in depth of left hemisphere.

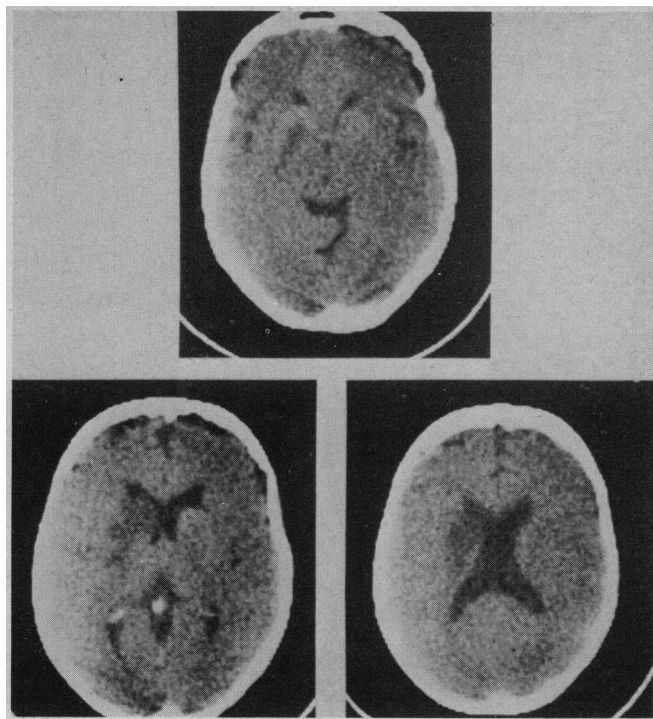
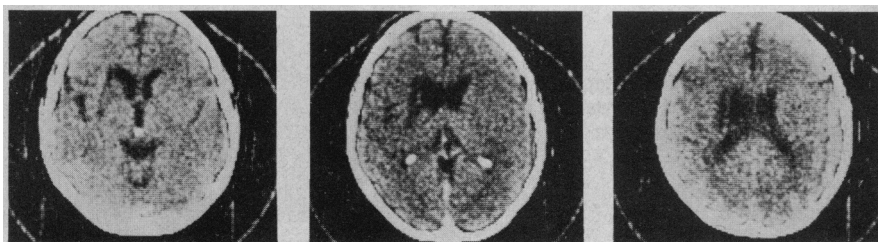

Fig 4.—Computed tomographic scan (case 4) shows large area of decreased density in depth of left hemisphere.

Fig 5.—Computed tomographic scan (case 5) shows area of decreased density in depth of left hemisphere.



did not make before his disease. Praxis, attention, and general memory function were always intact. The problems of classification of this syndrome were similar to those described for patient 1.

The CT scan (Fig 5) demonstrated an area of decreased density in the depth of the left hemisphere. It involved the head and the body of the caudate nucleus, most of the anterior limb of the internal capsule, as well as the white matter lateral to the body of the caudate nucleus, and the putamen. Both the left frontal horn and the left insular region were retracted toward the lesion, producing a small degree of hydrocephalus ex vacuo and enlargement of the Sylvian fissure.

CASE 6.—A 19-year-old right-handed man suffered an acute right hemiparesis and aphasia in December 1978, after trauma to the left carotid artery while he was wrestling. Speech was dysarthric and nonfluent with semantic and phonemic paraphasias. There was impaired aural and reading comprehension. Repetition was normal. Visual naming was defective with frequent paraphasic responses. There was remarkable improvement of all aspects of language, but speech remained dysarthric and

nonfluent, with word-finding difficulties. Hemiparesis improved rapidly. One year later, only mild facial weakness remained.

The presence of nonfluent speech, defective aural comprehension, and normal repetition suggested a complex transcortical aphasia of the type described as isolation of the speech area. However, the high level of nonlinguistic cognitive behavior was not compatible with that diagnosis, and the dysarthria and the extensive right hemiparesis are not common with border-zone infarcts. One year after onset, the residual disability in the patient's speech best resembled a recovered Broca's aphasia.

The CT scan showed an area of decreased density in the depth of the left hemisphere. It involved the most anterior portion of both the head of the caudate nucleus and the anterior limb of the internal capsule, as well as the anterior and superior aspects of the putamen.

CASE 7.—A 46-year-old right-handed man experienced right hemiparesis and dysarthria that started abruptly in December 1978. The upper extremity was severely involved and remained paralyzed three months after onset, while weakness of the

face and lower extremity had improved. Dysarthria persisted. Extensive testing disclosed all verbal and nonverbal performances to be normal.

The CT scan (Fig 6) showed a small area of increased density (caused by contrast enhancement) in the midportion of the body of the caudate nucleus, adjacent white matter in the corona radiata, and medial aspect of the putamen.

CASE 8.—A 55-year-old left-handed man suffered acute onset of speech disturbance and right hemiparesis in October 1979. Articulation was normal, but prosody was severely disturbed. There was abnormal prolongation of vowel sounds that, in effect, produced musical tones and conferred to speech an unusual melodic contour. This could be heard even on single-word utterances, and it was equally intense in all forms of speech production, including reading aloud and actual singing. Otherwise, speech was fluent and without paraphasias. Aural comprehension reading, repetition, and writing were entirely normal.

The CT scan (Fig 7) demonstrated a round area of decreased density that involved the anterior and lateral aspects of

Fig 6.—Computed tomographic scan (case 7) shows small area of increased density.

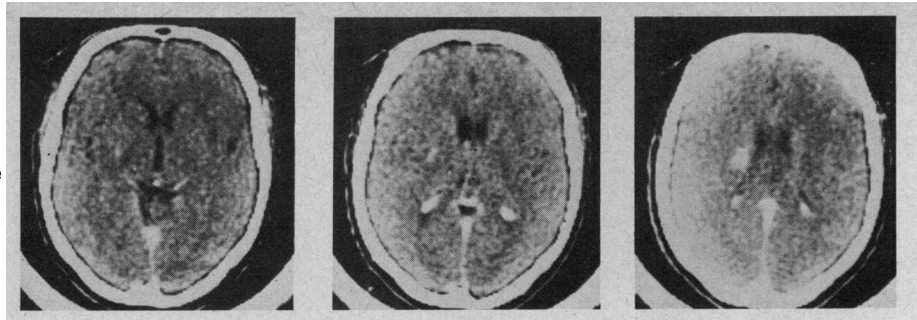


Fig 7.—Computed tomographic scan (case 8) shows round area of decreased density involving anterior and lateral aspects of left putamen.

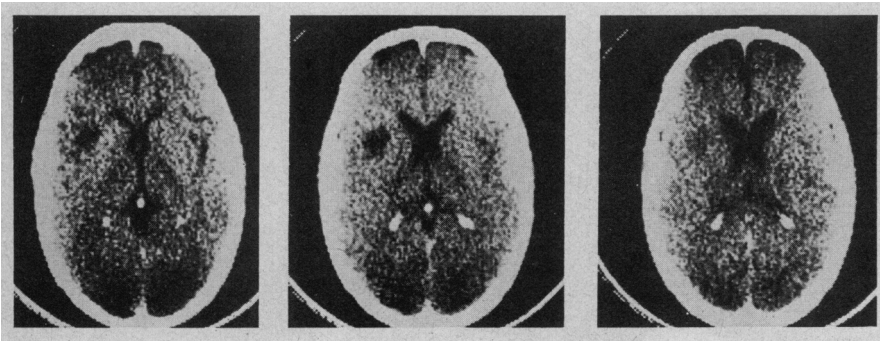
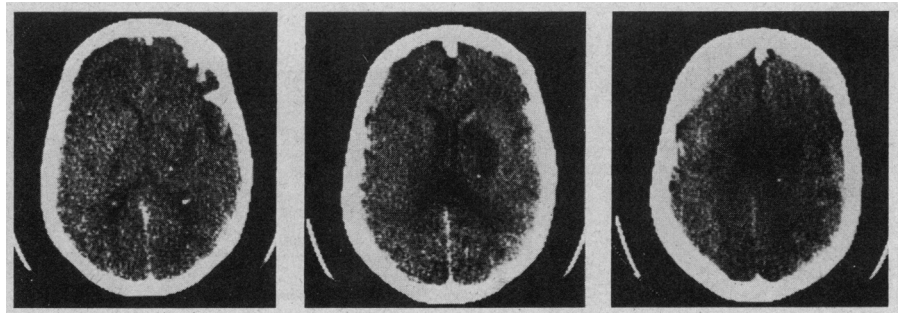


Fig 8.—Computed tomographic scan (case 10) shows area of decreased density in depth of right hemisphere.



the left putamen.

CASE 9.—Left hemiparesis and a mild confusional syndrome developed suddenly in a 24-year-old right-handed woman in July 1976. Confusion cleared, and speech, though fluent, was poorly articulated. Language was otherwise normal, and extensive testing produced no evidence of aphasia. The paresis improved rapidly, and in October 1976, only mild flatness of the left side of the face remained. Articulation had improved as well, although it had not returned to normal.

The CT scan (Fig 8) showed a large area of decreased density in the depth of the right hemisphere. It involved the head of the caudate nucleus, most of the anterior limb of the internal capsule, and the anterior and superior aspects of the putamen.

CASE 10.—Mild confusion, speech disturbance, and left hemiparesis developed suddenly in a 60-year-old right-handed woman in September 1978. Confusion cleared, but speech remained dysarthric and dysprosodic. Left hemiparesis persisted. Language was otherwise normal, and extensive testing showed no evidence of aphasia. There was neglect of the left hemisphere that cleared in two weeks.

The CT scan (Fig 9) disclosed an oval-shaped area of decreased density in the depth of the right hemisphere that involved a small portion of the head and body of the caudate nucleus, the putamen, the anterior limb of the internal capsule, and a fraction of the posterior limb, sparing the genu.

CASE 11.—An 82-year-old right-handed man suddenly became mute with left hemiparesis in July 1980. As the patient regained the ability to speak, on the second day, dysarthria was noted. Language was entirely normal. There was neglect of the left hemisphere.

The CT scan showed a large area of decreased density in the depth of the right hemisphere that involved the head and body of the caudate nucleus, the anterior limb of the internal capsule, the white matter lateral to the body of the caudate nucleus, and the putamen.

RESULTS

Nature of Lesions

On the basis of clinical characteristics and CT scan appearance, all lesions were produced by nonhemor-

rhagic deep infarction. Considering the maximal vertical and horizontal diameters of each lesion, it seems that, in all but two cases (cases 7 and 8), the lesions were too large to be classified as lacunar. Interestingly, patients 7 and 8 did not have aphasia. Also of interest is the fact that only two patients had a history of systemic hypertension (patients 1 and 7.)

Localization of Lesions

In all but two cases, the lesion consistently involved three structures: (1) the anterior limb of the internal capsule, (2) the head of the caudate nucleus, and (3) the putamen (Fig 10). In some of the cases, most of the anterior limb of the internal capsule and the superior aspect of the head of the caudate were involved (cases 4 and 5), while in other cases, the compromise was more limited (cases 1 through 3 and 6). The involvement of the putamen was almost always limited to its anterior and superior

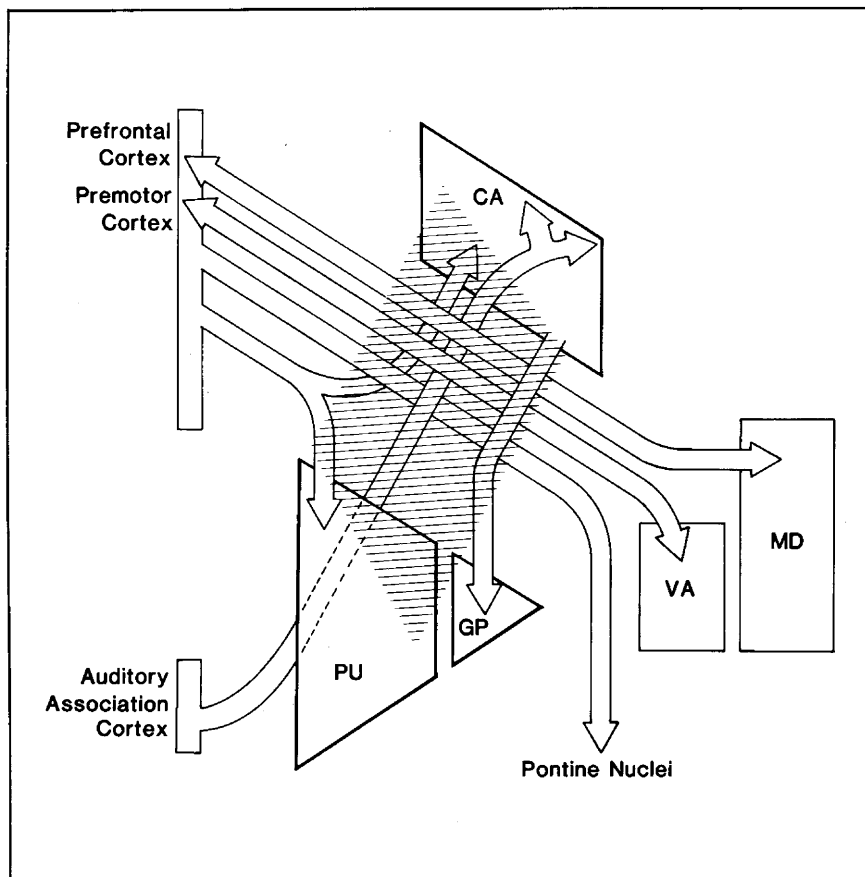


Fig 9.—Major pathways traveling in anterior limb of internal capsule. CA indicates caudate nucleus; PU, putamen; GP, globus pallidus; MD, medialis dorsalis; and VA, ventralis anterior.

aspects. The pallidum did not seem to be involved. The posterior limb of the capsule was involved in only one of the right-hemisphere cases without aphasia. Judging from the affected area, these lesions fall in the territory of the lateral lenticulostriate branches of the middle cerebral artery, thereby sparing the usual territory of the medial lenticulostriate artery, eg, the pallidum, as well as the territory of Heubner's artery, eg, the lower aspect of the head of the caudate nucleus and its junction with the putamen.

Cases 7 and 8 were exceptional in relation to the size of the lesions. The lesion in case 7 failed to involve both the anterior limb of the capsule and the head of the caudate nucleus. However, fibers in the corona radiata, en route to the genu and posterior limb of the capsule, were most certainly involved along with a small portion of the body of the caudate nucleus and of the putamen. As noted previously, this was in all likelihood a lacunar infarction that produced hemiparesis and dysarthria. The lesion in case 8 was predominantly in the putamen. The fact that the patient was left handed limits the significance of the interest-

ing syndrome of dysprosody without aphasia, which resulted from this lesion.

Aphasias

Given the small number of cases, it does not seem prudent to constitute different syndromes on the basis of the clinical variation exhibited in this sample. This is not to deny that there may be indeed different syndromes or that a small anatomic deviation could not be responsible for such differences. But our data do not allow those correlations.

On the other hand, the cases did share some of the following distinguishing features: (1) Dysarthria occurred in most cases, independently of the degree of fluency and often accompanied by dysprosody. (2) Hemiparesis occurred in all cases. (3) Gestural praxis on verbal command was intact in most cases. (4) Recovery of aphasic symptoms tended to occur rapidly and preceded recovery of motor disturbances.

The unusual clustering of symptoms and the pattern of recovery precluded categorization into the classic aphasia syndromes. In general, the cases more

nearly resembled those described in thalamic and putaminal hemorrhage, in itself, a rather heterogeneous group; however, there were substantial differences since these patients did not exhibit significant disturbances of attention or memory.

Conclusion

Our results can be summarized as follows.

1. Right-handed patients with left-sided lesions that involve the anterior limb of the capsule, the head of the caudate, and the putamen had aphasia, right hemiparesis, and, often, dysarthria and dysprosody.

2. A right-handed patient with a lesion that failed to involve the previously mentioned areas but did compromise more posterior aspects of the internal capsule, corona radiata, caudate nucleus, and putamen had dysarthria and right hemiparesis but no aphasia.

3. Right-handed patients with right-hemisphere lesions, involving the anterior limb of the capsule, head of the caudate, and putamen had dysarthria and left hemiparesis but no aphasia.

COMMENT

It is well accepted that subcortical lesions can produce aphasia. Thus, at least some cases of conduction and transcortical aphasia are associated with purely white-matter lesions,⁴⁻⁶ while atypical aphasic disturbances have been noted after hemorrhage in the thalamus^{7,8} or in the putamen.^{9,10} The pathologic nature of the latter (substantial size of most hemorrhages, mass effect, overriding of nuclear gray masses, and surrounding white matter) renders the interpretation of the anatomicoclinical correlations problematic. Most such patients have important disturbances of attention and memory in addition to aphasia, which raises the question whether the linguistic disorder is primary or secondary to a nonverbal cognitive defect.

The cases that we have reported in this article help answer some of those questions, given the limited size and the nonhemorrhagic nature of the lesions. These cases suggest that there is a powerful association between aphasia and a well-circumscribed anatomic region: the anterior limb of the internal capsule and both the head of the caudate nucleus and the anterior aspect of the putamen. Lesions anterior to that locus, located in the depth of frontal white matter, outside the striatum, and rostral to the anterior

limb of the capsule, produce transcortical motor aphasia (A. Galaburda, MD, oral and written communications, October 1980 and April 1981).^{5,11} Lesions that are located caudally to that crucial locus, eg, in the genu and posterior limb of the capsule, and in the corona radiata immediately above those structures, produce motor disturbances (affecting speech and contralateral movement) but not aphasia. Lesions in a symmetric locus of the right hemisphere produce motor disturbances (dysarthria and left hemiparesis) but not aphasia. Some support for these preliminary findings comes from a study by Naeser and associates (see p 2) who have reported cases of atypical aphasia in relation to infarcts of the basal ganglia and capsule. Although several clinical and anatomic features may be comparable, the lesions described by Naeser et al appear to be much larger than the lesions found in our study. In some cases, the lesions extend into the temporal isthmus, well outside the deep cerebral region that we are considering here, and closer to the subcortical white matter, which has been implicated classically in aphasia.

In all of the cases in our study, the lesion was astride a major white-matter funnel (anterior limb of the capsule) and major gray-matter nuclei (caudate nucleus and putamen). In all cases, then, the interpretation of the several manifestations can be proposed by reference to (1) disconnection of important fiber pathways, (2) damage to gray-matter neuronal operators, or (3) both. The interpretation should take into account modern concepts of structure and function of both the anterior limb of the capsule and the striatum.

The striatum is no longer regarded as a pure motor structure that mediates a collateral aspect of the generation of movement. Rather, the striatum receives input from all the major sensory, suprasensory (multimodal), and limbic areas of the cerebral cortex and is a high-level integrative organ. Input to the striatum is highly patterned. For instance, areas of the cerebral cortex that are reciprocally connected by corticocortical pathways project, in part, to the same region of the caudate nucleus¹²; however, projections from sensory areas approach the caudate along its entire length, and most enter the nucleus at its head.¹² The caudate nucleus and putamen receive different preponderant projections, visual and auditory mainly to the former, sensorimotor to the latter.¹³⁻¹⁵ Practically all of the

striatal output is aimed at the pallidum in which output is to the "motor thalamus," which in turn projects preferentially to the premotor, Rolandic, and somatosensory cortices, thereby closing one of the two reentrant motor circuits.^{16,17} The striatum is clearly a principal programmer of movement in relation to ongoing multimodal perception and imagery and, in all likelihood, also plays a role in the organization of perception.¹⁸⁻²⁰ Damage to the striatum produces dysprosody and conceivably could produce dysarthria. But it could also disrupt language decoding and encoding, disturbing aural comprehension and giving rise to paraphasias.

On the other hand, the anterior limb of the capsule carries, among others, the following major fiber systems: (1) projections from the frontal cortex to the pons,²¹ (2) projections from the auditory cortex to the head of the caudate nucleus,²² (3) projections from the motor thalamus to the frontal premotor cortex,²³ (4) projections from the head of the caudate nucleus toward the pallidum, and (5) projections from the mediodorsal thalamus to the prefrontal cortex²³ (Fig 10). Damage to the first four systems could contribute to the disturbances that were seen in the patients in our study, in different ways: by producing dysarthria (systems 1, 3, and 4), and by producing paraphasias and aural comprehension defects (system 2). The final clarification of which component results from white-matter disconnection or gray-matter damage depends on the ultimate but unlikely discovery of a lesion exclusive to the anterior limb of the capsule, to the head of the caudate nucleus, or to the putamen.

The interpretation of our findings rests on the assumption that the lesions were confined to the abnormal areas that were seen in CT scans and that there were no concomitant lesions in cortical areas. In the absence of pathologic verification, such an assumption depended on critical judgment of the images and consideration of the nature of lesions. The quality of the images was satisfactory. The lesions were all located deeply, far away from cortex, and there were no suspect cortical areas. The possibility of cortical lesions smaller than the resolution of the CT scanner is undeniable. Yet, it is unlikely that such a small lesion could produce the type and severity of aphasic symptoms described in the present study. Be that as it may, we offer our preliminary findings in the

hope that, by calling attention to the problem, the necessary pathologic confirmation will soon take place.

References

- Goodglass H, Kaplan E: *The Assessment of Aphasia and Related Disorders*. Philadelphia, Lea & Febiger, 1972.
- Benson DF, Geschwind N: The aphasias and related disorders, in Baker AB, Baker LH (eds): *Clinical Neurology*. New York, Harper & Row Publishers Inc, 1974, vol 1, chap 8.
- Benton AL: *Multilingual Aphasia Examination*. Iowa City, Department of Neurology, University of Iowa, 1976.
- Geschwind N: Disconnection syndromes in animals and man. *Brain* 1965;88:237-294, 585-644.
- Damasio H, Damasio A, Hamsher K, et al: CT scan correlates of aphasia and allied disorders. *Neurology* 1979;29:572.
- Damasio H, Damasio AR: The anatomical basis of conduction aphasia. *Brain* 1980;103:337-350.
- Fisher CM: The pathological and clinical aspects of thalamic hemorrhage. *Trans Am Neurol Assoc* 1959;84:56-59.
- Mohr JP, Watters WC, Duncan GW: Thalamic hemorrhage and aphasia. *Brain Lang* 1975;2:3-17.
- Hier DB, Davis KR, Richardson EP, et al: Hypertensive putaminal hemorrhage. *Ann Neurol* 1977;1:152-159.
- Alexander MP, Lo Verme SR: Aphasia after left hemispheric intracerebral hemorrhage. *Neurology* 1980;30:1193-1202.
- Damasio AR, Damasio H: Anatomical correlates of the aphasias. Read before the World Federation of Neurology, Research Group of Aphasia Meeting, Boston, Oct 1, 1980.
- Yeterian EH, Van Hoesen GW: Corticostriate projections in the rhesus monkey: The organization of certain cortico-caudate connections. *Brain Res* 1978;139:43-63.
- Jones EG, Coulter JD, Burton H, et al: Cells of origin and terminal distribution of corticostriatal fibers arising in the sensory-motor cortex of monkeys. *J Comp Neurol* 1977;173:53-80.
- Kemp JM, Powell TPS: The cortico-striate projection in the monkey. *Brain* 1970;93:525-546.
- Künzle H: Bilateral projections from precentral motor cortex to the putamen and other parts of the basal ganglia: An autoradiographic study in *Macaca fascicularis*. *Brain Res* 1975;88:195-209.
- Nauta WJH, Mehler WR: Projections of lentiform nucleus in the monkey. *Brain Res* 1966;1:3-42.
- Kim R, NaKano K, Jayaraman A, et al: Projections of globus pallidus and adjacent structures: An autoradiographic study in the monkey. *J Comp Neurol* 1976;169:263-290.
- Purpura DP: Physiological organization of the basal ganglia, in Yahr MD (ed): *The Basal Ganglia*. New York, Raven Press, 1976.
- Teuber HL: Complex functions of basal ganglia, in Yahr MD (ed): *The Basal Ganglia*. New York, Raven Press, 1976.
- Hassler R: Striatal control of locomotion, intentional actions and of integrative and perceptive activity. *J Neurol Sci* 1978;36:187-224.
- Brodal P: The corticopontine projection in the rhesus monkey: Organization and principles of organization. *Brain* 1978;101:251-283.
- Van Hoesen GW, Yeterian EH, Lavizzo-Mourey R: Widespread cortico-striate projections from temporal cortex of the rhesus monkey. *J Comp Neurol* 1981;199:205-219.
- Kienet J, Kuypers HGJM: Organization of thalamocortical connexions to the frontal lobe in the rhesus monkey. *Exp Brain Res* 1977;29:299-322.