

# Disorientation for Place

C. Miller Fisher, MD

• The study of a patient with remarkable disorientation for place associated with an acute nondominant parietooccipital lesion raised the general question of a relationship between disorientation for place and topographical disorientation. The literature does not address this matter. The clinical findings of one case in particular are presented here in detail. Another six patients had been seen with a disproportionate disorientation for place; in each there was an acute insult to the nondominant hemisphere. Based on these cases, there is preliminary evidence of a possible relationship.

(*Arch Neurol* 1982;39:33-36)

This study was occasioned by the finding of an unusually severe disorientation for place in a patient with acute infarction of the parietooccipital region of the right cerebral hemisphere. In addition to being geographically dislocated to distant places, the patient exhibited several of the visuospatial disorders described with lesions at the involved site, ie, constructional apraxia, topographical disorientation, agnosia for the left half of space, oculomotor symptoms, etc. The classic accounts of this syndrome, however, make no reference to orientation for place. Indeed, the literature surprisingly contains only a few references to the topic, and those are usually in relationship to head injury<sup>1</sup> or senility.<sup>2</sup> Only one article mentioned disturbances of orientation for place in association with focal brain lesions, that of Weinstein and Kahn,<sup>3</sup> who

studied anosognosia and denial of illness in 22 cases of brain tumor. There appears to be a discrepancy between the prominence that orientation for place occupies in the standard neurologic examination and the attention it has been accorded by investigators. The present brief excursion into the field is merely introductory and serves mainly to draw attention to the possible relationship of disorientation for place to acute nondominant parietal lobe lesions.

For purposes of clarity, the specific term "orientation for place" will be used here, and the broader generic term "spatial orientation" avoided because of its varied connotations.

## REPORT OF CASES

### Index Case

**CASE 1.**—An architect, aged 72 years, mentally sound, curator of a small museum, was admitted to Massachusetts General Hospital, Boston, because of left-sided weakness, including his face, arm, and leg, and dysarthria, which had developed in a period of one day. There may have been some fluctuation in the severity of signs in the first few days, but thereafter the picture was relatively stable for five weeks. Eleven years before, the patient had had transient ischemic attacks associated with stenosis of the intracranial portion of the right internal carotid artery and thereafter received warfarin sodium therapy. Myocardial infarction had occurred nine years before the current admission, mid-thigh amputation of the right leg 1½ years previously, and transient spells of right-sided homonymous hemianopsia one year previously. A left internal carotid endarterectomy had been performed 1½ years previously. Anticoagulant therapy had been discontinued ten days before the onset of the present stroke, and was reinstituted in half the usual dosage five days before the onset of the stroke.

On examination one week after the onset of the stroke, the patient was awake,

answered questions, and obeyed commands with a moderate degree of psychomotor retardation (abulia). Also present were moderate left-sided facial weakness, slight dysarthria, and very slight weakness of the left arm and leg. Sensation on the left side was normal for pin and touch stimulation, joint position, vibration, and identification of objects. The right side functioned normally. Carotid angiography showed occlusion of the previously stenotic right internal carotid artery. A computed tomographic (CT) scan showed a 3-cm low-density lesion (infarct) in the watershed area of the inferior right parietooccipital region (Fig 1).

The data concerning the patient's orientation for place during the first five weeks in the hospital will be presented at this point, while the details of the pertinent higher cortical functions that did not change materially over the period will be presented later.

**Responses Showing Disorientation.**—The patient always recognized and correctly addressed his family, physicians, and nurses. When asked what place he was in, he usually mentioned Massachusetts General Hospital or MGH, often referring to the "old MGH," "MGH East" or "a branch of the MGH." When asked "where" or "whereabouts," the answers changed from day to day or every few days. In response to, "What place is this," he gave the following answers. On hospital day 2: "My assumption is that it relates to the huge hospital, outside of London [England] or the London suburbs." What hospital? "It eludes me at the moment." Day 3: "It's a far extension of MGH in California." Day 4: "I know what you tell me but it seems to me I'm in Paris. . . . When there is an association of doctors they need not all be in one place." Day 5: The patient asked his wife, "Do you think the doctor will come to Arizona to see me?" Day 7: "It is a luxury hotel, somewhere in the Far East, probably Tokyo." Day 8: "It's a hotel in China or . . . it could be Japan." Day 9, "Concord, Massachusetts [15 miles from Boston]." Day 13, when asked where he was: "I don't know." Is it a hospital? "I assume it is." Which hospital do I practice in? "MGH,

Accepted for publication April 15, 1981.

From the Neurology Service, Massachusetts General Hospital, and the Department of Neurology, Harvard Medical School, Boston.

Reprint requests to Neurology Service, Massachusetts General Hospital, Fruit Street, Boston, MA 02114 (Dr Fisher).

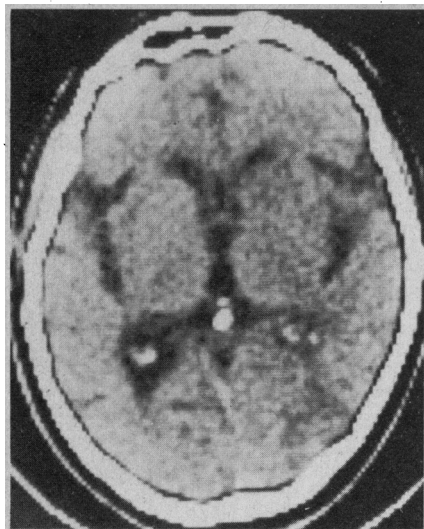


Fig 1.—Computed tomographic scan showing right parietooccipital low-density lesion (patient 1).




Fig 2.—Drawing of clock on day 4 (patient 1).

Boston." Therefore, where are we? "It's not a sequitur." When asked further he said, "I'd say somewhere in New England." Day 15: "MGH in Chicago." Day 16: "MGH East.... When I say east I'm thinking more of Baghdad rather than east Boston." How could I come to Baghdad to see you? "I may be confused by the music I hear [television in a nearby room]." Day 17: "MGH generally in the vicinity of Africa." Day 19: "The Deaconess Hospital [Boston hospital where he had been a patient in the past].... It's the same as the MGH." Is it Boston? "Are you trying to be difficult?... It's more Africa, East Timbuktu." Day 26: "It's connected with MGH but that doesn't give the location, I'd say west of Denver, Colorado." Day 28: "I'd say old MGH, facing south to the White Building." Day 29: "Framingham [25 miles from Boston]." Day 31: "It's old MGH on the Cape near Falmouth [Cape Cod, 60 miles away]." Day 33: "MGH on Fruit Street, Boston [correct]." Thereafter the patient was

usually correctly oriented. During the disorientation period his family came to see him each day. When they left for home each evening, he asked where they were going, and said, "Will you be able to find me in the morning?" Once when they were leaving he said, "Are you going upstairs now?" When he said he was in Africa, it was cold outdoors.

**Other Neurologic Findings.**—In the days during which the preceding answers were given, the patient was afebrile, alert, calm, cooperative, and free of agitation. Spontaneity was diminished, and he replied with a delay of 10 s to 60 s; however, before his stroke he normally spoke very deliberately and his answers were not prompt. He was in bed most of the time to promote blood flow to the brain. He received phenytoin sodium for seizures, and the blood level did not exceed 8 mg/dL. There were no hallucinations or spontaneous confused behavior except as described. He usually gave the correct month and year but not the exact date. He recalled the events of the day and what he had had to eat. He was interested in family matters and proffered sound advice. On the telephone he spoke volubly, including discussion of the content of a publication he was writing with a colleague. He made appropriate humorous comments.

There was no dysphasia in conversation. There was a severe left homonymous hemianopsia to finger movement. Pursuit eye movements were full without nystagmus. Optokinetic nystagmus was absent with targets moving to the right. When asked specifically, he was unaware of the visual-field defect. He in no way ignored his left arm and leg, and he consulted his wristwatch on that side. He was able to tie a knot in his pajama sash. He put on his glasses correctly. In reading a newspaper he noted only the right-hand 5 cm of a 35-cm headline. He could read small print in a column but omitted the left-hand two thirds of lines and was unable to follow the order of words in lines of print, precluding any comprehension of content. He ignored the left-hand side of pictures. He ignored food on the left side of his tray. He was not interested in television. He placed the midpoint of a 12-cm line far to the right. He copied a diamond balanced on a square but nothing more complicated. His signature was executed normally. A drawing of the plan of the first floor of his home was laboriously pursued for ten minutes, at which time it was found to consist of three disconnected walls and two large doors. Yet, on the telephone he gave his daughter complicated directions to find some documents in one of the cabinets in his home. He could not read the time on a clock. Drawing a clock from memory was reasonably good on the right side but greatly disordered on the left (Fig 2). He was unable to place two pieces of bread together to make a sandwich. His drawing of a bicycle was basically correct but spatially bizarre. His drawing of a man showed a head, nose, and two legs. He could not visually enumerate horizontal or vertical lines. He could not trace out a line with two

loops. He gave his correct home address. He was unable to trace his usual route from home to his work, a distance of six miles. He could not trace a familiar route on a map. He gave the compass direction of various cities from Chicago. He correctly identified objects, faces, colors, and fingers. He quickly spelled Boston in reverse. He interpreted the proverb, "People who live in glass houses," etc, as "Don't do anything to hurt your environment."

The answers to the question as to his whereabouts were given after deliberating for 15 s to two minutes. He never said he did not know or was not sure. He had no insight into his errors. He failed to use clues from events and circumstances around him. At times he requested that a map be brought to him. He was more or less passive rather than critical and observant. He was unaware that he saw only one seventh of a line and that intelligent reading was precluded. His greatly impaired performance in drawing and copying drew no comment. The great conflict between the realities of daily events and his surroundings and his own impressions of his location was beyond the preserved part of his intellect. Yet, he did not act on the basis of his mistaken locale.

**Comment.**—In this patient, disturbance of orientation for place seemed out of proportion to the rest of his behavior, which was relatively rational in many ways. The dislocation of his whereabouts was fanciful to a degree that suggested delirium or the amnesic syndrome, but neither of these states pertained. He usually placed himself in a relatively general region—near London, west of Denver, in the Orient, etc—rather than at a particular site. The patient had traveled in Europe but not in Africa, the Near East, or the Orient.

On day 33, when he first became correctly oriented, various facets of the right parietooccipital syndrome had also greatly improved. For example, on that day he read six sevenths of a headline, saw finger movement in the left visual field, and was less abulic. Because of the parallel change it is tempting to suggest a relationship between the temporary disorientation for place and the visuospatial defects associated with a nondominant parietooccipital lesion. The patient clearly exhibited moderate psychomotor retardation, and the possibility that the disorientation arose primarily from or was modified by a nonvisualized lesion in the left anterior cerebral territory must be entertained. However, disorientation for place does not regularly accompany psychomotor retardation or abulia. The latent cerebral changes of advancing age might also have been a contributing factor.

#### Additional Cases

This report is based chiefly on the findings from patient 1, but a search of my records disclosed the following six cases, which, although inadequately documented, illustrate the same phenomenon.

**CASE 2.**—A 66-year-old man experienced the sudden development of left-sided sen-

sensorimotor hemiplegia as a result of thrombosis of the right internal carotid artery. Examination showed a severe sensory loss, left-sided homonymous hemianopsia, left-sided spatial neglect (he omitted the left six sevenths of a newspaper headline), dressing apraxia, constructional apraxia, anosognosia, optical disorientation, psychomotor retardation, agitation, and fluctuating confusion. He gave the date within one year. At a time when he knew the correct year he gave his location variously as St James, Watertown, a public building in Maine, Charles River, James River, a mid-Bostonian city, Fishhill, the University of Pennsylvania Hospital, Philadelphia, Yale-New Haven, Conn, and others. In five weeks, orientation for place improved as the other abnormalities—constructional apraxia, spatial neglect, left homonymous hemianopsia and sensory deficit—also decreased.

**CASE 3.**—In a former military pilot, aged 44 years, a left-sided hemiplegia developed following surgical clipping of a ruptured right internal carotid-posterior communicating artery aneurysm ten days after the bleeding. On postoperative day 3 he moved the left limbs well, but remarked, "This place was a restaurant ten years ago but they have taken out the tables and turned it into the Massachusetts General Hospital." On postoperative day 5, when asked where he was, he said, "Out of the country, in Europe somewhere." Day 7: "Nuremberg—A/26, I'd say we are right at the German boundary—north-south. . . I can't tie this all together, the loose edges, I came down here when I was a prisoner of war in Germany, then back to the mainland. There I was, right there, the southern channel. . . That complex is still in my mind and the physical layout. . . We'll get the stitches out and get out of here." Later in the day when asked the place he said, "I know it's Boston, Massachusetts, but I feel I'm still at the German boundary." Day 8: "A [pause] recreation center, I guess." Day 10: "I've learned that I should say Boston, MGH." Day 11: "Was there some talk of my going to Japan? They allocated the gasoline to go there." On day 12 he was still intermittently confused. Recovery was ostensibly complete on day 22. During the postoperative period, the patient was conversant and knew that he had been vacationing in Maine and had had an operation. Disorientation for place was surprisingly out of proportion to the rest of his behavior. Unlike patient 1, he distinguished between feeling where he was and what he had been told.

**CASE 4.**—A man, aged 71 years, awakened confused one morning. The left side of his face sagged, his speech was slightly slurred, and there was a left-sided Babinski's sign. These signs disappeared in one week, and a vascular insult was suspected. Investigations, including angiography, CSF examination, and CT scan were normal. When asked where he was he said, "I don't know what building this is unless its legal name is MGH, your MGH." He looked out of the window at the nearby Charles River and said, "I don't know if I

ever knew of that as the estuary of the James or Potomac [rivers in Virginia]." He thought he was still wintering in Florida and said, "I have to decide when to go north." He gave the month, date, and year correctly. He recalled half of a ten-point story after 24 hours and eight days. His ability to draw and copy were greatly impaired. His condition improved in the following three months, but he continued to be geographically dislocated, imagining he was in a city 150 miles away, and remarked that the next-door neighbor had a little dog just like the one his neighbors at home had. He often referred to "a second place" or another city. At this time, performance on constructional tasks was within normal limits. The patient's condition gradually declined in the next five years, consistent with Alzheimer's disease. Disorientation for place, which at first paralleled constructional apraxia, was prominent at a time that he could give the correct date, that is, space and temporal orientation were dissociated.

**CASE 5.**—A man, aged 80 years, had an acute left-sided sensorimotor hemiplegia due to thrombotic occlusion of the right middle cerebral artery. Examination showed in addition a left-sided homonymous hemianopsia, anosognosia, autotopagnosia, psychomotor retardation (abulia), and a right grasp reflex. He lived for one year with little recovery. Usually he knew the month and was able to carry on a complex professional conversation that impressed visitors. Although he named the hospital (MGH), he did not know where he was and gave the following places at various times: Rochester, Dublin, Philadelphia, Bangor, Me (180 miles away), Australia, the Caribbean Sea, and Washington, DC. He described imaginary travels he thought he had taken while he was a bed patient.

**CASE 6.**—A 64-year-old woman suddenly experienced a severe headache and left-sided sensorimotor hemiplegia as the result of rupture of a right middle saccular aneurysm. Movement returned to the left side but a severe sensory deficit to pinprick, joint-position sense, and vibration, a left-sided homonymous hemianopsia, anosognosia, constructional apraxia, and left-sided spatial agnosia persisted. She omitted the left one sixth of a headline. She was correctly oriented for time, and her memory was excellent. She conversed normally. Although oriented for place, hospital room, and city and able to describe routes, the relation of the place in the hospital to her home was disturbed as judged by the following statements: "My kitchen is down the corridor although in my mind I know it can't be. . . The kitchen of my house is over that way," pointing to the door of her hospital room. Although she knew where she was, she invited her physician "to cocktails upstairs" or "to join [her] in the kitchen for a martini." She said, "There is ice cream in the refrigerator upstairs." When asked where she was she said, "In the Massachusetts General Hospital." When asked how her refrigerator could be upstairs she said, "It seems to me my kitchen is somewhere overhead of this

room." This disorientation improved greatly in five weeks, at which time the other parietooccipital deficits had also improved.

**CASE 7.**—A hypertensive woman, aged 62 years, had a severe left-sided sensorimotor hemiplegia in a period of 15 minutes. Vertical gaze was absent, the CSF was bloody, and a diagnosis of right thalamic hemorrhage was made. The blood pressure was 215/135 mm Hg. On day 20, when alert and conversant, she gave the place as the French Quarter and on the next day the Massachusetts Eye and Ear Infirmary. There was a persistent left-sided homonymous hemianopsia. Three months later, when otherwise fully recovered mentally (she was addressing Christmas greeting cards), she thought she was on the first floor of another building in the Department of Radiology, whereas she had been in the same room on the ninth floor for two months ("They say it's nine but it's really one"). She usually turned to the left instead of to the right and erroneously insisted that when she went for physiotherapy it was to still another floor. She had little sense of orientation and was unable to find her way around her hospital floor. She would be found in her wheelchair in places other than where she wanted to be. At the end of a year she was fully oriented.

## COMMENT

Pick,<sup>2</sup> in describing a case of senile dementia with seizures, noted that in the patient's mind events and institutions were duplicated, that is, there were two hospitals of the same name or two head physicians of the same name, a feature that he termed reduplicative paramnesia. He did not specifically mention disorientation for geographic place. Paterson and Zangwill<sup>1</sup> traced the recovery from disorientation for place in two cases of posttraumatic confusion. They identified several phases—double orientation, partial reorientation, the entertainment of incompatible propositions without awareness, verbal identification, spatial displacement, and reduplicative paramnesia. In both instances there was a severe memory deficit. An anatomic correlation was not made. Weinstein and Kahn<sup>3</sup> reported disorientation for place in 19 of 22 patients with tumors in various regions of the brain. A clinicoanatomic correlation was not attempted. They attributed the disorientation to denial of illness, a psychologic process. The same authors<sup>4,5</sup> reported somewhat the same patterns of disorientation as those described by Paterson and Zangwill.<sup>1</sup> Our concern here, however, is not with patterns of disorientation but with the possible cerebral localization of orientation, a subject not considered in the classic reports on spatial disorientation.<sup>6-11</sup>

If it is assumed that orientation for place has a specific anatomicophysiological substrate, it would be logical to suspect the nondominant parietooccipital cortical region, acute lesions of which are classically associated with disturbances of topographic orientation and routefinding. Hécaen<sup>12</sup> found that of 40 patients with a topographic disturbance, 29 had right-hemisphere lesions, eight had left-hemisphere lesions, and three had bilateral lesions. It seems reasonable that a close relationship should exist between an individual's faculty of finding his way and the ability to appreciate his geographic location. This hypothesis is supported not only by the main case (case 1) but the minor cases as well, in each of which the nondominant parietooccipital region or the nondominant hemisphere was involved. Evidence that it is the parietooccipital region rather than another part of the hemisphere that subserves orientation for place is provided by case 1, in which there was no sensorimotor hemiplegia, that is, only the posterior part of the hemisphere was involved. In three cases, disorientation for place paralleled the other deficits in higher cortical function. On the other hand, from personal experience, patients with left-sided sensorimotor hemiplegia in which the parietooccipital association area is spared do not show disorientation at least of the degree under consideration. The question of whether aphasia interferes with recognition of similar deficits in dominant lesions has never been settled. Cases of disorientation similar to those described here but associated with acute dominant lesions were not found in my records.

It would be of considerable interest if orientation for place were related fundamentally to function of a restricted focal area of the brain. Although variability in the details of disorientation would be expected according to variation in the location,

size, and acuteness of the pathologic process, a disorder seemingly as simple as this might lend itself to fruitful analysis, permitting further insights into the human orienting system.

An objection to localization of orientation for place exclusively in the nondominant parietooccipital region is the temporary nature of the disturbance, the tendency to natural recovery. Recovery could of course result from restoration of function in the damaged tissue. If, however, some other area of the cortex, possibly in the opposite hemisphere, assumed the disrupted function, disorientation would represent a transient, unstable state that lasts until reorganization of function has occurred. Three of the patients recovered in about five weeks, suggesting a common temporal factor. The present findings, if relevant, should apply in acute cerebral disorders.

A few further comments on patient 1 may be made. Orientation for place is usually given in terms of home, building or institution, city or town, street address, state, and country. It might be further narrowed to the floor or room number in the hospital. It will be recalled that patient 1 usually identified the institution often with a qualifying adjective suggesting reduplicative paramnesia, and the main error lay in identification of the geographic or territorial place. This added inquiry is often overlooked in clinical practice once the building is identified. By what means does an individual know his whereabouts? Introspection would indicate that sighted persons have an instantaneous recall of the visual and locomotor memories of their recent itinerary. It seems to be another dimension of disorientation, however, when a patient (case 1) imagines he is hundreds of miles or even continents away in places he has never visited. It was not merely a matter of misnaming, as the patient emphasized aspects of the false place

other than the name. His answers might be classified as confabulatory, but this does not add to our understanding. No explanation for the choice of the fanciful places in which he imagined himself is forthcoming. The degree of sophistication of the patient must be a factor. Contrary to the usual rules, he was not displaced to his hometown or to his home. The disturbance could not be attributed to a failure of general memory, for the patient recalled many of the details of his meals and of the events of the day. Disorientation for place exceeded temporal disorientation. Normally, information concerning one's dynamic ever-changing whereabouts is automatically and constantly pictured in one's mind, and without this there is an uneasy feeling of strangeness and bewilderment. Patient 1 had no such concern. It is remarkable that visual and other clues in the patient's hospital room were of no avail, that is, failure of orientation and the ability to recognize errors were mutually exclusive. Like a delusion, the images portrayed in the patient's mind by neuronal activity constituted reality.

It is conceivable that if a general principle concerning disorientation could be discerned in these patients with acute focal lesions, the nature of disorientation for place in other conditions might be explored, for example in acute loss of memory due to hippocampal fornical lesions. Also, analysis of disorientation for place in cases of delirium could furnish clues to the process of delirium itself. I favor the view that in senile dementia the tendency to get lost is attributable at least in part to parietooccipital disease rather than to loss of global memory. But further investigation of disorientation for place in acute focal brain lesions is the next step.

This study was supported by a grant from The Freed Foundation, Washington, DC.

## References

1. Paterson A, Zangwill OL: Recovery of spatial orientation in the posttraumatic confusional state. *Brain* 1944;67:54-68.
2. Pick A: On reduplication paramnesia. *Brain* 1903;26:260-267.
3. Weinstein EA, Kahn RL: The syndrome of anosognosia. *Arch Neurol* 1950;64:772-791.
4. Weinstein EA, Kahn RL: Patterns of disorientation in organic disease of the brain. *Arch Neurol* 1951;65:533-534.
5. Weinstein EA, Kahn RL, Sugarman LA: Phenomenon of reduplication. *Arch Neurol* 1952;67:808-814.
6. Meyer O: Ein- und doppelseitige homonyme Hemianopsie mit Orientierungsstörungen. *Monatsschr Psychiatr Neurol* 1900;8:440-456.
7. Scheller H, Seidemann H: Zur Frage der optisch-räumlichen Agnosie. *Monatsschr Psychiatr Neurol* 1932;81:97-188.
8. Brain WR: Visual disorientation with special reference to lesions of the right cerebral hemisphere. *Brain* 1941;64:244-272.
9. Paterson A, Zangwill O: Disorders of visual space perception associated with lesions of the right cerebral hemisphere. *Brain* 1944;67:331-358.
10. Paterson A, Zangwill OL: A case of topographic disorientation associated with a unilateral cerebral lesion. *Brain* 1945;68:188-212.
11. Whiteley AM, Warrington EK: Selective impairment of topographical memory: A single case study. *J Neurol Neurosurg Psychiatry* 1978;41:575-578.
12. Hécaen H: Clinical symptomatology in right and left hemisphere lesions, in Mountcastle VB (ed): *Interhemispheric Relations and Cerebral Dominance*. Baltimore, Johns Hopkins Press, 1962.