

Transient Aphasia With Persistent Apraxia Uncommon Sequela of Massive Left-Hemisphere Stroke

Ola A. Selnes, PhD; Alan B. Rubens, MD; Gail L. Risse, PhD; Ronald S. Levy, PhD

• A 58-year-old, right-handed man became aphasic following a left-hemisphere stroke. Despite the massive size of the lesion, the aphasia was transient. An apraxia and agraphia did, however, persist three years after onset. The pattern of language impairment and subsequent recovery is believed to represent the rarely documented condition of mixed cerebral dominance for language.

(*Arch Neurol* 1982;39:122-126)

Although certain areas of the left cerebral hemisphere are generally accepted as crucial to normal language functioning, a number of reports documenting exceptions to this standard have been published. They include examples of crossed aphasia in dextrals,¹ lack of correlation between type of aphasia and location of lesion,² and absence of aphasia despite an appropriate lesion.³ Such cases are of importance for clinico-pathologic correlations and also contribute to the development of a more detailed account of the ways in which language may be organized in the human brain. The purpose of this communication is to report an exceptional case of aphasia in a right-handed man, in whom massive damage to the anterior and posterior supra-Sylvian language zones produced only a moderate aphasia that cleared completely over a short time. Ideomotor apraxia and agraphia were the only language-

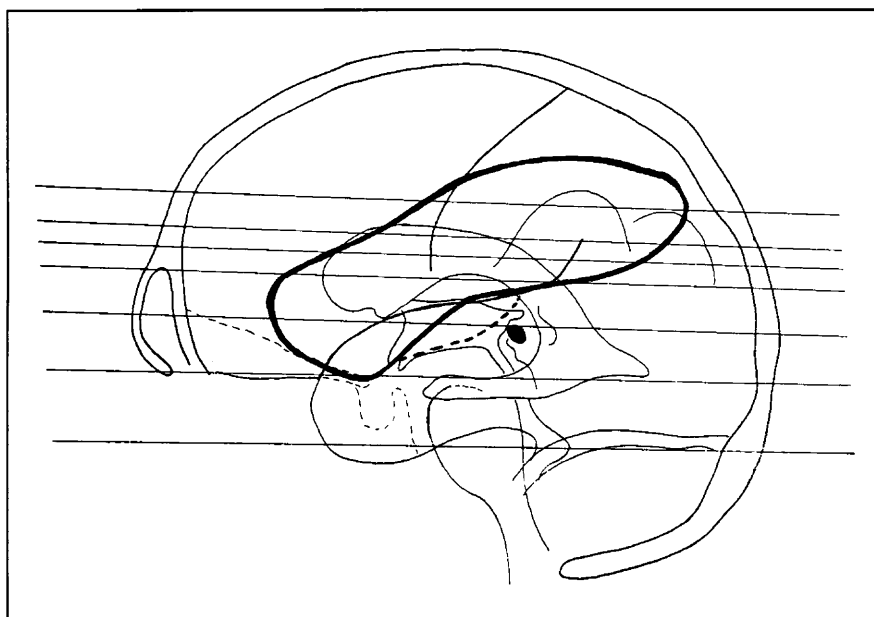


Fig 1.—Approximate lateral projection of lesion, which involves most of frontal operculum, including "Broca's area," and extends posteriorly to involve central and parietal opercula. Dotted line indicates involvement deep to temporal lobe in insula and underlying white matter.

related behavioral deficits that persisted. The case is important in that it documents the rarely seen condition of mixed, as contrasted with bilateral, cerebral language dominance in a right-handed aphasic patient.

REPORT OF A CASE

A 58-year-old, right-handed man was hospitalized on June 26, 1976, with the sudden development of a right hemiparesis and aphasia. Neurologic examination revealed a dense right hemiparesis and cortical hemisensory loss, severe ideomotor apraxia, and Gerstmann's syndrome. The aphasia, which was moderately severe, was characterized during the first several days by a deficit in auditory comprehension, repetition, and writing. The patient's

speech was dysarthric but fluent. In response to the question "Why are you here?" he said, "I had an accident." The hemiparesis cleared in several days so that the patient was able to walk around the ward. He was left, however, with a right-sided lower facial weakness that persisted for several months and a cortic sensory deficit involving the right hand that has persisted up to the present. The ideomotor apraxia and some elements of Gerstmann's syndrome have also persisted. The details of his language recovery will be discussed in a separate section. A radioisotopic brain scan obtained during the second week after onset revealed a large area of abnormal uptake in the left frontoparietal region over the superior division of the left middle cerebral artery. A diagnosis of occlusion of branches of the left middle cerebral artery with infarction of the frontocentral and

Accepted for publication April 21, 1981.

From the Neurology/Aphasia Service, Hennepin County Medical Center, Minneapolis (Drs Selnes, Rubens, and Risse), and the Department of Psychology, University of Houston (Dr Levy).

Read in part at the 17th annual meeting of the Academy of Aphasia, San Diego, Oct 15, 1979.

Reprint requests to Neurology/Aphasia AB 280, Hennepin County Medical Center, 701 Park Ave S, Minneapolis, MN 55415 (Dr Selnes).

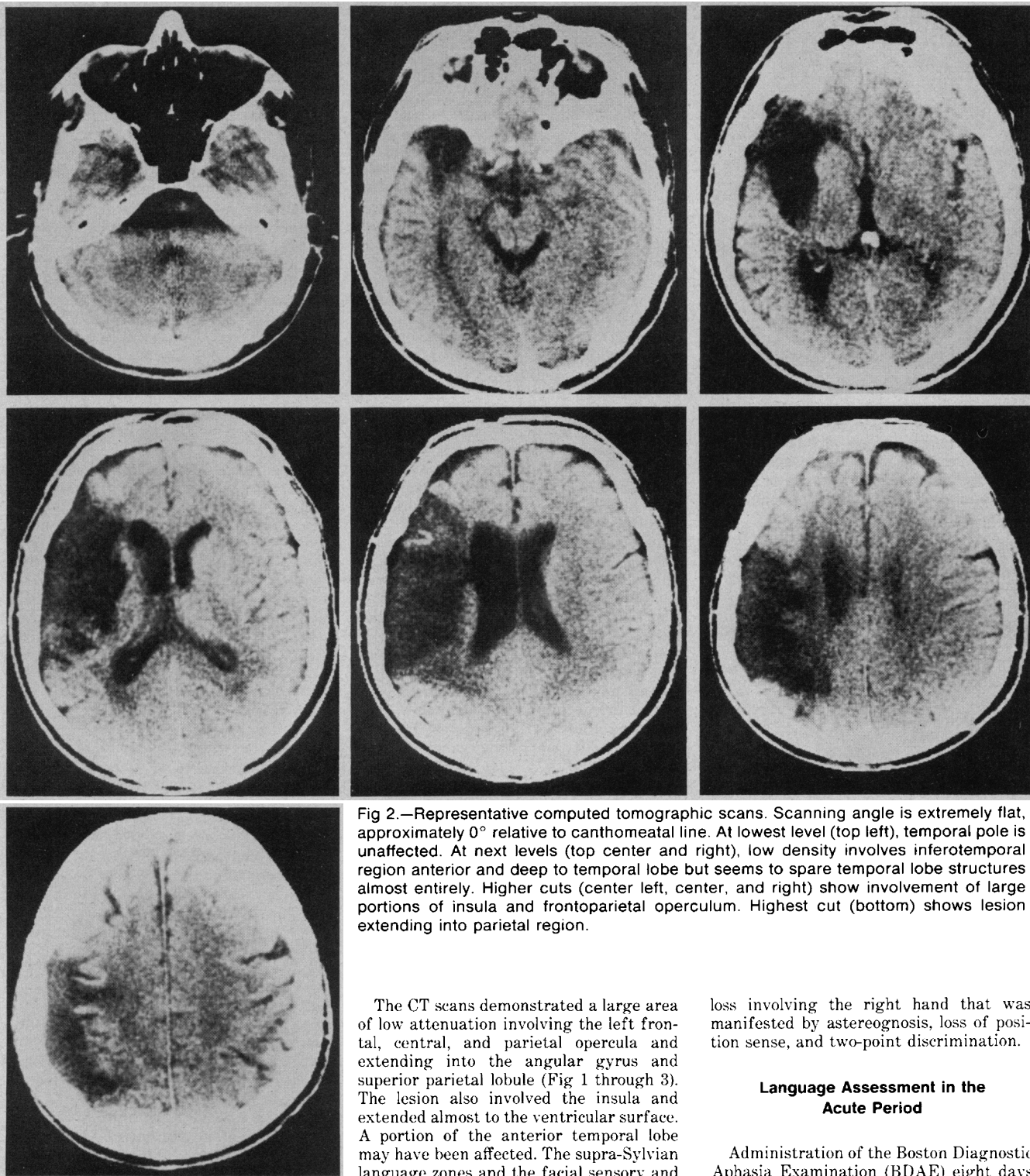


Fig 2.—Representative computed tomographic scans. Scanning angle is extremely flat, approximately 0° relative to canthomeatal line. At lowest level (top left), temporal pole is unaffected. At next levels (top center and right), low density involves inferotemporal region anterior and deep to temporal lobe but seems to spare temporal lobe structures almost entirely. Higher cuts (center left, center, and right) show involvement of large portions of insula and frontoparietal operculum. Highest cut (bottom) shows lesion extending into parietal region.

The CT scans demonstrated a large area of low attenuation involving the left frontal, central, and parietal opercula and extending into the angular gyrus and superior parietal lobule (Fig 1 through 3). The lesion also involved the insula and extended almost to the ventricular surface. A portion of the anterior temporal lobe may have been affected. The supra-Sylvian language zones and the facial sensory and motor cortical region were almost totally destroyed. The lesion seemed to spare Heschl's gyrus and the posterior superior temporal lobe (Wernicke's area).

The findings on CT scan were particularly surprising in that despite total destruction of the frontal, central, and parietal opercula and much of the angular gyrus, the aphasia had cleared completely, and all that remained were a writing disturbance and a moderately severe ideomotor apraxia. There was also a residual cortic sensory

loss involving the right hand that was manifested by astereognosis, loss of position sense, and two-point discrimination.

Language Assessment in the Acute Period

Administration of the Boston Diagnostic Aphasia Examination (BDAE) eight days after onset demonstrated that expressive language functions were essentially intact; overall results were as follows:

Severity rating, 4/5
 Articulatory rating, 7/7
 Phrase length, 5/7
 Verbal agility, 11/14

Word discrimination, 29/72
 Body-part identification, 15/20
 Commands, 11/15
 Complex material, 7/12

parietal regions on the left side was made. This diagnosis was confirmed, during another hospitalization 2½ years later, by cerebral arteriography and computed tomographic (CT) scanning. The arteriogram revealed an occlusion of a major branch of the left middle cerebral artery with a scarcity of vessels in the frontal and parietal opercula and sparing of the temporal branches.

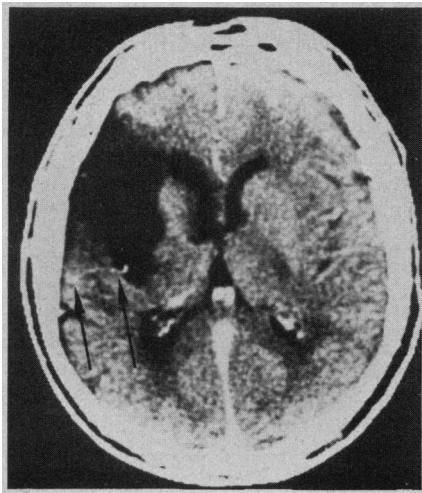


Fig 3.—Scan with contrast enhancement of middle cerebral artery indicating position of posterior Sylvian fissure and showing intact temporal lobe at this level (arrows). Anterior to enhancing vessel, temporal lobe is less dense because of partial volume effect, associated with absence of central and parietal opercula.

Responsive naming, 17/30
Confrontation naming, 91/105
Animal naming, 9/23
Body-part naming, 18/30

Oral reading, 30/30
Oral sentences, 10/10

Repetition (words), 10/10
High probability, 8/8
Low probability, 8/8

Neologisms, 0
Literal paraphasias, 0
Verbal paraphasias, 0

Word recognition, 8/8
Oral spelling/comprehension, 1/8
Word-picture matching, 8/10

Primer dictation, 10/15
Written confrontation naming, 2/10
Spelling to dictation, 1/10
Sentences to dictation, 6/12
Narrative writing, 2/4

Sentence melody, phrase length, and articulatory agility were within normal limits, and there were no paraphasic errors or any evidence of agrammatism. There were, however, some minor word-finding problems. The patient was noted, for example, to be vague and nonspecific when asked to explain his duties as an engineer; he had difficulty finding the appropriate words. His speaking rate was also increased, and his sentences often had a peculiar, burst-like onset. Repetition of both high- and low-probability sentences was intact at this time.

Comprehension was more severely impaired than expression. On body-part identification, he could point to major body parts but had difficulty with finer discriminations, such as shoulder, wrist, and

thumb. Left-right discrimination was appropriate but slow. He could follow axial commands, but was unable to do multi-stage commands requiring manipulation of objects, such as "Put the pencil on top of the card, then put it back." On a test of word discrimination (pointing to pictures of named objects), he also evidenced difficulty, scoring 16 of 36 points, and showed particular difficulty with letters, numbers, colors, and forms. His score on comprehension of complex ideational material was seven of 12 possible points, and on part 5 of the Token Test, he scored eight of a possible 21 (38% correct), suggesting a substantial impairment. Comprehension of written language was relatively intact. He scored eight of a possible ten on a word-picture matching task and nine of a possible ten on a task requiring comprehension of printed sentences and paragraphs. He was, however, unable to comprehend words spelled aloud by the examiner.

The patient's writing was considerably more impaired than his speech. He could write to dictation (with his right hand) four of five letters and two of five numbers. He could also write a few simple words to dictation, for example "boy," "run," and "come," but was unable to write more difficult ones, for example "belong," "soap," and "fight." His oral spelling was similarly impaired. On written confrontation naming, he was able to write the names of two of ten pictures, and his responses contained both paraphrasias (eg, "zee" for "thee," "sofa," for "chair," and "schair" for "square"). His written description of the Cookie Theft Card was incomplete but otherwise appropriate: "The boy in the cookie jar giving candy to the girl."

His ability to name was mildly to moderately impaired. He scored 60% correct on a test of responsive naming, 94% correct on a test of visual confrontation naming, and 60% correct on the body-part naming test. His fluency score was reduced in that he was able to name only nine animals in a one-minute period. On the test of word definition, he tended to perseverate with the response, "It's an instrument of success." He defined a chair as "a table," a hand as "an instrument of success," and his definition of a calendar was as follows: "A person uses a calendar to improve his image, among other things."

One of the most striking components of this patient's deficit was severe buccofacial and limb apraxia. On De Renzi's Oral Apraxia Battery (approximately three weeks after onset), he performed only two of ten commands completely correctly. Demonstration by the examiner only marginally improved his performance. To explore his apraxic difficulties further, he was given a specially designed apraxia battery, the results of which fit the classic picture of ideomotor apraxia: adequate comprehension, poor performance to verbal command, not much improvement with demonstration by the examiner, but success when using the real objects. There was no substantial difference between his left and right hands, which makes it unlikely that his apraxia was due to a callosal

separation from the language-processing hemisphere.

Language Assessment 34 Months After Onset

On retesting almost three years after the patient's stroke, word-finding difficulties were no longer evident in his spontaneous speech, but a moderately increased rate of speech was still present.

Auditory language comprehension had dramatically improved to the point that all test results were within the normal range, including normal performance on part 5 of the Token Test. In addition, he made no errors on an Experimental Test of Syntax, comprising 84 sentences that require primarily syntactic knowledge for their proper decoding. His reading comprehension was also entirely within normal limits, although the patient maintained that his reading now required more effort and proceeded somewhat more slowly than before his stroke.

The only persisting deficit was a spelling problem, which manifested itself both in oral and written spelling. Although his writing had improved, he still found it difficult to write and limited his writing to that of writing checks. His narrative writing had improved, but he still had difficulties with spelling certain words. When describing the Cookie Theft Card of the BDAE, he was, for example, unable to spell "tilted"; he then tried to write "slanted," but failing that, finally had to settle for "off balance." His word fluency was still impaired; he was able to produce only five words beginning with specified letters of the alphabet in a three-minute period.

An incidental finding was the patient's difficulty in providing nonconcrete interpretations of proverbs. When asked to explain a proverb like "Rome was not built in a day," he responded, "It took a long time for that city to be built." This deficit was also present when he was tested on a multiple-choice version of Gorham's Proverbs Test (57.5% correct).

A complete battery of nonlanguage and memory tests was also administered, the results of which are summarized in Table 1. As can be seen, both the Performance portion of the Wechsler Adult Intelligence Scale and Porteus Maze Test scores are above normal. No impairment was detected in the area of memory, with the possible exception of some mildly increased susceptibility to interference effects, verbal being greater than nonverbal. His visual, perceptual, and spatial functions all seemed to be intact. Tests of manual praxis, dexterity, and sensory functions still showed moderate to severe impairment with the right hand and less severe but still notable difficulty with the left. Words, numbers, and drawings tachistoscopically presented to a single visual field were correctly named on 70% of left-field trials and 80% of right-field trials, thus arguing against a visual disconnection syndrome. However, extinction of items in the right field was noted on double simultaneous stimulation. His performance on tests for apraxia was improved relative to his ear-

Table 1.—General Intelligence, Memory, Somatosensory Function, and Dichotic Listening*

Test	Score	
	1979	1976
General Intelligence		
Wechsler Adult Intelligence Scale		
Verbal	113	106
Performance	104	97
Full-scale	110	102
Porteus test quotient	132	118
Word fluency (Thurstone)	17	...
Memory		
Wechsler Memory Quotient	124	...
Rey Figure	30/36	...
Buschke's Verbal Learning	10/12	...
Somatosensory Function		
2-Point discrimination		
Right hand (total errors)	23/90(moderate impairment)	...
Left hand (total errors)	15/90(mild impairment)	...
Dichotic Listening		
Digits		
Right ear, %	73	...
Left ear, %	100	...
Consonant-vowel syllables		
Right ear, %	30	...
Left ear, %	96	...

*Results in 1979 are approximately three years after onset; 1976 scores are presented as available.

Table 2.—Performance on Experimental Apraxia Battery Immediately and Three Years After Onset*

Stimulus and Task	August 1976		May 1979,
	Right Hand	Left Hand	Right Hand
1. Name—pointing	8/10	9/10	10/10
2. Sound—pointing	4/10	6/10	9/10
3. Name—gesture	0/10	2/10	5/10
4. Picture—gesture	1/10	2/10	7/10
5. Sound—gesture	0/10	0/10	6/10
6. Imitation—gesture	1/10	1/10	9/10
7. Real object—gesture	8/10	7/10	10/10

*In conditions 1 and 2, the patient points to a picture of an object in response to either its name or sound. In the remaining conditions, the patient demonstrates the appropriate use of the object in response to (3) the spoken name of the object, (4) a picture of the object, (5) the sound associated with the object, (6) demonstration of the use of the object by the examiner, and (7) using the real object.

lier evaluation, but was still moderately impaired, regardless of the mode in which the commands were presented. These results are given in Table 2. The most notable improvement was his ability to imitate gestures, which was almost completely intact on retesting.

In summary, in the acute period there was severe impairment of auditory comprehension and somewhat less but still notable impairment of reading and writing, particularly of spelling. Three years later, a complete recovery of both reading and auditory comprehension was evident. The only remaining deficits formally documented were an impairment in word fluency and in oral and written spelling,

difficulty with providing interpretations of proverbs, and a moderately severe apraxia.

COMMENT

The most important feature of this case is that the initial degree of aphasia was far less severe than one would have predicted based on the size of this massive ischemic lesion of the frontoparietal language zone in a right-handed man. Recent studies by Mohr and his colleagues^{5,6} suggested that patients with large lesions of the frontoparietal operculum that destroy

Broca's area and much of the surrounding cortex typically are seen initially with a severe, global type of aphasia that gradually evolves into a chronic Broca-type aphasia. Our patient, despite the fact that the lesion destroyed the entire frontoparietal operculum, had only a mild aphasia, which subsequently cleared within a short time. Another important feature is the persistence in the nonacute period of ideomotor apraxia and dysgraphia (associated with an underlying receptive and expressive spelling deficit) in the absence of aphasia.

The key to understanding the unusual features of this case is probably found in the patient's premorbid anatomic organization of language. Basically, there are only three possibilities: either language was represented unilaterally in the left or in the right hemisphere or it was represented in both hemispheres.

Compatible with the possibility of left-hemisphere language dominance are the observations that the patient has always and still prefers to write with his right hand despite a persistent right sensory deficit. This feature is even more surprising given that one of his younger brothers is left-handed. In addition, left-hemisphere dominance for language is suggested by the presence of Gerstmann's syndrome initially. Finally, the patient was not left-hemisphere dominant for visuospatial perceptual functions, because at no time did he show any evidence of visual neglect, visuospatial deficit, or other nondominant hemisphere involvement. The major problem with this hypothesis, however, is that if language functions were mediated by the classical peri-Sylvian areas of the left hemisphere, this patient should have had a nonfluent aphasia of greater severity, most likely a severe global aphasia. Since he manifestly did not have a global aphasia, one may conclude that either his language functions were not mediated by the left hemisphere, or if they were they must have been subserved by areas other than those traditionally believed to be involved in language functions. Although the literature documents considerable individual variation in the neuroanatomic organization of cortical functions,⁷ it is unlikely that the brain of this patient could have deviated so much from the norm that it almost completely escaped the effects of this massive left hemisphere lesion. Even if one does assume that Broca's area in this patient was in a region of the frontal lobes not affected by the lesion, it

would still be functionally disconnected from the temporal lobe, which on CT scan appears isolated from anterior regions of the left hemisphere, as well as from homologous right-hemisphere areas. It is unlikely, therefore, given the virtual absence of any expressive or articulatory difficulties, that the patient was left-hemisphere dominant for expressive language functions.

It is, however, equally unlikely that the patient could have been entirely right-hemisphere dominant for language. Were this the case, he should not have become aphasic at all following his left-hemisphere stroke.

The possibility of some degree of premorbid bilaterality of language representation therefore must be considered. The major argument against the assumption of bilateral language in a right-hander is a statistical one. The amobarbital (Amytal) sodium studies of the Montreal group⁸ indicate that right-handers who become aphasic with injection of barbiturate on one side do not become aphasic when the other carotid is injected, thus suggesting that bilateral language function in right-handers is exceedingly rare. Assuming, however, that some degree of bilaterality or mixed dominance is present, the details of the organization of language functions in this patient's brain must still be determined. In light of the patient's minimal impairment in expressive speech even in the acute stage, it is most likely that the motor components of his language were represented largely in the right hemisphere premorbidly, although one may not completely rule out some left hemispheric influence to account for the minor changes in his prosody.

It is, however, somewhat more difficult to account for his early comprehension problems, particularly since this function showed near complete recovery. Unquestionably, the left hemisphere played an important role in auditory decoding of language premorbidly, given the severity of his initial comprehension deficit. Although the left temporal lobe appeared on CT scan to be relatively spared by the lesion, the comprehension deficit might be explained in terms of a disconnection between language areas within the left hemisphere or transcallosally. The lesion was located so as to compromise temporotemporal transcallosal connections, as well as intrahemispheric left temporal lobe connections with anterior motor regions.^{9,10}

Recovery of auditory comprehen-

sion, which is now complete, could have taken place in either hemisphere, but results of dichotic listening tests (Table 1), which showed a pronounced left-ear advantage for both digits and consonant-vowel syllables, are most compatible with current right-hemisphere auditory processing.

The patient's writing and spelling functions must have been mediated by the left hemisphere. The fact that he used and still uses his right hand would lead one to suspect this association. However, prior to his stroke, the patient used an inverted or hooked writing posture, which would be interpreted by some as a sign of right-hemisphere dominance. His spelling errors are much like those seen in the syndrome of alexia with agraphia of left parietal-lobe origin, although our patient is not alexic in the true sense. He does show evidence of impaired phonologic processing when asked to spell words orally and to decide which words rhyme. Whether his relatively intact reading ability means that he is using the right hemisphere and thus possibly bypassing the phonologic stage remains an open question. The possibility that aphasics may use such a route has been suggested by some investigators.

The persistent ideomotor apraxia strongly suggests that premorbidly the left hemisphere was dominant for higher-level motor control. To our knowledge, the only previous description of ideomotor apraxia and agraphia in a nonaphasic right-hander is that of Heilman et al.¹¹ The patient was a 56-year-old, right-handed man who was not examined until three months following his left-hemisphere stroke; therefore, it is possible that mild aphasia was present initially. The patient had a right hemiplegia and hemianopsia, and he neglected the left side of the page when reading. Beyond reporting that he correctly spelled the word "cat" aloud, no account of oral spelling or comprehension of orally spelled words was presented. Information about the site of the lesion as determined by CT scan was not available. The authors concluded that in their patient the right hemisphere was dominant for language and the left was dominant for complex manual skills. The finding of buccofacial apraxia without a disorder of speech production demonstrated the independence of the two motor mechanisms. In our patient the absence of hemiplegia permitted the demonstration of bilateral ideomotor apraxia and agraphia and therefore ruled out the possibility (that existed

in the hemiplegic patient of Heilman and associates) that the left-hand writing and praxis errors were of callosal origin. Also in our patient there was no neglect or other visuospatial deficit.

In summary, the language functions in our patient seem to have been represented in both hemispheres premorbidly and, with the possible exception of auditory comprehension, were without duplication. We interpret our data as being most compatible with right-hemisphere dominance for expressive language and visuospatial function and with left-hemisphere dominance for praxis, writing, and spelling. In the patient's current stage of recovery, comprehension is subserved by the right hemisphere; however, this point remains conjectural. His premorbid reading functions cannot be as easily localized.

Rather than calling this case bilateral language representation, one might more appropriately refer to it as a case of mixed dominance, representing an interesting example of the variety of ways in which language and high-level motor functions may be distributed in the human brain.

This study was supported in part by contract N01-NS-2378 from the National Institute of Neurological and Communicative Disorders and Stroke.

References

1. Brown JW, Wilson FR: Crossed aphasia in a dextral: A case report. *Neurology* 1973;23:907-911.
2. Lhermitte F, Lecours AR, Ducarne B, et al: Unexpected anatomical findings in a case of fluent jargon aphasia. *Cortex* 1973;9:433-446.
3. Boller F: Destruction of Wernicke's area without language disturbance. *Neuropsychologia* 1973;11:243-246.
4. Geschwind N: The apraxias: Neural mechanisms of disorders of learned movement. *Am Sci* 1975;63:188-195.
5. Levine DN, Mohr JP: Language after bilateral cerebral infarctions: Role of the minor hemisphere in speech. *Neurology* 1979;29:927-938.
6. Mohr JP, Pessin MS, Finkelstein S, et al: Broca aphasia: Pathologic and clinical. *Neurology* 1978;28:311-324.
7. Whitaker HA, Selnes OA: Anatomic variations in the cortex: Individual differences and the problem of localization of language. *Ann NY Acad Sci* 1976;280:844-854.
8. Branch C, Milner B, Rasmussen T: Intracarotid sodium amytal for the lateralization of cerebral speech dominance. *J Neurosurg* 1964;21:399-405.
9. Rubens AB, Johnson MG, Speaks C: Location of lesions responsible for the 'paradoxical ipsilateral ear effect' with dichotic listening tests in patients with aphasia due to stroke. *Neurology* 1978;28:396.
10. Damasio H, Damasio A: 'Paradoxical' ear extinction in dichotic listening: Possible anatomic significance. *Neurology* 1979;29:644-653.
11. Heilman KM, Goneya EF, Geschwind N: Apraxia and agraphia in a right-hander. *Cortex* 1974;10:284-288.