

Transtentorial Herniation with Posterior Cerebral Artery Territory Infarction

A New Mechanism of the Syndrome of Alexia Without Agraphia

H. S. KIRSHNER, M.D., J. STALLER, PH.D.,
W. WEBB, PH.D., AND P. SACHS, PH.D.

SUMMARY A 39-year-old male developed a right homonymous hemianopsia and alexia without agraphia following emergency surgery for hemorrhage into a left frontal tumor. A computerized tomographic (CT) scan demonstrated low density areas in the left frontal region and in the territory of the left posterior cerebral artery. The alexia without agraphia syndrome appeared to result from compression of the left posterior cerebral artery by a transtentorial pressure cone, a mechanism not previously reported in this syndrome. The behavioral investigation confirmed the diagnosis and replicated recent findings related to the syndrome of alexia without agraphia.

Stroke, Vol 13, No 2, 1982

THE SYNDROME of alexia without agraphia is an uncommon disorder in which reading is impaired in isolation, leaving writing and other language functions intact, except for dysnomia. The syndrome has been reported with left occipital lesions including posterior cerebral artery occlusion,¹⁻⁵ tumors,⁶⁻⁹ trauma,¹⁰⁻¹² surgical resection,¹³ and intracranial hemorrhage.³ We report a case in which alexia without agraphia appeared to follow transtentorial herniation and posterior cerebral artery compression secondary to hemorrhage into a frontal tumor.

Case Report

This 39 year old, right-handed male consulted an ophthalmologist for headaches and blurred vision. On examination, he was found to have papilledema, but his neurological examination was otherwise normal. Radionuclide brain scan and left carotid arteriography disclosed a large left frontal tumor. Prior to elective surgery, the patient was found comatose with fixed dilated pupils. Emergency craniotomy and decompression were performed, with removal of most of the left prefrontal region. Pathological examination revealed a grade II astrocytoma with gross intraparenchymal hemorrhage. The patient made a gradual recovery with transient speech disturbance and permanent difficulty with reading. At first he was unable to read even single words, though he could read some single letters. Over the next year he regained the ability to read short phrases and sentences, always with great effort.

When examined neurologically four years after onset, the patient had a dense right homonymous hemianopsia. Bedside aphasia testing¹⁴ was remark-

able only for difficulty in reading and in naming colors. Auditory comprehension was normal, including matching of dictated spelled words to pictures. The patient showed the striking ability to write sentences to dictation, but not to read his own written productions, shown to him minutes later. Aside from the visual field defect, there were no discernible cranial nerve, motor, or sensory deficits.

A CT brain scan (fig. 1) revealed left frontal and left occipital low density areas. The frontal lesion involved the superior and middle frontal gyri and subjacent white matter. The inferior frontal and precentral gyri appeared spared. There was no mass effect or enhancement with contrast infusion to suggest residual tumor. The large medial occipital lesion included the calcarine, cuneate, lingual, and occipitotemporal gyri and subcortical white matter.¹⁵

Behavioral evaluation included a normal Wechsler Adult Intelligence Scale IQ of 103, a reduced Wechsler Memory Quotient of 74, and subnormal scores on the Benton Visual Retention and Trail Making Tests. The Boston Diagnostic Aphasia Examination (BDAAE)¹⁶ was within normal limits except for the reading items and the naming of objects, colors, and body parts. The patient correctly named only 2/6 colors and 6/10 body parts. He correctly named the six pictures of objects, but latencies were markedly prolonged. His performance on the short item reading subtests of word-picture matching, word recognition, and comprehension of oral spelling was slow but errorless. The symbol and word discrimination test showed mild impairment.¹⁶ Oral reading was extremely slow, and he failed to comprehend paragraphs of more than two sentences in length. All of the writing subtests were normal. The Gates-McGinitie reading test (Form C-Primary 3) showed a grade equivalent of 1.7 on the comprehension subtest and 3.9 on the vocabulary subtest.

The patient was given an experimental test battery previously employed in alexia without agraphia.¹² The battery included a letter naming task, a word naming task, a word-nonword discrimination or "lexical decision" test, and a cueing test. In the cueing test, a dic-

From the Departments of Neurology, Psychology and Hearing and Speech Sciences, Vanderbilt University School of Medicine, Nashville, Tennessee.

This research was supported by NINCDS Teacher Investigator Development Award #1 K07 NS00429-02 to Dr. Kirshner.

Address Correspondence to: Howard S. Kirshner, M.D. Department of Neurology, Vanderbilt University School of Medicine, Nashville, Tennessee 37232.

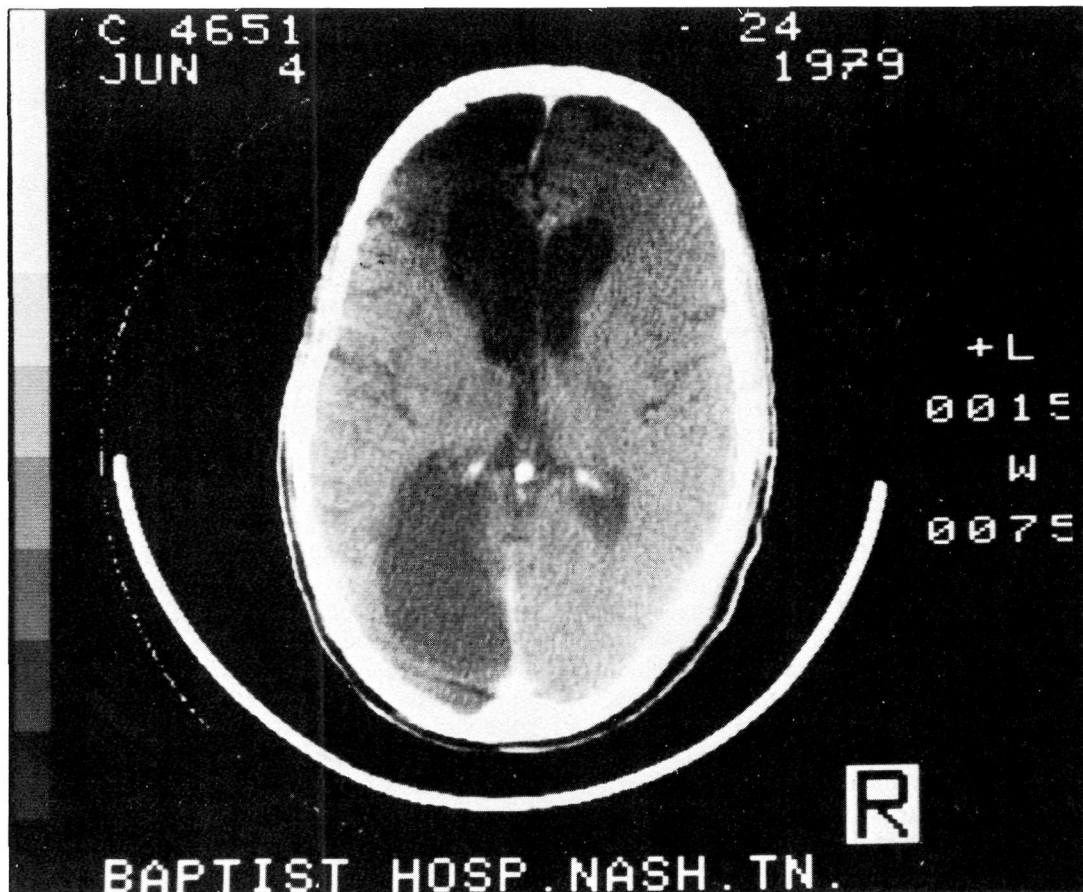


FIGURE 1. CT Scan photograph showing left frontal and left occipital areas of reduced attenuation.

tated word name, a printed word name, and a picture were compared as facilitators of the patient's ability to identify a word from a list. Letter naming was mildly impaired (12/144 errors), but latencies were much shorter than for words. Latencies increased with length in both the word naming and lexical decision tasks indicating that the patient was reading by a letter-by-letter decoding process. In the cueing test, the dictated words were more effective than either the printed word name or picture, indicating the preservation of auditory language processing. These results were similar to previous findings in alexia without agraphia.¹²

Discussion

The patient's reading disorder appeared typical of alexia without agraphia in bedside testing, in the BDAE, and in the experimental test battery. Alexia with preserved writing, difficulty in naming colors, short term memory loss, and right homonymous hemianopsia are all characteristic of the syndrome. Letter-by-letter reading and ability to interpret dictated spelled words have also been emphasized.^{3, 12, 14} The hallmark of alexia without agraphia, however, is the remarkable ability of the patient to write sentences to dictation, yet not to read these same sentences.

The pathogenesis of the syndrome in our patient appeared to involve hemorrhage into the left frontal tumor, with creation of a transtentorial pressure cone,

compression of the posterior cerebral artery, and infarction of the left occipital lobe.

Compression of the posterior cerebral artery and resultant temporo-occipital infarction has been well documented in cases of transtentorial herniation.¹⁷⁻¹⁹ While survival after transtentorial herniation is unusual, cases with both cortical blindness and hemianopsia have been reported.^{17, 18, 20} Kertesz²¹ reported a case of alexia and visual agnosia secondary to severe head trauma with prolonged coma, but no evidence for transtentorial herniation or posterior cerebral artery compression was presented. The behavioral syndrome of alexia without agraphia has not previously been described as a sequel of transtentorial herniation.

The experimental findings of preservation of letter reading and letter-by-letter decoding of words confirm previous findings in alexia without agraphia.^{12, 22, 23} These findings are not easily explained by the traditional model of alexia without agraphia, which postulates a disconnection of the intact right visual cortex from left hemisphere language centers, and especially from the left angular gyrus, which is thought to be a center for intermodality associations such as the visual to auditory transcoding needed for reading.^{2, 24} The direct site of this disconnection is thought to be the splenium of the corpus callosum which, along with occipital lobe, is supplied by the posterior cerebral artery. Most instances of alexia without agraphia in

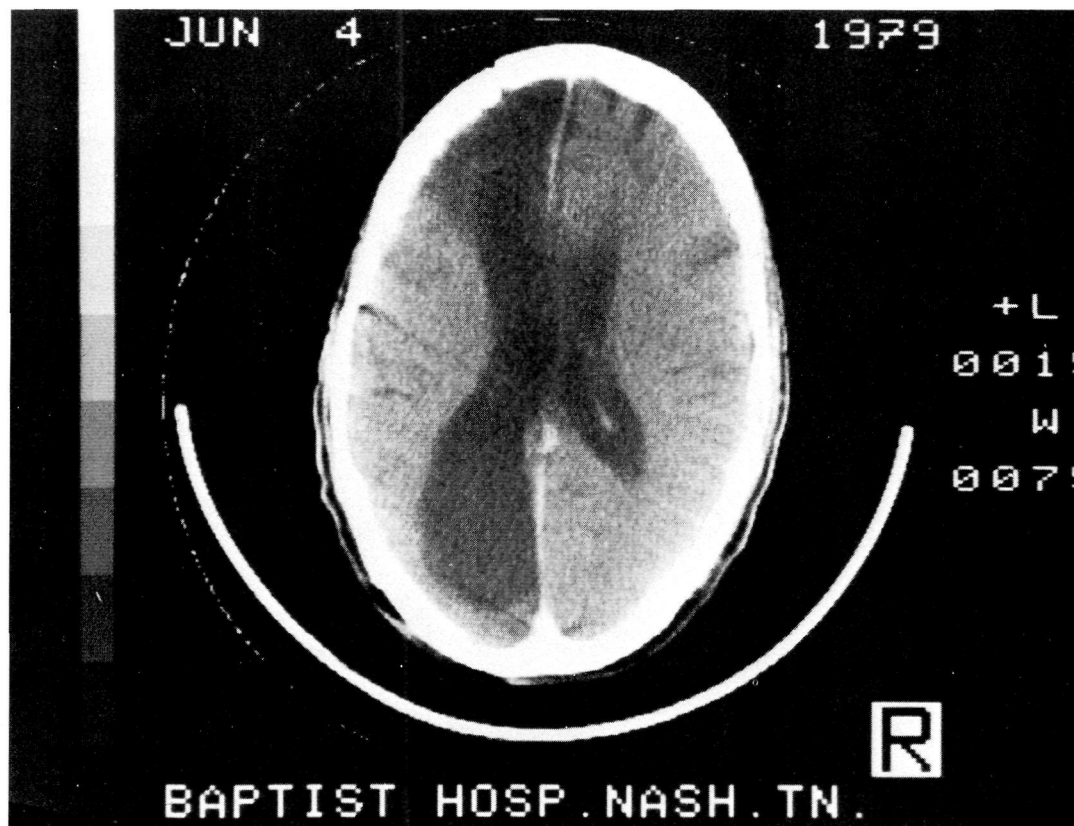


FIGURE 2. CT Scan, showing a higher tomographic cut.

the literature have been caused by stroke in the territory of the left posterior cerebral artery.¹⁻⁵ Reports of alexia without agraphia in other pathological conditions affecting the left occipital lobe — including tumors,⁶⁻⁹ surgical resection,¹³ trauma,¹⁰⁻¹² and intracerebral hemorrhage,³ all of which should not affect the corpus callosum — suggest that anatomical disconnection may not fully account for the syndrome. Others have suggested that an occipital white matter lesion alone may be sufficient to disconnect the right visual cortex,⁷ or even both visual cortical areas,²⁵ from the angular gyrus. The experimental and clinical findings in alexia without agraphia can also be explained by a disturbance of a more fundamental visual process such as the ability to perceive more than one language stimulus simultaneously³ or the ability to recognize a “visual word form”.²³ The status of these competing theories regarding the mechanisms of alexia without agraphia will have to await the verdicts of future research.

Acknowledgments

We thank Dr. James E. Hays for providing helpful information about the patient's surgery and clinical course. Mrs. Jane S. Smith, Ms. Mary Henry, and Ms. Beth Gehrke assisted with preparation of the manuscript.

References

- Cumming WJK, Hurwitz LJ, Perl NT: A study of a patient who had alexia without agraphia. *J Neurol Neurosurg Psychiatr* **33**: 34-39, 1970
- Dejerine MJ: Contribution a l'étude anatomo-pathologique et clinique des différentes variétés de cécité verbale. *C.R. Soc Biol (Paris)* **4**: 61-90, 1892
- Levine DN, Calvanio R: A study of the visual defect in verbal alexia-simultanagnosia. *Brain* **101**: 65-81, 1978
- Mohr JP, Leicester J, Stoddard LT, et al: Right hemianopsia with memory and color deficits in circumscribed left posterior cerebral artery territory infarction. *Neurology* **21**: 1104-1113, 1971
- Patterson JV, Bramwell E: Two cases of word blindness. *Med Press Circ* **79**: 507-508, 1905
- Cohen DN, Salanga VD, Hully W, et al: Alexia without agraphia. *Neurology* **26**: 455-459, 1976
- Greenblatt SH: Alexia without agraphia or hemianopsia. Anatomical analysis of an autopsied case. *Brain* **96**: 307-316, 1977
- Turgman J, Goldhammer Y, Graham J: Alexia without agraphia, due to brain tumor: a reversible syndrome. *Ann Neurol* **6**: 265-268, 1979
- Vincent FM, Sadowsky CH, Saunders RL, et al: Alexia without agraphia, hemianopsia or color-naming defect: A disconnection syndrome. *Neurology* **27**: 689-691, 1977
- Heilman KM, Safran A, Geschwind N: Closed head trauma with aphasia. *J Neurol Neurosurg Psychiatr* **34**: 265-269, 1971
- Lhermitte J, de Massary J, Huguenin R: Syndrome occipital avec alexie pure d'origine traumatique. *Rev Neurologique (Paris)* **2**: 703-707, 1929
- Staller J, Buchanan D, Singer M, et al: Alexia without agraphia: An experimental case study. *Brain Lang* **5**: 378-387, 1978
- Ajuriaguerra J. de, Hécaen H: La restauration fonctionnelle après lobectomie occipitale. *J Psychologie (Paris)* **44**: 510-540, 1951
- Benson DF, Geschwind N: The aphasias and related disturbances. In Baker AB and Baker LH: *Clinical Neurology*. Hagerstown, Harper & Row, Publishers, Inc., Vol 1. Chapter 8, pp 3-5, 1980
- Gado M, Hanaway J, Frank R: Functional anatomy of the cerebral cortex by computed tomography. *J Comp Assist Tomogr* **3**: 1-10, 1979

16. Goodglass H, Kaplan E: *The Assessment of Aphasia and Related Disorders*, Philadelphia, Lea & Febiger, 1972
17. Meyer A: Herniation of the brain. *Arch Neurol Psychiat* **4**: 387-400, 1920
18. Hoyt WF: Vascular lesions of the visual cortex with brain herniation through the tentorial incisura: Neuroophthalmologic considerations. *Arch Ophthalmol* **64**: 44-57, 1960
19. Lindenberg R, Walsh F: Vascular compression involving intracranial visual pathways. *Trans Am Acad Ophthalmol Otolaryngol* **68**: 677-694, 1964
20. Keane JR: Blindness following tentorial herniation. *Ann Neurol* **8**: 186-190, 1980
21. Kertesz A: Visual agnosia: The dual deficit of perceptions and recognition. *Cortex* **15**: 403-419, 1979
22. Hinselwood J: *Letter-Word-and Mind-Blindness*. London, H.K. Lewis, 1900
23. Warrington ED, Shallice T: Word-form dyslexia. *Brain* **103**: 99-112, 1980
24. Geschwind NS: Disconnection syndromes in animals and man. *Brain* **88**: 237-294, 1965
25. Greenblatt SH: Subangular alexia without agraphia or hemianopsia. *Brain Lang* **3**: 229-245, 1976

Transtentorial herniation with posterior cerebral artery territory infarction. A new mechanism of the syndrome of alexia without agraphia.

H S Kirshner, J Staller, W Webb and P Sachs

Stroke. 1982;13:243-246

doi: 10.1161/01.STR.13.2.243

Stroke is published by the American Heart Association, 7272 Greenville Avenue, Dallas, TX 75231

Copyright © 1982 American Heart Association, Inc. All rights reserved.

Print ISSN: 0039-2499. Online ISSN: 1524-4628

The online version of this article, along with updated information and services, is located on the World Wide Web at:

<http://stroke.ahajournals.org/content/13/2/243>

Permissions: Requests for permissions to reproduce figures, tables, or portions of articles originally published in *Stroke* can be obtained via RightsLink, a service of the Copyright Clearance Center, not the Editorial Office. Once the online version of the published article for which permission is being requested is located, click Request Permissions in the middle column of the Web page under Services. Further information about this process is available in the [Permissions and Rights Question and Answer](#) document.

Reprints: Information about reprints can be found online at:
<http://www.lww.com/reprints>

Subscriptions: Information about subscribing to *Stroke* is online at:
<http://stroke.ahajournals.org/subscriptions/>