

APHASIA IN A PRELINGUALLY DEAF WOMAN

by CHRISTINE CHIARELLO, ROBERT KNIGHT
and MARK MANDEL¹

*(From the Department of Linguistics, University of California, Berkeley, CA 94720,
University of California, Davis, and the Veterans Administration Medical Center Martinez,
California, USA)*

INTRODUCTION

IN order to understand the neural substrate of linguistic behaviour it is necessary to consider language in all its various guises. This will include data integration of non-European spoken and written languages (Sasanuma, 1975; Naeser and Chan, 1980), as well as languages which do not utilize the vocal/auditory modality (Critchley, 1970). Identification of the similarities and differences in the neural representations of such diverse language systems may identify those which are shared by all languages, and those which are related to specific linguistic structures or particular input/output modalities.

Of the various manual languages of the deaf, American Sign Language (ASL) has recently become the focus of intense study. It is the primary means of communication used by many deaf persons in the United States, and is a fully developed language (Klima and Bellugi, 1979), although it is not derived from English or any other spoken language. Finger-spelling, in contrast, is a system in which words are spelled manually, with one symbol for each letter of the English alphabet. (Those unfamiliar with the structure of ASL may wish to consult the Appendix for a brief synopsis of those properties relevant to this study.)

ASL is of particular neurolinguistic interest because of the simultaneity inherent in the structure of signs, and its use of space to encode linguistic information. Visual half-field studies have generally suggested a greater involvement of the right hemisphere in the processing of ASL by native signers than is expected for a spoken language (Manning, Goble, Markman and LaBreche, 1977; McKeever, Hoemann, Florian and Vandeventer, 1976; Poizner, Battison and Lane, 1979; Poizner and Lane, 1979; but *see also* Neville and Bellugi, 1978). Only a handful of cases of sign language aphasia have been recorded (Burr, 1905; Critchley, 1938; Leischner, 1943; Tureen, Smolik and Tritt, 1951; Douglass and Richardson, 1959; Sarno, Swisher

¹ Current affiliation: Department of Psychology, Northeastern University.

and Sarno, 1969; Kimura, Battison and Lubert, 1976; Meckler, Mack and Bennett, 1979; Underwood and Paulson, 1981). In all these cases the lesion involved the left hemisphere, although precise intrahemispheric localization data have been lacking. It is reasonable to expect a somewhat different intrahemispheric organization for visual-gestural languages. Isolated disturbances of visual language (alexia with agraphia) have usually been associated with lesions in the left parietal lobe, in particular the angular gyrus (Dejerine, 1892; Albert, 1979). It would follow that this region, rather than the classic auditory association areas, would subserve the decoding of sign language.

Previous studies of sign language aphasia have been inconclusive. In some cases, the individual was not prelingually deaf (Critchley, 1938; Kimura *et al.*, 1976; Meckler *et al.*, 1979). In others, adequate lesion localization data were not available (Burr, 1905; Douglass and Richardson, 1959; Sarno *et al.*, 1969; Underwood and Paulson, 1981). Leischner (1943) presented detailed post-mortem findings, but the existence of multiple lesions involving both hemispheres prevents specific clinico-anatomical correlations. Lastly, investigators have not viewed sign language aphasia as the disruption of a cohesive linguistic system. Thus, little information on the quality of the aphasic symptoms in such cases is available for comparison with data from hearing aphasic patients.

In this paper we report sign language aphasia in a 65-year-old prelingually deaf woman who was fluent in ASL before suffering a left parietal cerebrovascular accident. Her language abilities were assessed three times within the first two weeks following her stroke, and a more extensive investigation was done five to seven weeks post-onset. Our aims were twofold: (1) to document the patient's linguistic disorder in sufficient detail to determine whether her symptom complex would parallel that expected for a hearing person and whether there were any features unique to the gestural modality; (2) to correlate the site of the lesion as evident on the CAT scan with the aphasic symptoms in order to provide information on the neuroanatomical organization of sign language.

CASE REPORT

Background

The patient, L.K., a right-handed woman, was born in Mexico in 1914. She entered the US the following year, and was adopted. She became deaf at 6 months of age after an episode of scarlet fever, and was the only deaf person in her (adoptive) family. Early records state only that L.K. was 'completely deaf in both ears'. Communication with her family was reportedly accomplished *via* finger-spelling. A childhood (hearing) friend, who had also communicated with L.K. using finger-spelling, stated that to her knowledge, the patient never lip-read or used speech. At the age of 5 years she was enrolled in a residential school for the deaf. There she was taught both oral techniques (speech and lip-reading) and finger-spelling. American Sign Language was not used for instruction, but was used among the students outside of the classroom. The patient stated that she learned ASL from an older student when she was 7 or 8 years old. She reported that she preferred signing to oral techniques and always used the former except in the classroom. She began learning to read and write English at approximately the same time. L.K. was a 'C' student, excelling in crafts and other manual arts. She left

school at 16 years of age without graduating, and was employed in a number of manufacturing jobs. In 1946 she married a hearing-impaired person, and remained married for seventeen years. An associate described the patient as quite self-sufficient and capable. Most of the patient's friends were members of the deaf community.

A sign language interpreter (J.L.), who had interpreted for the patient several times within the year before her stroke, stated that L.K. was fluent in ASL and used finger-spelling to a moderate extent. She was described as being quite voluble, and was known to sign non-stop for extended periods. The patient also vocalized, but her 'speech' was not understandable, and therefore could not serve as a medium of communication. This interpreter felt that L.K. did not read lips. L.K.'s reading level was estimated by a hearing associate to be at least fifth grade at this time. She reportedly read and understood the newspaper. A sample of her pre-stroke writing (see fig. 1) indicates that, while adequate

December 30-1979

Dear Sirs;

I am enclosing several pieces of identification. I desire a Delayed Birth certificate. I best recall that I was born in Dec 24-1916 in Phoenix Arizona last December - 1975. I received identification card, Identification card from the Motor Vehicle Dept for last five yrs until 1979 of December as expiring. Someone stole my black billfold wallet with including my I.D. card from my coat's pocket while I stood behind them at bus stop in Oakland down town last week.

I am deaf person and have great difficulty, cashing checks because I don't have in I.D. card. (identification card).

Your help, in the matter is greatly appreciated

FIG. 1. Sample of L.K.'s writing, approximately three months before her stroke.

to serve her needs, it was substandard in some respects. The errors in punctuation, spelling, and the misuse or omission of articles and prepositions are characteristic of the writing of deaf persons who are not highly educated. However, it is notable that the patient used appropriate English syntax and verb inflections.

It appears, then, that the patient primarily used ASL, supplemented by finger-spelling, to communicate prior to her stroke. She could also read and write English sufficiently well to manage her own affairs. As far as could be determined, L.K. never acquired spoken language. Finger-spelled English may have been her 'first language', but her fluency in finger-spelling prior to the acquisition of signs could not be ascertained.

We will adopt the following conventions to represent words in the various language systems used by the patient: WATER represents an ASL sign; I-GIVE-YOU represents a single ASL sign which requires more than one word to translate: W-A-T-E-R indicates a finger-spelled English word; *water* represents printed or written English; 'water' is the translation of an ASL sign, or signs.

Neurological Examination and CAT Scan Findings

On March 27, 1980, L.K. developed right-sided weakness of acute onset and was brought to the Emergency Room. On admission, her general medical examination was unremarkable. Neurological examination revealed her to be awake and alert with moderate weakness of the right arm and slight right central facial and right leg weakness. Pin-prick, touch, vibration and proprioception were markedly decreased on the right side. Her reflexes were increased on the right side, her right arm and leg were flaccid and she had a right extensor plantar response. No hemi-inattention was noted. Vascular examination revealed a loud left carotid bruit. The patient was admitted with a diagnosis of embolic infarction of the left hemisphere. A sign language interpreter (J.L.), who had known L.K. prior to her stroke, was called for more detailed evaluation of her mental status. The patient was found unable to follow two-part sign commands. Her output of signs was limited to YES, NO and I-DON'T-KNOW. She was able to read and perform a bucco-facial command such as *open your mouth* or an axial command such as *close your eyes* but could not perform more complicated written commands. Her writing was severely impaired and she wrote her first name as response to all sign questions. She could mimic all letters of the finger-spelling system, but when asked to finger-spell the alphabet spontaneously, she spelled A-B-C-D-I-D-I-D. She tended to use gestures to express her needs to the examiners.

Five days after admission the patient remained with a trace of right central facial paresis, worse to volitional than to emotional movement. She had severe weakness of her right upper extremity with some increase in tone in her arm, and her leg was moderately weak. Strength and dexterity in her left arm were normal. She had marked right-sided sensory decrease to primary somatosensory modalities with the arm most severely affected. She was able to perform, without difficulty, discrete oral movements such as puckering, opening her mouth or sticking out her tongue. However, she had difficulty performing sequential combinations of these movements. She was able to perform isolated left-hand movements such as open palm, make fist, spread fingers, but her ability to combine these motor acts in a sequence was impaired. For example, she was unable to perform the sequence 'flat, fist, edge of palm' with her non-paretic hand although she could perform each individual position well. Stereognosis was intact in her left hand and absent in her right hand. Optokinetic nystagmus was present in both directions. No visual field defects were detected and no hemi-inattention was observed. Visual acuity was 20/20, right eye and 20/30, left eye.

Neurological evaluation at six weeks post-onset demonstrated clear improvement. Sensory examination to primary modalities showed recovery in her right hand. She had return of stereognosis, although objects still felt 'different' in her right hand. She was now able to move the fingers of this hand against gravity. She performed at 100 per cent accuracy on the Ishihara colour plates. Audiograms performed at this time revealed no response up to 115 dB in both ears.

A CAT scan performed the day after admission revealed a low density lesion in the left anterior parietal lobe in the region of the supramarginal and angular gyri. The combination of CAT scan

findings, right arm paresis, and severe primary somatosensory loss indicated that the lesion involved or undercut areas 4, 3, 1 and 2 in addition to areas 39 and 40 (Gado, Hanaway and Frank 1979; Gonzales, Grossman and Palactos, 1976; Mazzocchi and Vignolo, 1978, 1979; Naeser and Hayward, 1978). A repeat CAT scan done at ten weeks post-stroke (*see* fig. 2) confirmed the left parietal localization and revealed an anterior slit-like subcortical extension under areas 4, 3, 1 and 2 not seen on the initial CAT scan. The inferior frontal operculum (areas 44 and 45) and the posterior superior temporal plane (areas 41, 42 and 22) were spared by the lesion.

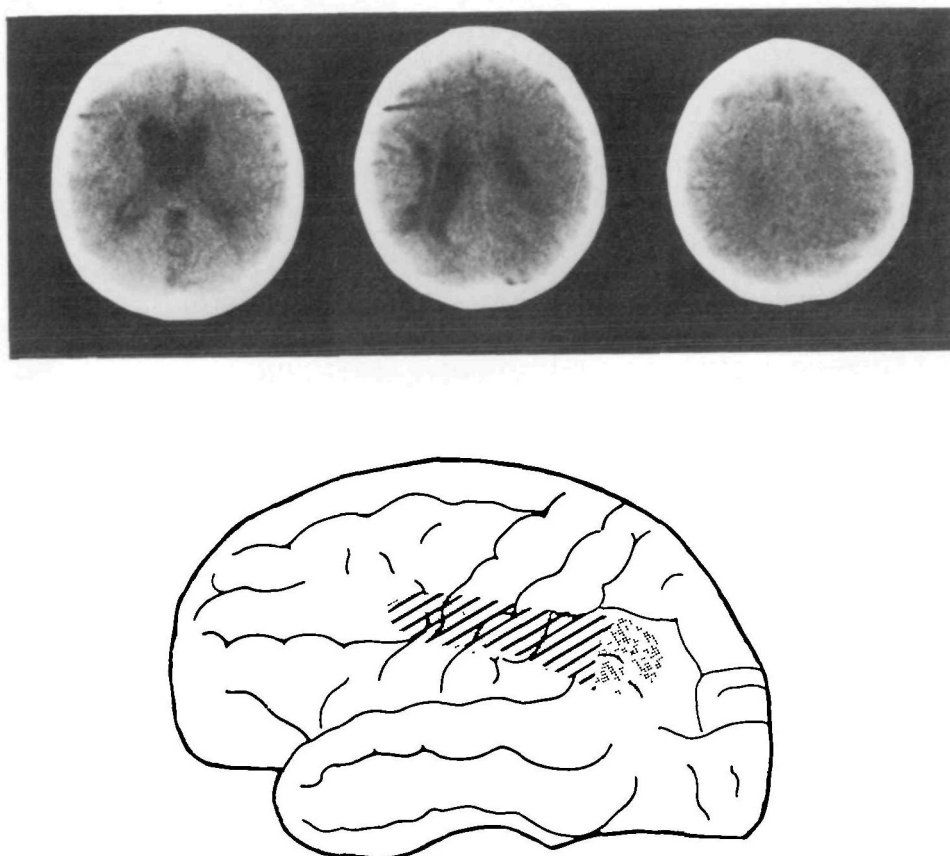


FIG. 2. CAT scan ten weeks after onset with lateral reconstruction of lesion. There is clear definition of the left parietal lesion (dots only). Note the slit-like anterior subcortical extension under the pre- and postcentral gyri (diagonal lines and dots). The lesion is not apparent on cuts immediately above or below.

Initial Language and Neuropsychological Assessment

Aphasia testing five days after admission showed the patient unable to perform two-part ASL commands accurately. Attempts to provoke spontaneous signing by questions about her childhood, friends, or pictures of simple scenes mainly produced a reiteration of the question or I-DON'T-KNOW. She had a severe

anomia in both ASL and finger-spelling for objects or pictures of objects, and could only produce the signs for 2 of 11 test items. Her usual response was I-DON'T-KNOW, although twice a gesture was given instead of a sign. When shown a picture of wine, the patient produced an uninterpretable sign (hand in front of mouth, fingers straight and parallel, pointing to side, palm down, repeatedly bringing extended fingertips to thumb), which consists of standard ASL formational parameters in a novel combination. She perseverated on this response frequently throughout the rest of the test session. L.K. could imitate signs she could not produce spontaneously, and could sometimes indicate what the test objects were used for. However, when given a choice of photographs of signs she could not select the depicted sign which represented the actual object. She could not name colours in either ASL or finger-spelling, although when asked in ASL to point to blue, red, or yellow she did so correctly.

The patient was unable to finger-spell the names of any of the test items, but could finger-spell her first name. She could not match an object to the correct printed word from a list of 3 or 4 words. However, she was able to give the correct sign for a few of the printed words, or produce a semantic paralexia (DRINK (signed incorrectly with closed fist) for *water*, ORANGE for *banana*) in some cases. The patient could count to 12 spontaneously. Her digit span, using signed response, was three. During this session, some vocalizations were noted, but they were not articulate, consisting mainly of simple phonation.

At two weeks post-onset, the patient's output of sign had noticeably increased, although it remained severely impaired. Her spontaneous expression still contained a great deal of gesturing rather than signing, and many signs were misarticulated. She was unable to recite the days of the week or the Lord's Prayer. She attempted to shadow the Lord's Prayer, but was unable to keep up with the experimenter, omitting many signs and mispronouncing others.

On an ASL sentence repetition task, single sign sentences were repeated correctly, but the patient made several articulatory errors on 2-sign sentences. On 3- and 4-sign sentences only 2 signs at best were repeated. Grammatical modulations were generally preserved in the patient's (often incorrect) responses. For example, L.K. repeated MAN KEEPS-ASKING-ME-QUESTIONS as MAN KEEPS-DRINKING-LIQUOR. The latter has a handshape similar to the stimulus sign and a simpler movement.

Articulatory errors, occurring both spontaneously and during repetition, often involved substitution of a hand configuration, place of articulation, or movement feature. SIN, for example, was mispronounced with a palm-in flat hand (instead of pointing hand) circling in front of the face (instead of the chest). Such errors appear to be literal paraphasias.

A marked anomia was still evident for ASL, finger-spelling, and written responses. The patient could write her first and last names, copy from a written sample, and write a simple sentence to ASL dictation. However, she was unable to finger-spell her last name correctly, and could not finger-spell any items in

confrontation naming. She could finger-spell from a written sample, but could not provide the ASL equivalents for the same printed words. On Marie's Three Papers Test (ASL), the patient could only perform the first of the three commands. Repeating the instructions resulted in the same response. Little vocalization, none of it articulate, occurred during this session.

The patient could demonstrate how 3 of 4 objects shown to her were used. Sequential movement copying ('flat, fist, edge of palm' sequence) was impaired. Digit span was 2. Nonverbal visual sequential memory span, as tested by the Knox Cube Test (Inglis, 1957), was 3. The patient could not add simple sums (written response), and had difficulty providing signs for written numbers.

L.K. was able to copy shapes (square, circle, Greek cross) and could copy block designs of up to 8 blocks. She correctly pointed to specific places on an outline map of the United States.

In summary, the patient's initial aphasia was characterized by a greatly reduced sign output, severe anomia and the production of literal and verbal paraphasias. Although ASL comprehension was not systematically assessed, some comprehension impairment was apparent in the patient's difficulty in grasping test instructions and inability to carry out 2- or 3-part commands. Finger-spelling, except in the presence of a written English stimulus, was impossible. No articulate vocalizations were present at this time. At least some reading and writing skills were preserved. In addition, there was deficient movement copying, reduced verbal and nonverbal visual memory span, and acalculia.

FURTHER LANGUAGE AND NEUROPSYCHOLOGICAL TESTING

The patient was available for more extensive testing between five and seven weeks following her stroke. During this period she was alert, gregarious, and extremely co-operative. She was aware of her linguistic problems, but was not very frustrated by them. Signing and writing were still carried out exclusively with the left hand.

Our assessment included tests of each of the patient's language systems (ASL, finger-spelling, and written English), as well as nonlinguistic gesture and verbal and nonverbal short-term memory. Testing was always conducted at the same time of day (a.m.), and with the assistance of a certified sign language interpreter. Sessions were videotaped for later analysis. All test instructions were given in ASL, and elaborated with pantomime if necessary.

Language Assessment

The language investigation was modelled after, but not limited to, the Neurosensory Center Comprehensive Examination for Aphasia (Spren and Benton, 1969). However, since test items were frequently modified to accommodate the structure of ASL, reference to the standard scoring procedures and norms is not appropriate.

1. *American Sign Language*

(a) *Production-Articulation*. Stimuli for this test comprised 86 ASL signs and 10 nonsense signs. The former were selected to represent all the known distinctive manual elements of ASL. Of the nonsense signs, 5 were composed of standard ASL parameters and could easily be signs, but in fact are meaningless, like the syllable 'blick' in English (Chomsky and Halle, 1968). The other 5 were constructed so as to be deviant or impossible as ASL signs (compare 'bnick', which could never be an English word). The patient was instructed to copy each sign as modelled by the interpreter. We made no special effort to limit the test to one-handed signs, having noted L.K.'s means of accommodation to her right hand paresis. Her previously nondominant hand assumed the active signing role. She used a tabletop or her paretic right hand as a substitute for the passive base hand in most signs requiring only one active hand (*see* Appendix). Two-handed symmetrical signs, in which both hands normally move, were simply 'halved'.

Overall performance on this test was quite good. Only three errors occurred in the patient's copying of actual signs: MORON and BIRD were copied with an improper hand orientation (fingertips pointing sideward, rather than facing toward (MORON) or away from (BIRD) the signer); OVERSLEEP was reproduced with an inappropriate contact and place of articulation (forehead), and downward (rather than upward) movement. All 5 of the possible nonsense signs ('blicks') were copied without error or hesitation. In contrast, 3 of the 5 impossible signs ('bnicks') were reproduced incorrectly (one of these was later self-corrected). In these cases, L.K.'s 'errors' involved changes in the direction of ASL phonology. That is, impossible signs were reproduced as possible or actual signs (analogous to changing 'bnick' into 'blick' or 'brick'). For example, a nonsense sign which involved a deviant contact and movement (flat hand, fingers together and palm down, taps chest with thumb-index edge; wrist and knuckles bend so fingers point down, then tap again) was reproduced with the contact and movement of an actual sign (TIRED, not in the test). Unimpaired signers show a similar normalizing tendency when imitating foreign signs (Coulter, 1974).

Visual Naming. Ten objects were presented for naming. Although L.K. was asked to provide the ASL sign, she often attempted to finger-spell the name as well. Six of the objects (ring, flowers, paper, fork, rope, umbrella) were named correctly in ASL, the first 4 of these also being correctly finger-spelled. In one case (cup), only the finger-spelled name could be produced. A thermometer elicited a gesture which could be interpreted as 'it goes up'. When shown a padlock L.K. finger-spelled L-O-C-K, but gave the sign TO-LOCK (as a door) which can only be used correctly as a verb. Finally, a parallel naming error in ASL and finger-spelling occurred to the stimulus object bottle:

L.K.: P-
 'you drink from it'
 P-O-P-L-

'that's wrong' . . . 'I've really forgotten—
I can see it and I know what it is'

L-K-P-A-

'I can't remember'

Interpreter: 'what's the sign?'

L.K.: SODA-POP

Interpreter: 'another sign?'

L.K.: 'drinking, drink, I've forgotten'

SODA-POP

Colour Naming. L.K. succeeded in producing ASL colour names with 100 per cent accuracy.

Description of Object Use. Ten objects (different from those used for naming) were presented to the patient, and she was asked to describe their use. She provided adequate sign descriptions for all objects.

Sentence Construction. The patient was shown 2 or 3 signs and instructed to form a sentence with them. Her responses were grammatical and appropriate. However, in 2 of the 5 sentences L.K. omitted one of the stimulus signs in her response. Some misarticulations resembling literal paraphasias were also noted. WRITE, for example, was articulated with improper extension of the fingers (a different ASL handshape).

Sentence Repetition. The stimulus set for this test contained 17 phrases and sentences of increasing length (1 to 10 signs) and grammatical complexity. The latter included the addition of dependent clauses and aspectual (habitual or continuous action) and indexical (subject, object) inflections.

L.K. repeated the first 5 stimuli (those composed of one or two signs) correctly. Only one of the longer sentences was copied even approximately correctly, with omission of at least one sign from each such sentence, as well as mispronunciations, hesitations, uninterpretable gestures, and perseverative errors. For example, she repeated MANY BLACK CAT ('many black cats') as BLACK (incorrect handshape) CAT. As the stimuli grew in length and complexity her responses were more and more garbled, seeming to be rearrangements of some remembered signs, often fleshed out with signs that had not been in the stimulus, but were semantically related and enabled the patient to construct a more or less coherent response. For example, the stimulus

MY FRIEND BRING-ME TWO NEWSPAPER 'My friend brought me two newspapers' was repeated as

?FRIEND ?MOVE-TO-ME NEWSPAPER ?SUBSCRIBE NEWSPAPER
BRING-ME gesture NEWSPAPER

This response is not interpretable as a sentence. It should be noted that, as in the earlier test of sign and phrase repetition, grammatical modulations were not lost. There was also a tendency for information which occurred near the end of the longer sentences to be preserved in the patient's responses.

Practised Sequences and Spontaneous Signing. L.K. was now able to recite the days of the week, with some hesitation. She attempted to sign the Lord's Prayer and could recall fragments of it, but was unable to recite the entire prayer.

The patient's spontaneous signing, during conversation or in interview, was described (by J.L.) as fluent, but somewhat vague and circumlocutory. This interpreter felt that she had to rely more on contextual information to understand the patient than was the case before her stroke. L.K. used indexical pronouns inconsistently in her narrative signing. In some cases she neglected to establish (*via* spatial placement) the referents for such pronouns. She was still using gestures (as opposed to signs) to a greater extent than she had pre-stroke, and misarticulated signs were not uncommon. Her characteristic garrulousness had returned. The patient frequently vocalized concurrent with signing, and many of the vocalizations now exhibited syllabic structure. However, as was the case pre-stroke, these were not interpretable and did not enhance her ability to communicate.

(b) *Comprehension-Identification by Name.* The patient could recognize the ASL names of all objects and colours used in the previously described naming test. She responded, without hesitation, by pointing to the correct object/colour from an array of items.

Token Test. The Spreen and Benton (1969) version of this test (39 items) was administered in ASL. Almost no modification of the standard procedure was necessary; scoring follows the weighted method of Spreen and Benton (1969), which awards credit for partially correct responses.

The patient's score on each of the subsections is indicated in Table 1A. It is evident that performance breaks down on those parts (E and F) which are highest in mnemonic and grammatical complexity. The total score would place L.K. in the bottom third of hearing aphasics who were given this version of the Token Test (Spellacy and Spreen, 1969), and indicates a substantial comprehension deficit.

Verbal Commands. The patient was able to perform two- but not three-part commands (Boston Diagnostic Aphasia Exam (Goodglass and Kaplan, 1972) and Marie's Three Papers Test). She had difficulties with left/right commands.

Story Comprehension. Four stories, adapted from a primary school reading test (Gates, 1958), were presented in ASL. Following each, L.K. was asked a series of yes-no questions, based on the story. She answered about 75 per cent of these questions correctly. Performance was unrelated to story length. The patient sometimes tended to base her answers on real-world knowledge rather than actual story content.

2. *Finger-spelling*

L.K. could now finger-spell her first and last names, but only fragments of the manual alphabet spontaneously (A-B-C-D-E-L-M-N-O-P ...). A series of line drawings and colours were presented to her to finger-spell. The former items were selected to encompass a range of spelling difficulty, the most difficult being spellable

by 99 per cent of ninth-graders (Buckingham, no date). Approximately one-third of her responses contained errors. In many such instances, however, she could provide the correct sign. Errors were most often misspellings (P-A-N-C-E for fence) or perseverations. The latter included intra-word repetitions (P-I-N-K-K) and intrusions from earlier items (M-A-N for monkey). In one case the patient appeared to carry over a handshape from ASL into finger-spelling. (Some ASL handshapes also occur as letters in the finger-spelling system. However, there is normally no relationship between the ASL signs in which such handshapes occur, and the spelling of the corresponding English words (Klima and Bellugi, 1979).) When shown a drawing of an Indian, she produced the correct sign (using the 'F' handshape, index finger and thumb opposed, other fingers extended) several times and then spelled F-A-I-N. Jargon responses were occasionally given (L-A-L-A-Y for suitcase). In general, however, L.K. appeared to have at least partial knowledge of the target's spelling.

When given the finger-spelled name for the same test items, L.K. always selected the appropriate drawing or colour. Finger-spelling from a written sample was much better than confrontation naming, with only occasional perseverative errors occurring.

TABLE 1. ASL AND READING COMPREHENSION TEST PERFORMANCE

A. Token Test

<i>Part</i>	<i>Sample item</i>	<i>Score</i>	
		<i>ASL commands</i> (5/5/80)	<i>Written commands</i> (5/9/80)
A	Show me a circle	7/7	7/7
B	Show me the yellow square	8/8	8/8
C	Show me the small white circle	11/12	10/12
D	Take the red circle and the green square	14/16	12/16
E	Take the large white circle and the small green square	12/24	16/24
F	Put the red circle on the green square	40/96	—
Total score		92/163	53/67

B. Reading Comprehension Battery for Aphasia (5/5/80)

<i>Subtest</i>	<i>No. correct</i>
Word Recognition	
Visual Confusions	9/10
Auditory Confusions	9/10
Semantic Confusions	9/10
Sentence Comprehension	9/10
Short Paragraph Comprehension	5/10

3. *Written English*

(a) *Writing*. L.K. could write her first and last names legibly. When asked to write the alphabet, she omitted several letters.

Written naming was assessed using the same stimuli as in the finger-spelling task. Less than half of the patient's responses can be considered adequate. Perseverative errors, either of letters, word fragments, or entire 'words', and/or misspellings were common, sometimes entirely obliterating any relation to the target word. For example, a drawing of an umbrella elicited *ummberr*, the next stimulus, bicycle, was written *gmber*. Many responses were elaborated. These might include the target word (fig. 3A, stimulus 'house'), an incorrect version of the target (fig. 3B, 'Indian'), or bear some type of relation to the target (fig. 3C, 'fence'). In some cases the patient provided the correct sign for stimuli which elicited agraphic responses, and in general demonstrated an awareness of her errors.




FIG. 3. Written Confrontation Naming. A: house; B: Indian; C: fence.

The sentence construction test which had previously been administered in ASL, was given with the stimulus words printed on cards and written response required. For the first three test items, L.K. wrote sentences devoid of paraphasias, but which seemed to follow ASL rather than English grammar (fig. 4A, stimuli *rain*, *cold*). The final two sentences in the test contained paraphrastic errors, and were so contaminated by words from the earlier sentences, as to be uninterpretable according to the grammar of either language (fig. 4B, stimuli *hair*, *water*, *girl*).

A rain all time cold

B
~~A~~
 fair
 hair morning
 water is drink drink

FIG. 4. Sentence Construction. A: stimuli *rain, cold*; B: stimuli *hair, water, girl, Morning* and *drink* had appeared in the previous sentence.

Writing to Dictation. A series of 10 words were dictated in finger-spelling. L.K. wrote 4 correctly. Errors were predominantly letter substitutions and/or perseverations from previous words. None of the former appeared attributable to finger-spelling confusions.

L.K. was able to write single words to ASL dictation. Sentences of 3 to 5 signs were also dictated. The only 3-sign sentence (MY SISTER PRETTY) was written in grammatical English (*my sister is pretty*). Longer sentences contained misspellings, word omissions, and what appear to be attempts to partially reconstruct stimulus information (fig. 5). Words occurring at the end of the signed sentences were more likely to appear in the patient's responses.

A I amyo children

B I watch at TV

FIG. 5. Writing to ASL dictation. A: ME HAVE TWO CHILDREN; B: NOW MORNING ME WATCH TV.

(b) *Reading*. Several subtests of the Reading Comprehension Battery for Aphasia (La Pointe and Horner, 1979) were administered, testing word, sentence and short paragraph comprehension. L.K. was 90 per cent correct on the word and sentence subtests (Table 1B). It should be noted that the sentence subtest items primarily tested comprehension of a single target word. When the information processing load increased (short paragraph comprehension), L.K.'s reading comprehension deteriorated (Table 1B). The most difficult paragraphs in this subtest were at the 4th grade reading level (La Pointe and Horner, 1979).

The Token Test was readministered using written commands. L.K. read the command, then the written stimulus was withdrawn, and she made a response. She was unable to follow this procedure, however, for the final subpart of the test. The results of the other subsections (Table 1A) indicate a comprehension level comparable to that in ASL.

Summary of Language Data

At five to seven weeks post-onset, L.K.'s signing was relatively fluent, with improved articulation, although paraphasias (mainly literal) were evident. Moderate anomia was present. There was a marked repetition deficit. ASL comprehension was intact at the single sign level, but broke down as mnemonic and grammatical complexity increased. Finger-spelling was at least as impaired as signing. A definite agraphia was present under all test conditions. Reading comprehension paralleled ASL comprehension, with impairment appearing at higher levels of linguistic complexity. The patient's vocalizations had returned to the pre-stroke level, at times being articulate, though uninterpretable.

Nonlinguistic Gesture

Apraxia Testing. A lengthy series of limb and facial movements were demonstrated for the patient to imitate. These included nonrepresentational (for example, placing hand behind head), intransitive (for example, saluting), and transitive (for example, hammering) movements (Brown, 1972). L.K.'s reproductions of these were accurate. We also assessed the patient's manipulation of actual objects (comb, screwdriver, etc.). In all cases, she demonstrated the object's use appropriately, and without hesitation. Since many ASL commands to perform an action (BRUSH-TEETH) are quite similar to the actual movements themselves (brushing one's teeth), it was not feasible to test the patient's praxis to verbal command. There was no evidence for an ideational apraxia (Brown, 1972). L.K. could, for example, fold a piece of paper, place it in an envelope, seal, and stamp it.

Movement Copying. The finger flexion and manual movement copying tests described by Kimura (Kimura and Archibald, 1974; Kimura *et al.*, 1976) were administered. L.K.'s finger flexion was normal. However, a severe impairment of movement copying was evident for 2 of the 5 sequences. Even with 3 consecutive attempts at these, L.K.'s copies were deficient. There were errors in hand posture,

orientation, place of contact, direction of movement, and number of movements. Sequencing errors *per se* (correct movements in incorrect order) were not noted.

The patient's reproduction of the 'flat, fist, edge of palm' sequence, which by now had been tested innumerable times, was still impaired. She tended to perseverate on hand postures and had great difficulty in switching from one posture to the next in the sequence. L.K. could, however, copy rhythmic hand-tapping sequences which did not involve changes in hand postures, and easily learned to tap once whenever the experimenter tapped twice, and *vice versa*.

Pantomime Comprehension. We devised a test of simple pantomime and gesture comprehension, similar to that of Gainotti and Lemmo (1976). The interpreter pantomimed the actions (for example, aiming and firing a pistol) using postural stances and body movements so as to be maximally distinct from the signs for the actions. The patient then selected, from a set of three drawings, the one which was related to the pantomime. One of the distractor drawings was associated in some way with the correct drawing (knife/pistol), but unrelated to the gesture or pantomime. L.K. erred on only one of the nine actions, selecting a drawing of a judge after having seen the interpreter stand at attention and salute.

Short-term Memory

The patient's digit span, with stimulus and response in ASL, was 3. Performance did not improve when the signed stimulus was reported by pointing to written numbers. In fact, under these conditions, she only achieved a digit span of 2. Although digit spans reported for deaf adults are typically lower than those for the hearing population (Olsson and Furth, 1966), this patient's performance seems depressed.

Nonverbal visual sequential memory span was assessed by the Knox Cube Test (Inglis, 1957). This test requires the subject to reproduce a tapping sequence on four blocks. Score is the longest sequence correctly copied. L.K.'s span was 4 on one administration and 3 on retesting two days later. Inglis (1957) reports a mean score of 4.25 for his elderly control subjects on this test.

Calculation

L.K. could carry out written calculations involving the addition, subtraction, or multiplication of one-digit numbers. However, she was unable to perform correctly more complex calculations which involved carrying over digits. We could obtain no information about her mathematical competence prior to her stroke, other than the fact that she had maintained her checkbook.

DISCUSSION

The aphasic sequelæ of a left parietal infarct in a deaf user of American Sign Language are consistent with what is known about aphasia in hearing populations and with the structure of ASL. Initially, the patient's nearly global aphasia was characterized by impoverished signing, severe anomia, literal and verbal paraphasias, impaired comprehension and an almost total loss of finger-spelling. By five to seven weeks post-onset expressive skills had improved, leaving the patient with a pattern of symptoms similar to that of hearing aphasics with posterior lesions: fluent signing with circumlocutions and (predominantly literal) paraphasic errors, anomia (less severe in ASL than in written English), impaired repetition, comprehension difficulties (for both ASL and written English), and agraphia. The associated findings of reduced short-term verbal memory and impaired movement copying are also frequently present with aphasia for spoken language (Albert, 1976; Heilman, Scholes and Watson, 1976; Kimura and Archibald, 1974; Mateer and Kimura, 1977).

Before discussing the issues raised by the present case, we will consider whether L.K.'s impaired signing might be traceable to motor imprecision or an apraxia. It might be expected that the patient's reliance on her nondominant hand for signing would entail articulatory difficulties. However, normal signers frequently use their nondominant hand in the active signing role for grammatical or stylistic reasons (Frishberg, 1979), and are accustomed to signing one-handed when tired, or when one hand is occupied with driving, carrying, etc. (Battison, 1974). It seems unlikely, then, that one-handed signing with the non-dominant hand, in and of itself, would have engendered many misarticulations. In addition, we observed that the patient's articulatory errors were no more likely to occur on two-handed than on one-handed signs. L.K.'s normal finger flexion and manual dexterity with handling objects in her left hand also suggest that adequate digital mobility was present.

The types of articulatory errors made by L.K. conform to the formational structure of ASL signs and resemble the speech errors of oral aphasic patients. It has been noted that aphasic errors tend to be substitutions of those sounds which are more frequent and less distributionally restricted, for sounds which are less common and more restricted in their occurrence (Blumstein, 1973). L.K.'s misarticulated signs, likewise, often involved the substitution of a common neutral handshape ('B', '5', 'G', 'O'), or were displaced to the mouth/lower face area, which is the most frequent place of articulation (Battison, 1978). Most of the patient's misarticulated signs can be analysed as the substitution, perseveration, or anticipation of one or more ASL formational parameters: handshape, place of articulation, movement, and orientation. Since they occurred in the midst of fairly fluent signing it seems reasonable to regard them as literal paraphasias.

Most previous investigators of sign language aphasia have remarked on the absence of apraxia (Critchley, 1938; Tureen *et al.*, 1951; Douglass and Richardson, 1959; Sarno *et al.*, 1969; Meckler *et al.*, 1979). L.K. was not apraxic as that disorder

has traditionally been defined. However, there was a definite impairment in her ability to copy unfamiliar movement sequences. A similar dissociation was reported in another aphasic signer (Kimura *et al.*, 1976). As mentioned earlier, L.K.'s movement copying errors were not attributable to a serial ordering difficulty, but rather to an inability to carry out smooth transitions between movements or to achieve a correct target posture when embedded in a complex sequence. Similar difficulties characterize the oral sequential movement copying of fluent hearing aphasics (Mateer and Kimura, 1977). Whether L.K.'s aphasia can be reduced to a sequential motor apraxia is debatable since the language comprehension deficit would be difficult to account for under this theory. The rule-governed nature of the patient's articulatory errors and their occurrence in a matrix of generalized linguistic disruption suggests to us an aphasic rather than an apraxic origin. It is probably advisable to consider the impaired movement copying as an associated finding in the absence of firm evidence to support its inherent relationship to aphasia (either oral or manual).

The presence of 'gestures' noted during L.K.'s signing requires comment. By this is meant any manual activity occurring during the patient's signing which was not interpretable as a sign or even a misarticulated approximation to a sign. Many of these (particularly those appearing within the first two weeks of her stroke) were fairly gross gestures lacking the expected internal structure of ASL signs, and imparting little specific information to the examiner. It is impossible to ascertain whether they represent attempted signs which were so degraded as to be unrecognizable, or some extralinguistic attempt to communicate. Occasionally, L.K.'s 'gestures' seemed to be more mimetic and occurred in contexts in which standard ASL signs would have been more appropriate. For example, on one occasion L.K. pantomimed pouring milk into coffee and stirring it, rather than providing an ASL sentence as requested. In several instances gestures of this type were replaced by ASL signs as the patient showed recovery. It should be noted that signers sometimes incorporate pantomimed sequences in their narrative signing. Such mimetic gestures, however, were more frequent in the patient's signing at five to seven weeks than they had been before her stroke.

Can any of the 'gestures', be considered instances of neologistic jargon? Since jargon-like responses were noted in L.K.'s written naming (*see* fig. 3) and to a lesser extent in finger-spelling, this would seem a likely possibility. We would expect a neologistic sign to conform to ASL formational structure conditions, but to be meaningless and unrelated to any sign expected in context (Buckingham and Kertesz, 1976). With one exception (a pseudo-sign used perseveratively by L.K. during an early testing session) it was the opinion of fluent signers that L.K.'s spontaneous signing was devoid of any neologisms. Occasionally when attempting to recall a sign, the patient would grope for the word, producing intermediate 'signs', of which some might be uninterpretable and bear no relation to the target sign. However, these intermediate gestures were never used in her spontaneous signing. The absence of sign neologisms suggests that their occurrence might be dependent

on a disruption of the sequential aspect of word structure not present in ASL. If we assume, however, a continuum between paraphasia and neologistic jargon (Kertesz and Benson, 1970; Brown, 1972) the more jargon-like responses for English (written and finger-spelled) in the present case may only reflect a quantitatively greater disruption of those systems which were less well-established premorbidly. In-depth studies of other aphasic signers with varying degrees of competency in written and/or finger-spelled English are needed to resolve this issue.

Disturbances of pantomime and gesture comprehension have been shown to occur with aphasia for spoken language (Gainotti and Lemmo, 1976; Seron, Van Der Kaa, Remitz and Van Der Linden, 1979). However, our patient performed rather well on such a test, despite deficits in ASL and reading comprehension. The greater redundancy of the relatively simple pantomimed sequences probably contributed to her better performance. L.K.'s sign comprehension was poorer for low redundancy commands (Token Test) than for connected texts (story comprehension). The relative preservation of pantomime (perception and production) in this patient may also indicate that these two forms of gestural communication are neurolinguistically separable.

With respect to behavioural-anatomical correlations, this case supplies further clinical evidence for a left hemisphere predominance for sign language. It would appear that the left hemisphere provides an essential substrate for the processing of a visual/gestural language, despite the equivocal lateralization results obtained from experiments using normal signers (Manning *et al.*, 1977; McKeever *et al.*, 1976; Poizner *et al.*, 1979; Poizner and Lane, 1979).

This patient's comprehension deficit was associated with a lesion which spared the posterior superior temporal plane. Studies correlating CAT findings with aphasia typically report involvement of the left posterior temporal-parietal region for fluent aphasias with impairment of spoken language comprehension (Naeser and Hayward, 1978; Kertesz, Harlock and Coates, 1979; Mazzocchi and Vignolo, 1979). This patient's lesion location fits better with reported cases of conduction aphasia (Benson, Sheremata, Bouchard, Segarra, Price and Geschwind 1973; Mazzocchi and Vignolo, 1979). The patient did have a severe repetition disorder with spontaneous sentence length being longer than the ability to repeat, but her comprehension is more impaired than reported cases of conduction aphasia. Comprehension disorders have been associated with subcortical lesions, particularly those involving the left putamen and thalamus (Naeser and Hayward, 1979; Alexander and LoVerme, 1980). However, this patient's subcortical involvement is rostral to that reported in these cases.

Based on the clinical constellation of left parietal deficits and the CAT scan findings, we suggest that the left supramarginal and angular gyri comprise the critical regions needed for linguistic decoding of sign language. Leischner (1943) made a similar suggestion. However, his patient's lesion also involved the left posterior superior temporal plane and subcortical structures in the right hemisphere

as well as the uncus. The present case more precisely delimits the cortical areas critical for sign language comprehension to the left parietal region.

In conclusion, we found the most striking behavioural finding in this case to be the fundamental similarity of L.K.'s symptoms to those of oral aphasic patients. While further studies will undoubtedly uncover some aphasic features unique to the gestural modality, our results indicate that many important aspects of the neural mechanisms of language are not modality-dependent, but are related to processes shared by all human languages.

SUMMARY

A left parietal infarct in a prelingually deaf person resulted in an aphasia for both American Sign Language (ASL) and written and finger-spelled English. Originally the patient had a nearly global aphasia affecting all language systems. By five to seven weeks post-onset her symptoms resembled those of hearing aphasics with posterior lesions: fluent but paraphasic signing, anomia, impaired comprehension and repetition, alexia, and agraphia with elements of neologistic jargon. In addition, there was a pronounced sequential movement copying disorder, reduced short-term verbal memory and acalculia. In general, the patient's sign errors showed a consistent disruption in the structure of ASL signs which parallels the speech errors of oral aphasic patients. We conclude that most aphasic symptoms are not modality-dependent, but rather reflect a disruption of linguistic processes common to all human languages.

This case confirms the importance of the left hemisphere in the processing of sign language. Furthermore, the results indicate that the left supramarginal and angular gyri are necessary substrates for the comprehension of visual/gestural languages.

ACKNOWLEDGEMENTS

This study was made possible by the enthusiastic participation of a number of people. We thank: Dr Jamil Sulieman for referring the patient to us; Jennifer Lane and Bobbe Skiles for their skilful interpreting; Ursula Bellugi, Ben Bahan, and Jennifer Lane for sharing their ideas and expertise in American Sign Language with us; Dr Robert Efron and Dr R. Conrad for helpful comments, Dr Brown and the staff of Fairmont Hospital for facilitating this research; Ann Juell (Educational TV, UCB) and Vic Harke (Health and Medical Sciences, UCB) for lending technical support and equipment; Beate Lewis for translation assistance; Bette Laccoarce for preparation and editing of the manuscript; Meredith Hoffman for help in obtaining funding; and finally, L.K. for her unflagging good humour and co-operation throughout the study. This research was partially supported by Biomedical Sciences Support Grant 1-44212032061.

APPENDIX: SOME ASPECTS OF ASL STRUCTURE

Signs in ASL have a conventionalized internal structure (Stokoe, 1978; Stokoe, Casterline and Croneberg, 1965/1976; Friedman, 1977a). Only some of the physically possible manual articulations are used to form lexical items (Friedman, 1977a). Every sign involves the simultaneous expression of a specific handshape, place of articulation, movement, and orientation (direction of palm and fingers) feature. These formational parameters in isolation have no meaning; they are actually sets of the articulatory primes which combine in certain restricted ways (Battison, 1978) to form meaningful units. In this way they are somewhat analogous to phones in a spoken language, although we must emphasize that they occur in parallel and not in a linear sequence. For example, in the sign BLACK the index finger is extended from the fist (handshape), with palm facing down and the index finger pointing to the side (orientation), pulling laterally (movement) across the forehead (place of articulation).

Some signs (approximately 40 per cent, according to the count of Klima and Bellugi, 1979) require the use of only one hand. Others are two-handed. These can be of two types (Battison, 1974): (1) both hands have identical handshapes and are active, making the same type of movement (about 35 per cent are of this symmetrical type); (2) only the signer's dominant hand moves; the other hand acts as a passive base for the articulation of the sign. The passive base hand either has the same hand configuration as the active hand, or assumes one of six simple handshapes.

ASL predicates can be inflected to express a variety of aspectual (habitual, repeated, or intense action) and deictic (source, goal, or place of action) modifications (Klima, Bellugi and Pedersen, 1979; Klima, Bellugi, Newkirk, Pedersen and Fischer, 1979; Fischer and Gough, 1978). While spoken languages typically inflect words by attaching a grammatical marker before or after the stem of the word, ASL inflections are generally formed by changing the movement or some other formational parameter of the stem sign itself. Several such inflections can be applied to a single sign; they are all present simultaneously when the sign is pronounced. There is no temporal division between the stem sign and its inflectional marker(s) (Ellenberger, 1977). Separate function words (such as *the, of, is*) do not occur in ASL.

We have only mentioned those structural properties relevant to the data we are presenting. Several studies of ASL grammar are available (Klima and Bellugi, 1979; Wilbur, 1979; Friedman, 1977b; Siple, 1978).

REFERENCES

- ALBERT, M. L. (1976) Short-term memory and aphasia. *Brain and Language*, 3, 28-33.
- (1979) Alexia. In: *Clinical Neuropsychology*. Edited by K. M. Heilman and E. Valenstein. New York: Oxford University Press.
- ALEXANDER, M. P. and LOVERME, S. R. (1980) Aphasia after left hemispheric intracerebral hemorrhage. *Neurology, Minneapolis*, 30, 1193-1202.
- BATTISON, R. (1974) Phonological deletion in American Sign Language. *Sign Language Studies*, 5, 1-19.
- (1978) *Lexical Borrowing in American Sign Language*. Silver Spring, MD: Linstok Press.
- BENSON, D. F., SHEREMATA, W. A., BOUCHARD, R., SEGARRA, J. M., PRICE, D. and GESCHWIND, N. 1973. Conduction aphasia. *Archives of Neurology, Chicago*, 28, 339-346.
- BLUMSTEIN, S. E. (1973) *A Phonological Investigation of Aphasic Speech*. The Hague: Mouton.
- BROWN, J. W. (1972) *Aphasia, Apraxia and Agnosia*. Springfield: Charles C. Thomas.
- BUCKINGHAM, B. R. No date. *Buckingham Extension of the Ayers Spelling Scale*. Bloomington: Public School Publishing Co.
- BUCKINGHAM, H. W. and KERTESZ, A. (1976) *Neologistic Jargon Aphasia*. Amsterdam: Swets and Zeitlinger, p. 85.
- BURR, C. W. (1905) Loss of the sign language in a deaf mute from cerebral tumor and softening. *New York Medical Journal*, 81, 1106-1108.

- CHOMSKY, N. and HALLE, M. (1968) *The Sound Pattern of English*. New York: Harper and Row, pp. 380-382.
- COULTER, G. (1974) Accent. Salk Institute Working Paper (unpublished).
- CRITCHLEY, M. (1938) 'Aphasia' in a partial deaf-mute. *Brain*, **61**, 163-169.
- (1970) *Aphasiology and Other Aspects of Language*. London: Edward Arnold.
- DEJERINE, M. J. (1892) Contribution à l'étude anatomo-pathologique et clinique des différentes variétés de cécité verbale. *Memoires de la Société de Biologie*, **4**, 61-90.
- DOUGLASS, E. and RICHARDSON, J. C. (1959) Aphasia in a congenital deaf-mute. *Brain*, **83**, 68-80.
- ELLENBERGER, R. (1977) Sequential aspects of American Sign Language phonology. Paper presented at Linguistic Society of America, Annual Meeting.
- FISCHER, S. and GOUGH, B. (1978) Verbs in American Sign Language. *Sign Language Studies*, **18**, 17-48.
- FRIEDMAN, L. (1977a) Phonology of a soundless language: Phonological structure of American Sign Language. Unpublished Ph.D. dissertation, University of California, Berkeley.
- (Editor) (1977b) *On the Other Hand: New Perspective on American Sign Language*. New York: Academic Press.
- FRISHBERG, N. (1979) Dominance constraint and dominance reversals in ASL. Paper presented at 54th Annual Meeting of the Linguistic Society of America, Los Angeles.
- GADO, M., HANAWAY, S. and FRANK, R. (1979) Functional anatomy of the cerebral cortex by computed tomography. *Journal of Computer Assisted Tomography*, **3**, 1-19.
- GAINOTTI, G. and LEMMO, M. A. (1976) Comprehension of symbolic gestures in aphasia. *Brain and Language*, **3**, 451-460.
- Gates Basic Reading Tests (Grades 3.5-8)*. (1958) Columbia: Teacher's College.
- GONZALES, C. F., GROSSMAN, C. B. and PALACTOS, E. (Editors) (1976) *Computed Brain and Orbital Tomography*. New York: John Wiley.
- GOODGLASS, H. and KAPLAN, E. (1972) *The Assessment of Aphasia and Related Disorders*. Philadelphia: Lea and Febiger.
- HEILMAN, K. M., SCHOLLES, R. and WATSON, R. T. (1976) Defects of immediate memory in Broca's and conduction aphasia. *Brain and Language*, **8**, 201-208.
- INGLIS, J. (1957) An experimental study of learning and 'memory function' in elderly psychiatric patients. *Journal of Mental Science*, **103**, 796-803.
- KERTESZ, A. and BENSON, D. F. (1970) Neologistic jargon: a clinico-pathological study. *Cortex*, **6**, 362-386.
- HARLOCK, W. and COATES, R. (1979) Computer tomographic localization, lesion size, and prognosis in aphasia and nonverbal impairment. *Brain and Language*, **8**, 34-51.
- KIMURA, D. and ARCHIBALD, Y. (1974) Motor functions of the left hemisphere. *Brain*, **97**, 337-350.
- BATTISON, R. and LUBERT, B. (1976) Impairment of nonlinguistic hand movements in a deaf aphasic. *Brain and Language*, **3**, 566-571.

- KLIMA, E. and BELLUGI, U. (1979) *The Signs of Language*. Cambridge, Mass: Harvard University Press.
- ——— NEWKIRK, D., PEDERSEN, C. C. and FISCHER, S. (1979) The structured use of space and movement: Morphological processes. In: *The Signs of Language*. Edited by E. Klima and U. Bellugi. Cambridge, Mass: Harvard University Press, pp. 272-315.
- ——— and PEDERSEN, C. C. (1979) Aspectual modulations on adjectival predicates. In: *The Signs of Language*. Edited by E. Klima and U. Bellugi. Cambridge, Mass: Harvard University Press, pp. 243-271.
- LA POINTE, L. L., and HORNER, J. (1979) *Reading Comprehension Battery for Aphasia*. Tilgard, Oregon: C.C. Publications.
- LEISCHNER, A. (1943) Die 'Aphasic' der Taubstummen. *Archiv für Psychiatrie und Nervenkrankheiten*, **115**, 469-548.
- MCKEEVER, W. F., HOEMANN, H. W., FLORIAN, V. A. and VANDEVENTER, A. D. (1976) Evidence of minimal cerebral asymmetries for the processing of English words and American Sign Language stimuli in the congenitally deaf. *Neuropsychologia*, **14**, 413-423.
- MANNING, A. A., GOBLE, W., MARKMAN, R. and LABRECHE, T. (1977) Lateral cerebral differences in the deaf in response to linguistic and nonlinguistic stimuli. *Brain and Language*, **4**, 309-321.
- MATEER, C. and KIMURA, D. (1977) Impairment of nonverbal oral movements in aphasia. *Brain and Language*, **4**, 262-276.
- MAZZOCCHI, F. and VIGNOLO, L. A. (1978) Computer assisted tomography in neuropsychological research: A simple procedure for lesion mapping. *Cortex*, **14**, 136-144.
- ——— (1979) Localization in aphasia: clinical-CT scan correlations in stroke patients. *Cortex*, **15**, 627-654.
- MECKLER, R. J., MACK, J. L. and BENNETT, R. (1979) Sign language aphasia in a non-deaf-mute. *Neurology, Minneapolis*, **29**, 1037-1040.
- NAESER, M. A. and CHAN, S. (1980) Case study of a Chinese aphasic with the Boston Diagnostic Aphasia Exam. *Neuropsychologia*, **18**, 389-410.
- ——— and HAYWARD, R. W. (1978) Lesion localization in aphasia with cranial computed tomography and the Boston Diagnostic Aphasic Exam. *Neurology, Minneapolis*, **28**, 545-551.
- ——— (1979) The resolving stroke and aphasia. *Archives of Neurology, Chicago*, **36**, 233-235.
- NEVILLE, H. and BELLUGI, U. (1978) Patterns of cerebral specialization in congenitally deaf adults: a preliminary report. In: *Understanding Language Through Sign Language Research*. Edited by P. Siple. New York: Academic Press, pp. 239-260.
- OLSSON, J. E. and FURTH, H. G. (1966) Visual memory-span in the deaf. *American Journal of Psychology*, **79**, 480-484.
- POIZNER, H., BATTISON, R. and LANE, H. (1979) Cerebral asymmetry for American Sign Language: the effects of moving stimuli. *Brain and Language*, **7**, 351-362.
- ——— and LANE, H. (1979) Cerebral asymmetry in the perception of American Sign Language. *Brain and Language*, **7**, 210-226.

- SARNO, J. E., SWISHER, L. P. and SARNO, M. T. (1969) Aphasia in a congenitally deaf man. *Cortex*, 5, 398-414.
- SASANUMA, S. (1975) Kana and Kanji processing in Japanese aphasics. *Brain and Language*, 2, 369-383.
- SERON, Y., VAN DER KAA, M. A., REMITZ, A. and VAN DER LINDEN, M. (1979) Pantomime interpretation and aphasia. *Neuropsychologia*, 17, 661-668.
- SIPLE, P. (Editor) (1978) *Understanding Language Through Sign Language Research*. New York: Academic Press.
- SPELLACY, F. J. and SPREEN, O. (1969) A short form of the Token Test. *Cortex*, 5, 390-397.
- SPREEN, O. and BENTON, A. L. (1969) *Neurosensory Center Comprehensive Examination for Aphasia*. Victoria, B.C.: Neuropsychology Laboratory, University of Victoria.
- STOKOE, W. C. (1978) *Sign Language Structure*. Silver Spring, MD.: Linstok Press.
- CASTERLINE, D. and CRONEBERG, C. (Editors) (1965/1976) *A Dictionary of American Sign Language on Linguistic Principles*. Washington, DC: Gallaudet College Press (Second edition revised, Silver Spring, MD.: Linstok Press).
- TUREEN, L. L., SMOLIK, E. A. and TRITT, J. H. (1951) Aphasia in a deaf mute. *Neurology, Minneapolis*, 1, 237-249.
- UNDERWOOD, J. K. and PAULSON, C. J. (1981) Aphasia and congenital deafness: a case study. *Brain and Language*, 12, 285-291.
- WILBUR, R. B. (1979) *American Sign Language and Sign Systems*. Baltimore: University Park Press.

(Received December 4, 1980)