

Transcortical aphasia from ischaemic infarcts of the thalamus: a report of two cases

DAVID McFARLING, LESLIE J ROTH, KENNETH M HEILMAN

From the Department of Neurology, College of Medicine, University of Florida, and the Veterans Administration Medical Center, Gainesville, Florida

SUMMARY Thalamic injury from various natural causes, including tumours and haemorrhage, has been reported to lead to abnormalities of language. The pathophysiology of these language disorders remains controversial because the naturally occurring thalamic lesions often are associated with mass effects. Two patients are described with hypodense left thalamic lesions, shown by computed tomography, probably representing infarction. Both patients had aphasia, but neither had evidence of appreciable brain swelling or distortion, nor were cortical language areas damaged.

Despite an increasing number of reports of aphasia following thalamic injury, the role of the thalamus in normal language function, and the existence of a characteristic "thalamic aphasia", remain controversial. Nevertheless, the clinical picture is reasonably consistent.¹ In the early stage there is partial or complete mutism, with various disturbances of comprehension or fluency or both. By contrast, repetition is well preserved; and the patients often have pallilalia, echolalia, and other perseverative phenomena. Dramatic spontaneous fluctuations in severity of the language deficit are also said to be characteristic.² Alexander and LoVerme³ noted that in thalamic aphasia repetition is often spared and in many respects the thalamic aphasias are similar to the transcortical aphasias. Specifically, Cappa and Vignolo⁴ described eight patients with left thalamic haemorrhage, seven of whom suffered from aphasia. Three case studies were described in which aphasia was characterised by sparse verbal output, semantic paraphasias, and "partially defective auditory verbal comprehension" in conjunction with spared repetition abilities—a transcortical aphasia.

The reported naturally occurring illnesses that may induce thalamic aphasia include thalamic tumours⁵⁻⁹ and thalamic haemorrhage.^{2-4, 7, 10-17} However, because of the nature of these illnesses, Geschwind¹⁸ was sceptical that lesions confined to

the thalamus could produce aphasia, suggesting instead that such symptoms may be "the sequel of pressure and oedema elsewhere." McKissock and Paine,⁹ as well as Fisher,¹² expressed similar views. Alexander and LoVerme³ also raised the possibility that "the transcortical elements in our patients may have been due to either pressure effects on the left hemisphere or impairment of the carotid circulation after compression of the carotid artery intracranially or its middle cerebral and anterior cerebral branches or both. This may produce diffuse ischaemic damage in the arterial border zone of the left hemisphere. ..."

Surgical intervention in the thalamus and its effect on speech and language have also been studied in cases of thalamotomy¹⁹⁻²³ and thalamic stimulation.²⁴⁻²⁸ These studies have shown that although aphasia does not inevitably follow left-sided thalamic ablations or stimulations, it does occur often. Language function appears to be selectively related to the ventrolateral nucleus and the anterosuperior pulvinar.²⁴⁻²⁷ Neither ablation or stimulation of the corresponding nuclei of the right thalamus has produced any effects on language. Although highly suggestive, as with the haemorrhage and tumour cases, surgical manipulation of the left thalamus cannot be said to provide conclusive evidence that the thalamus participates in language. The procedures are always performed on brains with pre-existing lesions, and both stimulation and ablation procedures may affect neighbouring structures with no natural physiological relationship to the thalamic nuclei in question.

Thalamic ischaemic infarctions would be less likely to induce pressure effects and would not have

Address for reprint requests: Dr KM Heilman, Box J-236, Department of Neurology, J Hillis Miller Health Center, University of Florida, Gainesville, FL 32610, USA.

Received 25 April 1981 and in revised form 20 August 1981
Accepted 26 September 1981

to occur in patients who have pre-existing lesions. According to Alexander and LoVerme,³ however, limited ischaemic infarctions of the thalamus have not been reported to be associated with aphasia. Although there have been three reported cases of aphasia induced by thalamic infarction, all of the three showed pressure effects.^{29 30} In this report we describe two patients who had thalamic lesions and aphasia. In both patients CT showed hypodense areas compatible with an ischaemic infarction. In neither patient was there significant mass effect.

Case reports

Case 1

A 52-year-old, right-handed man had severe occipital headache and blurred vision for 2 days. He abruptly lost all power of speech and became paralysed on the right side. Five days after admission to hospital his condition stabilised, and he was transferred to the Gainesville Veterans Administration Medical Center for further study and treatment of stroke. Before the stroke he was employed as a barber and was in good health except that he had had poorly controlled hypertension for 2 years and was being treated with prazosin HCl. The past medical history was unremarkable except for moderate alcohol intake and chronic cigarette smoking.

General examination showed a large, moderately obese man paralysed on the right side. His blood pressure was 124/80 mm Hg. Although appearing alert, he was extremely irritable and uncooperative and produced little or no spontaneous speech. He consistently responded to his name, but his comprehension of verbal and written language fluctuated remarkably—from almost total loss of comprehension to brief periods of near normal performance. In general, improvements in comprehension were roughly paralleled by improvements in spontaneous speech; however, he tended to persevere and was often echolalic. Repetition suffered the least, and although moderately dysarthric, he could repeat words and phrases. In moments of irritation he also showed a facility with expletives. Because of the language disorder, complete formal verbal memory testing was impossible, but he clearly recognised his physicians from day to day and identified familiar faces among a crowd. Cranial nerve examination showed a right homonymous hemianopia and loss of opticokinetic nystagmus with the tape moving toward the patient's left. There was no gaze apraxia, and extraocular movements were full to finger pursuit. The face was paralysed on the lower right side. The tongue protruded to the right of midline and had lost some mobility. Motor examination disclosed a right hemiparesis with much greater weakness of the arm than the leg. All deep tendon reflexes were briskly active and bilaterally symmetrical. The plantar response was extensor on the right. There was a grasp response on the right.

We used a modified Western Aphasia Battery to test language formally.³¹ Spontaneous speech fluctuated from sparse to absent, and although verbal output was extremely limited in length, no syntactic errors were

noted. The patient's responses to simple conversational questions, such as "How are you today?" elicited either no response or occasional monosyllabic words and short phrases. No verbal or phonemic paraphasias were noted. The phrases were sometimes appropriate and sometimes not. Spontaneous speech generally paralleled transient improvements in comprehension. We tested auditory verbal comprehension with questions that could be answered "yes" or "no" or with a corresponding gesture, such as a nod of the head. The questions varied in difficulty from "Is your name Smith?" to "Is a hammer good for cutting wood?" Of the 20 questions, 12 were correctly answered. Mistakes were made on questions 11-18, in succession, followed by correct responses on the last two. This illustrates the rapid fluctuation of the patient's comprehension deficit, inasmuch as the last two questions were as difficult as the preceding eight in a row that were missed. Word discrimination was tested by having the patient point to various real objects (for example, a watch, wallet), parts of the room (for example, floor), and parts of the patient's body ("Show me your nose."). Only two of 10 responses were correct. He was next required to identify fingers and lateralised body parts (for example, right ear). Again, only two of 10 responses were correct. He could perform to only the simplest sequential commands: "Point to the ceiling, then to the floor." Repetition was tested using monosyllabic words (chair), polysyllabic words (banana), phrases (no ifs, ands, or buts), and sentences (the quick brown fox jumped over the lazy dog). Although dysarthria caused some slurring, the patient repeated all items without difficulty. Naming was tested by asking the patient "What do you call this?" and at the same time holding up or pointing to 10 common objects (for example a watch, a pen). Only three of 10 objects presented were correctly named. Sentence completion was tested by asking him to provide the final word of a familiar sentence such as "Roses are red, violets are . . ." He successfully completed three of five sentences. Finally, on the Controlled Word Association test³² he could not name a single object beginning with a designated letter during the 60 seconds allotted.

Routine laboratory studies were all within normal limits. VDRL was weakly reactive, and FTA-ABS was 2+ positive. Electrocardiography and an echocardiogram were both normal. Electroencephalography showed diffuse bilateral slowing with focal left anterior delta activity. Computed tomography (CT) on the day of admission showed radiolucencies of the left internal capsule and the adjacent posterior-lateral portion of the left thalamus and possibly in the medial portion of the left occipital lobe. There was no evidence of significant mass effect (fig 1). A CT scan repeated 1 week later with contrast enhancement revealed no additional information.

Toward the end of the second week in hospital, the patient's language function deteriorated suddenly and dramatically. The problems with spontaneous speech and comprehension worsened, and he could no longer repeat. A CT scan showed an area of apparent new infarction involving the left posterior temporal and parietal areas, which suggested an infarction in the distribution of the middle cerebral artery. Formal language testing with the

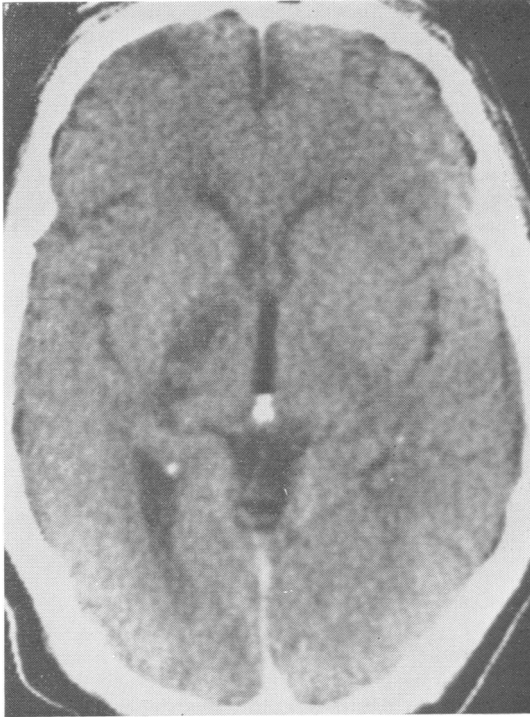


Fig 1 CT scan of patient 1 performed 7 days after onset of symptoms.

Western Aphasia Battery showed total loss of all language function; however, before the patient's discharge 1 month after onset of the first episode, aphasia returned to the same quality and severity as before the second episode.

Case 2

An 18-year-old right-handed man received several minor lacerations on both legs while fishing. He was taken to a nearby emergency room where the cuts were sutured, and tetanus toxoid was administered. After breakfast the next morning, he arose from a couch, took a few steps, and abruptly lost consciousness. Generalised tonic-clonic seizure activity ensued. He was taken to a local hospital, where seizures were terminated by intravenous diazepam. The total duration of the seizure was estimated at 20-40 minutes. The patient was then somnolent, but neither the duration of the drowsiness nor the language function immediately thereafter was recorded. No focal neurological details were recorded.

Laboratory examinations showed a normal white blood cell count and a negative screen for toxic substances in the serum. A mononucleosis spot test was negative. The CT scans with and without contrast showed no abnormalities. The patient was given diphenylhydantoin, 300 mg daily, and discharged. During the next few days at home the patient was noted to be "weak", though ambulatory, and "confused" about time and place. One week after the

initial episode, in addition to being confused, he developed right-sided limb weakness and right facial paralysis. He was readmitted to the local hospital, and a lumbar puncture was performed but was unremarkable, except that the total protein content was 126 mg/100 ml.

Cerebrospinal fluid (CSF) protein electrophoresis showed normal distribution of protein subtypes. Gram stains and cultures of CSF were negative, and CSF viral antibody titres were not increased. Other laboratory data included normal concentrations of serum ammonia, calcium, inorganic phosphate, uric acid, creatinine, lactic acid dehydrogenase, glutamine orthotransferase, and glucose. Serum electrolytes were all within normal limits. A left carotid arteriogram was performed and showed no abnormalities. After this work-up was completed, the patient was transferred to the University of Florida Shands Teaching Hospital for further evaluation.

General neurological examination showed the patient to be alert, well-oriented, and cooperative. There was right lower facial weakness and asymmetry of optokinetic nystagmus with poor saccadic refixations to the right (tape moving to the patient's left). Voluntary saccades to the right were also slower and more erratic than those to the left. Pursuit movements were normal in all directions. Motor examination showed mild right hemiparesis manifested chiefly by a pronator drift of the extended and supinated upper extremity, clumsiness, decreased facility with rapid alternating movements of the right hand, and a tendency to veer to the right when walking. An extensor plantar response was elicited on the right. The remainder of the neurological findings were normal. The patient could report seven digit sequences and recalled three objects correctly after delays of 5 and 15 minutes. His remote memory and general fund of information seemed intact and appropriate for his educational background (described as a "C" student in the 12th year of schooling). Language evaluation showed markedly reduced spontaneous speech associated with very mild dysarthria. Evaluation of spontaneous speech with simple questions, produced correct, appropriate, but short responses without elaboration. Description of a simple picture was similarly laconic. No phonemic or verbal paraphasias nor syntactic errors were noted in any verbal productions. On the Controlled Word Association test³⁰ he could name only four objects beginning with the letter F. For objects beginning with A or S only one response was made. Normal response is considered to be the naming of at least nine objects in 60 seconds for the letter A and at least 11 objects for the letters F and S.³³

In summary, verbal production of spontaneous speech was characterised by a diminution of the quantity and elaborateness of responses. In contrast to the sparse language production, comprehension and repetition were intact. He correctly answered all of 20 questions requiring yes or no responses (for example "Is this a hotel?"; "Is a lion larger than a dog?"). He correctly pointed to 42 common objects or pictures of objects (for example wallet, pen, police whistle) and named 20 similar objects presented to him. He correctly identified fingers and lateralised body parts on 11 of 12 commands (for example, "Show me your left ear") and flawlessly performed to commands with auditory sequencing ("Put

the watch on the other side of the pencil and turn over the card"). With the exception of one paraphasic error ("manana" for "banana"), he repeated all monosyllabic or polysyllabic words, phrases, and sentences. Similarly, he correctly completed familiar phrases and sentences (for example, "Roses are red, violets are. . .").

In the Syntactic Comprehension test³² a sentence is read aloud to the patient (for example, "He showed the boy's dog the cages."). The patient must then match the sentence by pointing to one of four pictures. One picture is correct (for example, a man showing cages to a dog), one is a semantically related syntactic foil (for example, a man showing dog cages to boys), and two are semantically unrelated (for example, a man showing bird seed to a girl and a man showing bird seed to a bird). Correct performance requires precise syntactic comprehension. The patient made no errors on 30 trials. He was unable to perform serial-7 subtractions or any but the simplest general arithmetic calculations. Problems involving money changing, however, were handled somewhat better. This dyscalculia was difficult to interpret because of the patient's history of poor school performance, including taking a remedial mathematics course to qualify for high school graduation. He had no difficulty with finger recognition or right-left lateralisation. Construction ability was unimpaired as shown by his ability to copy complex figures and draw figures, like daisies and clocks, on command. There was no evidence of hemineglect or hemi-inattention. Proverb interpretation was adequate.

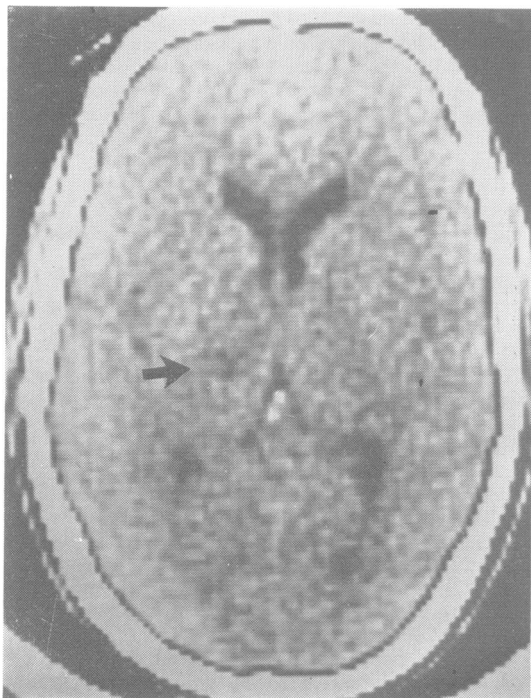


Fig 2 CT scan of patient 2 performed 2 weeks after onset of symptoms.

Results of routine laboratory studies were within normal limits. Prothrombin time, partial thromboplastin time, and platelet count were all within normal limits. Assays for antinuclear antibody and rheumatoid factor were negative as were the mononucleosis spot test and the serological test for syphilis. Sedimentation rate was 3 mm/h. Lumbar puncture was performed, and clear CSF was obtained. Microscopic analysis showed 15 red blood cells and two white blood cells per field. Cultures of CSF were negative for all organisms. Gram stains and India ink preparation were negative. Viral titres in CSF were not increased. Glucose in CSF was 60, and total protein was 61 mg/100 ml (normal range, 15-45) with a slight increase of IgG at 5.9% (normal range, 1.9-4.2%). An EEG was normal. A CT scan showed a small hypodense area in the left thalamic region (fig 2). This was compatible with an ischaemic infarction. To rule out a cardiac source of emboli, we obtained an electrocardiogram, echocardiogram, and Holter monitor cardiogram; all findings were normal.

The patient showed considerable improvement while in hospital. After the diagnostic studies were completed, he was discharged to be observed as an outpatient.

Discussion

In summary, we have described two cases of non-fluent aphasia with relatively preserved repetition. One patient had poor comprehension, and the other normal comprehension. These patients conform to the syndrome complex termed "transcortical aphasia, mixed and motor".¹ Both had hypodense areas on CT that were compatible with a thalamic infarction.

In the absence of a postmortem examination we cannot be certain that the cortex was not involved. This is especially true in the second patient who had a seizure. In neither case, however, during the time these patients had a transcortical type of aphasia was there evidence on CT scanning, with or without contrast enhancement, that any cortical areas were involved except the medial portion of the left occipital lobe in the first patient. Destruction of this area might well cause visual agnosia or a similar syndrome in addition to the right homonymous hemianopia but should not, by itself, have caused the mixed transcortical aphasia in this patient. Similarly, destruction of the posterior limb of the internal capsule accounted for the right hemiparesis but would not be expected to contribute to any language disturbance, although the mechanical speech disorder (dysarthria) may have been caused by the interrupted descending corticobulbar fibres running in the genu of the internal capsule. In the second patient the area of infarction was somewhat smaller and entirely localised in the left internal capsule and adjacent thalamus. In both patients the apparently spared medial portions of the thalamus may account for the absence of vertical oculomotor apraxia and

memory loss, as in a patient with bilateral medial thalamic infarcts described by Mills and Swanson.³⁴ Their patient was hypersomnolent and apathetic but not aphasic. Finally, in the two patients described here, CT scans were obtained within 2 weeks of the onset of symptoms. The hypodense areas on CT were interpreted to represent ischaemic infarction, and there was no sign of haemorrhage, tumour, cerebral oedema, or distortion of brain structures from mass effect. Therefore, it is unlikely that the associated aphasia was being induced by compression of vessels and watershed ischaemia on infarction. According to Lazorthes³⁵ the area of the thalamus infarcted in our patients are usually supplied by the thalamo-perforating stalk, which arises from the junction of the basilar artery and the proximal part of the posterior cerebral artery. Small branches reach not only the lateral thalamic nuclei but also the internal capsule.

Although both our patients had thalamic lesions, comprehension was normal in one and impaired in the other. These differences may be related either to small differences in the locus or size of the lesion or to other factors. For example, it has been shown that the right hemisphere may mediate comprehension in aphasic left-hemisphere-damaged patients.³⁶ It has also been demonstrated that young brain-injured patients are more likely to recover comprehension than are older patients.³⁷ Thus, the intact comprehension in patient 2 might have been related to his age and not to the locus or size of the lesion.

In 1884 Hughlings Jackson,³⁸ influenced by the burgeoning Darwinian revolution, proposed hierarchical organisation of the nervous system with higher centres (defined as the least organised, the most complex, and the most voluntary) being the least resistant to injurious influences. Head³⁹ incorporated Hughlings Jackson's ideas of different levels of complexity of nervous activity and stated that "the more highly differentiated the act, the greater degree of vigilance does it require and the more easily can it be abolished by toxic influences, such as chloroform, or by other conditions unfavourable to physiological activity". Beatty and Wagoner⁴⁰ have confirmed that higher levels of information processing are associated with increased brain activation as measured by pupillary dilation.

Ojemann²⁵ proposed that the left ventrolateral thalamus has a "specific alerting function" with regard to language and that the aphasia with thalamic lesions is the outcome of deficient arousal of otherwise intact cortical language mechanisms. The clinical features of such aphasia would be determined by selective loss, or "dissolution" in Jacksonian terminology, of the more complex language functions, which probably require "greater diffuse

energising activity".²⁵ Such aphasias are classified as "transcortical" and characterised by the loss of more complex language functions with relative sparing of repetition—often to the point of echolalia. In both of our patients the clinical diagnosis was transcortical aphasia. Cappa and Vignolo⁴ have emphasised the transcortical features of the reported cases of aphasia from left thalamic haemorrhage. We believe that our cases show clinical evidence that Ojemann's conclusions based on his experimental work with thalamic stimulation are essentially correct.²⁵

Experimental work with nonhuman primates and other laboratory animals presents a picture of ventrolateral nucleus (VL) function compatible with a role in at least the motor aspects of language. Classically regarded as a motor relay nucleus,⁴¹ the VL receives afferent projections from the cerebellum and, to a lesser extent, from the globus pallidus. Efferent projections from VL are distributed rather diffusely to areas 4 and 6 of the motor cortex.⁴² Recent work however has shown that the VL is by no means a simple relay station on the way to the cortex. Complex gating of cortical input from the VL occurs and is mediated both by the mesencephalic reticular formation and by the medial thalamic-frontocortical system, projecting from the frontal cortex on to the portion of the nucleus reticularis thalami immediately adjacent to the VL.⁴³ As Purpura¹⁴ observed, these complex interrelated input-output systems make the VL an "interface" between the motor control systems of the basal ganglia and the cerebellum on the one hand and the neocortex on the other".

Nonfluent aphasias with spared repetition and echolalia (transcortical motor and mixed transcortical aphasia), similar to the form in our two patients, are commonly associated with dorsolateral and medial frontal lobe lesions. These regions of the frontal lobe not only receive projections from the VL⁴² but also have close connections with the neostriatum,⁴⁴ which, as has been discussed, projects to the ventroanterior-ventrolateral complex. Therefore, it is not surprising that lesions in these cortical areas may induce a clinical picture closely resembling that induced by thalamic lesions.

This study was supported in part by National Institutes of Health Grant NS-15229 and the Research Service of the Veterans Administration.

References

- 1 Benson DF. *Aphasia, Alexia and Agraphia*. New York: Churchill-Livingstone, 1979.
- 2 Mohr J, Watters W, Duncan G. Thalamic hemorrhage and aphasia. *Brain Lang* 1975;2:3-17.

- ³ Alexander M, LoVerme SR. Aphasia following left intracerebral hemorrhage. *Neurology (Minneapolis)* 1980;**30**:1193-202.
- ⁴ Cappa SF, Vignolo LA. "Transcortical" features of aphasia following left thalamic hemorrhage. *Cortex* 1979;**15**:121-30.
- ⁵ Arseni C. Tumors of the basal ganglia. *AMA Arch Neurol Psychiatry* 1958;**80**:18-26.
- ⁶ Cheek WR, Taveras J. Thalamic tumors. *J Neurosurg* 1966;**24**:505-13.
- ⁷ Luria AR. On quasi-aphasic speech disturbances in lesions of the deep structures of the brain. *Brain Lang* 1977;**4**:432-59.
- ⁸ Smyth G, Stern K. Tumours of the thalamus—a clinicopathological study. *Brain* 1938;**61**:339-74.
- ⁹ McKissock W, Paine KWE. Primary tumors of the thalamus. *Brain* 1958;**81**:41-63.
- ¹⁰ Bugiani O, Conforto C, Sacco G. Aphasia in thalamic hemorrhage. *Lancet* 1969;**2**:1052.
- ¹¹ Ciemins VA. Localized thalamic hemorrhage: a cause of aphasia. *Neurology (Minneapolis)* 1970;**20**:776-82.
- ¹² Fisher CM. The pathologic and clinical aspects of thalamic hemorrhage. *Trans Am Neurol Assoc* 1959;**84**:56-9.
- ¹³ Horenstein S, Chung H, Brenner S. Aphasia in two verified cases of left thalamic hemorrhage. *Trans Am Neurol Assoc* 1978;**103**:193-8.
- ¹⁴ Purpura DP. Operations and processes in thalamic and synaptically-related neural subsystems. In: Schmitt FO, ed. *The Neurosciences. Second Study Program*. New York: Rockefeller University Press, 1970:458-70.
- ¹⁵ Reynolds AF, Harris AB, Ojemann GA, Turner PT. Aphasia and left thalamic hemorrhage. *J Neurosurg* 1978;**48**:570-4.
- ¹⁶ Reynolds AF, Turner PT, Harris AB, Ojemann GA, Davis LE. Left thalamic hemorrhage with dysphasia, a report of five cases. *Brain Lang* 1979;**7**:62-73.
- ¹⁷ Samarel A, Wright TL, Sergay S, Tyler HR. Thalamic hemorrhage with speech disorder. *Trans Am Neurol Assoc* 1976;**101**:283-5.
- ¹⁸ Geschwind N. Discussion of cerebral connectionism and brain function. In: Millikay CH, Darley FL, eds. *Brain Mechanisms Underlying Speech and Language*. New York: Grune and Stratton, 1967:71-2.
- ¹⁹ Allen C, Turner J, Gadea-Ciria M. Investigation into speech disturbances following stereotactic surgery for Parkinsonism. *Br J Disord Commun* 1966;**1**:55-9.
- ²⁰ Bell DS. Speech functions of the thalamus inferred from the effects of thalamotomy. *Brain* 1968;**91**:619-38.
- ²¹ Brown JW. Language, cognition and the thalamus. *Confin Neurol* 1974;**36**:33-60.
- ²² Darley FL, Brown JR, Swenson WM. Language changes after neurosurgery for Parkinsonism. *Brain Lang* 1975;**2**:65-9.
- ²³ Riklan M, Levita E, Zimmerman J, Cooper IS. Thalamic correlates of language and speech. *J Neurol Sci* 1969;**8**:307-28.
- ²⁴ Ojemann GA. Language and the thalamus: object naming and recall during and after thalamic stimulation. *Brain Lang* 1975;**2**:101-20.
- ²⁵ Ojemann G. Subcortical language mechanisms. In: Whitaker H. *Neurolinguistics*, vol 1. New York: Academic Press, 1976:103-38.
- ²⁶ Ojemann GA, Fedio P, Van Buren JM. Anomia from pulvinar and subcortical parietal stimulation. *Brain* 1968;**91**:99-116.
- ²⁷ Ojemann GA, Ward AA. Speech representation in the ventrolateral thalamus. *Brain* 1971;**94**:99-117.
- ²⁸ Fedio P, Van Buren JM. Memory and perceptual deficits during electrical stimulation in the left and right thalamus. *Brain Lang* 1975;**2**:78-100.
- ²⁹ Cohen JA, Gelfer CE, Sweet RD. Thalamic infarction producing aphasia. *Mt Sinai J Med NY* 1980;**47**:398-404.
- ³⁰ Demeurisse G, Derouck M, Coekaerts MJ, Deltene P, Van Nechel C, Demol O, Capon A. Study of two cases of aphasia by infarction of the left thalamus. *Acta Neurol Belg* 1979;**79**:450-9.
- ³¹ Kertesz A, Poole E. The aphasia quotient: taxonomic approach to measurement of aphasic disability. *Can J Neurol Sci* 1974;**1**:7-16.
- ³² Spreen O, Benton AL. *Neurosensory Center Comprehensive Examination for Aphasia*. Victoria BC: University of Victoria, 1969.
- ³³ Borkowski JG, Benton AL, Spreen O. Word fluency and brain damage. *Neuropsychologia* 1967;**5**:135-40.
- ³⁴ Mills RP, Swanson PD. Vertical oculomotor apraxia and memory loss. *Ann Neurol* 1978;**4**:149-53.
- ³⁵ Lazorthes G. *Vacularisation et circulation cerebrales*. Paris: Masson Cie, 1961. Cited by Martin JJ. Thalamic syndromes. In: Vinken PJ, Bruyn GW, eds. *Handbook of Clinical Neurology*, vol 2. New York: American Elsevier, 1969:473-4.
- ³⁶ Kinsbourne M. The minor hemisphere as a source of aphasic speech. *Arch Neurol* 1971;**25**:302-6.
- ³⁷ Vignolo LA. Evolution of aphasia and language rehabilitation: a retrospective exploratory study. *Cortex* 1964;**1**:344-67.
- ³⁸ Jackson JH. Evolution and dissolution of the nervous system. *Lancet* 1884;**1**:555-8.
- ³⁹ Head H. *Aphasia and Kindred Disorders of Speech*. London: Cambridge University Press, 1926.
- ⁴⁰ Beatty J, Wagoner BL. Pupillometric signs of brain activation vary with level of cognitive processing. *Science* 1978;**199**:1216-8.
- ⁴¹ Walker AE. *The Primate Thalamus*. Chicago: University of Chicago Press, 1938.
- ⁴² Strick PL. Light microscopic analysis of the cortical projections of the thalamic ventrolateral nucleus in the cat. *Brain Res* 1973;**55**:1-24.
- ⁴³ Yingling CD, Skinner JE. Gating of thalamic input to cerebral cortex by nucleus reticularis thalami. In: Desmedt JE, ed. *Attention, Voluntary Contraction and Event Related Cerebral Potentials*. Basel: Karger, 1977:70-96.
- ⁴⁴ Divac I. Neostriatum and functions of prefrontal cortex. *Acta Neurobiol Exp (Warsz)* 1972;**32**:461-77.