

On the Role of the Anterior Cingulate Cortex in Phonation: A Case Report

U. JÜRGENS AND D. VON CRAMON

Max-Planck-Institut für Psychiatrie, Kraepelinstrasse 2, 8000 Munich 40, West Germany

A 41-year-old male patient is presented with a lesion in the anterior cingulate cortex, medial orbital cortex, and rostral striatum bilaterally and supplementary motor area on the left side. The patient first exhibited a state of akinetic mutism which lasted about 6 weeks. During this state, no volitional vocal utterances were made; there were, however, occasional groans of pain. During recovery, the mute phase was replaced by a state in which the patient could whisper but not phonate verbal utterances. About 10 weeks after the accident, phonation was restored. The speech was characterized, however, by monotonous intonation and a very low frequency of spontaneous utterances. While the frequency of spontaneous speech improved noticeably during the following months, emotional intonation remained permanently defective. A comparison of the present case with other cases from the literature as well as experimental monkey data suggest that the anterior cingulate cortex is involved in the volitional control of emotional vocal utterances.

In the neurophysiological literature on monkey phonation, there are a number of observations which point to a possible role of the anterior cingulate cortex in phonatory control. Smith (1945), Kaada (1951), Showers and Crosby (1958), and Robinson (1967) reported that electrical stimulation of the anterior cingulate cortex yields vocalization in the rhesus monkey. Jürgens and Ploog (1970) confirmed this result in the squirrel monkey. In a more recent study (Jürgens, 1976a), it could be shown that the vocalizations elicitable from the anterior cingulate cortex are not accompanied by specific motivations; they, therefore, cannot be interpreted as secondary reactions due to stimulation-induced motivational changes, but rather seem to represent primary stimulus responses. Neuroanatomical studies, in addition, have shown that there is a pathway running from the anterior cingulate cortex to the laryngeal motoneurons with only one synapse in the region of the caudal periaqueductal grey

Address reprint requests to: Dr. U. Jürgens, Max-Planck-Institut für Psychiatrie, Kraepelinstrasse 2, 8000 Munich 40, West Germany.

(Jürgens & Pratt, 1979a,b). Furthermore, there are direct projections from the anterior cingulate cortex to almost all other brain areas yielding vocalization when electrically stimulated (Jürgens & Müller-Preuss, 1977). Ablation studies have shown that monkeys trained to perform a vocal conditioning task, that is, to vocalize in order to obtain a food reward or postpone an electroshock, are no longer able to do this task after destruction of the anterior cingulate cortex (Sutton, Larson, & Lindeman, 1974; Aitken, 1981); these animals are, however, still able to do a lever-pressing conditioning task after lesioning of this area. Finally, single-unit recording has revealed that there are a number of neurons in the anterior cingulate cortex of the monkey that change their activity a few hundred milliseconds prior to each vocalization uttered in a vocal conditioning situation; these neurons do not react, however, to other conditioned oral movements like biting or licking (Sutton, Samson, & Larson, 1978).

Considering all these observations, together with the finding that destruction of the anterior cingulate cortex neither changes the acoustic structure nor the frequency of occurrence of spontaneous monkey calls (Kirzinger & Jürgens, *in press*), the conclusion may be drawn that the anterior cingulate cortex probably plays a role in the volitional initiation of species-specific vocalizations. In other words, the anterior cingulate cortex seems to participate neither in the motor coordination of phonation nor in the initiation of emotional (nonvoluntary) vocal reactions, but it seems to be of importance for the production of vocalizations in an operant conditioning situation, that is, for voluntary vocalization.

The human homolog of the monkey's vocalizations probably are the nonverbal emotional vocal utterances like laughing, crying, moaning, jubiling, as well as the emotional intonation patterns used in speech, for instance, when expressing rage, tenderness, disgust, triumph, etc. Both, monkey calls and human emotional nonverbal utterances and intonations, have in common that they need not be learned, in contrast to speech, but are innate. Thus monkey infants raised from birth by mute mothers nevertheless produce all call types of the species without ever having had the opportunity to hear an adult's call (Winter, Handley, Ploog, & Schott, 1974). Deaf-blind human infants also show typical laughing and crying (Goodenough, 1932). Furthermore, a transcultural comparison of emotional intonation patterns reveals that sentences expressing tenderness, anger, contempt, or sadness can be understood in their emotional content even if the verbal content is not understood (Kramer, 1964). Monkey calls, like human emotional intonations and nonverbal utterances, represent vocal expressions of specific motivational states, that is, they signal the preparedness to react in a specific way (Jürgens, 1979). There are further indications that corresponding emotional states

are expressed in monkey and man by similar acoustic patterns (Jürgens, 1981).

Therefore, if we assume that the cerebral control of phonation is organized in monkey and man in a homologous manner, we may hypothesize that a bilateral destruction of the anterior cingulate cortex should impair the volitional control of emotional vocal utterances in man as in monkey. The clinical literature on this point is very scanty. There are a few reports associating the syndrome of akinetic mutism with anterior cingular lesions (Barris & Schuman, 1953; Buge, Escourolle, Rancurel, & Poisson, 1975; Nielsen & Jacobs, 1951). But since in all three studies the patients succumbed before having regained speech, there is no description of the intonation quality after recovery from mutism. The aim of the present study is to fill this gap.

RESULTS

Case History

The 41-year-old right-handed male patient, P.A., abruptly lost consciousness on the morning of December 24, 1975. Except for complaints about occasional dizziness, no premonitory symptoms had been noticed. The patient was admitted to a general hospital. There, transfemoral arteriography disclosed the occlusion of the ascending branches of both anterior cerebral arteries. The horizontal segments of these arteries, as well as the anterior communicating artery, had been preserved. Heubner's recurrent arteries, as well as medial striate arteries, however, could not be visualized. A thorough medical examination did not provide any etiological explanation for the cerebrovascular accident. In the angiogram, no variations or malformations of the cerebral vessels were detected.

For somewhat more than 6 weeks, the patient remained in a state of akinetic mutism. He lay in bed nearly immobile, his eyes open most of the time, his gaze following whatever was going on in his field of vision. If stimulated strongly enough, he minimally moved his head or arms. On rare occasions, he responded to painful stimuli with a groan, but never made a semantically recognizable verbal utterance.

In late February 1976, the patient adequately responded to verbal commands, viz., three-stage questions, in a nonverbal manner. He remained completely mute, however, and did not make an effort to articulate either. His tongue movements seemed to be unrestricted in rate and range, and he could swallow easily. Occasionally, the patient tried to smile.

In the course of 2 more weeks, the patient began to whisper. He repeated even long sentences without making mistakes. He promptly responded to questions addressed to him. His spontaneous speech activity, however, remained reduced to a few monosyllabic utterances.

In March 1977, we could examine the patient for the first time. His speech activity still seemed to be somewhat reduced, but at several occasions he initiated a conversation of his own accord. The patient showed no signs of aphasia or dysarthria; his intonation, however, was characterized by great monotony. Respiratory control during speaking was normal. There was no sensorimotor deficit, no signs of spasticity or abnormal grasp reflexes. Pathological reflexes were missing. Urinary incontinence, present in the first weeks of the illness, had completely receded. The patient's psychic state was characterized by a lack of concentration, extreme distractibility, and motor restlessness. The behavior was dominated by compulsory counting and recounting of buttons, window panes, paving stones, or his own paces. These compulsory acts, however, seemed to lack a strong emotional component, for we could interrupt them without provoking feelings of fear or guilt. An endogenous depression from which the patient had suffered before the cerebrovascular accident did not return. In comparison to his premorbid personality, he also has become less aggressive and intolerant.

Lesion Site

A computer-tomographic scan, made in March 1977, when the patient was transferred to our clinic, revealed a bilateral infarction in the region of both anterior cerebral arteries, possibly including that of Heubner's recurrent arteries (Fig. 1). In order to get a better idea of the lesion site, we have redrawn the lesion and introduced it into a series of semischematic frontal sections (Fig. 2). This reconstruction was made by projecting the computer-tomograms on the respective horizontal sections of the stereotaxic atlas of Schaltenbrand and Bailey (1959) by aid of an enlarger. The anterior-posterior, sagittal, and horizontal lesion coordinates were then transferred to frontal sections of the same atlas. From these sections the brain diagrams of Fig. 2 (including the lesion) were traced. Despite the fact that this method can give only an approximate idea of the extent of the lesion, there is no doubt that in our patient the lesion invades the anterior cingulate cortex bilaterally; in addition, it affects the left supplementary motor area (F1), the medial orbital cortex bilaterally, and the most rostral part of the striatum bilaterally. The dots in section AP 12 (just above the Sylvian fissure) indicate the site of the larynx representation in the motor face cortex according to Penfield and Roberts (1959); the dashes running from the cortical larynx area into the internal capsule and cerebral peduncle represent the corticofugal pathway by which the cortical larynx area controls the laryngeal motoneurons (Jürgens, 1976b). This pathway has been introduced into the diagrams to demonstrate that the phonatory deficits in our patient are not due to an interruption of the cortical output of the classical motor speech area.

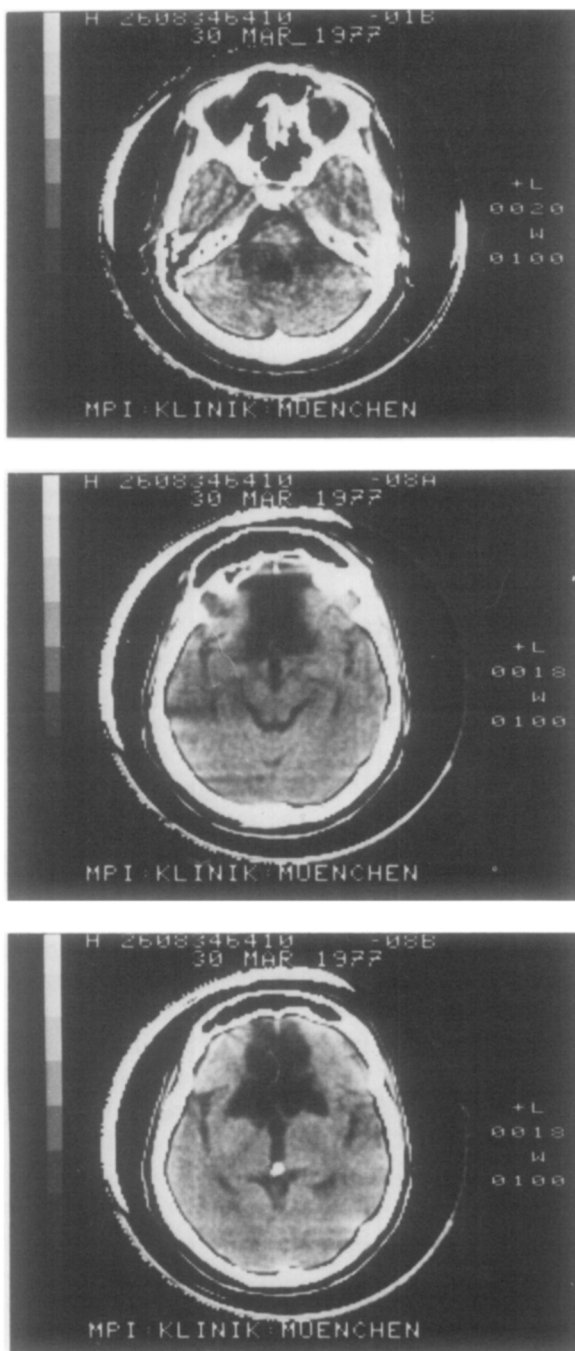


FIG. 1. Computer tomograms of patient P.A. (intersection distance: 10 mm).

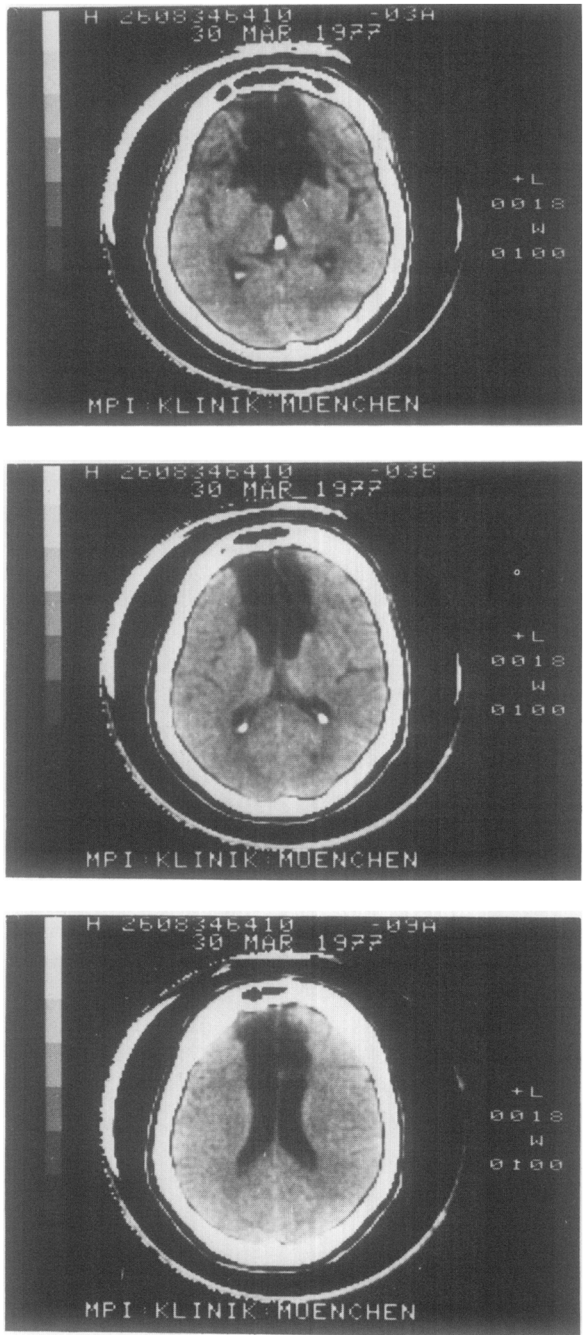


FIG. 1. Continued

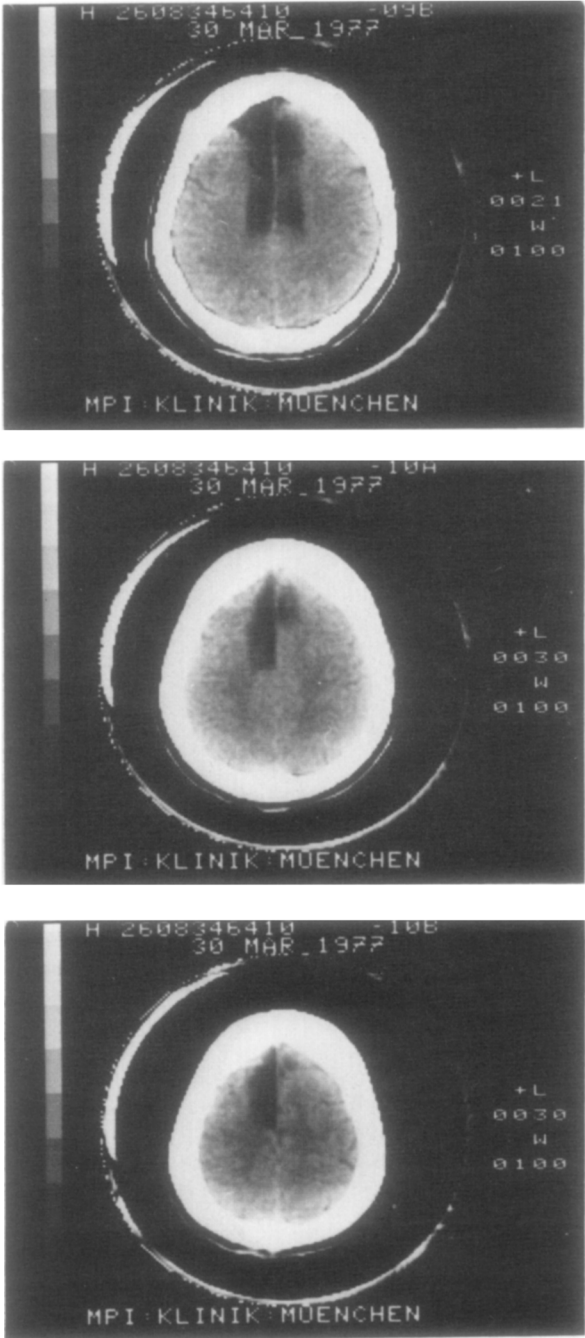


FIG. 1. *Continued*

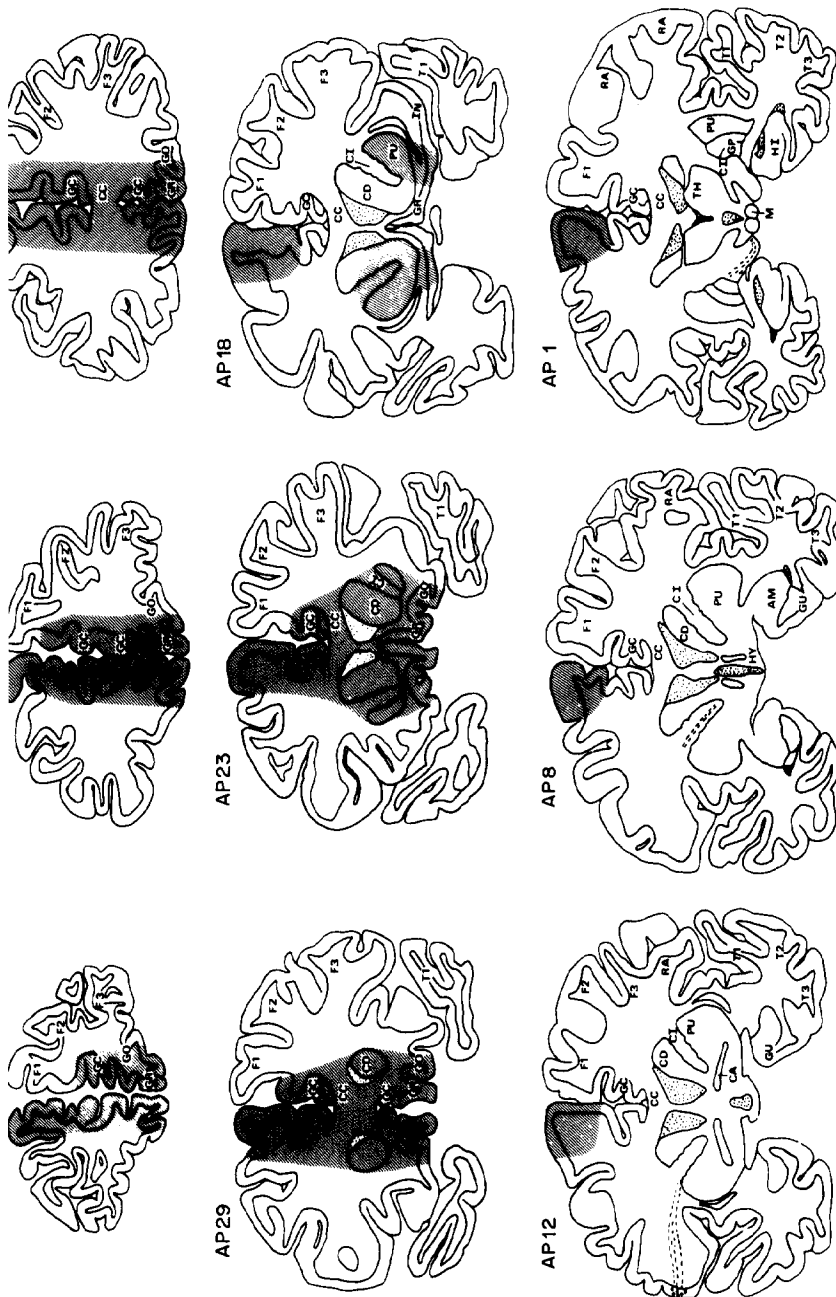


FIG. 2. Lesion site (hatching) reconstructed from Fig. 1. The dots in section AP 12 just above the Sylvian fissure indicate the larynx area within the motor cortex; the dashes represent the cortico-bulbar output of this region. Abbreviations: AM: amygdala; CA: commissura anterior; CC: corpus callosum; CD: nucl. caudatus; CI: capsula interna; F1-3: gyrus frontalis superior, medius, and inferior; GC: gyrus cinguli; GO: gyrus orbitalis; GP: globus pallidus; GR: gyrus rectus; GU: gyrus uncinatus; HI: hippocampus; HY: hypothalamus; M: corpus mamillare; PU: putamen; RA: gyrus praecentralis; T1-3: gyrus temporalis superior, medius and inferior; TH: thalamus.

Intonation Test

In June 1980, during a second stay in our clinic, the patient was asked to utter five short sentences with five different emotional intonations. The sentences were written on a sheet of paper; comments about how these sentences should be spoken were given orally. The five test items were:

1. Emotion: rage; sentence: "*Halt den Mund!*" (Shut up!); comment to the patient: "Utter this sentence in a scolding manner as if you are very angry."

2. Emotion: pain; sentence: "*Au!*" (Oh!); comment: "Somebody steps on your toes thus producing an intense feeling of pain."

3. Emotion: tenderness; sentence: "*Ich mag Dich*" (I like you); comment: "You try to comfort your infant."

4. Emotion: exultation; sentence: "*Prima!*" (Super!); comment: "You express your joy about the fine weather."

5. Emotion: dislike; sentence: "*Ich habe keine Lust*" (I dislike it); comment: "You reject an unpleasant proposal made to you."

The same test was given to four normal male control subjects (average age: 38 years). All utterances were recorded on tape and analyzed spectrographically; they are shown in the form of sonagrams in Fig. 3. A comparison of the fundamental-frequency course between patient P.A. and the control subjects revealed that all control subjects had a greater frequency range than P.A. for all five emotions tested. For instance, the expression of rage was realized by our patient using a frequency range between 120 and 150 Hz; that is, the difference between minimal and maximal fundamental frequency (Δf) of the utterance was 30 Hz. The control subjects showed a Δf of between 40 and 111 Hz, with an average of 80 Hz. For the expression of dislike, the patient used a frequency dynamic Δf of 16 Hz, whereas the control subjects showed a Δf of between 20 and 46 Hz, with an average of 34 Hz. These two examples also show that different emotions were characterized by different frequency dynamics. The lowest Δf in the controls were found for the expression of tenderness (average Δf : 26 Hz), the highest for exultation (average Δf : 146 Hz). It is of interest that our patient also showed the lowest Δf for tenderness (4 Hz), the highest for exultation (81 Hz), even though his values were far below those of the controls. This finding means that the patient is still able to differentiate emotional intonation patterns, but the extent of volitional control and thus the expressiveness of his emotional utterances is greatly reduced.

It may be added that different emotional intonations are not only discriminated by their Δf , but by a number of additional parameters. As there are at present no studies relating specific acoustic features to specific emotional intonations, a detailed comparison between P.A.'s and the controls' intonations is not possible. From the limited material at our




FIG. 3. Frequency-time diagrams (sonagrams) of five different emotional vocal utterances made by the patient P.A. and four control subjects. The numbers above each sonagram indicate the minimal and maximal fundamental frequencies, respectively.

disposal, we may conclude, however, that, apart from Δf , it is the absolute intensity and the amount of noiselike (that is nonharmonic) energy in vowels which seem to be especially important for the differentiation of emotional intonations. For instance, the expression of rage, exultation, and sudden intense pain is uttered louder than the expression of tenderness and dislike. Interestingly, these relationships hold for all subjects, including the patient. The other parameter, namely, amount of nonharmonic energy (especially in the beginning) of vowels, indicates whether the voice is strained or not. Accordingly, that emotion with the lowest amount of nonharmonic energy (that is the most relaxed one) is tenderness, the emotion with the highest amount is pain, with the other emotions being in between. While this parameter differentiates well among the control subjects, it is of little diagnostic value in the patient—which underlines again the reduced expressiveness of P.A.'s emotional utterances.

DISCUSSION

The present study shows that there is a long-lasting (more than 5 years) impairment in the volitional control of emotional vocal expressions after a lesion of both anterior cingulate gyri, medial orbital cortex, rostral striatum, and left supplementary motor area. From this, the question arises as to which part of the total lesion is responsible for this deficit. A review of clinical literature reveals that speech disturbances have been observed in connection with lesions of the supplementary motor area and anterior cingulate cortex but not with lesions limited to the medial orbital cortex and most rostral striatum. The type of speech disturbance reported in the case of supplementary motor-area lesions, if left-sided, is an initial complete mutism of up to 14 days (Botez, 1960; Damasio & Van Hoesen, 1980; Penfield & Rasmussen, 1952; Petit-Dutaillis, Guiot, Messimy, & Bordillon, 1954). This mutism can be, but needs not to be, accompanied by akinesia (Damasio & Van Hoesen, 1980). During recovery, the mutism changes into a state in which the patient repeats sentences spoken to him but shows no or almost no spontaneous speech utterances. Finally, spontaneous speech comes back to more or less normal. Interestingly, during the phase of recovery, the speech shows neither typical aphasic (paraphasic, agrammatic, anomic) nor dysarthric defects (Petit-Dutaillis et al., 1954; Damasio & Van Hoesen, 1980). It is evident that the case history of our patient P.A. parallels that of patients with left-sided supplementary-area lesions. A more exact comparison, however, is hampered by the fragmentary data in the literature. For instance, it remains unclear whether speech recovery after supplementary lesions, as in our case, begins with a state in which the patient is able to whisper but not to phonate verbal utterances. Secondly, no information is available on the postmutistic course of emotional intonation.

Lesions in the anterior cingulate cortex also have been reported to cause mutism (Botez & Carp, 1968; Buge et al., 1975; Nielsen & Jacobs, 1951). In the case of bilateral lesions, this mutism was always accompanied by global akinesia. As none of the patients with bilateral lesions survived the state of akinetic mutism (Buge et al., 1975; Nielsen & Jacobs, 1951) and no details are given for the patient with the unilateral lesion (Botez & Carp, 1968), there are at present no data on speech recovery after anterior cingulate lesions. Furthermore, also those cases in the literature which had a combined lesion of both anterior cingulate gyri together with one or both supplementary motor areas died before having recovered from akinetic mutism (Barris & Schuman, 1953; Buge et al., 1975). Patients with a unilateral (left-sided) combined cingulate-cortex/supplementary-area lesion showed a similar course of speech impairment as those with left-sided supplementary lesions alone (Liepmann & Maas, 1907; Masdeu, Schoene, & Funkenstein, 1978; Rubens, 1975). In the context of emotional vocal utterances, it is of interest, however, that one patient of Rubens (1975) in the initial phase of mutism exhibited voiceless laughing and crying; after having regained the ability to speak aloud, this patient's voice was characterized by monotony.

At present, it thus seems to be impossible on the basis of brain lesions to discriminate the roles played by the anterior cingulate cortex, on the one hand, and the supplementary motor area, on the other, in speech control. This makes it difficult to determine which of the two brain areas destroyed is responsible for the impaired control of emotional intonation. We think, however, there are some hints suggesting that it is the anterior cingulate cortex which, at least in part, is responsible for this effect: (1) Lesions of the anterior cingulate cortex alone can cause mutism and thus also block the volitional control of emotional utterances (see above). (2) Our patient has a unilateral lesion of the supplementary area and a bilateral lesion of the anterior cingulate cortex. As his intonational impairment is practically a permanent one, it is more likely that the bilateral and not the unilateral lesion is responsible for this effect (for unilateral lesions have a higher probability of being compensated functionally—due to the intact contralateral side). (3) The anterior cingulate cortex, because of its intimate anatomical relationship with other limbic brain structures, is in a position especially suited for the control of emotional behavior (Jürgens & Müller-Preuss, 1977). (4) Monkeys trained to do a homologous task similar to the one performed by our patient, namely, to produce emotional vocal expressions volitionally, showed a severe impairment comparable to that of our patient when their anterior cingulate cortex was ablated (with the supplementary area left intact) (Sutton et al., 1974; Aitken, 1981).

Granted that the anterior cingulate cortex is involved in the control of vocal behavior, the question arises as to its specific role in this task.

The fact that our patient neither showed dysarthria nor dysphonia means that the anterior cingulate cortex is neither involved in the motor coordination of the verbal nor of the intonational component of speech. As there also were no paraphasic, agrammatic, or anomie errors, the anterior cingulate cortex obviously does not participate in the planning, ordering, and elaboration of verbal sequences. So we must assume that this brain area has only a modulatory influence on vocal production. More specifically stated, the anterior cingulate cortex seems to function as a drive-controlling mechanism which determines by its activity the readiness to phonate as well as the intensity, viz., the degree of expressiveness, of an emotional vocal utterance. Correspondingly, we find that, if the activity of this region is eliminated more or less completely, as we assume it is in the initial stage of a bilateral infarction, mutism arises. This mutism is characterized by an incapability to produce volitional vocal utterances. Emotional vocal utterances of a nonvoluntary nature, however, are preserved, at least in part, as the pain moans of our patient showed. This corresponds to the monkey situation in which only conditioned (i.e., voluntary) but not unconditioned (nonvoluntary) vocalizations are lost after cingular lesions (Sutton et al., 1974). Despite this similarity, however, the monkey situation seems to differ somewhat from that in man in the sense that cingular lesions in the latter have a much more drastic effect than in the former. While destruction of the cingular cortex in monkey leaves all vocalization types intact and even does not change the frequency of occurrence of the calls (Kirzinger & Jürgens, *in press*), the only emotional utterance to be heard in man is moans of pain, whereas other vocalizations like laughing and crying either are lacking or are produced in a voiceless manner (as Rubens, 1975, describes it for a unilateral cingular-supplementary lesion).

It is of interest that during our patient's recovery phase articulation came back earlier than phonation. Corresponding observations have been made in two patients with unilateral cingular-cortex/supplementary-area lesions by Masdeu et al. (1978) and Rubens (1975). These patients also were able to whisper verbal utterances several days before they could speak them aloud. As this phenomenon has not been reported for the supplementary motor-area lesions leaving the anterior cingulate cortex essentially intact, we think, this is a further argument for the importance of the cingular area in phonatory control.

The last stage of recovery reached by our patient is characterized by the reappearance of his voice. It remains unclear whether this stage is reached due to restitution of the cingulate function by intact cingulate cortex remnants or other brain areas. The fact that the voice remained monotonous and lacked the emotional expressiveness typical for a normal voice is an indication, in our view, that the function of the anterior cingulate cortex has been restituted only partially.

Finally, it should be mentioned that the anterior cingulate cortex is not only involved in phonatory control but has a much wider function. The fact that mutism caused by a bilateral destruction of the anterior cingulate cortex does not occur as an isolated phenomenon but is bound to global akinesia makes this clear. Also, our patient's case history makes it evident that even in the late phase of recovery it was not only the emotional intonation but emotionality in general which appeared flattened. Finally, it should be kept in mind that the anterior cingulate cortex is not the only area the destruction of which can cause impairment of emotional intonation. Ross and Mesulam (1979) described two patients with such an impairment caused by right-sided lesions in the area of the sensorimotor face cortex. Furthermore, it is general clinical experience that also subcortical lesions, particularly in the midbrain (for instance, in Parkinson's disease or after traumatic midbrain lesions), can have this effect (Darley, Aronson, & Brown, 1975). This does not jeopardize the role of the anterior cingulate cortex as proposed above; it just shows that it is not a single brain area but a system which controls emotional intonation.

REFERENCES

- Aitken, P. G. 1981. Cortical control of conditioned and spontaneous vocal behavior in rhesus monkeys. *Brain and Language*, **13**, 171–184.
- Barris, R. W., & Schuman, H. R. 1953. Bilateral anterior cingulate gyrus lesions. *Neurology (Minneapolis)*, **3**, 44–52.
- Botez, M. J. 1960. Clinical contribution to the study of tumoral frontal syndrome. *Psychiatrie und Neurologie (Basel)*, **140**, 347–368.
- Botez, M. J., & Carp, N. 1968. Nouvelles données sur le problème du mécanisme de déclenchement de la parole. *Revue Roumaine de Neurologie*, **5**, 153–158.
- Buge, A., Escourolle, R., Rancurel, G., & Poisson, M. 1975. Mutisme akinétique et ramollissement bi-cingulaire. 3 observations anatomo-clinique. *Revue Neurologique*, **131**, 121–137.
- Damasio, A. R., & Van Hoesen, G. W. 1980. Structure and function of the supplementary motor area. *Neurology (Minneapolis)*, **30**, 359.
- Darley, F. L., Aronson, A. E., & Brown, J. R. 1975. *Motor speech disorders*. Philadelphia: Saunders.
- Goodenough, F. L. 1932. Expression of the emotions in a blind-deaf child. *Journal of Abnormal and Social Psychology*, **27**, 328–333.
- Jürgens, U. 1976. Reinforcing concomitants of electrically elicited vocalizations. *Experimental Brain Research*, **26**, 203–214. (a)
- Jürgens, U. 1976. Projections from the cortical larynx area in the squirrel monkey. *Experimental Brain Research*, **25**, 401–411. (b)
- Jürgens, U. 1979. Vocalization as an emotional indicator. A neuroethological study in the squirrel monkey. *Behaviour*, **69**, 88–117.
- Jürgens, U. 1981. Die Stimme als emotionales Ausdrucksmittel und ihre zentralnervöse Steuerung. *Hexagon* **9**(4), 7–11.
- Jürgens, U., & Müller-Preuss, P. 1977. Convergent projections of different limbic vocalization areas in the squirrel monkey. *Experimental Brain Research*, **29**, 75–83.
- Jürgens, U., & Ploog, D. 1970. Cerebral representation of vocalization in the squirrel monkey. *Experimental Brain Research*, **10**, 532–554.

- Jürgens, U., & Pratt, R. 1979. The cingular vocalization pathway in the squirrel monkey. *Experimental Brain Research*, **34**, 499–510. (a)
- Jürgens, U., & Pratt, R. 1979. Role of the periaqueductal grey in vocal expression of emotion. *Brain Research*, **167**, 367–378. (b)
- Kaada, B. R. 1951. Somato-motor, autonomic and electrocorticographic responses to electrical stimulation of the rhinencephalic and other structures in primates, cat and dog. *Acta Physiologica Scandinavica, Suppl.* **83**, 1–285.
- Kirzinger, A. & Jürgens, U. Cortical lesion effects and vocalization in the squirrel monkey. *Brain Research*, in press.
- Kramer, E. 1964. Elimination of verbal cues in judgment of emotion from voice. *Journal of Abnormal and Social Psychology*, **68**, 390–396.
- Liepmann, H., & Maas, O. 1907. Fall von linksseitiger Agraphie und Apraxie bei rechtsseitiger Lähmung. *Journal für Psychologie und Neurologie*, **10**, 214–227.
- Masdeu, J. C., Schoene, W. C., & Funkenstein, H. 1978. Aphasia following infarction of the left supplementary motor area. A clinicopathologic study. *Neurology, Minneapolis*, **28**, 1220–1223.
- Nielsen, J. M., & Jacobs, L. L. 1951. Bilateral lesions of the anterior cingulate gyri. *Bulletin of the Los Angeles Neurological Society*, **16**, 231–234.
- Penfield, W., & Rasmussen, T. 1952. *The cerebral cortex of man*. New York: Macmillan.
- Petit-Dutailis, D., Guiot, G., Messimy, R., & Bourdillon, C. 1954. A propos d'une aphémie par atteinte de la zone motrice supplémentaire de Penfield, au cours de l'évolution d'un anéurisme artério-veineux. Guérison de l'aphémie par ablation de la lésion. *Revue Neurologique*, **90**, 95–106.
- Robinson, B. W. 1967. Vocalization evoked from forebrain in *Macaca mulatta*. *Physiology and Behavior*, **2**, 345–354.
- Rubens, A. B. 1975. Aphasia with infarction in the territory of the anterior cerebral artery. *Cortex*, **11**, 239–250.
- Schaltenbrand, G., & Bailey, P. 1959. *Einführung in die stereotaktischen Operationen mit einem Atlas des menschlichen Gehirns*. Stuttgart: Thieme.
- Showers, M. J. C., & Crosby, E. C. 1958. Somatic and visceral responses from the cingulate gyrus. *Neurology (Minneapolis)*, **8**, 561–565.
- Smith, W. K. 1945. The functional significance of the rostral cingular cortex as revealed by its responses to electrical excitation. *Journal of Neurophysiology*, **8**, 241–255.
- Sutton, D., Larson, C., & Lindeman, R. C. 1974. Neocortical and limbic lesion effects on primate phonation. *Brain Research*, **71**, 61–75.
- Sutton, D., Samson, H. H., & Larson, C. R. 1978. Brain mechanisms in learned phonation of *Macaca mulatta*. In D. J. Chivers & J. Herbert (Eds.), *Recent advances in primatology*. New York: Academic Press.
- Winter, P., Handley, P., Ploog, D., & Schott, D. 1974. Ontogeny of squirrel monkey calls under normal conditions and under acoustic isolation. *Behaviour*, **47**, 230–239.