

CASE REPORT

drug reactions, phenylpropanolamine;
phenylpropanolamine, reactions to

Phenylpropanolamine: A Potentially Hazardous Drug

Three cases of toxic reactions following relatively small doses of phenylpropanolamine are presented. One patient had a hypertensive crisis and seizures; the others had intracerebral hemorrhages culminating in death. A discussion of the pharmacology of phenylpropanolamine and its previously documented side effects and drug interactions is included. [Bernstein E, Diskant BM: Phenylpropanolamine: A potentially hazardous drug. Ann Emerg Med 11:311-315, June 1982.]

Edward Bernstein, MD*†
Barry M. Diskant, MD*
Albuquerque, New Mexico

From St. Joseph Hospital* and the
Division of Emergency Medicine,
University of New Mexico School of
Medicine,† Albuquerque, New Mexico.

INTRODUCTION

The availability of phenylpropanolamine (PPA) as a decongestant, anorectic, and as a component of "legal-stimulants," or "pic-me-ups" as they are sometimes called, has increased dramatically in the United States over the past five years.¹ With this increase in use has come an increase in the frequency of toxic reactions and overdoses in which PPA plays a role. Between 1975 and 1980, the frequency of PPA involvement in poison control case reports increased tenfold² (Figure 1).

In the past few years there has been increased advertising of over-the-counter anorectic adjuncts, most of which contain PPA.³ Despite the fact that PPA has been known to be associated with hypertensive reactions,⁴ seizures,⁵ and intracerebral hemorrhage,⁶ its use continues to grow. The recent appearance of "look-alike" stimulants (Figure 2) which are virtually indistinguishable from prescription amphetamines, and which generally contain PPA along with caffeine and ephedrine in non-time-released capsules, is especially worrisome.

We recently saw three patients who had severe cardiovascular and central nervous system problems after taking relatively small doses of PPA.

Address for reprints: Barry M. Diskant,
MD, Emergency Physicians, Inc, St.
Joseph Hospital, 400 Walter, NE,
Albuquerque, New Mexico 87102.

CASE REPORTS

Case Number One

An 18-year-old obese woman with no prior history of medical illness presented with severe frontal headache, nausea, epigastric pain, blurred vision, and shakiness 2½ hours after taking two Comtrex® tablets for "congestion."

On initial examination in a physician's office her vital signs were as follows: temperature, 37 C; blood pressure, 210/130 mm Hg; pulse, 120 beats/min; and respirations, 24/min. She was tremulous, anxious and restless, but was noted to be oriented to person, place, and time. General examination was unremarkable. Hydralazine 10 mg was administered intramuscularly and the patient was transferred to a local hospital for further evaluation and treatment. En route to the hospital she had a grand-mal seizure.

On arrival the patient was disoriented and lethargic. Shortly after arrival a second grand-mal seizure occurred. Diazepam 10 mg was administered intravenously, resulting in cessation of seizure activity. Vital signs immediately after the second seizure were as follows: temperature, 37.1 C; blood pressure, 148/98 mm Hg; pulse, 134 beats/min; and respirations, 24/min. A repeat physical examination was unremarkable except for the patient's post-ictal

Fig. 1. Frequency of PPA product mentions in poison control case reports, 1975-80. (From FDA Bulletin.²)

Fig. 2. "Look-alike" stimulants which are virtually indistinguishable from prescription amphetamines.

mental state. Fundoscopic examination was within normal limits.


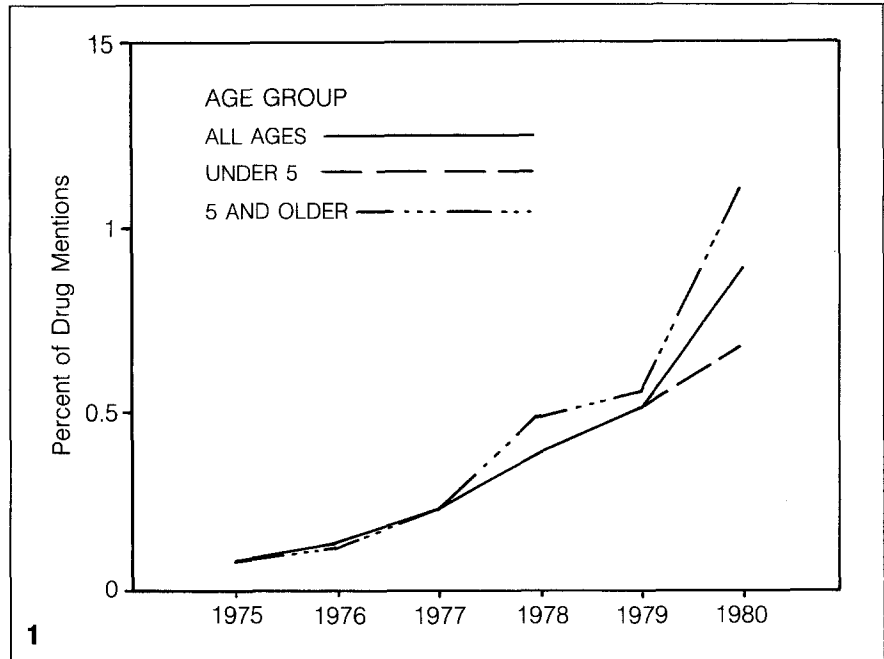
Laboratory data revealed a white blood count of 12,000/cu mm with 54% segs, 17% bands, 24% lymphs, and 3% monos. The hemoglobin was 16.8 g/dl, and the hematocrit was 48%. Serum electrolytes, creatinine, glucose, urea nitrogen, urinalysis, and chest and skull radiographs were entirely within normal limits. The electrocardiogram revealed sinus tachycardia at a rate of 120/min.

The patient was admitted to the intensive care unit, IV D5W was started TKO, but no other drugs were administered. Her blood pressure gradually returned to normotensive levels; it was recorded as 118/80 mm Hg four hours after admission. Her level of consciousness gradually improved, and within 12 hours she was alert and oriented. The initial electroencephalogram (EEG), performed on the day following admission, was abnormal with a basic dysrhythmia of sagittal origin. Subsequent EEG, performed 48 hours after admission, was within normal limits. A radionuclide brain scan, CT scan of the head, intravenous pyelogram, and CT scan of the abdomen were all within normal limits. Twenty-four-hour urinalysis for catecholamines, metanephrines, 17-ketosteroids, creatinine, and protein was within normal limits. Serum cortisol and ACTH were also within the normal range. No drug screen was done.

The patient was discharged on the 16th hospital day. She was free of residual neurologic deficits and required no medication.

Case Number Two

A 26-year-old man drank three to six ounces of whiskey eight hours prior to presentation, and took two black capsules three to four hours prior to admission to the emergency department. The capsules were later identified as "legal-stimulants," each containing caffeine 200 mg, ephedrine 25 mg, and PPA 50 mg. Approximately one hour after ingestion of the capsules he went to sleep and was noted



to be sober and without somatic complaints. Thirty minutes prior to presentation he began vomiting and was said to be "having a lot of trouble breathing," presumably because of upper airway obstruction. A friend cleared his upper airway manually and brought him to the emergency department by private vehicle.

Examination revealed a slightly cyanotic man in obvious respiratory distress who was unresponsive to verbal and noxious stimuli. The vital signs were as follows: temperature, 37.2 C; blood pressure, 134/78 mm Hg; pulse, 60 beats/min; and respirations, 40/min and of the Kussmaul

type. Stridor was present. The pupils were symmetrically dilated, measuring 7 mm across, and were unreactive to light. Fundoscopic examination revealed a large subhyaloid hemorrhage on the right and splinter hemorrhages on the left. The oculocephalic reflex was absent. Neurologic examination revealed no evidence of reflex or motor activity. The patient was flaccid.

Laboratory data revealed a white blood count of 21,000/cu mm with 68% segs, 19% bands, 7% lymphs, 5% monos, and 1% eos. Hemoglobin and hematocrit were 19.4 g/dl and 53.9%, respectively. Initial arterial blood gas determination with the patient on

room air revealed a PO₂ of 52 mm Hg; PCO₂, 36 mm Hg; and pH, 7.33. The serum electrolytes and urea nitrogen were normal; the serum glucose was 147 mg%. Urinalysis revealed a specific gravity of 1.021; pH of 5; 3+ protein; trace occult blood; 50 to 75 white blood cells per high power field; and no bacteria. Chest radiograph revealed diffuse areas of infiltration bilaterally compatible with aspiration pneumonitis.

Toxicology studies were drawn on admission and the results were as follows: blood alcohol, 5 mg%; serum ephedrine, 3 µg/ml; negative screens for tricyclic antidepressants, opiates, glutethimide, and amphetamines. Analysis for PPA was not ordered.

A nasotracheal airway was inserted and an IV of D5LR was begun. The patient was admitted to the intensive care unit. Two ampules of naloxone were administered without noticeable effect. The patient became apneic and required mechanical respiratory assistance. A consulting neurosurgeon thought the patient had suffered an intracranial hemorrhage with possible brainstem herniation.

The patient's blood pressure rose to 156/110 mm Hg and later to 208/148 mm Hg. After several hours in the intensive care unit his blood pressure fell to 80 mm Hg systolic and a dopamine infusion was administered. He remained unresponsive. Approximately 11 hours after admission, he developed ventricular fibrillation and died.

At autopsy, extensive subarachnoid and intraventricular hemorrhage was found. The site of hemorrhage could not, however, be localized. No morphologic vascular abnormalities were noted.

Case Number Three

A 17-year-old man ingested two black capsules which were later identified as "pic-me-up" capsules containing caffeine 200 mg, ephedrine 25 mg, and PPA 50 mg. Shortly after ingestion he became tremulous and agitated, and was unable to sleep. He was oriented and alert during that time. Approximately six hours after taking the capsules there was an abrupt change in his mental status, with agitation giving way to somnolence, confusion, and disorientation. His speech became slurred and incomprehensible.

His family observed him at home, and his brother repeatedly stated that

he was "just crashing from speed," and that the effects would, in time, wear off. The patient became very drowsy and slept for periods of two to three hours at a time. When aroused he remained disoriented. Approximately 17 hours after ingestion, he was brought to the emergency department.

Examination revealed a well-developed white man who was somnolent and disoriented to place, person, and time. Vital signs were as follows: temperature, 37 C; blood pressure, 120/60 mm Hg; pulse, 60 beats/min; and respirations, 12/min. His speech was slurred and could not be understood. He could not follow simple verbal commands. He responded to loud verbal stimuli by speaking nonsensically. He had appropriate withdrawal responses to painful stimuli. Pupils were 4 to 5 mm in diameter, round, equal, and reactive to light. Funduscopic examination was unremarkable. Eye movements were conjugate and the oculocephalic reflex was intact. Deep tendon reflexes were 2+ and equal bilaterally. Babinski responses were flexor bilaterally. Detailed neurologic examination failed to reveal any focal abnormality. Gait could not be tested.

Initial laboratory data were as follows: white blood count, 17,400/cu mm with 67% segs, 25% bands, 4% lymphs, 4% monos; hemoglobin, 16.2 g/dl; and hematocrit, 45.8%. The electrolytes, blood urea nitrogen, serum glucose, and urinalysis were unremarkable, as was the room air arterial blood gas determination. An SMA-20 blood chemistry profile done on the day after admission was within normal limits. Chest and skull radiographs were unremarkable.

Toxicology studies drawn on admission were positive only for urinary ephedrine, detected at 2 µg/ml. No ethanol, opiates, methaqualone, or amphetamines were detected. Analysis for PPA was not ordered.

The patient was admitted to the intensive care unit for observation. Throughout the first day and night he was noted to be drowsy and intermittently combative. Approximately 15 hours after admission, the nurse noted that the patient became deeply comatose. He was unarousable. Decerebrate posturing was observed. Shortly thereafter he had a grand-mal seizure followed by respiratory arrest. Seizure activity was controlled with diazepam 10 mg IV. Additionally phenobarbital

60 mg was given IM. Endotracheal intubation was performed promptly but the patient failed to resume spontaneous respiration. Mechanical ventilatory support was required.

Neurologic consultation was obtained. Pupils were mid-position and unreactive. The oculocephalic reflex was absent. Decerebrate posturing occurred with any stimulation. Babinski responses were extensor bilaterally.

A CT scan of the brain revealed a large intracerebral hemorrhage in the left parieto-occipital area with a moderate mass effect and midline shift. The intracerebral hematoma measured 4 cm in length and 2.5 cm in width. Dexamethasone (10 mg IV followed by 6 mg IV qid) and mannitol (500 cc of 20% solution in a single dose) were given to reduce cerebral edema. Brainstem auditory evoked responses (BAER) performed on the second hospital day were indicative of bilateral brainstem dysfunction.

Maximal supportive therapy was continued. An EEG performed on the fourth hospital day was isoelectric. Repeat BAER showed no evoked potentials. It was concluded that brain death had occurred and mechanical ventilatory support was discontinued. The patient died shortly thereafter.

At autopsy the patient was found to have a massive intracerebral hemorrhage in the left parieto-occipital area. Intraventricular hemorrhage on the left was also noted. No morphologic vascular abnormalities of the intracranial vessels were seen.

DISCUSSION

These three cases raise the interesting and important question of whether the severe reactions reported were individual and idiosyncratic or widespread and part of a continuum of reactions to phenylpropanolamine-containing drugs. There has been recent consumer interest and media coverage of the problems of phenylpropanolamine-containing, over-the-counter, pic-me-up drugs and the diet tablets. The medical community's knowledge of phenylpropanolamine, however, lags behind public interest.

Horowitz et al⁴ demonstrated in a large group of young, healthy, normotensive adults an "important and sometimes potentially dangerous rise in blood pressure may occur even after ingestion of a single capsule of a PPA-containing preparation." The mean supine diastolic blood pressure before taking the capsule was 70 ± 1.4 mm

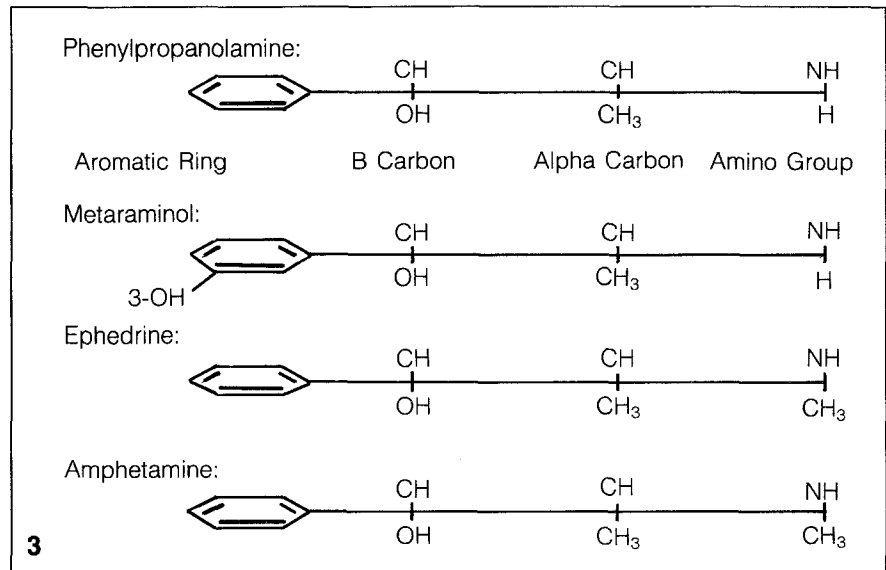
Fig. 3. Structures of phenylpropanolamine, metaraminol, ephedrine, and amphetamine.

Hg, after taking a preparation containing 85 mg phenylpropanolamine, 12 of 37 subjects had a supine diastolic blood pressure rise to 100 mm Hg or more, and one had a rise to 190/142 mm Hg. Because of the very severe effects with the 85-mg preparation, the second half of the study was done on Contac 500® which contained only 50 mg PPA. On the lower dose, only 4 of 34 subjects had a comparable rise in blood pressure. The authors concluded that the response was dose related. The results of this study are especially significant in light of the fact that the Food and Drug Administration has been conducting hearings on whether to allow the pharmaceutical industry to continue incorporating higher dosages of PPA in these over-the-counter anorectics.³

In 1965, Livingston⁷ reported the cases of two young men who had transient BP rises of 180/110 mm Hg following ingestion of single capsules of Contac®. A number of cases in which two or more capsules produced severe hypertensive reactions have been reported.⁸⁻¹² One case reported by King⁶ describes a 37-year-old woman who developed right hemiparesis secondary to a hemorrhage in the left internal capsule following ingestion of two diet capsules, each containing 85 mg PPA.

In addition to hypertensive effects, arrhythmias (premature ventricular contractions, premature atrial contractions together with paroxysms of ventricular and atrial tachycardia) have been reported.¹³ The authors postulate that the vasoconstrictive effect of PPA causes hypertension with a reflex bradycardia which may allow the ectopic pacemaker to assume control of the ventricles.

Another important side effect of PPA is its central nervous system stimulant properties. Although this is less prominent than the stimulant properties of amphetamines, the effects are well documented^{1,14} and are illustrated by our cases. They include restlessness, headache, dizziness, disorientation, confusion and agitation and even hallucinations, and psychosis (convulsions and visual hallucinations were reported in a 4-year-old child taking PPA-containing cold preparations⁵).



Our second and third cases are dramatic examples of the effects of PPA in combination with caffeine and ephedrine. Although severe hypertensive reactions have been reported when phenylpropanolamine was used concomitantly with monoamine oxidase inhibitors,^{15,16} foods containing tyramine,¹⁷ anti-hypertensive drugs such as methyl dopa and oxprenolol,¹⁸ and indomethacin,¹⁹ never before has death resulting from intracerebral bleed associated with the combination with ephedrine and caffeine been reported. The combination and synergistic effect these drugs represent is a new problem arising from the attempt to find a substitute stimulant for the discredited amphetamine preparations. These "look-alike" drugs contain as much as 50 mg PPA and 25 mg ephedrine, and because they usually do not give the user a high equivalent to amphetamine, the user seems more likely to take several pills at a time. Because PPA and ephedrine have a much more pronounced peripheral effect than do the amphetamines, the hypertensive reactions from these stimulants are much greater. These preparations are sold legally in "pic-me-up" shops and mail order houses. Their identification can be extremely difficult for emergency physicians and pharmacists.

Phenylpropanolamine is found in more than 75 over-the-counter preparations, many of which are in widespread use.²⁰ In addition, PPA is contained in such common prescription medicines as Ornade® and Novahistamine®. Despite PPA's great popularity

for the past two decades, many physicians are not well versed in its biochemistry, structural similarities to other potent vasoactive amines, and interactions with other drugs.

PPA has been frequently compared with ephedrine and amphetamine because of structural similarities.¹ Comparison of the structural similarity between PPA and metaraminol (Aramine®) (Figure 3), is especially helpful in understanding their pressor actions.

Phenylpropanolamine has two modes of action: 1) a direct alpha adrenergic action, and 2) an indirect action by virtue of its ability to release norepinephrine from nerve ending storage sites.^{8,19} The OH on the beta carbon enhances both alpha and beta adreno-receptor activity,²¹ while the absence of substitution on the NH amino group enhances the activity and selectivity for alpha agonist action,²¹ explaining the potent vasopressor properties of PPA as well as those of metaraminol. The absence of the OH group on the aromatic ring accounts for the enhanced CNS activity, but also explains why PPA is less potent as an alpha and beta agonist than is metaraminol.

In addition, the methyl CH₃ group on the alpha carbon prolongs and enhances this alpha agonist action.²¹ The CH-CH₃ methyl group blocks the degradation of PPA by monoamine oxidase (MAO), allowing it to persist in nerve terminals and enabling it to release norepinephrine from sites of storage. The methyl group blocks the MAO enzyme in the liver and intestines and prevents PPA's rapid deg-

radation and detoxification. This permits oral administration with good absorption and prolonged duration of action, especially with respect to its peripheral vasoconstrictive action.²¹

PPA and ephedrine (from which PPA is chemically derived) also share structural similarities. The difference between them lies in ephedrine's methylation at the terminal amino (NH) group which increases its potency as a primary amine, especially enhancing its beta adrenergic activity. This explains ephedrine's ability to produce bronchodilatation.²¹ The "look-alike" stimulants that contain considerable amounts of both PPA and ephedrine have potent vasopressor and CNS stimulant properties which could likely be enhanced in the presence of caffeine and alcohol.^{22,23} The pharmacologic interaction of PPA, ephedrine, and caffeine needs further study.

The ability of MAO-Inhibitors (MAO-I) to potentiate the pressor effects of PPA and to cause hypertensive crisis when these drugs are taken together has been explained.¹⁶ The MAO-I, by preventing the degradation of catecholamines, raises their concentration at nerve endings, and thus more catecholamines are available for release by the action of PPA. The interaction of PPA with foodstuffs high in tyramine (such as aged cheese) occurs because tyramine also releases norepinephrine from nerve endings and the synergistic action potentiates the pressor effects of PPA.¹⁷

The effects of indomethacin have been explained.¹⁹ Indomethacin inhibits prostaglandin production. Prostaglandins are known to control a negative feedback loop which regulates the release of catecholamines at the sympathetic nerve endings.¹⁹ The inhibition of prostaglandin formation allows for the unopposed action of PPA in releasing catecholamines. Additionally, indomethacin suppresses production of vasodilator prostaglandins. Because PPA has a direct effect on small arterioles, the absence of vasodilator prostaglandins allows PPA to exert its vasoconstrictor effect unopposed. PPA's direct and indirect modes of action are potentiated by indomethacin. Indomethacin and such other nonsteroidal anti-inflammatory drugs as aspirin are in widespread use, and undoubtedly are used by persons also taking PPA. Therefore, hypertensive episodes with indomethacin and PPA present a greater threat to the public than is generally recognized.

CONCLUSIONS

Recently Blum³ stated, "Clearly the use of phenylpropanolamine poses a danger to the public." His conclusions, though strongly worded, have been voiced a number of times. In 1979, Tonks and Lloyd concluded that, "The therapeutic and prophylactic effects of PPA in upper respiratory tract infections and in serious otitis media have been questioned. Since psychic disturbances including psychotic episodes seem to be a problem, the prescribing of drugs containing PPA should be restricted."¹⁵

Lee et al¹⁹ concluded that, "There is little evidence that phenylpropanolamine produces sustained therapeutic benefit as an appetite suppressant, and its value in nasal decongestants or cough (syrup) linctuses is questionable. In view of the risk of severe hypertension caused by the interaction between phenylpropanolamine and various commonly used drugs, withdrawal of pharmaceutical preparations containing this substance should be considered."

Because PPA is now widely marketed as a substitute for amphetamines as an anorectic, it is not likely that this drug will be restricted or taken off the market for some time.

For two decades phenylpropanolamine has been regarded by the public, the medical community, and the Food and Drug Administration as a relatively safe drug. Our three cases and other cases in the literature give evidence to the contrary. It is our hope that the FDA will recognize that the risk to benefit ratio of this drug is very high, and that it will act in an expedient and responsible manner in removing the drug from all over-the-counter and prescription medicines.

REFERENCES

1. Dietz AJ: Amphetamine-like reactions to phenylpropanolamine. *JAMA* 245:601-602, 1981.
2. *Phenylpropanolamine Weight Control Products*. Bulletin, FDA National Clearinghouse for Poison Control Centers. 25:16-20, 1981.
3. Blum A: Phenylpropanolamine: An over-the-counter amphetamine. *JAMA* 245:1346-1347, 1981.
4. Horowitz JD, Lang WJ, Howes LG, et al: Hypertensive responses induced by phenylpropanolamine in anorectic and decongestant preparation. *Lancet* 1:60-61, 1980.
5. Norvenius G, Widerlov E, Lonnerholm G: Phenylpropanolamine and mental disturbance. *Lancet* 2:1367-1368, 1979.

6. King J: Hypertension and cerebral hemorrhage after Trimolets (85 mg PPA-containing anorectic) ingestion. *Med J Aust* 2:258, 1979.
7. Livingston PH: Transient hypertension and phenylpropanolamine. *JAMA* 196:1159, 1966.
8. Horowitz JD, McNeil JJ, Sweet B, et al: Hypertensive and postural hypotension induced by phenylpropanolamine (Trimolets). *Med J Aust* 1:1975-1976, 1979.
9. Shapiro SR: Hypertension due to anorectic agent. *N Engl J Med* 280:1363, 1969.
10. Wolfgang FC, Duvernoy MC: Positive phenylpropanolamine test in hypertension induced by a nasal decongestant. *N Engl J Med* 280:877, 1969.
11. Ostern S, Dodson WH: Hypertension following Ornade ingestion. *JAMA* 194:472, 1965.
12. Salmon PR: Hypertensive crisis with Eskornade. *Br Med J* 1:193, 1965.
13. Peterson RB, Vasquez LA: Phenylpropanolamine-induced arrhythmias. *JAMA* 223:324, 1973.
14. Schaffer CB, Pauli MW: Psychotic reaction caused by proprietary oral diet agents. *Am J Psychol* 137:10, 1256-1257, 1980.
15. Tonks CM, Lloyd AT: Hazards with monamine oxidase inhibitor. *Br Med J* 1:589, 1965.
16. Cuthbert MF, Greenberg MP, Morley SW: Cough and cold remedies: A potential danger to patients on monamine oxidase inhibitors. *Br Med J* 1:404-406, 1969.
17. Gibson GJ, Warrell DA: Hypertensive crisis and phenylpropanolamine. *Lancet* 2:492, 1972.
18. McLaren EH: Severe hypertension produced by interaction of phenylpropanolamine with methyl dopa and oxprenolol. *Br Med J* 2:283-284, 1976.
19. Lee KY, Beilin LJ, Vandongen R: Severe hypertension after ingestion of appetite suppressant (phenylpropanolamine) with indomethacin. *Lancet* 2:1110-1111, 1979.
20. *Physicians' Desk Reference*, ed 34. Oradell, NJ, Medical Economics Co, 1980, p 311.
21. Weiner N: Norepinephrine, epinephrine, and the sympathomimetic amines, in Goodman LS, Gilman A (eds): *The Pharmacological Basis of Therapeutics*, ed 6. New York, MacMillan, 1980, p 142-143.
22. Rall TW: Xanthines, in Goodman LS, Gilman A (eds): *The Pharmacological Basis of Therapeutics*, ed 6. New York, MacMillan, 1980, p 593-594.
23. Ritchie JM: The aliphatic alcohols, in Goodman LS, Gilman A (eds): *The Pharmacological Basis of Therapeutics*, ed 6. New York, MacMillan, 1980, pp 376, 377, 387.