

## Atrial Myxoma Presenting As Stroke

*Atrial myxoma is rare. We report the case of a 54-year-old woman who presented with findings of a typical acute cerebrovascular accident, which was found to be caused by emboli from an unsuspected atrial myxoma. Unrelated aortic regurgitation also was present. Diagnosis was made by echocardiography. Surgery was performed to remove the tumor; however, the patient remained with a left hemiparesis. The pitfalls of misdiagnosis are discussed and the need for early use of echocardiography in the work-up of stroke victims is suggested. [Barber F, Rosen P, Okin T: Atrial myxoma presenting as stroke. Ann Emerg Med 11:316-318, June 1982.]*

Frank Barber, MD\*\*  
Peter Rosen, MD\*\*  
Thomas Okin, MD†  
Denver, Colorado

From Denver General Hospital,\* St. Anthony Hospital Systems,† and St. Joseph Hospital,‡ Denver, Colorado.

### INTRODUCTION

Approximately one-third of cerebral vascular accidents are due to embolic phenomena.<sup>1</sup> Most frequently these emboli originate from thrombi of cardiac origin in the presence of atrial fibrillation. Occasionally cardiac tumors are the source of emboli.<sup>2</sup> Primary cardiac tumors are found in 0.007% of all autopsies. Of these, 38% are left atrial myxomas.<sup>2</sup> Clinical diagnosis of atrial myxoma is notoriously difficult, and antemortem diagnosis was missed in 50% to 80% of cases before the advent of echocardiography.<sup>3,4</sup>

We discuss the pitfalls of misdiagnosis and suggest the need for early use of echocardiography in the work-up of stroke victims.

Address for reprints: Frank Barber, MD, Denver General Hospital, 750 Cherokee Street, Denver, Colorado 80204.

### CASE REPORT

A 54-year-old white woman was brought to the emergency department after awaking that morning unable to use her left side. There was no history of headache, previous strokes, or seizures. Her only cardiac history consisted of a vague recollection of palpitations years earlier which were never evaluated by a physician and were no longer a problem. She thought she may have been told of a heart murmur, but was uncertain on this point. She was a diet-controlled diabetic.

On physical examination, the patient was alert and oriented. Her blood pressure was 180/80 mm Hg, her respirations, 20/min, and her pulse, 80/min and regular. She was afebrile. Her neurologic examination revealed a dense left central facial nerve palsy, a right gaze preference, paralysis of her left arm, and 1+ strength in her left leg. Sensation was intact. Left toe was upgoing. Cardiac examination revealed a high-pitched diastolic murmur beginning with the second heart sound, an accentuated first heart sound, and an early diastolic sound thought to be an opening snap. The rest of her physical examination, laboratory values, chest film, and electrocardiogram were unremarkable.

A computed tomography scan of her brain was normal initially, but when repeated one week later, it showed an area of infarction in the distribution of the right middle cerebral artery. A 24-hour Holter monitor and oculoplethysmography were normal. Echocardiography revealed classical findings consistent with a left atrial myxoma (Figure 1). Cardiac angiography showed moderate aortic regurgitation. A tumor mass was not visualized. Pulmonary artery pressure was 48/18 mm Hg (mean of 31). Wedge pressure was 13 and aortic outflow pressure was 175/60 mm Hg.

**Fig. 1.** *Echocardiography of an atrial myxoma shows dense echoes of tumor behind mitral valve (MV).*

**Fig. 2.** *Atrial myxoma at surgery.*

At surgery, a myxoma was found attached to the left atrial septum partially obstructing the mitral orifice (Figure 2). Removal led to an uneventful recovery. Five weeks after admission, the patient remained with a left hemiparesis. She was discharged after six weeks.

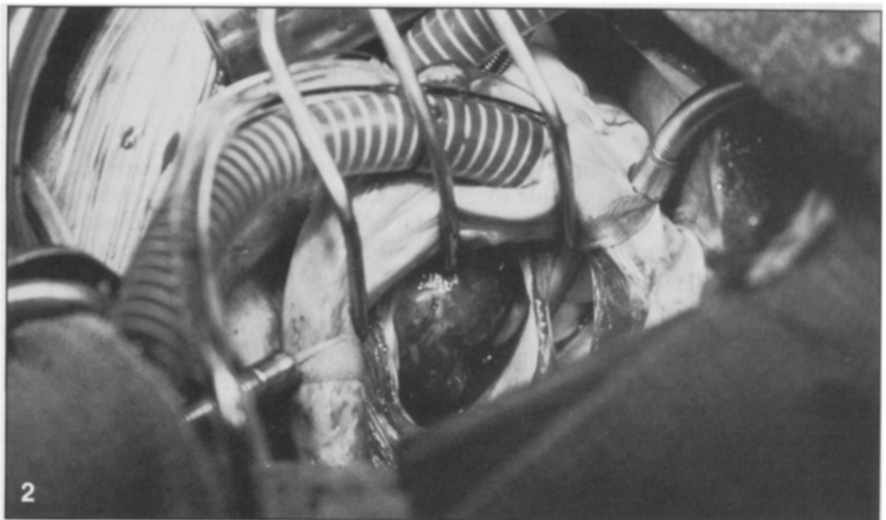
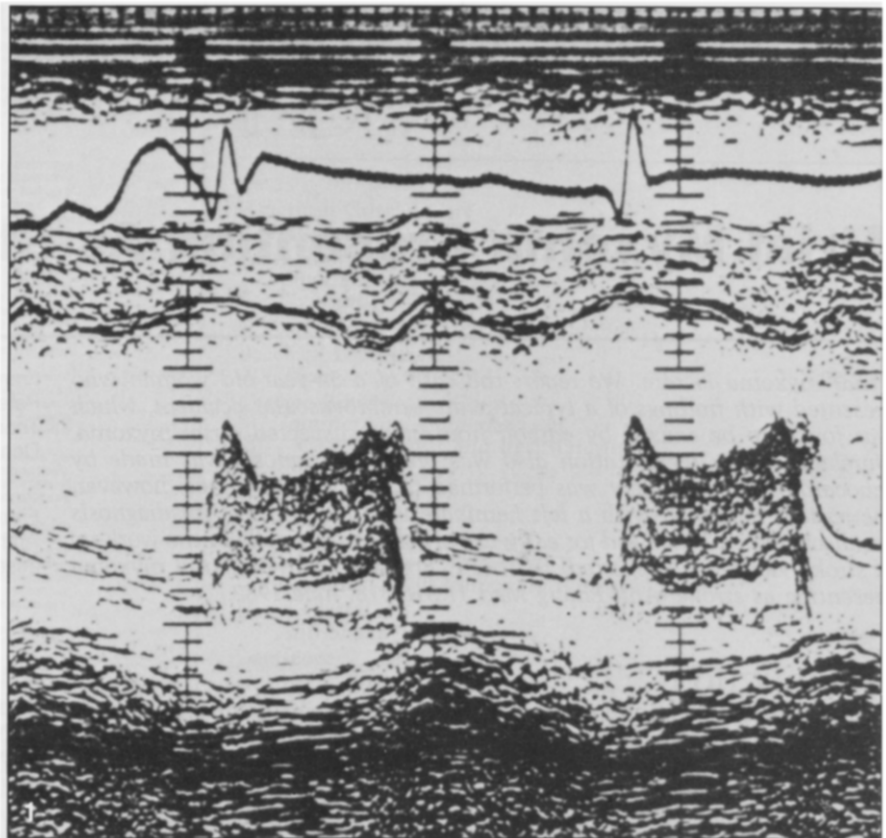
### DISCUSSION

The clinical diagnosis of atrial myxoma is still a significant challenge. The difficulty in diagnosis is due, in part, to its rarity (25% to 35% of strokes are due to emboli, and less than 1% of these are from cardiac tumors<sup>5</sup>), and also because of the variety of presenting signs and symptoms. Between 50% and 75% of patients present with congestive heart failure.<sup>3,4</sup> From 20% to 33% have embolic phenomena (80% of these are cerebral emboli).<sup>3,4</sup> One-third of patients have constitutional symptoms of fever, malaise, and weight loss.<sup>3,4</sup>

The symptoms, of course, depend on the chamber involved. Symptoms of congestive heart failure, neurologic deficits due to emboli, fever, malaise, and weight loss may be due to endocarditis, mitral stenosis, collagen disease, or myocarditis. Classically, auscultatory findings for a left atrial myxoma include an increased first heart sound and early diastolic murmur coincident with a "tumor plop."<sup>4</sup>

One interesting aspect of our case is that the predominant finding was a murmur starting immediately with the second heart sound, a finding more consistent with aortic regurgitation. Cardiac catheterization proved that mild regurgitation was present; because this finding supported the auscultatory findings, the correct diagnosis would probably have been delayed significantly without the availability of echocardiography. The use of cardiac angiography alone in diagnosing atrial myxomas has a false negative rate of 25%, as compared with an 8% false negative rate for echocardiography.<sup>4</sup>

A rapid diagnosis and expeditious corrective surgery can be lifesaving, as a mortality rate of up to 18% has been reported in these patients awaiting surgery.<sup>6</sup> The post-operative mortality for these patients is reported to be



negligible,<sup>7</sup> and should be no higher than that for cardiac surgery in general.

### CONCLUSION

This case demonstrates two important points. The first is a reminder that thrombosis is only one of several etiologies for stroke. Most physicians will think of embolus when a patient presents with a new tachyarrhythmia

or has known intermittent atrial fibrillation or a recent myocardial infarction — all situations in which emboli are common. But it is easy to overlook a more subtle source, such as that found in this case. The murmur was not identified on initial examination, but only on re-examination in a quieter setting outside the emergency department.

The second point is a further dem-

---

onstration of the usefulness of the echocardiogram. In this case, the echocardiogram was the only way to make the diagnosis preoperatively. As discussed, a delay in making this diagnosis can be costly. The availability, relatively low cost, and non-invasive nature of echocardiography make it a procedure worth using early in the work-up of stroke victims. Perhaps echocardiography should be done in the emergency department or in the radiology department along with CT scan as the patient is being admitted, especially in young patients in whom

severe thrombotic disease is less prevalent.

#### REFERENCES

1. Goldstein RJ, Bleich HL, Caplan LR: Computer stroke registry and diagnosis program. Read before the American Academy of Neurology Annual Meeting, Bal Harbour, Florida, May 1975.
2. O'Neil MB, Grehl TB, Hurley EJ: Cardiac myxomas: A clinical diagnostic challenge. *Am J Surg* 138:68, 1979.
3. Bulkley BH, Hutchins GM: Atrial myxomas: A fifty-year review. *Am Heart J* 97:639-643, 1979.
4. Sutton MG, Mercier UA, Lie JT: Atrial myxomas: A review of clinical experience in 40 patients. *Mayo Clin Proc* 55:371-376, 1980.
5. Alpers BJ, Mancoll EL: *Clinical Neurology*. Philadelphia, FA Davis, 1971, p 222.
6. Symbas PN, Hatcher CR, Gravanis MB: Myxoma of the heart: Clinical and experimental observations. *Ann Surg* 183:470, 1976.
7. Glenn WWL, Liebow AA, Lindskog GE: *Thoracic and Cardiovascular Surgery With Related Pathology*, ed 3. New York, Appleton-Century Crofts, 1975, p 1126.