

CLINICAL REPORTS

Cerebral aneurysm presenting with epilepsy

DAVID K. McCULLOCH  
M.B., M.R.C.P.

BRYAN ASHWORTH  
M.D., F.R.C.P.

*The Neurological Unit and University Department of Medical Neurology, Northern General Hospital, Edinburgh EH5 2DQ*

Summary

Two patients with cerebral aneurysm are reported. Both presented with temporal lobe epileptic attacks. In one of the patients there was a family history of aneurysm and cerebral haemorrhage. One aneurysm was recognized by calcification on a plain radiograph but could not be demonstrated by angiography during life. The aneurysms were large and originated from the middle cerebral artery. Previous reports are reviewed. Difficulties of diagnosis and prognosis are discussed.

Introduction

Epilepsy is a rare presenting symptom of cerebral aneurysm (Currie *et al.*, 1971). Aneurysms which cause epilepsy are usually large (Bull, 1969; Kamrin, 1966), and situated on the middle cerebral artery (Höök and Norlen, 1958; Frankel and Alpers, 1955; Ammerman and Smith, 1977). It has been known for many years that cerebral aneurysms are occasionally familial and Bannerman (1970) reported 27 pedigrees.

The authors report 2 patients who presented with temporal lobe epilepsy associated with unruptured cerebral aneurysm. One gave a family history of aneurysm and subarachnoid haemorrhage. The difficulties of diagnosis and prognosis are discussed.

Case 1

A 41-year-old woman was seen in 1972 following a generalized convulsion. Neurological examination and electro-encephalogram (EEG) were normal. Over the next 5 months she described 8 episodes in which she felt an unpleasant taste in her mouth, voices became loud and distorted for several minutes, and she became sleepy and disorientated for about 30 min. Neurological examination was again normal, but her EEG showed continuous underlying delta activity at 2-3 Hz, with some sharp wave discharge over the right temporal area. A right carotid arteriogram (Fig. 1) demonstrated a bilobed aneurysm of the middle cerebral artery, 4 cm long  $\times$  1.8 cm at its maximum diameter. The neck of the aneurysm

appeared to arise in relation to the second and third branches of the middle cerebral artery and was directed laterally, downwards and slightly posteriorly.

At operation the aneurysm was dissected free and excised. Part of the wall appeared exceptionally thin and it was thought that rupture was imminent. Postoperatively she had a transient left hemiparesis but within one week had no neurological deficit. Her EEG continued to show a right fronto-parietal sharp wave focus mixed with delta waves. During the next 2 years she had 3 focal seizures involving the left arm and face, and one generalized convulsion. These were controlled with primidone. Over the next 3 years and, since anticonvulsant medication was withdrawn in 1977, she has remained free from fits. A computerized axial tomography (CAT) scan in 1979 showed slight distortion of the body of the right lateral ventricle and a degree of porencephaly.

The family pedigree is shown in Fig. 2. Her mother died suddenly aged 54 years, but no details are known. One brother died aged 24 years with a subarachnoid haemorrhage originating from a small aneurysm situated at the junction of the left middle cerebral and posterior communicating arteries. The patient's sister died at the age of 38 years, following her second subarachnoid haemorrhage. Another brother died during an operation for aneurysm following a cerebrovascular accident when aged 54 years. Of her 2 remaining brothers, one was drowned at the age of 31 years, and the other is still alive aged 52 years. The patient has 3 children who are well and have not been investigated.

Case 2

A 47-year-old man presented in 1955 following 3 generalized convulsions. In the previous 7 years he had had several episodes beginning with a peculiar sensation spreading from the abdomen to the chest associated with smacking of the lips and tongue, sweating on the forehead, and the sense of voices

Downloaded from https://academic.oup.com/ptm/advance-article-abstract/doi/10.1093/ptm/58.2.94 by University of Cambridge user on 04 April 2019

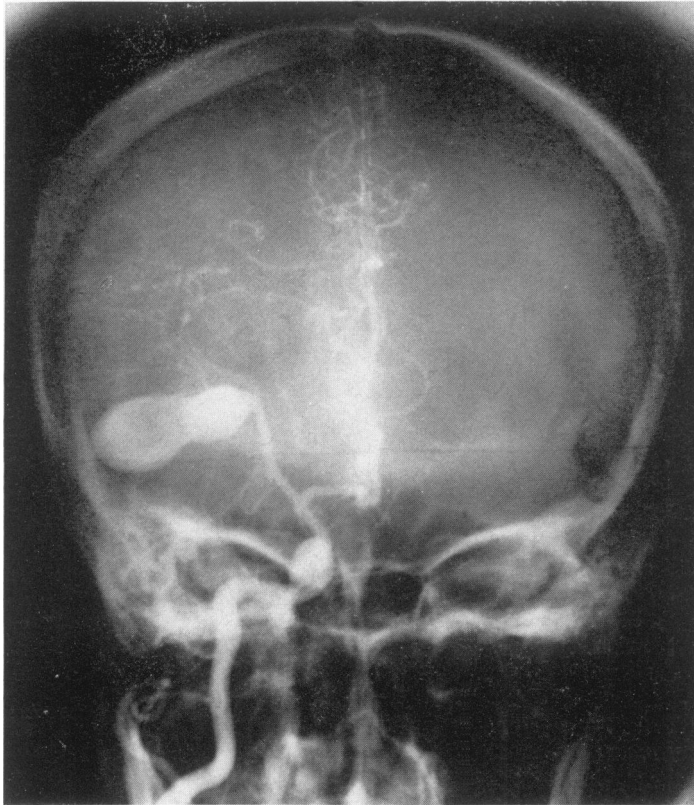


FIG. 1. Right carotid arteriogram of Case 1 showing a large aneurysm of the middle cerebral artery.

sounding distorted and distant. Neurological examination and cerebrospinal fluid were normal. His EEG showed a spike focus in the right fronto-temporal region. Plain skull radiographs showed calcification in the region of the right temporal lobe (Fig. 3). Over the next 14 years, he was treated with

phenytoin and phenobarbitone, and continued to have one or 2 minor seizures each year. In 1969, he had a further generalized convulsion. Neurological examination was again normal and radiography of the skull showed no increase in the size of the calcified lesion. A radio-isotope brain scan was normal and right carotid angiography did not demonstrate a connection of the calcified area to the vascular system. He continued to have infrequent temporal lobe seizures over the next 3 years until he died in 1972, aged 64 years, following massive retroperitoneal haemorrhage from a ruptured atheromatous aortic aneurysm. Post-mortem confirmed the presence of a multilobular aneurysm, 2.5 cm in diameter, arising from the right middle cerebral artery at its bifurcation and embedded in the upper surface of the temporal lobe (Fig. 4). The aneurysm wall was 2 mm thick, fibrous and calcified, and its lumen was occluded by laminated organized thrombus. No other cerebral aneurysms were seen.

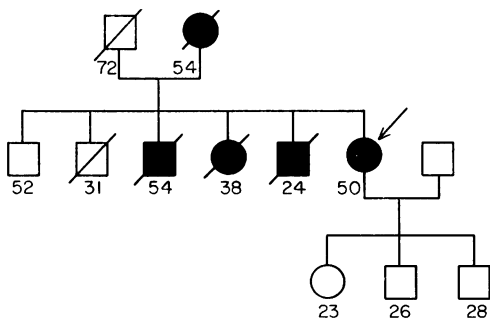


FIG. 2. Pedigree of Case 1. Shading indicates members probably affected; the propositus is identified by the arrow.

**Discussion**

Although it has been recognized for many years

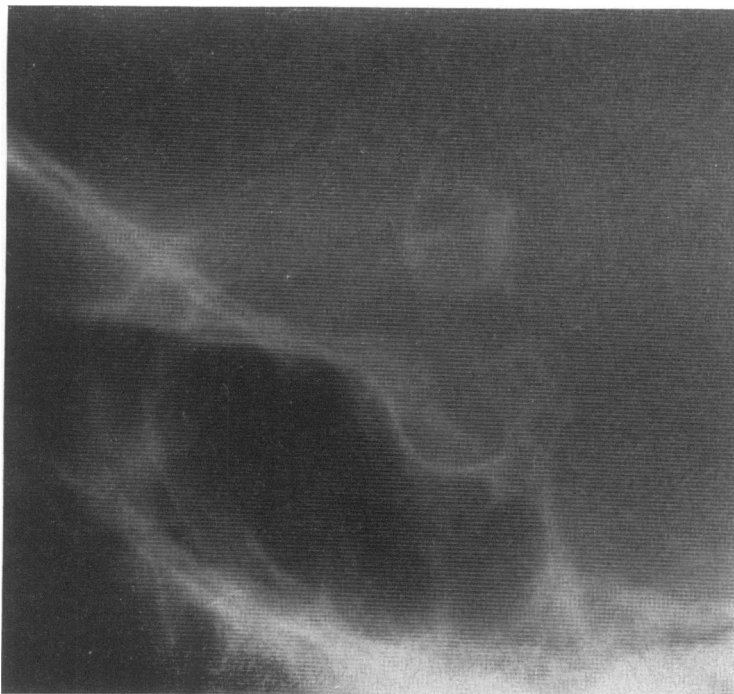

FIG. 3. Detail of plain lateral skull radiograph of Case 2 showing calcification both within the substance of the aneurysm and in the surrounding wall.

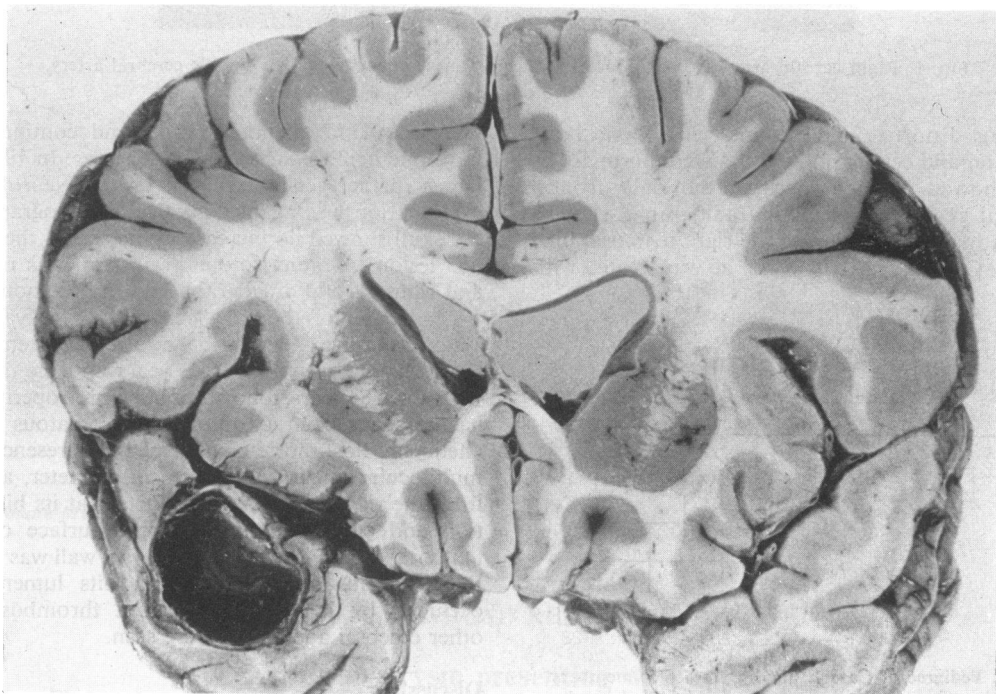


FIG. 4. Coronal section of Case 2 showing the relation of the aneurysm to the temporal lobe.

that cerebral aneurysm may cause epilepsy (Gowers, 1898), this is not common. Currie *et al.* (1971) found an underlying structural abnormality in 169 of 666 cases of temporal lobe epilepsy and only one of these was associated with an aneurysm. Epilepsy occurs most frequently where aneurysms are large (Bull, 1969; Kamrin, 1966; Gowers, 1898), and particularly when situated near the middle cerebral artery (Höök and Norlen, 1958; Frankel and Alpers, 1955). The seizures are usually of temporal lobe type. However, there are no specific clinical features to suggest that an aneurysm is the underlying cause of the epilepsy. A ring of calcification seen on plain skull radiograph, as in Case 2, may alert suspicion (Bull, 1969). Angiography is helpful in the identification of aneurysm in most cases although false negative results are obtained when the aneurysm becomes thrombosed and non-communicating, as in Case 2. Computerized tomography may be used to follow the progress of large cerebral aneurysms (Ammerman and Smith, 1977) but is of no value for exclusion.

A family history of cerebral aneurysm may alert suspicion about the underlying cause of epilepsy, but such associations are rare. Two of the family members in Case 1 had their aneurysm in a similar anatomical site, and this was also noted in over 50% of the pedigrees reviewed by Bannerman (1970).

The prognosis for patients presenting with epilepsy and cerebral aneurysm is difficult to

determine. Case 2 survived for 22 years without any progression of the condition, and other examples with long duration are recorded (Bull, 1969; Kamrin, 1966). It seems likely that in Case 1, if the aneurysm had been left untreated, it would have ruptured. Surgical treatment is advised in most of these patients unless calcification of the wall is demonstrated.

#### Acknowledgment

We are grateful to Mr J. F. Shaw for the surgical treatment of Case 1, and Dr A. F. J. Maloney for the pathology of Case 2.

#### References

- AMMERMAN, B.J. & SMITH, D.R. (1977) Giant fusiform middle cerebral aneurysm: successful treatment utilising microvascular bypass. *Surgical Neurology*, **7**, 225.
- BANNERMAN, R.M. (1970) The familial occurrence of intracranial aneurysms. *Neurology. Minneapolis*, **20**, 283.
- BULL, J. (1969) Massive aneurysms at the base of the brain. *Brain*, **92**, 535.
- CURRIE, S., HEATHFIELD, K.W.G., HENSON, R.A. & SCOTT, D.F. (1971) Clinical course and prognosis of temporal lobe epilepsy. A survey of 666 patients. *Brain*, **94**, 173.
- FRANKEL, K. & ALPERS, B.J. (1955) The clinical syndrome of aneurysms of the middle cerebral artery. *Archives of Neurology and Psychiatry*, **74**, 46.
- GOWERS, W.R. (1898) *A Manual of Diseases of the Nervous System*, 2nd edn, Vol. 2, p. 533. Blakiston, Philadelphia.
- HÖÖK, O. & NORLEN, G. (1958) Aneurysms of the middle cerebral artery. *Acta chirurgica scandinavica*, **235**, 1.
- KAMRIN, R.P. (1966) Temporal lobe epilepsy caused by unruptured middle cerebral artery aneurysms. *Archives of Neurology*, **14**, 421.