

Pontine Hemorrhage Presenting as Ataxic Hemiparesis

ROBERT A. SCHNAPPER, M.D.

SUMMARY A 54 year old hypertensive male developed the sudden onset of ipsilateral pyramidal and cerebellum syndrome: the ataxic hemiparesis syndrome. Computed tomography revealed a small hemorrhage in the contralateral pons. This is an uncommon presentation of pontine hemorrhage and adds to the known causes of ataxic hemiparesis.

Stroke, Vol 13, No 4, 1982

THE CLINICAL PICTURE of hypertensive pontine hemorrhage is felt to be uniform. Coma is of abrupt onset with pupillary miosis, total external ophthalmoplegia, and quadriplegia. Death is the rule and occurs within hours to days.^{1,2} This picture has been somewhat modified since the advent of CT scanning.³ Case reports have documented "submassive" pontine hemorrhage with partial to complete recovery. These have included pure motor hemiparesis,⁴ quadriplegia with bilateral sixth and seventh nerve palsies with total recovery,⁵ and two cases which presented with ocular bobbing with partial recovery.⁶ I report a case that presented with ataxic hemiparesis resembling a well known lacunar syndrome.

Case Report

A 54 year old hypertensive male was admitted with the acute onset of left arm and leg weakness while driving his truck. This was preceded by a dull right occipital headache but no nausea, vomiting, or speech difficulty. Physical examination revealed a blood pressure of 210/135. No ocular or carotid bruits were heard. He was fully alert and oriented and had gaze evoked horizontal nystagmus, moderate left central facial weakness, and mild left hemiparesis arm equal to leg. Finger to nose testing was appropriate in the left arm but on heel-knee-shin testing in the left leg there was a definite ataxia out of proportion to the mild degree of weakness. No tremor was noted and sensation was normal. The gait was wide based and ataxic and a left plantar extensor response was elicited. Computed tomography (CT) revealed an area of abnormal high density in the right mid pons consistent with a pontine hemorrhage (fig.) There was no enhancement with contrast medium. Over the ensuing week, his weakness and gait ataxia resolved. When seen six weeks after the onset, he had only minimal left leg ataxia and some difficulty with tandem walking. A second CT scan showed complete resolution of the pontine hemorrhage.

Discussion

The patient was felt to have a small vessel occlusion because of his hypertension and the clinical picture resembling the lacunar syndrome termed ataxic hemi-

paresis. Fisher coined this term after clinical and pathological studies of patients who had the simultaneous onset of pyramidal and cerebellar deficits.^{7,8} Autopsy studies in three cases revealed infarct cavities in the basis pontis on the side contralateral to the pyramidal and cerebellar signs. In no case was residual hemorrhage found. Ataxic hemiparesis has also been described as a result of lesions in the ventrolateral mid-brain⁹ and superior portion of the posterior limb of the internal capsule.¹⁰

The term ataxic hemiparesis describes a clinical picture and implies neither localization nor pathologic process. Though a cryptic arteriovenous malformation cannot be excluded in this case, a highly localized hypertensive hemorrhage must also be considered since the lesion occurred in the distribution known to

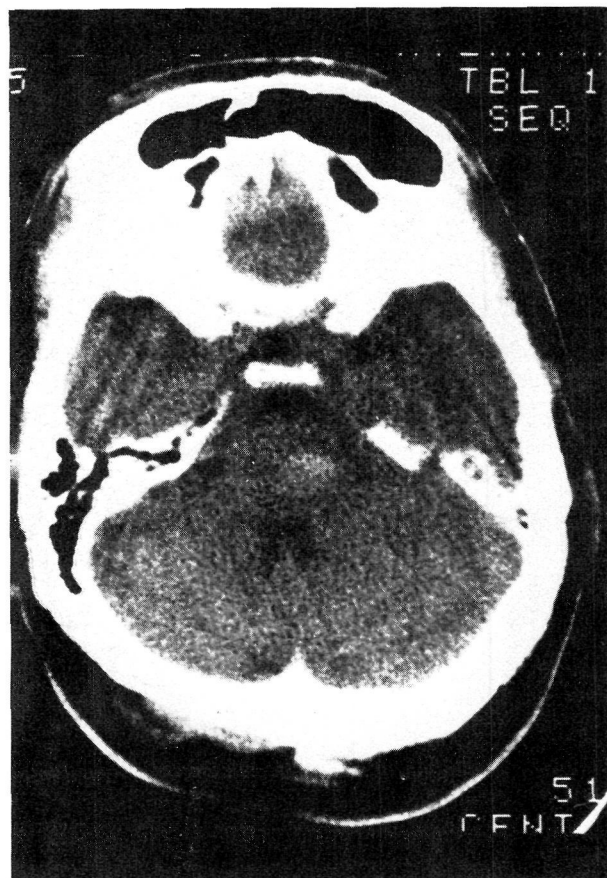


FIG. Unenhanced CT scan showing a small hemorrhage in the right mid pons. There was no enhancement with contrast medium.

From Department of Neurology, Emory University School of Medicine, Atlanta, Georgia.

Address for correspondence: Robert A. Schnapper, M.D., Department of Neurology, Emory University School of Medicine, 69 Butler St., SE Atlanta, Georgia, 30355

Received February 10, 1982 and accepted March 19, 1982.

be the site of the miliary aneurysm of hypertensive cerebral vascular disease.¹¹ Fisher postulated that tumor and demyelinating disease could be the cause for ataxic hemiparesis. To my knowledge this is the first reported case resulting from an intracerebral hemorrhage thus widening the clinical spectrum of this commonly occurring process.

References

1. Silverstein A: Primary Pontine Hemorrhage. *Handbook of Clinical Neurology*. Vicken PJ and Bruyn GW, Editors, North-Holland Publishing Company, Amsterdam, Volume 12, Chapter 3, pp 37-53, 1972.
2. Goto N, Kaneko M, Hosaka Y, Koga H: Primary pontine hemorrhage: Clinicopathological correlations. *Stroke* **11**: 84-90, 1980
3. Payne HA, Maravilla KR, Levinstone A, et al: Recovery from primary pontine hemorrhage. *Ann Neurol* **4**: 557-558, 1978
4. Gobernado JM, deMolina ARF, Gimeno A: Pure motor hemiplegia due to hemorrhage in the lower pons. *Arch Neurol* **37**: 393, 1980
5. Lavi E, Rothman S, Reches A: Primary pontine hemorrhage with complete recovery. *Arch Neurol* **38**: 1320, 1981
6. Kase CS, Maulsby GO, Mohr JP: Partial pontine hematomas. *Neurology* **30**: 652-655, 1980
7. Fisher CM: Ataxic hemiparesis: A pathologic study. *Arch Neurol* **35**: 126-128, 1978
8. Fisher CM, Cole SM: Homolateral ataxia and crural paresis. A vascular syndrome. *J Neurol Neurosurg and Psych* **28**: 248-255, 1965
9. Bendheim PE, Berg BO: Ataxic hemiparesis from a midbrain mass. *Ann Neurol* **9**: 405-407, 1981
10. Perman GP, Racy A: Homolateral ataxia and crural paresis. Case report. *Neurology* **39**: 1013-1015, 1980
11. Cole SM, Yates PO: The occurrence and significance of intracerebral microaneurysm. *J Pathol and Bacteriol* **93**: 393-411, 1967

Analysis of the Gamma Ray Spectra Recorded in the Use of Xenon-133 for Cerebral Blood Flow Studies

D. J. MACEY, B.Sc., Ph.D.,* L. J. FILIPOW, M.Sc., D.Phil.,† S. T. MCCARTHY, M.A., B.M., M.R.C.P.,**
AND M. PITKANEN, M.Sc.‡

SUMMARY A problem in the measurement of cerebral blood flow with ¹³³Xenon is the presence of extra-cerebral counts in the total counts recorded with a collimated gamma ray detector looking at the brain. A method of studying qualitatively the contribution of this extra-cranial component in patients is described. This entails the sequential accumulation of gamma ray spectra recorded during the clearance phase of ¹³³Xenon from the brain. It is shown that different CBF indices are obtained for various regions of the recorded gamma ray spectra. The principal component of the extra-cerebral counts at 15 minutes post-injection appears to be intra-cranial, and not the scalp as assumed previously in the spectrum subtraction method.

Stroke, Vol 13, No 4, 1982

Downloaded from <http://ahajournals.org/> by on April 10, 2024

THE CLEARANCE OF ¹³³XENON from the brain is the most commonly used method for measuring regional cerebral blood flow in man. The radioactive gas is introduced into the brain by inhalation,¹ internal carotid injection,² or recently by intravenous injection.³ The clearance of Xenon is usually analysed by the Obrist two-compartment analysis programme,⁴ although for clinical use, two alternative methods of deriving a cerebral blood flow index have been applied: the two minute slope⁵ and the initial slope index.⁶

Problems in measuring cerebral blood flow arise from the method of introducing ¹³³Xenon, from extra-cerebral contamination, and in choosing a method of analysis. The various cerebral and extra-cerebral compartments are loaded with the Xenon at different rates,

and their degree of saturation depends on the method of administration. The proportion of counts measured from each compartment is therefore affected, and this probably affects the shape of the clearance curve, which, in turn, influences the calculated CBF value.

Risberg et al.⁷ have applied the spectrum subtraction method proposed by Crawley and Veall⁸ to remove the scalp contribution from slow clearing extra-cerebral tissues. Phantom studies indicate that the spectrum subtraction method used overestimates the Xenon in the scalp for two reasons. Firstly, multiple scattering of 80 keV photons results in a significant proportion of counts in the 30 keV energy window defined with a single channel analyser (SCA). Secondly, the skull does not act as a perfect filter for the 30 keV photons emanating from Xenon in the cerebral tissue.

An attempt is made in this paper to study some of the problems associated with extra-cerebral and, in particular, extra-cranial contamination, and to examine the changes in the CBF values that result. The method entails analysis of the changes in the recorded gamma ray spectrum during the clearance of Xenon. The contribution of the scalp counts at any time during the clearance phase can only be estimated if the skull thickness could be determined.

From Department of Radiation Physics* and Department of Geriatric Medicine,** Churchill Hospital, Oxford and Division of Biomedical Engineering and Applied Sciences,† University of Alberta, Edmonton, Canada, and Department of Radiotherapy,‡ Tampere Central Hospital, SF-36280 Pikonlinna, Finland.

Address for correspondence: Dr. D. J. Macey, Department of Radiation Physics, Churchill Hospital, Headington, Oxford, OX3 7LJ.

Received June 17, 1981; revision accepted March 5, 1982.