

VISUAL AGNOSIA IN AN ARTIST¹

Wendy Wapner², Tedd Judd and Howard Gardner

(Aphasia Research Center and Psychology Service, Boston Veterans Administration Hospital,
and Harvard Project Zero)

INTRODUCTION

Visual agnosia as an isolated disturbance in the ability to recognize objects presented visually is no longer accepted uncritically as a syndrome (cf. Bay, 1953; Critchley, 1964; Milner and Teuber, 1968; Bender and Feldman, 1972). Nonetheless, the term *visual agnosia* (or *agnosic-like* disturbances) retains usefulness as a generic name designating all disorders of "higher" visual functions. Moreover, a sufficient number of cases presenting with agnosic-like disorders has now been reported to justify "visual agnosia" as a viable clinical entity, with predictable anatomical correlates (Ajuriaguerra and Hécaen, 1964; Benson, Segarra and Albert, 1974) as well as associated behavioral symptomatology (Newcombe and Ratcliff, 1974; Kinsbourne and Warrington, 1962).

Further studies of agnosic-like disorders can yield a number of dividends. First of all, several forms of agnosia have been posited, ranging from prosop-agnosia to simultanagnosia; the legitimacy of these hypothesized syndromes and the possible interrelations among them merit study (cf. Frederiks, 1969; Brown, 1972). Second, while visual agnosia as a receptive disorder has been carefully studied (Newcombe and Ratcliff, 1974; Kinsbourne and Warrington, 1962; Rubens and Benson, 1971), the effects of this recognition difficulty upon patients' practic capacities has not yet received adequate attention. Finally, a comprehensive understanding of the mechanisms underlying agnosic-like disorders can contribute to better understanding of receptive and practic capacities in normal individuals.

In this paper we report on a former amateur artist who presented with an agnosic-like disorder. His condition seems best described as a form of

¹ This research was supported in part by the National Institute of Neurological Disease and Stroke (through Grant NS 11408-04 and NS 06209), the National Institute of Mental Health (through Training Grant No. MH-13894-03 to Cornell University) and Harvard Project Zero.

² Senior authorship was decided between the first two authors by lot.

simultanagnosia — a special difficulty in recognizing complex objects composed of several parts, or in integrating several disparate elements of a complex scene (Wolpert, 1924; Kinsbourne and Warrington, 1962; Luria, 1966). In addition to analyzing his visual recognition difficulties we collected examples of the patient's premorbid as well as a large number of post-stroke drawings done under a variety of conditions. We paid particular attention to drawing strategies and compensating techniques in order to better understand the effect of a receptive-recognition disorder upon the style and technique of a skilled artist.

CASE REPORT

J.R. is a 73 year old familiarly left-handed male with an occipital cerebral vascular insufficiency. The patient suffered a cerebral vascular accident on 2/11/76 and was admitted to the Neurobehavioral Service of the Boston Veterans Administration Hospital on 2/26/76. His major deficits at that time were a right homonymous hemianopsia, visual recognition difficulties, and a moderate memory disorder.

Personal history

The patient, a high school graduate, was a retired assembly worker and amateur theater director. In connection with his theater work he had for over 40 years done extensive poster work, set sketches and make-up. He reported a ten-year history of peripheral hearing loss and poor memory, especially for names.

Neurologic examination

This patient's examination was normal except for the visual and memory difficulties elaborated below. A brain scan performed on 3/2/76 showed increased uptake bilaterally in the medial occipital region, greater on the left than on the right. An electroencephalogram showed slowing in the left occipital and temporal regions.

Mental status and orientation

Evidence from a battery of psychological tests suggested that the patient's verbal reasoning was essentially intact. He was oriented to place, person, and time of day although he often did not know the exact date. Praxis, left-right orientation, and knowledge of body parts was normal. He was appropriately concerned about his condition. The patient's problems in recognition caused difficulties in finding his way around the ward and in carrying out daily activities. For instance, he had to rely heavily on tactile

information when he was eating and on auditory cues to permit location and recognition of speakers. He was garrulous and would frequently engage in extended conversations.

On formal IQ testing, J.R. received a Wechsler Adult Intelligence Scale (WAIS) Verbal score of 123, but even with no time limits he failed on all items of the Performance section except the Mannikin of the Object Assembly subtest. He answered all of the first 19 questions of the Information subtest correctly with the exception of four questions, all of which had to do with geographical or spatial knowledge. Further testing revealed disproportionate difficulties in answering other questions which depended upon spatial knowledge or visual imagery (for example, "Describe the bedroom in your house.").

Memory

The patient suffered from a moderate memory disturbance, particularly in the retention of new material. His Wechsler Memory Quotient was 98 three weeks after his stroke and 102 near the end of testing two months later. Performance on the visual portions of the Wechsler was again particularly impaired, a result consistent with marked problems in visual retention to be detailed below. The patient showed some impairment of memory for recent and remote public events; however he could often select the answer from multiple choices and he accurately remembered recent events of importance in his life, including the events surrounding his stroke. Aware of his deficit the patient frequently constructed elaborate verbal mnemonics to compensate for it.

Studies of sensory and recognition capacities

Of critical importance in any study of agnosia is an examination of sensory and recognition processing. While cognizant of the controversy about the contribution of sensory deficits to agnosic symptomatology (cf. Bay, 1953; Ettlinger, 1956; Rubens and Benson, 1971) we have sought to avoid this debate by focusing instead on the combination of sensory and higher cortical functions which apparently produced J.R.'s deficits. Accordingly, our test battery included assessment of basic visual capacities; administration of cognitive tasks in which vision plays a crucial role; an inventory of the capacity to recognize and draw under various conditions; and an investigation of certain visual illusions which might illuminate those disturbances most central in J.R.

Basic visual and visual-linguistic capacities

Visual acuity was 20/70 in each eye, both corrected and uncorrected. Visual fields were tested using standard perimetry with a 16 mm² and a

64 mm² white spot moved slowly from periphery to center. Each point was determined several times and the extreme values are represented in Figure 1. Subsequent perimetry testing included presentation with flashing lights and with a black tangent screen. The fields varied appreciably depending upon date and conditions of testing (cfr. Bender and Krieger, 1951).

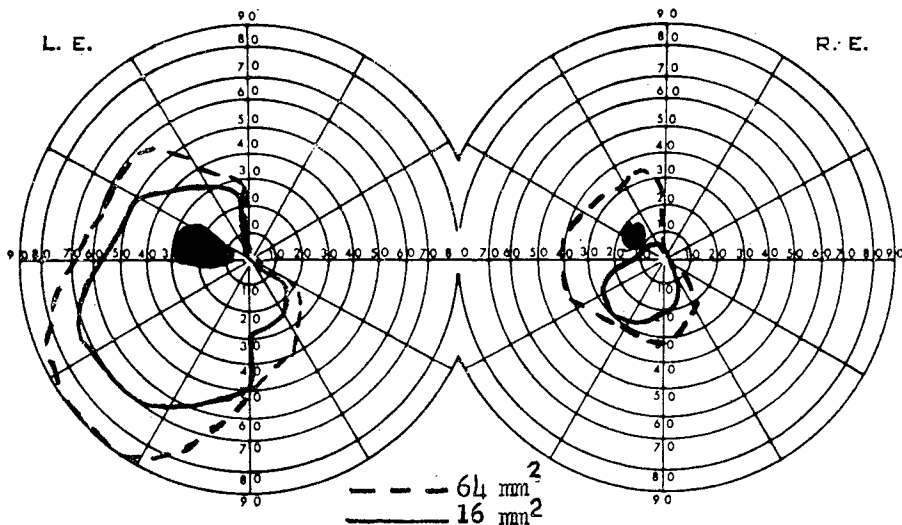


Fig. 1 — Standard perimetry illustrating J.R.'s restricted visual fields.

Although the upper right hand quadrant proved blind in nearly all circumstances, these tests document a considerable range of preservation for function across J.R.'s fields. A moderately dense scotoma was found in the upper left paracentral area. Other areas showed partial functioning: e.g. the peripheral upper left and lower right quadrants were perimetrically blind, yet flashing or rapidly moving stimuli were sometimes detected. Still other areas showed mild impairment: e.g. decreased fade-out time for a stationary stimulus. A mild neglect of the upper left was occasionally noted in some drawing and other tasks.

J.R. had a full range of eye movements with no nystagmus or deviation and a normal optokinetic response. The patient showed a slight impairment in visual tracking in that he could be fooled by sudden unexpected movements. Accommodation and pupil reactivity were normal. The patient's performance on tests of depth perception and on measures of stereopsis including random dot stereograms were normal.

Performance on the Ishihara Test for retinal color-blindness was normal and the patient was able to sort color chips accurately. Nonetheless, the patient often selected inappropriate crayons in drawing (making purple trees and people with purple and green hair) and also sometimes misnamed colors

(cf. Newcombe and Ratcliff, 1974). The patient frequently complained that everything seemed dim as if it were twilight even when it was in fact midday (cf. Critchley, 1964).

The patient read exceedingly slowly. Recognition of letters was most easily achieved by finger tracing either directly on the page or elsewhere. Watching the writing process also greatly facilitated letter recognition. Words were read only on a letter-by-letter basis as is consistent with Wolpert's (1924) definition of simultanagnosia. In contrast to this alexic symptomatology, the patient's writing, oral spelling, and recognition of orally spelled words were normal. The patient could also touch-type full sentences.

Test of recognition

Visual presentation

J.R. was shown several dozen different objects and drawings in both formal and informal testing situations; he consistently failed to identify most (over 75%) of the items. Even his ability to recognize the most common and simple items, such as a comb or a fork, proved inconsistent.

When unable to recognize an object, J.R. would describe the object, hoping to deduce its identity from his own remarks. He explained, "I have to use my mind to interpret what I'm seeing. My eyes used to do that." For instance, confronted with a drawing of two giraffes, he would reason, "The way this comes down, this could be an animal, four legs and a tail... a long neck comes up, an awfully long neck... here's a head because here's an eye... two crude drawings of some kinds of animals... not a mouse God knows... what would have such an extraordinary long neck?... a giraffe." In the course of such descriptions, the patient mentioned a broad range of attributes; he usually began with obvious basic shapes, such as overall shape, protruding parts, and prominent geometric forms like squares, rectangles and circular parts such as wheels; then he proceeded to possible functional aspects, such as natural or manufactured appearance, material, weight distribution, means of support, means of manufacture, and possible uses. Yet, though his procedures were quite logical, only occasionally was J.R. able to infer the identity of the object. Similarly when shown a more intricate drawing, or a magazine photograph, J.R. could at best discern specific elements, and was never able to describe the whole scene.

Severely prosopagnosic, the patient was never able to recognize his son, brother, or familiar hospital staff such as his doctor or the authors. Nonetheless, the patient scored well on a standard test of facial recognition, when exact matching was called for [correctly responding on 5/6 of the items (where chance is 1/6) on the first of the unpublished Benton-van Allen test for facial discrimination]. His successes were apparently due to his ability to match specific details in the faces, such as the angle of a hairline.

J.R.'s scores dropped radically when he was instead asked to match faces portrayed from different perspectives (answering 12/21 correctly, when chance was 1/2), or to match exact faces with no opportunity for repeated comparison (12/18, when chance was 1/2). These latter tasks make a heavier demand on visual imagery and visual memory.

While J.R.'s drawing performance is detailed below, it is germane here to note his poor performance on another test tapping visual memory and imagery — the unpublished Berea Visual-Motor Gestalt test. Gross distortions, simplifications and breaks in configuration were present in 13 out of 15 drawings of figures done from memory immediately after examining each for 10 seconds; all drawings significantly improved in the presence of the model. Also, after looking away from a stimulus for as little as one second, J.R. was often unable to recall having seen it before.

Recognition in other modalities

In sharp contrast to his poor visual recognition, J.R. was quite accurate at identifying objects through tactile presentation. For example, on visual presentation, he identified only three of 25 common objects, namely scissors, a hammer, and a book of matches. On tactile presentation however, twenty were correctly identified. Attempts to test auditory gnosis were confounded by his pronounced hearing loss: when tested purely on auditory cues J.R. was only able to get 6 out of 16 correct. However, auditory recognition remained superior to visual recognition. Asked to identify a bell, whistle, harmonica, hammer, and comb on auditory presentation, J.R. accurately named all but the comb. None of these objects was recognized on visual presentation.

The nature of J.R.'s gnosic difficulties

The above findings suggest some tentative conclusions concerning J.R.'s recognition difficulties. The absence of paraphasic responses, the ability to write, and the inability to indicate object recognition in any fashion, all indicate that J.R.'s problem was not secondary to a linguistic deficit. Analogously the patient's superior performance on tactile presentation, and the absence of circumlocutory responses indicating knowledge of the object's identity, suggest that his problem did not derive from a linguistic naming deficit.

Evidence that the patient did not have a general problem with recognition comes from his superior performances on auditory and tactile presentation. Any attempt to attribute the difficulty to confusion is belied by his superior performance on the intelligence tests and the patient's capacity to follow and participate appropriately in conversation. Finally, were this artistically-trained patient experiencing a complete stimulus "stripped of its meaning,"

his ability to copy complex objects, line drawings, and the WAIS block designs should have been more fully preserved.

J.R.'s problems in elementary visual functioning, such as scotomata and limited visual fields, have been noted above. This combination of visual defects may conceivably account for the patient's difficulty (but cf. Ettlinger, 1956; Rubens and Benson, 1971; Geschwind, 1965). It seems more probable, however, that J.R.'s visual difficulties were compounded by impaired immediate visual retention, possibly a component of his more generalized memory disturbance. Suggestive evidence favoring this hypothesis are the severe depression in Barea and face-recognition scores immediately following a removal of the model; the relatively low score on visual reproductions in the Wechsler Memory test; the inability to recognize objects and drawings seen a few moments earlier; and impoverished knowledge of visual-spatial features of the ward.

A further related deficit is suggested by the patient's poor performance on those items of the WAIS which required visual-spatial processing; his parallel failure on other questions concerning geography and geometry; his inaccurate and inconsistent drawing from memory of familiar objects (cf. figure 7 below) and familiar scenes such as the apartment complex in which he had lived; his description of objects which relied heavily on functional attributes to the conspicuous neglect of visual aspects; and a reported lack of dreams since his stroke. These findings can be parsimoniously described as a deficit in visual imagery, defined here as the ability to utilize presumed mental representations — possibly in visual form — of visual-spatial information to solve problems, make drawings from memory, give descriptions of visual features from memory, etc.

Such considerations suggested that J.R.'s difficulties may well have resulted from the combined effects of selected elementary visual deficits, an impairment in visual memory and a possibly-related difficulty with visual imagery. Fluctuating function of the peripheral portions of his visual fields and pattern completion across his paracentral scotoma may have produced a considerable distortion to his visual world, of which he may have been unaware. His restricted visual fields made scanning necessary in order to take in the entire scene, yet his impaired visual retention probably interfered with the integration of information acquired from successive fixations. Impaired visual imagery capacity may have limited his capacity to infer the identity of an object from faulty clues.

Some revealing data concerning J.R.'s hypothesized difficulty in integrating new information from successive fixations comes from a study of the patient's perception of certain visual illusions. On a series of standard illusions and special effects (Necker cube, Kopferman cubes, Schröder staircase, reversible craters and blisters, corridor, Ponzo, Müller-Lyer, and Hering illusions, all from Kaufmann, 1974), including many requiring a sensitivity

to depth, his performance was normal. However, his reports were systematically abnormal when presented with the class of illusions called *subjective* or *anomalous contours* (Schumann, 1904; Kanizsa, 1976).

Subjective contours are visual displays which create in the viewer the experience of perceiving a contour or form which is not actually present in the stimulus. For example, Figure 2 is perceived by most observers as a solid white triangle resting on top, and thereby obscuring segments of the other forms. J.R. reported this figure as "a three-cornered thing... I see three edges, and three circles," adding "if you drew lines along the rest of the way (indicating the lines suggesting a broken triangle, not the subjective contour) then mentally you could make a triangle." Similarly when presented with partially occluded figures, for example a circle drawn on top of a triangle such that all but its three tips were occluded, J.R. failed to appreciate the relation among the parts and simply reported "a circle with three wedges on it." Here, as in each of the other eight examples presented, J.R.'s descriptions and drawings focused on the individual elements physically present, omitting, despite probing, any reference to the subjective occluding figure.




Fig. 2 — *An example of a subjective contour.*

It should be noted that J.R.'s perception of subjective contours was normalized by stereoscopic presentation in which the subjective occluding form was made to appear closer to the viewer. This result is reported on more fully in Stevens (1976).

J.R.'s difficulties with the subjective contours, in the face of his ability to perceive other illusions, seem explicable in terms of the combination of factors cited above. Were his visual memory intact, but his visual fields

deficient, he should have been able to scan the stimulus rapidly and recall enough of what had been previously seen to "get" the effect. Were his fields intact, he should have been able to see at least some of the subjective contours at one glance (as he had seen several of the illusions) and would not need to rely on his memory. The combination of these factors, however, appears to account for the essential features of J.R.'s agnosia, and may even help clarify the entire syndrome of simultanagnosia.³

Studies of drawing

An analysis of J.R.'s drawings is best undertaken in light of some considerations about drawing processes in naive and skilled artists. Young children and naive artists rely heavily in their drawing activity on what has been termed a *schematic* approach (Bartlett, 1932; Gombrich, 1960; Luquet, 1927). These individuals have mastered certain graphic formulae (and/or motor patterns) for depicting familiar objects (a house, a cat, a person); they simply reproduce these "schemas" as the occasion requires. To be sure, some modifications will be made in portraying a specific house or person but, in general, depictions of members of the same class markedly resemble one another in this schematic approach.

Skilled artists have a wealth of such schemas at their disposal. In addition, however, artists in Western society will have gained a set of skills which enables them to draw in a *veridical manner*: By drawing on such techniques as rules of perspective and foreshortening and methods for portraying shadows and textures, they are able to portray a person or object so that it resembles a particular member of the class and may even at times achieve photograph-like fidelity to the model (Gombrich, 1960).

Studies of drawing by brain-damaged patients have necessarily focused on the products of individuals without special training in the arts. Differences have been reported with reference to site of lesion (Warrington, 1969; Kaplan, 1975) but these findings shed light chiefly on the schematic approach. A few case reports exist of famous artists who have suffered unilateral brain lesions (for a review, cf. Gardner, 1975); these isolated descriptions indicate that a brain-injured artist displays certain symptoms of the non-artistic individual, but that the artist's style may be preserved despite considerable pathology (Jung, 1974). In all, however, the literature on brain-damaged artists is still too scanty to allow generalization; and even less information exists on the artistic output of agnosic patients (cf. Brain, 1941; Newcombe and Ratcliff, 1974).

³ J.R.'s field defects and impaired visual retention can be mimicked in normals to a first approximation by an apparatus which provides a restricted field of vision and a very slow scanning speed. Informal experimentation with such an apparatus seems to duplicate the subjective experience reported by J.R. on partially occluded figures and subjective contours.

The case of J.R. offers a unique opportunity to examine the role assumed by reception-recognition factors in artistic performance. It is possible to examine the effect of brain damage upon a highly developed skill, including the lesion's impact upon the patient's premorbid style, approach, thematic proclivities and the like; to probe specific effects of the receptive disorders; to uncover compensatory mechanisms; and to determine which stimuli and condition of presentation aid the artist in his work and which pose difficulties.

In characterizing J.R.'s drawings, it is useful first to indicate those features which typified his post-morbid drawing. Against this background, it is then possible to isolate three additional factors which affected the quality of his post-morbid drawings: the complexity of the object (or "target") being drawn; the conditions of presentation of the "target" (three-dimensional object, line-drawing, photograph, or a mere verbal instruction); and the presence or absence of knowledge concerning the identity of the object being depicted. Though these three aspects are closely inter-related they will for the purpose of exposition be discussed separately.

Characteristic of post-morbid drawings

Perhaps the chief characteristic of J.R.'s drawing was his tendency to lose his place while in the middle of drawing. Whether this disorientation was due primarily to a difficulty in recognizing what he had done, or an impairment in visual memory, could not be ascertained. Such confusion gave rise to a number of recurring practices. Sometimes J.R. would neglect features of the object, for example, leaving out the nose and far wing of an airplane (cf. Figure 3) or the receiver of his telephone (Figure 4). If it was suggested to him that his drawing might be incomplete, J.R. would carefully recheck his drawing. However, attempts to compensate usually



Fig. 3 — Overdrawing (of the propellers) and neglect of features (such as the nose of the plane and the far wing - added later) demonstrated in J.R.'s copy of a toy airplane.

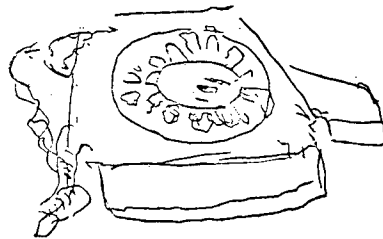


Fig. 4 — Initial omission of the receiver in copy of a desk telephone. The fixture was added later incorrectly.

resulted in the feature being misplaced or drawn out of proportion to the rest of the object. Sometimes J.R. would redraw a feature that already had been depicted: the patient would refocus on an area previously noted and unknowingly recopy it. The results were such anomalies as a five-legged rhinoceros, an accordion with three keyboards, and an airplane with a multitude of propellers.

Particularly when confronted by more complex targets, J.R. exhibited difficulty in differentiating between insignificant details and the defining features of the object. For instance, in copying a drum, he elaborated the design of the decorative figures on the side at great length but neglected to complete the external contour. Yet, despite these deficiencies, J.R. rarely drew directly on top previous lines. This scrupulousness was no doubt due in part to his perception that lines were already present; yet his ability to draw for some seconds even when not attending to the paper suggests a preservation of motor memory which may have contributed significantly to the effectiveness of his drawings.

Factors determining complexity

The patient was able to draw with greater speed and accuracy those objects which were relatively simple, while experiencing great difficulties with more complex objects (cf. Critchley, 1964). Specific factors which gave rise to complexity included the number of different parts or forms comprising the object, the number of shapes found in a target, and the number of irregular lines and angles. J.R.'s inability to recognize complex objects undoubtedly contributed to his difficulties in drawing them.

Conditions of presentation

The factor of complexity can be substantially controlled when an individual is asked to draw the "same object" (or members of the same class) presented under various conditions. Conditions can range from the most naturalistic copying (presentation of the actual physical object) to various two-dimensional representations (photographs and line drawings) to a verbal command, where the patient is merely told what to draw. In what follows, we describe specific problems and strategies encountered under various conditions of stimulus presentation.

Obviously familiar with techniques for transposing a three-dimensional target onto a flat piece of paper (Pirenne, 1970), the patient drew upon a set of well-practiced skills. His first step was to "locate the vanishing point" and properly align his paper with the object. Aware that forms are frequently not described fully by contours, the patient would occasionally use shadow to define his form as in the foreshortened leg of the doll in

Figure 5, or to indicate a change in plane, as illustrated in the darkened base of the opposite foot. Another favored technique included the drawing of a double line "to represent thickness."



Fig. 5 — Copy of a Raggedy-Ann doll. J.R. employs shadow and line to demonstrate foreshortening and thickness.

The copying of two-dimensional representations, while not requiring the reduction of physical objects to geometric shapes, presented other problems. Discrimination of photographs depends heavily upon color and light/dark contrasts to create edges and define shapes, cues which were difficult for utilize. As a result, he rarely recognized the objects in the photograph; indeed he had trouble even finding contours, evidenced in his complete elimination of the shadowed underside of one wing of an airplane as external to the main body (cf. Figure 6). Simple line drawings proved easier for J.R. to copy accurately, whether or not the picture was recognized. One problem did prove specific to line drawings: J.R. could not differentiate lines of the background from those comprising the foreground figure, and tended to run them together.

When merely instructed to draw an object, J.R. relied almost exclusively on a verbal program. This program was remarkable for its lack of visual information; nearly every feature mentioned was an element necessary for the object's use rather than a characteristic of its physical appearance. Typically, J.R. would catalogue all functional components of the target item, drawing each feature as he listed it. Thus, a telephone was constructed with the following reasoning: "It needs a base for it to stand on, a place to speak into, something to hear with, a wire to plug in for communication, and a place to dial." A striking demonstration of J.R.'s lack of a visual

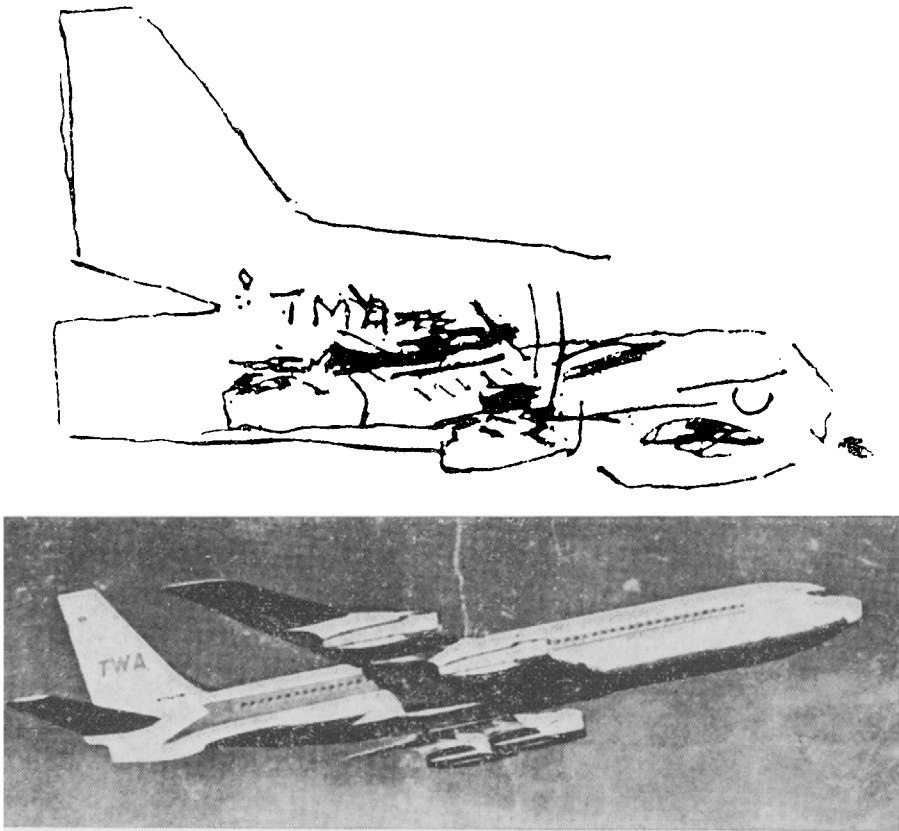


Fig. 6 — J.R.'s copy of a photograph of an airplane. Note difficulty in distinguishing edges and shapes when contrasts of light and dark are the only cue.

image from which to work can be seen by comparing four telephones designed on four different occasions, each accompanied by essentially the same requirements mentioned above (cf. Figure 7).

The only exceptions to this "verbal-functional" strategy came when J.R. was drawing items from memory which he had drawn quite frequently premorbidly, e.g. faces and stage sets. Here his verbal program also included visual features as he drew them, usually in a stereotyped order. It was only these frequently drawn items which bore a strong resemblance to "real-life" objects.

Knowledge of the identity of an object

Perhaps the most striking feature of J.R.'s drawing was his ability to draw an object with accuracy despite his inability to recognize it. Even as he failed repeatedly to produce a drawing which he himself could recognize,

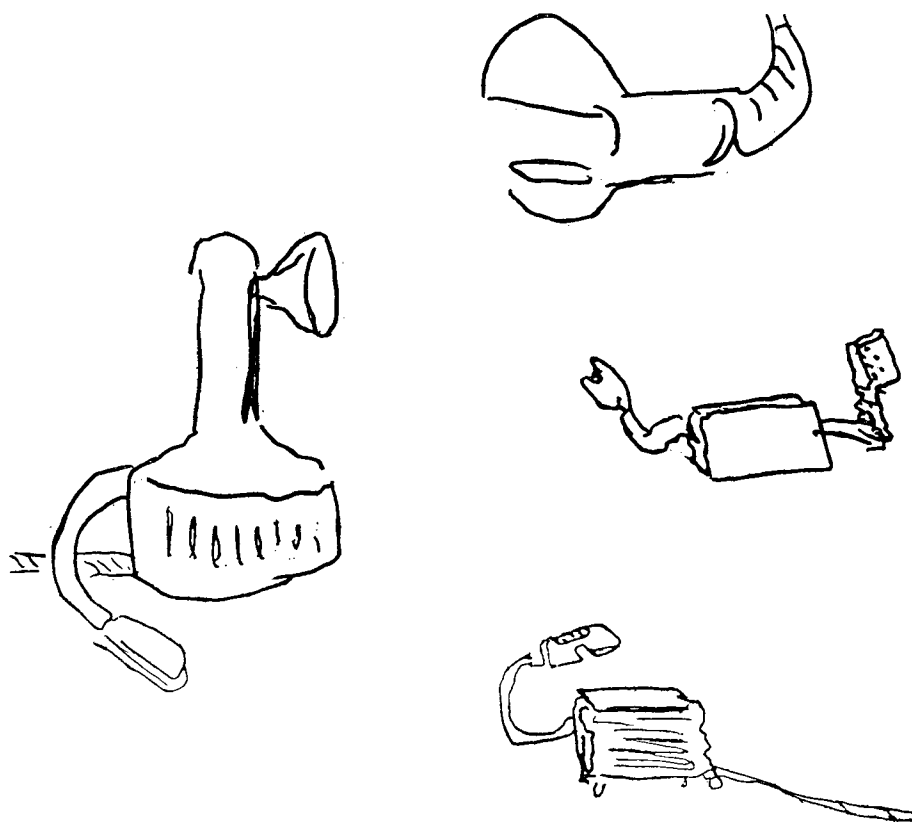


Fig. 7 — Four examples, from different days, of J.R.'s attempts to draw a telephone on request with no model present.

he nonetheless revealed, in his slavish movement from one part of the target to the next, the specific details he was apparently able to perceive. For instance, when producing a copy of a telephone (Figure 4) his comments referred almost exclusively to basic shapes, quite unlike his functional dissection of a telephone mentioned earlier. Describing the dialing apparatus, he said, "a circle, another circle, a square... things keep coming out... they're round, not oval... and this is as though it hooks onto something." Attempts to guess the objects identity were usually unsuccessful: When asked if he knew what he had drawn he replied, "No I'm just following the line."

Asked to draw an object that he could correctly identify, the patient no longer drew meaningless shapes. Rather, relying upon a preserved knowledge of the essential components of an object, he was able to employ schemas in his depiction. His verbal descriptions were accordingly far more explicit. Presented with a soup spoon, he remarked, "I see a big spoon, I think the spoon is metal, you could use it in the kitchen to dish out things," thus

indicating not only recognition of the object but also its physical attributes, function, and customary location. The patient completed his drawing rapidly and purposefully, producing a sketch that was faithful to the specific target as well as to the general class of objects.

An even clearer example of this non-slavish approach can be found in J.R.'s depiction of a watch. Knowing how the object should appear, he entered the 12 on the top, the 6 on the bottom, and then sequentially filled in the other numbers, commenting, "If I were doing it for a poster or something, I'd just try to get the effect." This contrasts sharply with his slavish copying of the numbers on the unrecognized telephone. The patient himself summarized his approach to recognized objects by adding, "can't help but use your natural knowledge in drawing the thing."

Comparison of pre- and post-stroke drawings

A comparison of pictures drawn by the patient before his illness (cf. Figure 8) with post-stroke drawings reveals interesting similarities and differ-




Fig. 8 — An example of a typical stage set drawn by J.R. before his stroke.

ences. The patient was instructed to "Draw a room" and the results of his effort can be seen in Figure 9. Most outstanding is the constancy of style between the pre- and post-stroke drawings. Use of line, concern with detail, and mode of composition have all survived, perhaps in exaggerated form (cf.




Fig. 9 — *The results of J.R.'s efforts when requested to draw a room without a model present.*

Jung, 1974; Gardner, 1975). Nonetheless, certain effects of his defect can also be noted. The two windows, not drawn consecutively were of different heights, and each was adorned with its own style of drape. The line in the middle of the page is a mistake of overdrawing; seeing the angle of the nearby chair, J.R. assumed that he had forgotten to draw in the angle of the corner of the room, and added the unnecessary line. As noted above, color anomalies were also present in his post-stroke drawings. Other technical difficulties resulted from his mechanical awkwardness: his hand tended to shake while drawing, making it difficult to achieve a clean, straight line.

When requested to draw an actual room (Figure 10), J.R. used a radically different approach. Rather than sketching in the edges of the room as guidelines, he began by drawing the main central object, the desk, and slowly worked his way towards the perimeters, first right, then left. This procedure yielded a slightly off-balance picture, which included the repetition of certain features.

A useful overview of the patient's post-stroke drawing ability was obtained by asking him to copy an original silk screen which resembled old stoves he had drawn in pre-stroke sets (cf. Figures 11 and 12). When first



Fig. 10 — A drawing of the office in which the patient was working.




Fig. 11 — An original silkscreen of a rooster perched on top of a pot-belly stove.



Fig. 12 — J.R.'s copy of the silkscreen.

shown the unfamiliar silk screen, he remarked, "Maybe that's a life form perched on top," but could not say on top of what. While in his drawing the tail of the rooster was included, "There's a lot of something coming down here," the patient neglected to draw the bird until asked to check that his picture was complete. Admitting that it "could be a domestic bird," he was intent for some time on maintaining that the feet of the stove "down here looks like two legs and a tail." Yet regardless of his difficulty in recognition, he reproduced a close approximation of the original.

Summary of drawing performance

J.R.'s receptive disorder was clearly reflected in his drawings. General characteristics of over-drawing, loss of place, highlighting of insignificant details follow from his impoverished visual memory and his difficulty in recognizing any but the simplest of objects and forms. Moreover, his heavy reliance on verbal-functional programs for drawing objects to dictation, coupled with the superior drawing of objects for which he apparently had an overlearned visual-motor pattern, suggest a difficulty in visual imagery which also significantly affected his post-stroke output. This contrast in his ability to depict frequently-drawn versus infrequently-drawn familiar objects also suggests a dissociation of purely visual from visual-motor and verbal schemas for drawing.

Nonetheless, despite the significant cortical pathology, comparisons of pre- and post-drawings document an essential continuity in style. Ability to draw objects which have been recognized indicates that the patient was able to invoke previously learned visual-motor schemas and to incorporate as well specific details of the target. Even in the face of non-recognition, J.R. was able to produce a drawing which, either in part or in sum, bears a strong resemblance to the target. Thus, the patient's knowledge of how to draw veridically "from nature" also remained, perhaps augmented by the careful verbal programs which he elaborated for himself. In sum, J.R.'s case demonstrates that the capacity to draw veridically and schematically can be preserved even in the face of a clinically severe agnosia, and that various verbal-mnemonic and visual sampling strategies can compensate for impaired recognition.

CONCLUSION

Our testing has rendered as inadequate any attempt to attribute J.R.'s disorder primarily to linguistic, naming, general recognitory difficulties, or confusion. While a number of specific visual difficulties have been identified, none of these seems sufficient in itself to account for his entire symptomatology. Instead, on the basis of his pronounced difficulties with occlusions and

subjective contours, and on his drawing performance, we have described his clinical picture as "agnosic-like," a combined product of his restricted visual fields, his related elementary disorders, and his hypothesized defects in immediate visual memory and visual imagery.

Certain behavioral and anatomical factors complicate any discussion of J.R.'s clinical picture. He is left-handed. He may well have suffered a significant amount of brain damage, possibly extending over a period of time, making it difficult to account for his symptomatology either in terms of a focal lesion or a discrete disconnection. By the same token, while his general intellectual functions are relatively intact, his repressed memory scores, occasional disorientation, and partial deafness render questionable any consideration of a single "higher order" cortical impairment. For these reasons, we refrain from affixing a single clinical label to J.R.'s condition or using his case as a springboard for commenting critically upon other cases of agnosia.

Nonetheless, a few general comments can be made. First, our case highlights the significance of careful examination of praxic capacities in patients judged to have recognition disorders. Second, it seems important to present tests which make strong reception-recognition demands without, at the same time, necessitating high-level cognitive processes: if conclusions about recognition disorders are to be correctly drawn, they should not be confounded with other intellectual measures (Weigl, 1964). Tests of illusions and subjective contours seem especially appropriate in this context. Third, our case also raises afresh the question of whether various visual agnosias can ever be distinguished clinically from one another. We would suspect that any individual who exhibits difficulties in recognizing simple objects or elements (the usual definition of agnosia) should, *a fortiori*, display difficulties in synthesizing more complex stimuli (like faces) or multi-faceted stimuli (like pictorial scenes). However, a deceptively good performance on these latter tasks might result from reliance on certain incidental cues such as "props" surrounding individual faces.

Our findings raise the possibility that deficits in visual imagery or visual memory may be necessary concomitants of agnosias, or alternatively, frequent complicating factors. Clearly, in the present case, we have relied chiefly on indirect measures of these capacities. Yet the capacities to recall (or resynthesize) visual images and to retain in short-term memory what has just been seen, may be important contributors to the recognition process and, as such, merit special study in both normal and diseased populations.

In addition to its neuropsychological interest, the intensive study of J.R.'s performances may yield implications for the understanding of normal processing. For instance the steps through which J.R. must pass in his attempts to recognize even the most common objects usefully supplements the information about "normal recognition processes" obtained from studies

using degraded (e.g. tachistoscopic) presentations of stimuli. By the same token, the examination of J.R.'s post-morbid drawing performance helps to clarify the contribution of purely receptive and recognition factors in representational depictions. J.R.'s tendencies, despite preserved motor programs, to overdraw, leave out details, and overemphasize incidental factors underline the crucial role of perceptual-recognitory factors in visual depiction.

Yet, one cannot fail to be struck by the essential preservation of drawing skill in the face of a severe impairment in recognition capacity. Style seems basically unaltered; copying even of an unidentified object is surprisingly faithful; and numerous previously-evolved schemas can be called upon and invoked. Moreover, a number of compensatory measures, such as verbal cueing and reliance upon overlearned motor or visual-motor sequences, can aid the agnosic artist: and in a younger and healthier agnosic patient, even further adaptation might be possible. (Some improvement in performance was observed even during the brief time of our study.) Overall, our patient stands as eloquent if poignant testimony that artistic skills can achieve sufficient consolidation so that they can quite effectively withstand a severe deficit in visual recognition.

SUMMARY

This report describes a 73 year old left-handed male artist who presented with agnosic symptoms following an occipital cerebral vascular accident. Against a background of a memory disturbance, but otherwise essentially intact linguistic and cognitive capacities, the patient was generally unable to identify single objects on visual presentation, and displayed marked difficulty in interpreting complex objects, depicted scenes, and partially occluded figures. The patient's preserved ability to recognize geometric forms, to perceive optical illusions, and to copy designs and objects with considerable accuracy suggested the clinical picture of visual agnosia.

An examination was undertaken of the effects of this recognition disorder on the artist's capacity to draw. Despite an inability to recognize an object or scene, the patient retained various techniques (perspective, shadowing, designation of texture) which allowed him to copy the display in a veridical fashion. When displays were recognized, or when the patient was given only the name of the object and asked to draw it, he adopted a less slavish approach, characteristic of his pre-morbid artwork. While his post-morbid drawings bore a strong similarity to his earlier works, such features as insufficient differentiation of figure from ground, over-elaboration of detail, and areas of neglect revealed the debilitating effects of the recognition disorder. Moreover, an examination of the patient's strategies revealed numerous compensatory verbal and motor procedures which guided his drawing.

Acknowledgments. We wish to acknowledge Dr. Prather Palmer, J.R.'s neurologist, for his cooperation and for making available his very thorough examination notes. Thanks also to Dr. Kent Stevens for providing the stereograms, and to Dr. Frank Benson and Dr. Edgar Zurif for their helpful comments on the manuscript.

REFERENCES

- AJURIAGUERRA, J., DE, and HÉCAEN, H. (1964) *Le Cortex Cérébral*, Masson et Cie, Paris.
- BARTLETT, F. (1932) *Remembering*, Cambridge University Press, Cambridge.
- BAY, E. (1953) *Disturbances of visual perception and their examination*, Brain, 76, 515-550.
- BENDER, M., and FELDMAN, M. (1972) *The so-called visual agnosias*, Brain, 95, 173-186.
- , and KRIEGER, H. (1951) *Visual function in perimetrically blind fields*, A.M.A. Arch. Neurol. Psychiat., 65, 72-79.
- , and TEUBER, H.-L. (1946) *Phenomena of fluctuation, extinction, and completion in visual perception*, A.M.A. Arch. Neurol. Psychiat., 55, 627-658.
- BENSON, D. F., SEGARRA, J., and ALBERT, M. L. (1974) *Visual agnosia-prosopagnosia*, Arch. Neurol. 30, 307-310.
- BRAIN, W. R. (1941) *Visual object-agnosia with special reference to the Gestalt theory*, Brain, 64, 43-62.
- BROWN, J. (1972) *Aphasia, Apraxia and Agnosia*, Thomas, Springfield, Illinois.
- COREN, S. (1972) *Subjective contours and apparent depth*, Psychol. Rev., 79, 359-367.
- CRITCHLEY, M. (1964) *The problem of visual agnosia*, J. Neurol. Sci., 274-290.
- ETTLINGER, G. (1956) *Sensory deficits in visual agnosia*, J. Neurol. Neurosurg. Psychiat., 19, 297-307.
- , and WYKE, M. (1961) *Defects in identifying objects visually in a patient with cerebrovascular disease*, J. Neurol. Neurosurg. Psychiat., 24, 254-259.
- FREDERIKS, J. A. M. (1969) *The agnosias*, in *Handbook of Clinical Neurology*, ed. by P. J. Vinken and G. W. Bruyn, vol. 4, North Holland, Amsterdam.
- GARDNER, H. (1975) *The Shattered Mind: The Person After Brain Damage*, Knopf, New York.
- GESCHWIND, N. (1965) *Disconnexion syndromes in animals and man*, Brain, 88, 237-294.
- GOMBRICH, E. H. (1960) *Art and Illusion*, Bollingen Foundation, New York.
- JUNG, R. (1974) *Neuropsychologie und Neuropsychologie des Kontur und Formsehens in Zeichnung und Malerei*, in *Psychopathologie Musischer Gestaltungen*, ed. by H. Wieck, F. K. Schattauer, Stuttgart.
- KANIZSA, G. (1976) *Subjective contours*, "Scient. Americ.," 234, 48-52.
- KAPLAN, E. F. (1975) *Personal communication*.
- KAUFMANN, L. (1974) *Sight and Mind: An Introduction To Visual Perception*, Oxford University Press, New York.
- KENNEDY, J. (1974) *A Psychology of Picture Perception*, Jossey-Bass, San Francisco.
- KINSBOURNE, M., and WARRINGTON, E. K. (1962) *A disorder of simultaneous form perception*, Brain, 85, 461-486.
- LISSAUER, H. (1889) *Ein Fall von Seelenblindheit nebst einem Beitrage zur Theorie derselben*, Arch. Psychiat. Nervenkr., 21, 2-50.
- LURIA, A. R. (1959) *Disorders of 'simultaneous perception' in a case of bilateral occipito-parietal brain injury*, Brain, 82, 437-429.
- (1966) *The Higher Cortical Functions in Man*, Basic Books, New York.
- LUQUET, G. (1927) *Le Dessin Enfantin*, Alcan, Paris.
- MILNER, B., and TEUBER, H.-L. (1968) *Alteration of perception and memory in man: reflections on methods*, in *Analysis of Behavioral Changes*, ed. by L. Weiskrantz, Harper and Row, New York.
- NEWCOMBE, F., and RATCLIFF, G. (1974) *Agnosia: a disorder of object recognition*, in *Les Syndromes de Disconnexion Calleuse chez l'homme*, ed. by F. Michael and B. Schott, Colloque International de Lyon.
- PIRENNE, M. H. (1970) *Optics, Painting and Photography*, Cambridge University Press, Cambridge.
- RUBENS, A. B., and BENSON, D. F. (1971) *Associative visual agnosia*, Arch. Neurol., 24, 305-316.
- SCHUMANN, F. (1904) *Einige Beobachtungen über die Zusammenfassung von Gesichtseindrücken zu Einheiten*, Psychologische Studien, 1, 1-32.

- STEVENS, K. (1976) *Occlusion clues and subjective contours*, Massachusetts Institute of Technology Artificial Intelligence Memo No. 363.
- WARRINGTON, E. K. (1969) *Constructional apraxia*, in Handbook of Clinical Neurology, ed. by P. J. Vinken, and G. W. Bruyn, vol. 4, North Holland, Amsterdam.
- WEIGL, E. (1964) *Some critical remarks concerning the problem of so-called simultanagnosia*, Neuropsychologia, 2, 189-209.
- WOLPERT, I. (1924) *Die Simultanagnosie - Störung der Gesamtauffassung*, Z. Ges. Neurol. Psychiat., 93, 297.

Howard Gardner, Psychology, 14th floor, Boston V.A. Hospital, 150 South Huntington Ave., Boston, Mass. 02130.