

## Case Reports

### Glue-Sniffing as a Cause of a Positive Radio-Isotope Brain Scan

C.M. Lamont and F.G. Adams

Department of Diagnostic Radiology, Western Infirmary, Glasgow, Scotland

**Abstract.** Convulsions are a known complication of the acute intoxicant effects of solvent abuse. A radio-isotope brain scan done 9 months following status epilepticus secondary to toluene inhalation, in a previously normal school-boy, demonstrated several wedge-shaped areas of increased uptake, in both cerebral hemispheres, consistent with infarcts. It is worth remembering that a positive brain scan in a young person, with recent onset of epilepsy, may be due to glue-sniffing.

#### Introduction

Glue-sniffing is a common addiction among children and young adults in America and Japan. Although it is less common in Britain it does tend to occur in areas of urban deprivation such as the South West of Scotland. The following complications of solvent abuse have been reported in the literature; cerebellar degeneration (Grabski 1961), permanent brain damage (Knox and Nelson 1966), hypokalaemic periodic paralysis (Bennett and Forman 1980), peripheral neuropathy (Shirabe et al. 1974; Korobkin et al. 1975; Towfighi et al. 1976), and convulsions due to the acute intoxicant effects of solvent abuse (Helliwell and Murphy 1979). The following brief case report demonstrates

the consequences in one such case and documents an abnormal radio-isotope brain scan.

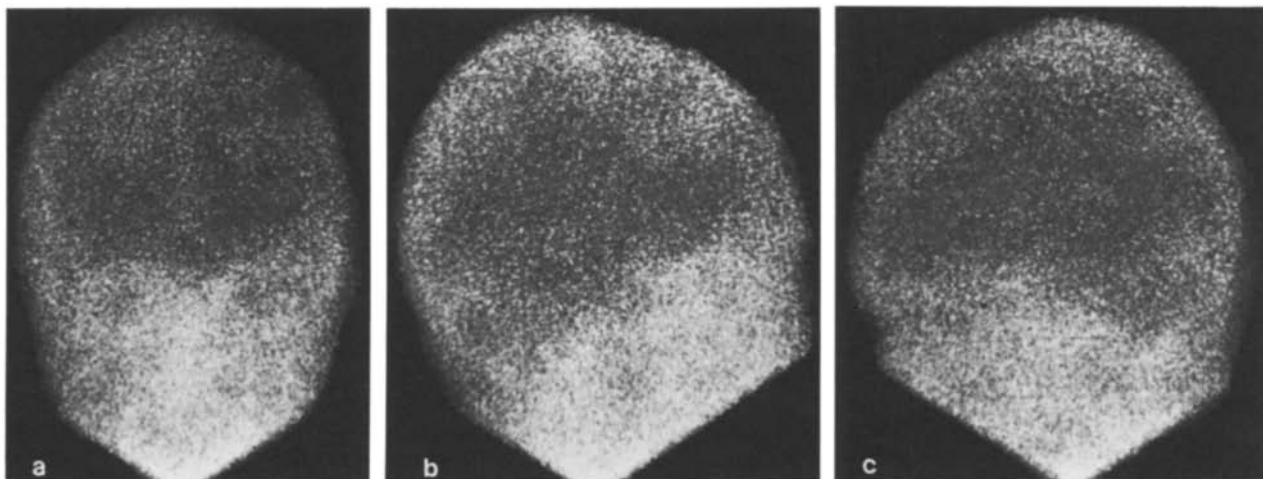
#### Case Report

A 15-year-old schoolboy was admitted to hospital in October 1978 following four grand-mal seizures. On examination the patient was found to be stuporous but responsive to speech. No focal neurological signs were present. Because of recurrent convulsions, which proved difficult to control, the patient was ventilated and fed parenterally.

There was a previous medical history of infantile pyloric stenosis and infantile febrile convulsions. Investigations, which included a CAT brain scan, skull and chest X-rays, EEG, metabolic and viral screening, were all normal. Two brain biopsies were carried out soon after admission and apart from some oedema the brain tissue was otherwise normal. However following information from an anonymous phone caller to the effect that the patient had been involved in glue-sniffing, the brain tissue samples were analysed and revealed high levels of toluene. Blood samples also contained high levels of toluene.

A diagnosis of status epilepticus secondary to glue-sniffing encephalopathy was made and the patient referred to the psychiatrist.

Nine months following the anoxic episode due to glue inhala-



**Fig. 1.** (a) AP. (b) Right Lateral. (c) Left Lateral Views of Radioisotope Brain Scan. The scan demonstrates at least 2 areas of increased uptake in the right frontal lobe and further lesions in the left frontal and left temporo-parietal regions. The area of diminished uptake on the left side, seen on the AP view, represents the burr hole

tion, the patient was still being troubled by frequent epileptiform seizures, mild left sided weakness and bizarre behaviour. An EEG revealed a diffuse disorder of both hemispheres and the isotope brain scan showed a large wedge-shaped area of increased uptake in the right fronto-parietal region consistent with an infarction. Several smaller lesions were also noted scattered throughout the cerebral hemispheres (Fig. 1).

The patient is still being seen by the neurologists and psychiatrists.

### Discussion

As far as we are aware this is the only report in the world literature of the radio-isotope brain scan changes following toluene inhalation. Other than a history of infantile febrile convulsions the patient had been previously well until his hospitalisation in 1978. The patient undoubtedly developed encephalopathy with multiple infarcts following status epilepticus and no reasonable cause other than glue-sniffing has been established.

Chemicals such as toluene, acetone, benzene, aliphatic acetates, hexanes, naphthas and alcohols cause euphoria, hallucination and pleasant exhilaration (Musclow and Allen 1971); these chemicals are highly toxic and readily available from commercial products such as paint sprays, paint removers, lacquer thinners, household glues, lighter fluid and degreasing cleaners. Helliwell

and Murphy (1979) state that 'glue-sniffing is a popular practice among the young and is worth bearing in mind in the previously non-epileptic adolescent who presents at hospital as a result of an epileptiform seizure'.

### References

- Bennett RH, Forman HR (1980) Hypokalaemic periodic paralysis in chronic toluene exposure. *Arch Neurol* 37:673
- Grabski DA (1961) Toluene sniffing producing cerebellar degeneration. *Am J Psychiatry* 118:461-462
- Helliwell M, Murphy M (1979) Drug-induced neurological disease. *Br Med J* 1 (6173):1283-1284
- Knox JW, Nelson JR (1966) Permanent encephalopathy from toluene inhalation. *N Engl J Med* 275:1494-1496
- Korobkin R, Asbury AK, Sumner AJ, Nelson SL (1975) Glue-sniffing neuropathy. *Arch Neurol* 32:158-162
- Musclow CE, Allen CF (1971) Glue-sniffing: Report of a fatal case. *Can Med Assoc J* 104:315-319
- Shirabe T, Tsuda T, Terao A, Araki S (1974) Toxic neuropathy due to glue-sniffing. *J Neurol Sci* 21:101-113
- Towfighi J, Gonatas NK, Pleasure D, Cooper HS, McCree L (1976) Glue-sniffer's neuropathy. *Neurology* 26:238-243

Received November 2, 1981