

# Prosopagnosia

## Report of Four Cases

*E. Nardelli, F. Buonanno, G. Coccia, A. Fiaschi, H. Terzian, N. Rizzuto*

Istituto di Clinica delle Malattie Nervose e Mentali, Università di Padova, Sede di Verona, Italia

**Key Words.** Bilateral temporo-occipital lesions · Topographical memory

**Abstract.** 4 patients with prosopagnosia are described. They presented associated neuropsychological deficits (achromatopsia, topographical disorientation) and visual field defects. In 1 case, gross pathological examination revealed bilateral symmetrical infero-medial occipito-temporal infarcts. In 2 other cases, computer tomography (CT) demonstrated bilateral inferior temporo-occipital infarction. In 1 case CT showed only occipital infarctions in the occipital lobes. This brings to 16 the number of anatomically studied cases of prosopagnosia (8 by necropsy, 8 by CT). In contrast to clinical localization, which often indicates only a right cerebral lesion, all anatomically verified cases of prosopagnosia exhibit bilateral lesions in the posterior cerebral artery distribution.

## Introduction

Prosopagnosia is a rare and unusual disability, in which impairment in recognition of familiar faces is associated with other neurobehavioural defects such as temporo-spatial disorientation, achromatopsia, metamorphopsia, visual field defects and constructional apraxia [4–6, 8, 12, 17]. Several clinical case reports suggest that a unilateral right parieto-occipital lesion is responsible for this

visual-perceptual disturbance in recognition of faces, places, objects, shapes and letters [10, 21, 22]. In contrast, the few anatomically verified cases have always demonstrated bilateral lesions in the occipito-temporal regions [3, 13, 16].

We report 4 patients with prosopagnosia, 1 with pathological verification, 3 with computerized cranial tomographic confirmation, with the aim of discussing the anatomical correlates of prosopagnosia.

## Case Reports

### *Case No. 1*

A.A., a 59-year-old right-handed normotensive male, presented to the outpatient department with a several days' history of difficulty in recognizing faces and objects. The patient had been treated almost 20 years previously for syphilis. After that episode he had enjoyed good health. In June 1971, he felt unwell and suffered an episode of vertigo, followed by transient loss of consciousness. Thereafter, he complained that all faces were alike and that he could not perceive colours. He became almost immediately aware of narrowing of his visual field.

On examination as an outpatient a few days later, the patient stated that only when he heard a person's voice was he able to identify this person, but was unable to do so by simply looking at the face itself. The remainder of the examination, including the cranial nerves, the motor system, and the sensory system, were unimpaired.

2 months later, the patient was re-evaluated: there was no left-right disorientation. Topographical memory and orientation were also unimpaired; he could draw the plan of his house and describe routes through it, and he travelled alone by bus for his errands or for his hospital visits. At no time was there any difficulty in his speech or in comprehension of spoken or written language; likewise, there was no dressing apraxia or neglect of extrapersonal space. His memory remained remarkably intact. Memory testing showed normal scores. He was alert, co-operative, and consistent in his responses.

Visual acuity, measured with the Snellen chart, was 10/10 in both eyes. The fundi were normal. The visual field examination revealed marked concentric narrowing of both fields (fig. 1). The patient mainly complained of impairment in the recognition of faces as such, or recognition of faces familiar to him, such as his wife's. His puzzlement and confusion was most striking when he was asked to identify photographs of his family or to choose between similar photographs. He had no difficulty in naming real objects. He was able to identify Ishihara colour charts. He had no difficulty in reading.

His condition remained unchanged until death from cardiac failure 4 months later in another hospital. We have noticed of the patient's demise several months later.

The pathological report we had the opportunity to

look over mentioned aortic atherosclerosis with calcification of the aortic ostium; the anterior descending coronary artery and its branches were obstructed near the ostium by an old organized thrombus.

Gross examination of the brain showed the large cerebral arteries to contain numerous atherosclerotic plaques. The lumen of both posterior cerebral arteries, just above the junction with the posterior communicating arteries, was reduced to 10–20% in its size. The surface of the hemispheres appeared normal all over the convexity; on the contrary, on the undersurfaces of both temporo-occipital regions, deep depressions, vascular in nature, were observed. Coronal sections showed bilateral, elongated cystic defects extending from the calcarine cortex to the fusiform and lingual gyri and involving the basal part of the optic radiations. All lesions were old and well-healed. No macroscopic evidence of other recent or remote infarctions was noted in the remaining lobes.

### *Case No. 2*

O.O., a 53-year-old man, was referred to the Neurologic Department in Verona in June 1978, because of a 4-month history of inability to recognize human faces. He had been a heavy smoker until 1968, when he had suffered from myocardial infarction. In 1976, he suddenly felt unwell, complaining headache, vomiting and vertigo, from which he made a slow but uneventful recovery. There had been no history of other embolic episodes. In February 1978, because of sudden confusion, headache and minimal right-sided weakness, he was hospitalized elsewhere and underwent cerebral angiography.

Left carotid angiograms showed no significant changes. Selective catheterization of the left vertebral artery showed only a slight stenosis of the distal third of the basilar artery and smaller distal branches with less evident capillary blush in the distribution of both calcarine arteries.

In June 1978, the patient was referred to our department for persistence of his inability to recognize human faces; he also reported a minor degree of non-specific forgetfulness. Neurological abnormalities at that time were confined to the visual sphere. Review of systems was unremarkable. On neurological examination, no motor or sensory deficits were detected. Visual acuity was 10/10 in both eyes. There was a bilateral upper quadrantic visual field defect (fig. 2a). Gaze and convergence were intact. He was fully oriented and had no difficulty with proverb interpreta-

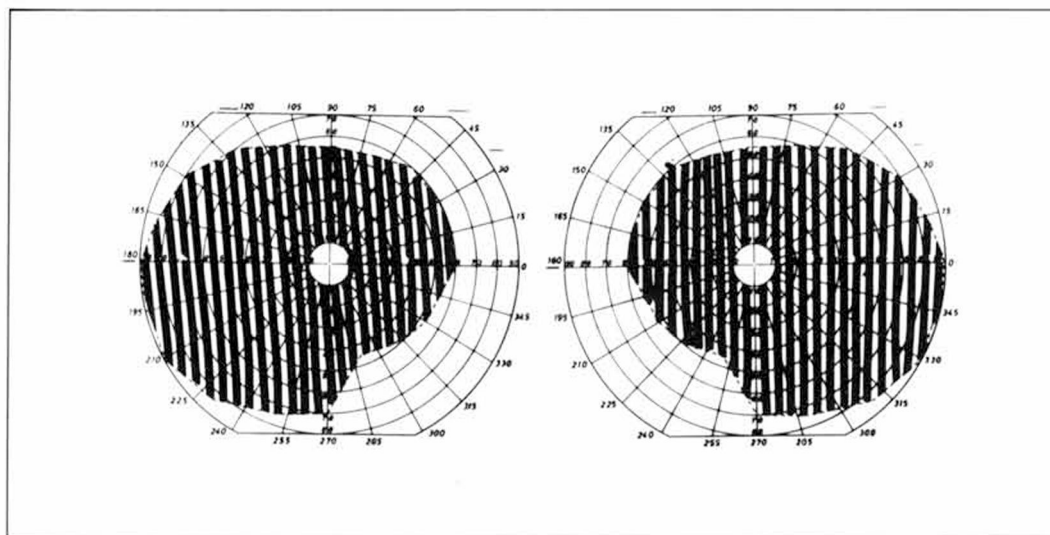


Fig. 1. Case No. 1. Double hemianopia with preserved central vision.

tion. A CT scan, done 4 months later, demonstrated bilateral infarctions of the inferior portions of both temporal and occipital lobes (fig. 2b, c).

The Farnsworth-Munsell 15 hue test for colour vision indicated a disturbance in hue discrimination in the red-green region. The patient complained that colours looked different degrees of gray, and he misnamed them. Although there was impaired colour discrimination, intact colour memory was present; the patient never failed to name the colour of fruit, sky and so forth, when asked with spoken word.

The patient was unable to recognize members of his family and the hospital staff, or even his own face in the mirror. He never showed signs of familiarity towards anyone on purely face-to-face confrontation, yet he readily recognized people by their voice. When explaining why he had difficulty in recognizing faces, he said the faces appeared 'flat'; 'I can see the eyes, the mouth and the dark hairs, but everything lies on the same plane and I cannot say if it is the face of (whomever).' The patient was able to name, describe and demonstrate the use of many common objects. However, his ability to recognize pictures of tridimensional objects was greatly impaired. He was always able to name plane geometrical forms (circle, square, triangle), but he failed in figure-ground discrimination tasks (such as masked hammer, flask, etc.). He was

unable to assemble a very simple jigsaw puzzle (train) or to arrange cards telling a story in the logical sequence (a child playing with matches, setting a fire causing the arrival of firemen). He failed the correct reproduction of a complex geometrical figure (the Rey-Osterrieth), with the omission of many details. He could perform better in drawing requested objects by memory than by copying given figures.

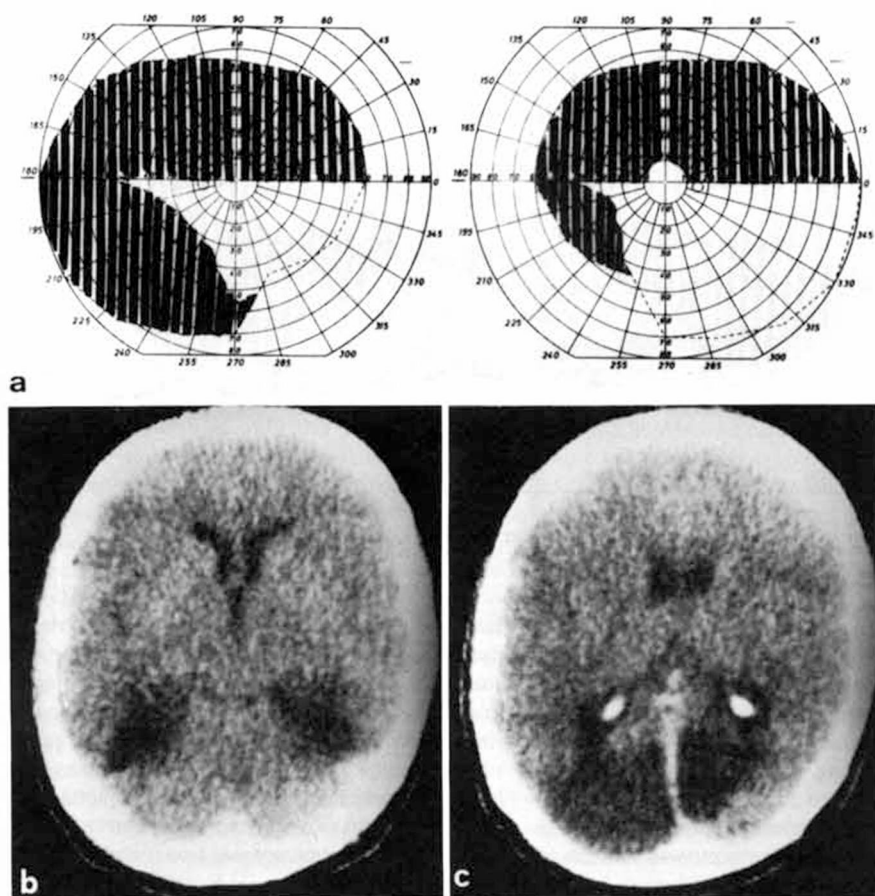
He was tested on a visual and verbal memory test procedure suggested by *De Renzi* [9]; at each delayed memory subtest his performance was poor, scoring below the mean.

During his hospitalization, he always failed to find the bathroom or to return to the ward. The patient also complained that his own house and the street in the small town, where he lived for about 30 years, seemed unfamiliar.

At follow-up visits to 1 year later, the patient complained further only that he had not recognized the change of seasons; his other deficits remained unchanged.

#### Case No. 3

G.B., a 36-year-old heavy smoker, had no past history of heart disease. In March 1980 he suffered from tight pain in his chest followed by arrhythmias, shock and depression of consciousness. A ventricular fibril-



**Fig. 2.** Case No. 2. **a** Homonymous upper quadrantic defects. **b, c** CT scan with enhancement showing temporo-occipital infarctions.

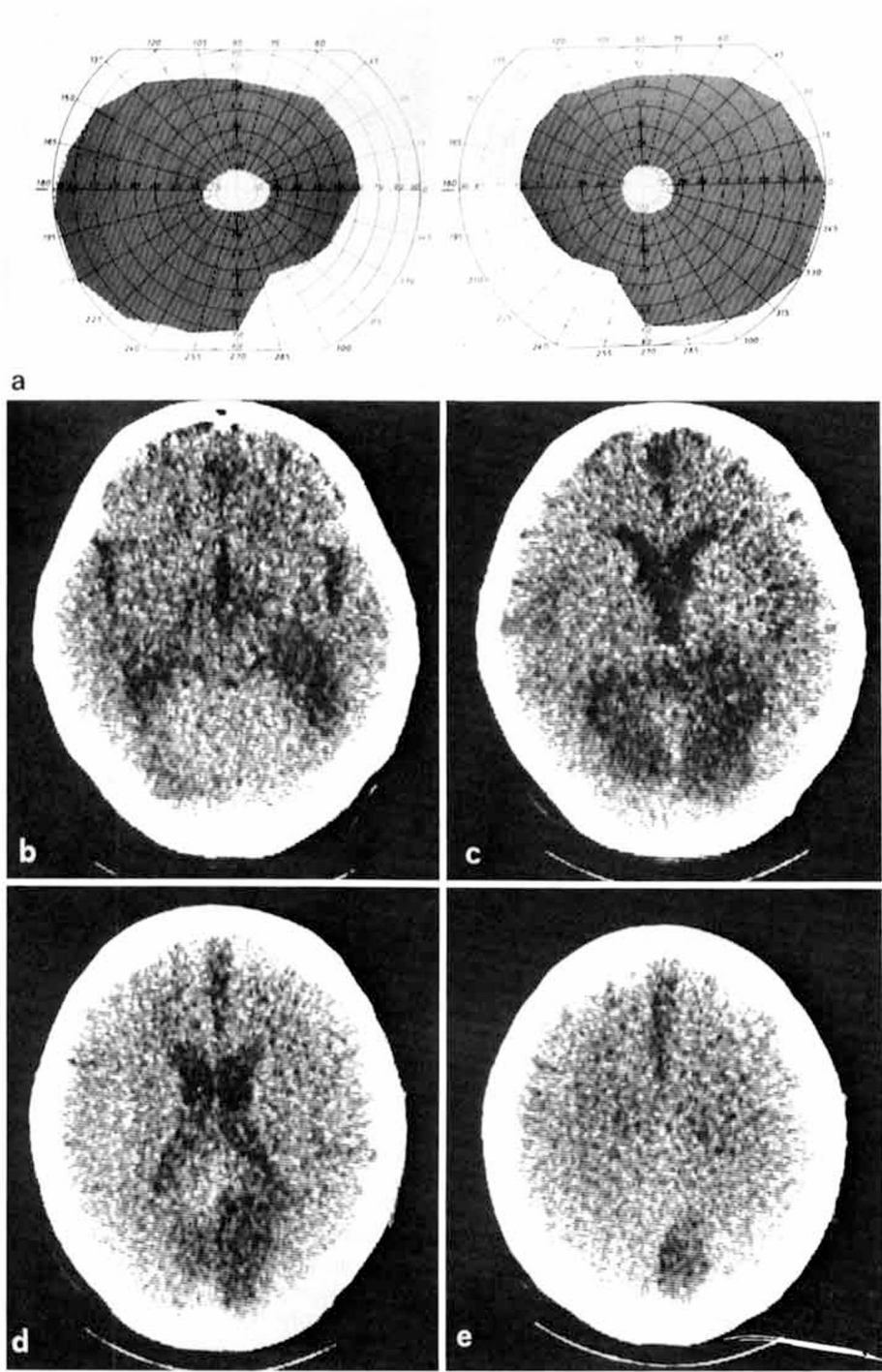
lation was ascertained upon admission to hospital. Soon after, the patient realized that he was unable to see objects on the left side of his body. Also he could not recognize people by their face or their clothing but only by their voice. At that time the CT scan revealed bilateral temporo-occipital infarcts (fig. 3). In October 1980 he noticed that he was unable to keep his left arm and hand still. When he was admitted to our department in March 1981, neurological examination revealed hemiparesis on the left side. He suffered from involuntary extension of the left wrist and flexion of

the fingers, sometimes accompanied by slow involuntary movements involving the arm, shoulder and neck on the left side.

Laboratory examinations showed normal values.

The EEG revealed slow diffuse abnormalities over both hemispheres. Tunnel vision was elicited by visual field examination. The patient's natural visual

**Fig. 3.** Case No. 3. **a** Patient with tunnel vision. **b-e** CT scan showing extensive bilateral infarction.



3

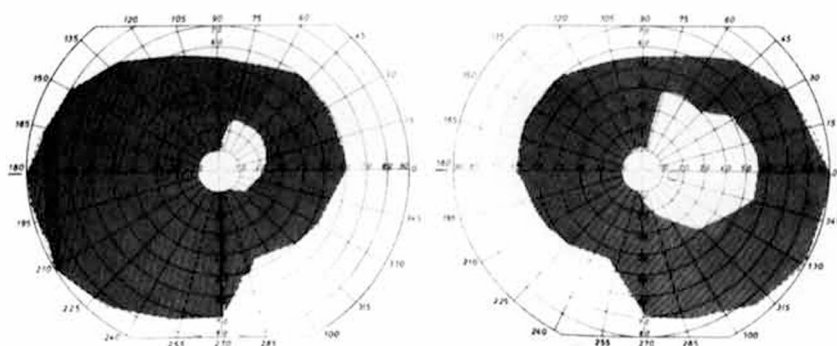


Fig. 4. Case No. 4. Marked reduction of the visual field.

acuity was 1/10 in both eyes. The Farnsworth-Munsell 15 hue test for colour vision indicated a disturbance in hue discrimination. The patient was able to recognize basic colours but not shades of colours. The result of fundusoscopic examination was normal.

Neuropsychological tests showed his comprehension of spoken language to be unaffected. Whilst reading he could not keep the line, but otherwise he was accurate. He promptly identified pictures of objects only when they were presented on the right side. He correctly named different objects which he felt in his right hand without looking at them, whereas he had to see them when holding them in his left hand. Performance in non-verbal subtests according to WAIS was moderately impaired, whereas verbal subtests showed a high score in keeping with the patient's high standard of education. His most remarkable defects were a moderate degree of constructional apraxia, complete failure on Bender's tests and Rey's figure, severe difficulty in copying or drawing tridimensional objects, and impairment of recent memory [9] both in visual and verbal subtests. He could not walk alone without getting lost in a neighbourhood he had lived in for 20 years. He even got lost in his house and he could not draw a plan of it.

#### Case No. 4

F.S., a 73-year-old right-handed normotensive male, had a transient episode of weakness of the right arm and leg in 1974. These symptoms cleared in 24 h

without residual defects. In 1978 a pacemaker was implanted because of tachycardia associated with atrial fibrillation. In 1979 he suffered from intermittent claudication in his legs and spasmodic blindness.

The patient was first examined in 1981, 1 month following the episode at which time he reported difficulty in recognizing familiar faces. The patient's visual acuity was 7/10 in the right eye and 3/10 in the left eye. Examination revealed a marked reduction of the visual field in both eyes (fig. 4). Fundusoscopic examination revealed arteriovenous compression and ill-defined exudates. On physical examination a cardiac arrhythmia was noted. Neurological examination revealed only right-sided hyperreflexia. An EEG showed a markedly abnormal posterior rhythm in both posterior areas, with diminution of the normal background. Non-enhanced computerized tomography showed a well-defined oval-shaped area of decreased density in the right occipital lobe and a small ill-defined area of increased lucency in the left posterior horn of the lateral ventricle (fig. 5).

Laboratory examinations showed normal values.

On neuropsychological examination, linguistic assessment showed fluent conversational speech, and comprehension of spoken language was intact. He could see, describe, draw and match visual stimuli which he could promptly identify. He could name seen objects or describe how to use them, yet he disregarded visual stimuli coming within his left visual field. He could read incomplete letters, words and sen-

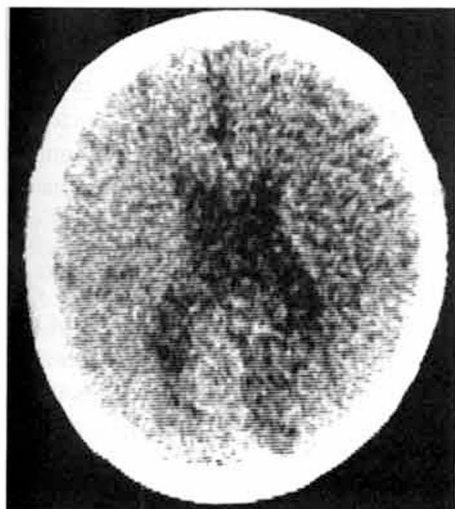


Fig. 5. Case No. 4. CT scan showing prevalent involvement of the right posterior pole.

tences without difficulty. Performance of non-verbal subtests according to WAIS was moderately impaired.

There was a marked impairment on reproduction of gestaltic figures of Bender's test and Rey's figure, while no agnosia or apraxia defects were elicited. An inability to reproduce tridimensional figures was discovered. Topographical memory was very good.

## Discussion

The inability to recognize familiar faces was first described by *Charcot* [7] in 1887 and by *Wilbrand* [25] in 1892 and clearly defined and named prosopagnosia by *Bodamer* [6] many years later (1947). Affected patients cannot identify people purely by their facial physiognomy, but can readily recognize them by their voice or by other visual clues. Prosopagnosia is often accompanied by visual field defects or by other associated disturbances such as impaired colour dis-

crimination, inability to identify familiar buildings or landscapes and difficulties in copying complex drawings [11, 18].

The exact nature of the neuropsychological dysfunction remains elusive; in-depth discussions are given by *Hecaen et al.* [10] and by *Lhermitte et al.* [13]. It has been hypothesized that prosopagnosia is (a) only a feature of a more generalized impairment of visual-spatial perception [8, 14, 15] or (b) a deficit in the mediation of a unique and specific perceptual process underlying facial recognition [6, 19, 20].

In our patients, examination demonstrated defects not only in the facial recognition but also in recognition of other visual stimuli, such as colours (case No. 2), buildings (cases No. 2, 3) and tridimensional objects (cases No. 2, 3, 4). As stated above, such neurobehavioural disturbances are frequently associated with inability of facial recognition [3, 17].

A major point of dispute in prosopagnosia is whether the condition results from a single (i.e., unilateral) cerebral lesion or whether multiple, bilateral lesions are necessary. The only consistent clinical sign of localizing value in these patients has been the presence of visual field defects.

Over 90% (38/42) of the cases culled by *Meadows* [16] presented visual field defects; about half (19/42) exhibited left homonymous defects indicating right hemisphere disease, but not excluding left-sided lesions (as in our case No. 2); about one third (15/42) exhibited bilateral field defects indicating bilateral lesions, while the remainder were equally divided between a right homonymous defect (4/42) and no field defect at all (4/42). The visual field examination in our cases indicated the presence of bilateral cerebral lesions.



In contrast to the vast majority of clinical reports, where right cerebral involvement seems predominant [10], all cases pathologically examined have clearly demonstrated the presence of bilateral occipito-temporal lesions [13, 16]. The main structures involved are the lingual and fusiform gyri and the underlying white matter comprising tectal fibres descending from the posterior portions of the corpus callosum, the inferior longitudinal fasciculus and the lower fibres of the optic radiation [3].

The lesions do not generally extend forward into the temporal lobes. It is interesting to recall that in our cases No. 2 and 3 prosopagnosia was associated with impairment in recognition of familiar places, a feature observed in other cases [2, 11, 18]. The incapacity in recognizing familiar places seems to be correlated with lesions in both inferior temporal lobes [24], as was here supported by CT scan findings.

The anatomo-pathological evidence continues to suggest the necessity of bilateral, although not always symmetric, inferior occipito-temporal lesions for the production of prosopagnosia and its associated neurobehavioural disturbances. In fact, the previously reported cases of prosopagnosia due to right occipito-temporal surgery [10, 14] or to left temporal lobectomy (in a left-handed patient) [19], where a unilateral lesion was suspected, lacked of anatomical examination excluding a contralateral lesion.

To the best of our knowledge, there are only two reports describing CT scan finding in prosopagnosic patients. Bilateral lesions were found in the left-handed patient of *Aptman et al.* [1] and in case I of *Whiteley and Warrington* [23], while a unilateral, right posterior lesion was noted in cases II and III of the latter series. It remains possible that in

the latter 2 cases contralateral lesions were not of sufficient size to be detected by CT.

As discussed above, CT in our cases No. 2 and 3 demonstrated bilateral lucencies in the inferior portions of both temporal and occipital lobes. CT scanning, therefore, is useful for verifying in vivo the gross extent of this syndrome, but we believe that only more accurate, detailed neuropathological examination will further our knowledge of the localization of the lesions responsible for the loss of the diverse perceptual skills involved in, and associated with, prosopagnosia.

### Acknowledgements

The authors wish to thank Dr. *R.H. Ackerman* and Dr. *D.N. Levine* for their critical reviews of the manuscript, and Prof. *Scomazzoni* for sending the pathological findings.

This paper was partly supported by CNR grant No. 79.01963.04.

### References

- 1 Aptman, M.; Levin, H.; Snelick, R.C.: Alexia without agraphia in a left-handed patient with prosopagnosia. *Neurology*, Minneap. 27: 533-536 (1977).
- 2 Assal, G.: Regression des troubles de la reconnaissance des physionomies et de la mémoire topographique chez un malade opéré d'un hématomme intracérébral pariéto-temporal droit. *Revue neurol.* 121: 184-185 (1969).
- 3 Benson, D.F.; Segara, J.; Albert, M.L.: Visual agnosia-prosopagnosia. *Archs Neurol.*, Chicago 30: 307-310 (1974).
- 4 Benton, A.L.; Van Allen, M.W.: Impairment in facial recognition in patients with cerebral disease. *Cortex* 4: 344-358 (1968).
- 5 Benton, A.L.; Van Allen, M.W.: Prosopagnosia and facial discrimination. *J. neurol. Sci.* 15: 167-172 (1972).
- 6 Bodamer, J.: Die Prosop-Agnosie. *Arch. Psychiat. Nervkrankh.* 179: 6-53 (1947).



- 7 Charcot, J.M.: Un cas de suppression brusque et isolée de la vision mentale des signes et des objets (formes et couleurs); dans Delahaye, Lacroisnie, Leçons sur les maladies du système nerveux, vol. I, tome 3, p. 518 (Paris 1887).
- 8 De Renzi, E.; Faglioni, P.; Spinnler, H.: The performance of patients with unilateral brain damage on facial recognition tasks. *Cortex* 4: 17–34 (1968).
- 9 De Renzi, E.: Le amnesia; dans Bisiach, Denes, De Renzi, Faglioni, Gainotti, Pizzamiglio, Spinler, Vignolo, *Neuropsychologia clinica*, pp. 199–246 (Angeli, Milano 1977).
- 10 Hecaen, H.; Angelergues, R.; Bernhardt, C.; Chiarelli, J.: Essai de distinction des modalités cliniques de l'agnosie des physionomies. *Revue neurol.* 96: 125–144 (1957).
- 11 Hecaen, H.; Angelergues, R.: Agnosia for faces (prosopagnosia). *Archs Neurol.*, Chicago 7: 92–100 (1962).
- 12 Hoff, H.; Pötzl, O.: Über eine optisch-agnostische Störung des «Physiognomie-Gedächtnisses». *Z. ges. Neurol. Psychiat.* 159: 367–395 (1937).
- 13 Lhermitte, F.; Chain, F.; Escourolle, R.; Ducarne, B.; Pillon, B.: Etude anatomo-clinique d'un cas de prosopagnosie. *Revue neurol.* 126: 329–346 (1972).
- 14 Lhermitte, F.; Pillon, B.: La prosopagnosie. Rôle de l'hémisphère droit dans la perception visuelle. *Revue neurol.* 131: 791–812 (1975).
- 15 Levine, D.N.: Prosopagnosia and visual object agnosia: a behavioral study. *Brain Lang.* 5: 341–365 (1978).
- 16 Meadows, J.C.: The anatomical basis of prosopagnosia. *J. Neurol. Neurosurg. Psychiat.* 37: 489–501 (1974).
- 17 Meadows, J.C.: Disturbed perception of colours associated with localized cerebral lesions. *Brain* 97: 615–632 (1974).
- 18 Pallis, C.: Impaired identification of faces and places with agnosia for colours. *J. Neurol. Neurosurg. Psychiat.* 18: 218–224 (1955).
- 19 Tzavaras, A.; Merieene, L.; Masare, M.C.: Prosopagnosie, amnésie et troubles du langage par lésion temporale gauche chez un sujet gaucher. *Encéphale* 62: 382–394 (1973).
- 20 Tzavaras, A.; Hecaen, H.; Le Bras, H.: Le problème de la spécificité du déficit de la reconnaissance du visage humain lors des lésions hémisphériques unilatérales. *Neuropsychologia* 8: 403–416 (1970).
- 21 Warrington, E.K.; James, M.: Disorders of visual perception in patients with localized cerebral lesions. *Neuropsychologia* 5: 253–266 (1967).
- 22 Warrington, E.K.; Taylor, A.M.: The contribution of the right parietal lobe to object recognition. *Cortex* 9: 152–164 (1973).
- 23 Whiteley, A.M.; Warrington, E.K.: Prosopagnosia: a clinical, psychological, and anatomical study of three patients. *J. Neurol. Neurosurg. Psychiat.* 40: 395–403 (1977).
- 24 Whiteley, A.M.; Warrington, E.K.: Selective impairment of topographical memory. *J. Neurol. Neurosurg. Psychiat.* 41: 575–578 (1978).
- 25 Wilbrand, H.: Ein Fall von Seelenblindheit und Hemianopsie mit Sectionsbefund. *Dt. Z. Nerv.-Heilk.* 2: 361 (1892).

Received: July 29, 1981

Accepted: September 24, 1981

Dr. E. Nardelli, Clinica della Malattie Nervose e Mentali dell' Università, Policlinico Borgo Roma, I-37134 Verona (Italy)