

Short report

Stroke as an early manifestation of systemic lupus erythematosus

LF HAAS

From the Department of Neurology, Wellington Hospital, Wellington, New Zealand

SUMMARY Both stroke and transient cerebral ischaemic attacks occurring in younger patients may be due to systemic lupus erythematosus. Other clinical features of the disease may be absent. Initially the ESR may be normal, as may serological tests. Seizures may occur at or near the time of the vascular events. Systemic lupus erythematosus may be the cause of an asymptomatic cerebral infarct or multi-infarct dementia.

Hemiparesis is not commonly associated with systemic lupus erythematosus¹⁻⁶ and when this does happen the diagnosis has usually been established. If stroke does occur early in the illness the true diagnosis may not be suspected. These reports show that stroke or transient cerebral ischaemia can be an early symptom of systemic lupus erythematosus.

Patients

Case 1 A 29-year-old man suddenly became quadriparetic and unable to move his jaw or speak. Recovery occurred within 5 minutes. Five months later there was a further episode of transient vertebrobasilar ischaemia. Neurological and cardiological examinations, echo cardiography, cerebral and left carotid angiography were all normal. His ESR was 5 mm/h, antinuclear factor positive to 1:320, DNA binding was elevated to 40 units per ml (normal less than 25). Leucopenia, lymphopenia and depression of the C3 fraction of the complement were present. Despite normal renal function renal biopsy was abnormal. Some glomeruli showed global sclerosis. Immunofluorescent IgM and IgA were detected in the mesangium and C3 in the capillary loops. Subendothelial electron dense deposits were present. At that time an additional history of recurrent pain and stiffness of joints over 2 years was obtained and there was slight splenomegaly. Sixteen to nineteen months after the original episode two further episodes of transient vertebrobasilar ischaemia occurred lasting 1 hour and 15 minutes respectively. Half an hour after the last event there was a focal seizure beginning in the right arm.

Address for reprint requests: Dr LF Haas, Neurology Dept, Wellington Hospital, Private Bag, Newtown, Wellington 2, New Zealand.

Received 5 November 1981 and in revised form 26 January 1982
Accepted 30 January 1982

Case 2 Ten days after the completion of her second pregnancy a 32-year-old woman suffered a transient left hemiparesis. ESR was 17 mm/h. During the pregnancy, at 20 weeks gestation, her WR and VDRL were positive. When 29 weeks pregnant these serological tests remained positive but her platelet count had fallen to $30 \times 10^9/l$. Coagulation studies were normal. Anti-nuclear factor was positive to 1:80. The ESR was 27 mm/h, normal for the stage of pregnancy. Bone marrow examination showed increased numbers of megakaryocytes. Within 2 months platelets returned to normal without treatment. Three months after the completion of the pregnancy, and the episode of transient cerebral ischaemia, spontaneous leg bruising occurred. There was now severe thrombocytopenia (platelets $10 \times 10^9/l$). DNA binding was 45 units per ml, Sm antibody positive and C3 and C4 fractions of the complement depressed. Prednisone 60 mg daily reducing to 10 mg daily was started. In the 12 months that followed there were five or six further transient left hemipareses. Platelet numbers were now normal. Platelet aggregation studies showed reduced aggregation with ADP, adrenalin, collagen and ristocetin but the bleeding time was prolonged (15 minutes). Dipyridamole (400 mg daily) was added to the prednisone (10 mg daily). In the subsequent 8 months there were no further hemiparetic attacks but frequent skin urticarial lesions occurred. CT scan was normal.

Case 3 A 41-year-old woman suffered hepatitis and the following year seronegative polyarthritis associated with an ESR of 50 mm/h. Over the next 3 years there were three right hemiparetic episodes with complete recovery except for minor right facial weakness persisting after the last attack. With each episode of weakness ESRs were normal, or near normal at 13, 12 and 10 mm/h. Systemic lupus erythematosus was suspected because of the presence of LE cells, raised IgG and changes on renal biopsy (wire loop capillary lesions and electron dense deposits in the mesangium). Progressive dementia without further neurological

signs followed. When re-investigated at the age of 51 the ESR was 30 mm/h, DNA binding 39 units/ml, and antibody to double stranded DNA was detected. Sm and RNP antibodies were absent, but LE cells were still present. CT scan showed cerebral atrophy and a large *right* temporo-parietal infarct (fig A).

Case 4 A 46-year-old woman suffered a paranoid psychosis which required treatment with electroconvulsive therapy. At age 49 yr a symptomatic left retinal venous occlusion occurred and an asymptomatic right retinal arterial occlusion was also present. Treatment for hypertension (190/120 mm Hg) was begun. Two weeks later there were two right sided epileptic events and the following day a right hemiparesis with near full recovery within minutes. Serial isotope scans indicated *right* frontal lobe infarction. The ESR ranged from 49 to 69 mm/h. Anti-nuclear factor and DNA binding were normal. A search for LE cells was negative. Three months later there were the skin changes of livedo reticularis, the anti-nuclear factor titre was 1:40, DNA binding 40 units/ml, Wasserman reaction positive, C3 and C4 fractions of complement depressed and renal function impaired. Renal biopsy showed a focally accentuated proliferative glomerulonephritis, occasional thickened capillary loops and electron dense deposits in the mesangium. Mesangial IgA was demonstrated with immunofluorescence. Three years later frequent focal and generalised seizures occurred associated with prednisone-induced hyperglycaemia (plasma glucose 53 mmol/l) and severe hypertension (230/160 mm Hg). The blood pressure became normal following treatment with drugs and quiescence of the lupus. Following recovery, slight dysphasia, moderate impairment of intellect, a dyspraxic gait and extensor plantar responses were present. The condition changed little in the following 2 years. At age 52 a CT scan showed severe cerebral atrophy with infarcts in both temporal, the left frontal and left parietal areas (fig B).

Discussion

Cerebral ischaemic events can occur as an early manifestation of systemic lupus erythematosus. Unless the diagnosis is actively considered the true nature of the underlying disease may not be established. With Case 1 stroke was the only known symptom at presentation. In Cases 2, 3, and 4 there were other important symptoms or signs prior to stroke but it was the cerebral episodes in Cases 3 and 4 that lead to the diagnosis of systemic lupus erythematosus. Only one of the patients (Case 4) showed a raised ESR and that patient's serological tests initially were negative. Fits do not usually accompany strokes or transient cerebral ischaemia. Moreover, asymptomatic or multiple infarcts are uncommon in younger patients. If either occur, there should be an awareness of the possibility of systemic lupus erythematosus, even in the absence of other clinical evidence of the disorder. Fits accompanying the hemiparesis of systemic lupus erythematosus have been commented on by others.²

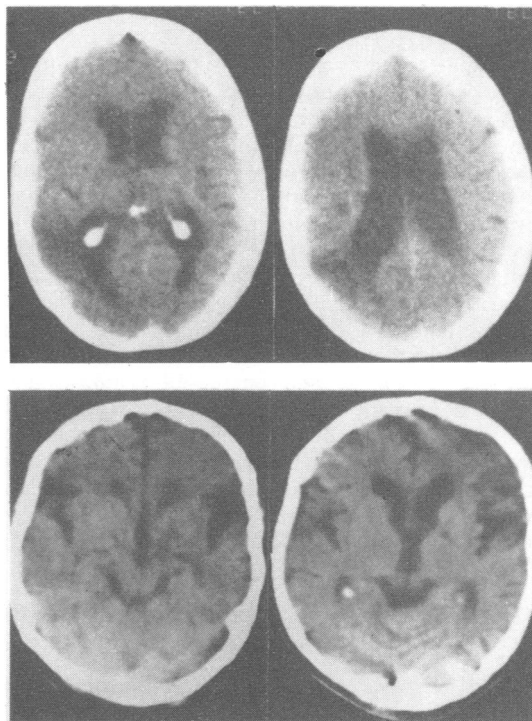


Figure (A) (above) CT scan. Selective cuts showing low attenuation in the right temporo-parietal region indicative of infarction. The ventricular system is dilated. (B) (below) CT scan. Selective cuts showing cerebral atrophy and areas of low attenuation indicative of infarction in both temporal and the left frontal regions. Further cuts (not shown) show left parietal involvement.

Several possible mechanisms may play a part in cerebral infarction or transient cerebral ischaemia occurring with systemic lupus erythematosus. When pathological changes have been seen in vessels of the brain in cerebral lupus these have involved principally small vessels. Microhaemorrhage and microinfarction may occur without small vessel abnormality.^{2 7 8} With lupus-related strokes occlusion of larger arteries have been seen radiologically^{1 2 10-12} and at necropsy.^{1 2 7-9 11} There may be intracranial haemorrhage, cerebral infarction secondary to venous occlusion, or brain infarction not clearly associated with arterial or venous occlusion.^{1 2 8 13} Because of the interval between the clinical event and necropsy, the role of emboli from verrucous endocarditis is uncertain. It is unlikely that deposition of gamma globulin in the choroid plexus,¹⁴ anti-neuronal antibodies or elevated serum and CSF levels of lymphocytotoxic antibodies (which may possibly cause other cerebral manifestations of

lupus^{12 15}) have a role in cerebral infarction or transient cerebral ischaemia. In at least one case of left middle cerebral artery obstruction CSF lymphocytotoxic antibody was not increased.¹²

Cerebral infarction with occlusion of vessels by platelet and fibrin thrombi have recently been demonstrated in two cases of cerebral systemic lupus erythematosus,¹⁶ one and possibly both of whom had suffered strokes. The importance of platelet thrombi has also been shown in a 43-year-old woman with systemic lupus erythematosus who died after myocardial infarction.¹⁷ The thrombotic tendency in systemic lupus erythematosus may be associated with physical changes in the platelets, platelet-aggregating immune complexes and decreased synthesis and release of prostacyclin.¹⁷⁻²⁰ In Case 2, quite frequent hemiparetic episodes stopped after taking dipyridamole, even though excessive platelet aggregation was not demonstrated. Treatment other than immuno-suppression may be important in lupus-related strokes.

References

- ¹ Silverstein A. Cerebrovascular accidents as the initial major manifestation of lupus erythematosus. *NY J Med* 1963;**63**:2942-8.
- ² Johnson RT, Richardson EP. The neurological manifestations of systemic lupus erythematosus. A clinical-pathological study of 24 cases and review of the literature. *Medicine* 1968;**47**:337-69.
- ³ Gibson T, Myers AR. Nervous system involvement in systemic lupus erythematosus. *Ann Rheum Dis* 1976;**35**:398-406.
- ⁴ Grigor RR, Edmonds J, Lewkonja R, Bresnihan B, Hughes GRV. Systemic lupus erythematosus. A prospective analysis. *Ann Rheum Dis* 1978;**37**:121-8.
- ⁵ Feinglass EJ, Arnett SC, Dorsch CA, Zizic TM, Stevens MB. Neuropsychiatric manifestations of systemic lupus erythematosus; Diagnosis clinical spectrum and relationship to other features of disease. *Medicine* 1976;**55**:323-39.
- ⁶ Guseva LL. Apoplectic stroke in lupus erythematosus disseminatus. (Russian). *Soviet Med* 1975;**38**:65-9.
- ⁷ Berry RG. Lupus erythematosus. In: Minkler J, ed. *Pathology of Nervous System Vol 2*. New York: McGraw-Hill, 1971:1482-8.
- ⁸ Funata N. Cerebrovascular changes in systemic lupus erythematosus. *Bull Tokyo Med Dent Univ* 1979;**26**:91-112.
- ⁹ Pinching AJ, Travers RL, Hughes GRV. Oxygen-15 brain scanning for detection of cerebral involvement in systemic lupus erythematosus. *Lancet* 1978;**1**:898-900.
- ¹⁰ Trevor RP, Sondheimer FK, Fessel WJ, Wolpert SM. Angiographic demonstration of major cerebral vessel occlusion in systemic lupus erythematosus. *Neuroradiology* 1972;**4**:202-7.
- ¹¹ Bennett R, Hughes GRV, Bywaters EGL, Holt PJJ. Neuropsychiatric problems in systemic lupus erythematosus. *Br Med J* 1972;**4**:342-5.
- ¹² Williams GW, Bluestein HG, Steinberg AD. Brain-reactive lymphocytotoxic antibody in the cerebrospinal fluid of patients with systemic lupus erythematosus: Correlation with central nervous system involvement. *Clin Immunol Immunopathol* 1981;**18**:126-32.
- ¹³ Lee P, Urowitz MB, Bookman AAM, et al. Systemic lupus erythematosus. A review of 110 cases with reference to nephritis, the nervous system, infections, aseptic necrosis and prognosis. *Q J Med* 1977;**146**:1-32.
- ¹⁴ Atkins CJ, Kondon JJ, Quismorio FP, Friou GJ. The choroid plexus in systemic lupus erythematosus. *Ann Intern Med* 1972;**76**:65-72.
- ¹⁵ Bresnihan B, Oliver M, Williams B, Hughes GRV. An anti-neuronal antibody cross reacting with erythrocytes and lymphocytes in systemic lupus erythematosus. *Arthritis Rheum* 1979;**22**:313-20.
- ¹⁶ Paterson A, Timperley W, Slater D. Coagulation abnormalities in fatal cerebral lupus erythematosus. *J R Soc Med* 1981;**74**:53-5.
- ¹⁷ Slater D. "Lupus" and prostacyclin formation. *Lancet* 1981;**1**:393.
- ¹⁸ McVerry BA, Machin SJ, Parry H, Goldstone AH. Reduced prostacyclin activity in systemic lupus erythematosus. *Ann Rheum Dis* 1980;**39**:524-5.
- ¹⁹ Carreras LO, Vermynen J. "Lupus" anticoagulant and prostacyclin. *Lancet* 1981;**1**:665.
- ²⁰ Marchesi D, Parbtani A, Frampton G, Livio M, Remuzzi G, Cameron JS. Thrombotic tendency in systemic lupus erythematosus. *Lancet* 1981;**1**:719.