

# Planned Carotid Artery–Jugular Vein Fistula

## 30-Year Follow-up and Surgical Correction

Harvey Lozman, MD; Moses Nussbaum, MD; Wen Yang, MD

• A patient had a common carotid artery–jugular vein fistula created 30 years previously for the treatment of mental retardation. During the years following this procedure, massive facial venous engorgement developed, and she had a stroke. Operative closure of the fistula successfully alleviated the facial swelling and venous engorgement.  
(*Arch Surg* 1982;117:1343-1345)

In 1948, Sciaroni<sup>1</sup> suggested that a double arteriovenous fistula between the common carotid artery and internal jugular vein might be beneficial in the treatment of stroke and mental disorders. He reported optimistic clinical results in three of four patients. Beck and co-workers,<sup>2</sup> one year later, presented at the American Pediatric Society their experience with side-to-side common carotid artery–internal jugular vein fistula for the treatment of mental retardation and convulsive disorders in four children. Beck et al<sup>3</sup> were so convinced that arterialization of the cerebral venous system would increase oxygen saturation in the capillaries of the brain that, by 1950, they had accumulated and reported results in 125 cases followed from two to 15 months. Fifty-four percent of the patients showed improvement (35% by objective criteria). They established a small side-to-side fistula between the common or external carotid artery and the internal jugular vein, with ligation of the internal jugular vein distal to the anastomosis and ligation of all internal jugular vein branches.

By 1953, after the results of surgery on 350 patients in the United States and Europe were evaluated, the procedure was found to be without merit.<sup>4,5</sup> Complications occurred in excess of 70% of patients when the fistula remained patent more than three years. Complications reported were pulsating exophthalmos with retinopathy, aneurysmal dilation of the venous component, elevated CSF pressure, subarachnoid hemorrhage, tinnitus, cardiomegaly, headache, arterial hypertension, and calcified vegetation on the wall of the jugular vein opposite the fistulous tract.<sup>6</sup> A mortality of 6% was reported when the fistula was created in adults. Furthermore, an-

giographic studies by Moretz and Bray<sup>7</sup> and Tarlov et al<sup>8</sup> convincingly demonstrated that blood flow was shunted from jugular vein to jugular vein via the transverse sinus and failed to reach the cerebral capillary circulation.

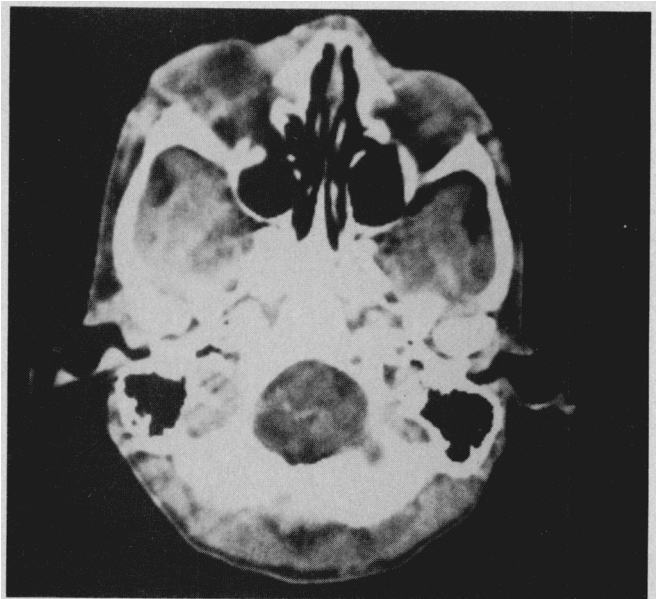We report the longest known follow-up in a patient 30 years after construction of such a fistula, with the added complications of cerebral vascular accident and hemiplegia.

### REPORT OF A CASE

A 34-year-old woman was admitted to Beth Israel Medical Center, New York, in October 1980, for evaluation of severe facial and upper eyelid swelling and left hemiplegia (Color Fig 1). She was the second child of a 34-year-old mother. At the age of 4 months, mental retardation had been noted, and at the age of 4 years, 30 years before this admission, the patient had had a right common carotid artery–internal jugular vein fistula created in an attempt to correct her mental retardation. At 6½ years of age, she was admitted to an institution for retarded children. At the age of 24 years, she manifested increasing facial and orbital edema with marked deformity. The right eyelids were more involved than the left. Three months before admission, a left hemiplegia had developed.

Examination showed a 15 × 7-cm, pulsatile mass in the right side

Fig 1.—Scan showing engorgement of intracerebral and ophthalmic veins. No cerebral infarct is noticeable.



Accepted for publication Oct 23, 1981.

From the Divisions of Vascular Surgery (Dr Lozman) and Head and Neck Surgery (Dr Nussbaum), Department of Surgery, and the Department of Radiology (Dr Yang), Beth Israel Medical Center, New York.

Reprint requests to Department of Surgery, Beth Israel Medical Center, 10 Nathan D. Perlman Pl, New York, NY 10003 (Dr Lozman).

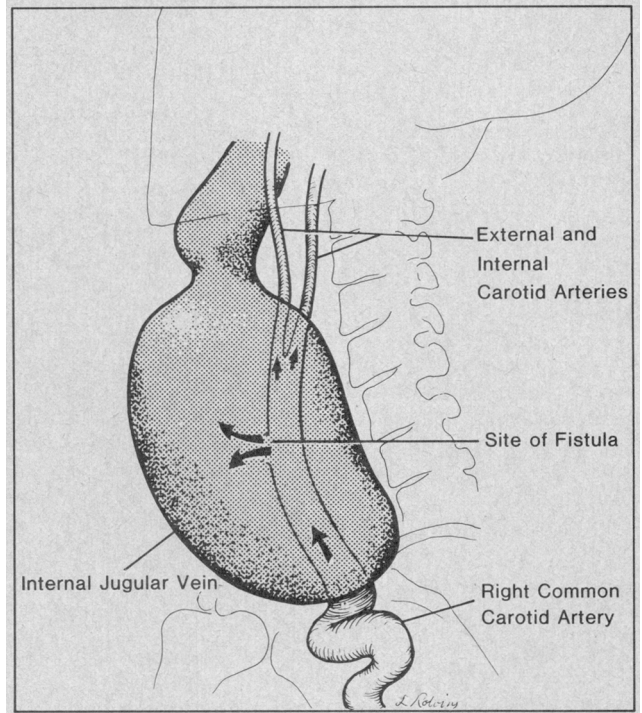
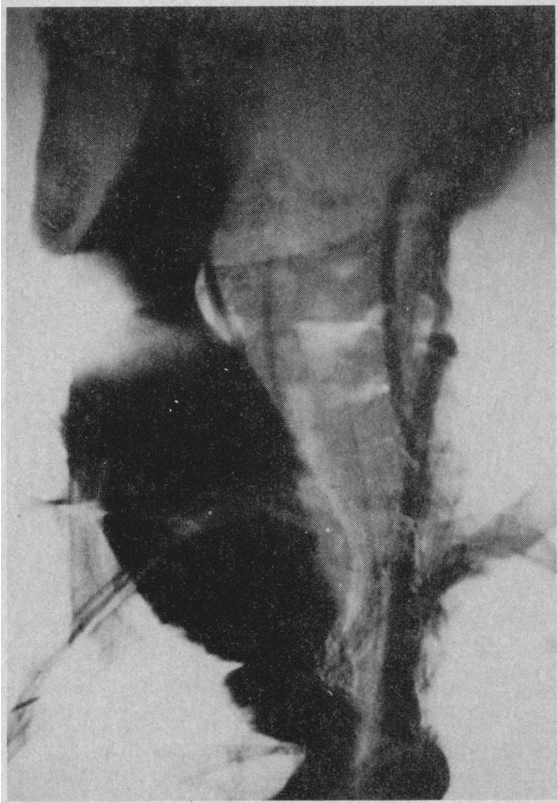
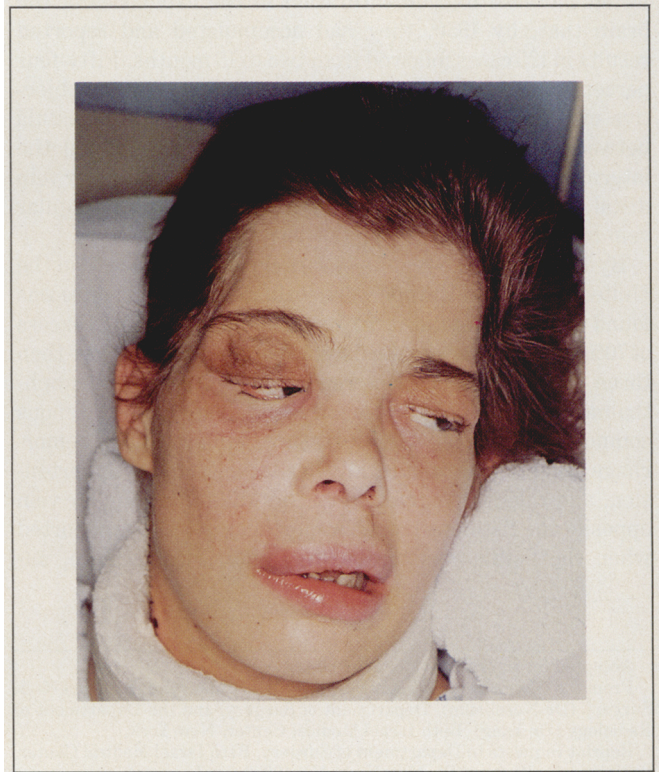
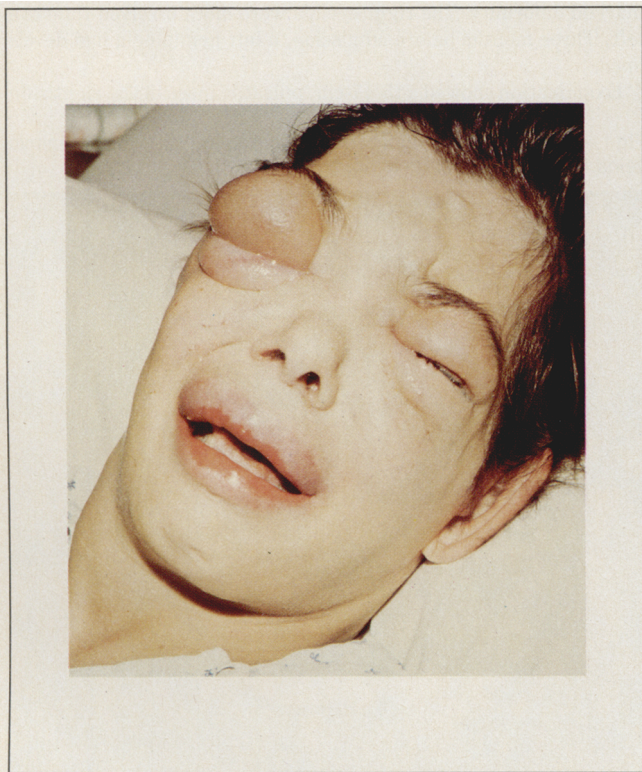Fig 2.—Percutaneous transfemoral angiogram confirming presence of arteriovenous fistula with 15 × 7-cm internal jugular vein vascular sac is at left. Drawing that shows location of fistula is at right.

Color Fig 1.—Patient with severe facial and upper eyelid swelling and left hemiplegia.

Color Fig 2.—Patient at discharge on tenth postoperative day with noticeable improvement in facial features.



of the neck that extended from the angle of the jaw to the clavicle and was associated with a machinery murmur and thrill. The murmur could be heard over both orbits. There was a left hemiplegia and right sixth nerve palsy, with extreme facial and palpebral edema and venous engorgement over both periorbital areas. Visual acuity in the right eye was limited by the massive palpebral edema. There was no evidence of high-output failure or cardiac enlargement by physical examination, chest x-ray film, or ECG. Ultrasonography disclosed multiple cystic spaces in the superior aspect of both orbits. A computed tomographic (CT) scan demonstrated intracerebral hemispheric calcifications and engorgement of intracerebral and ophthalmic veins but did not demonstrate a cerebral infarct (Fig 1). Results of percutaneous transfemoral angiography confirmed the presence of an arteriovenous fistula with a 15×7-cm internal jugular vein vascular sac (Fig 2). The internal and external carotid arteries were narrow. There was venous regurgitation with dilated lateral and cavernous sinuses and ophthalmic veins.

On Nov 10, 1980, with the patient under general anesthesia, the right side of the neck was exposed with an incision along the anterior border of the sternocleidomastoid muscle. A 15×7-cm, pulsatile, partially compressible internal jugular vein with a palpable thrill was found. The common carotid artery, proximal to the anastomosis, was thin walled, fragile, and aneurysmal to a level just above the clavicle. An internal carotid artery stump pressure of 99 mm/Hg was measured. The carotid artery proximal to the aneurysm and distal to the arteriovenous anastomosis was cross clamped and transected. The fistula was oversewn from within the carotid artery, thus eliminating the communication with the internal jugular vein. This step precluded the need to dissect the vein. A 6-mm, knitted, Dacron velour graft was interposed end to end between the proximal and distal portions of the common carotid artery. The patient's postoperative course was uneventful, except for several brief convulsions on the first and second postoperative days. She was discharged on the tenth postoperative day with great improvement in her facial features (Color Fig 2).

### COMMENT

Surgeons have long been fascinated by arteriovenous fistulas. In 1948, before his report on brain revascularization, Beck<sup>9</sup> reported creating an aortocoronary sinus fistula in a 45-year-old patient with the use of a segment of brachial artery to revascularize the heart. Arteriovenous fistulas have been used to enhance limb growth and improve patency of vascular anastomoses. According to Gordon,<sup>10</sup> arteriovenous shunts with the use of Teflon elastic catheters, as described by Scribner et al, have been successfully used since 1960 for hemodialysis. In 1966, Cimono and associates introduced the subcutaneous arterial venous fistula now most commonly used for dialysis and more recently used for chemoaccess therapy.<sup>10</sup> To our knowledge, none of the arteriovenous fistulas created for treatment of cardiac, cerebral, or extremity ischemia has withstood the test of time.

As noted by Rich and colleagues,<sup>11</sup> cardiac hypertrophy and proximal arterial dilation and tortuosity resulting from an arteriovenous fistula was first reported in 1757 by Hunter. In 1923, Holman<sup>12</sup> convincingly demonstrated this finding to be a cause-and-effect relationship and not a coincidental association. To prevent long-term sequelae, traumatic carotid jugular arteriovenous fistulas are repaired early, and long-term follow-up is unusual. Rich et al<sup>11</sup>

reported 558 traumatic arteriovenous fistulas and false aneurysms from the Vietnam Registry and found only two patients with demonstrated cardiac abnormalities and one patient with proximal arterial dilation following a fistula of 5½ years' duration. Holmes<sup>13</sup> described two patients with carotid jugular fistula in whom cardiac failure developed 12 years after creation of the fistula, and Adam and Getz<sup>6</sup> described one patient with high-output failure and cardiac enlargement 16 years after such a fistula was created. Our patient had neither cardiomegaly nor congestive heart failure, but proximal common carotid artery aneurysmal dilation was present.

The cause of the left hemiplegia in this patient is speculative. An internal carotid artery stump pressure of 99 mm/Hg should preclude decreased cerebral perfusion as a cause. Moretz and Bray<sup>7</sup> described one patient with a fistula who died in status epilepticus; autopsy disclosed small intracerebral hemorrhages in addition to a single left frontal lobe subarachnoid hemorrhage. A preoperative CT scan from our patient demonstrated intracerebral hemispheric calcifications without evidence of an infarct. Adam and Getz<sup>6</sup> found calcified vegetations on the wall of the internal jugular vein opposite the arteriovenous anastomosis; they did not note vegetation at the anastomotic site. Embolization from vegetative deposits at the arteriovenous anastomosis does occur and may have accounted for the left hemiplegia in this patient. However, we did not expose the original anastomosis in our patient.

An early report of good results, later shown to be invalid, led to the performance of this procedure on 350 children and adults with mental retardation, convulsive disorders, and strokes. Our report of the long-term consequences of planned carotid artery–jugular vein fistula, added to those previously described, should write the final chapter on this surgical misadventure.

### References

1. Sciaroni GH: Reversal of circulation of the brain. *Am J Surg* 1948;76:150-164.
2. Beck CS, McKhann CF, Belnap WD: Revascularization of the brain through establishment of a cervical arteriovenous fistula. *J Pediatr* 1949; 35:317-328.
3. Beck CS, McKhann CF, Belnap WD: Revascularization of the brain. *Am J Ment Defic* 1950;55:218-219.
4. Jervis GA, McAllister FF, Hogg BM, et al: Revascularization of the brain in mental defectives. *Neurology* 1953;3:871-878.
5. Hammer JM, Heersma HS, MacGregor JR, et al: Complications and effects observed in 33 patients with cervical arteriovenous fistulas. *Arch Surg* 1951;63:477-479.
6. Adam YG, Getz RH: Surgically produced carotid jugular fistula: Eighteen-year follow-up. *Ann Surg* 1970;171:93-97.
7. Moretz WH, Bray PF: Observations of the effects of carotid-jugular anastomosis. *Am Surg* 1953;29:765-777.
8. Tarlov IM, Shure B, Epstein BS, et al: Brain revascularization after carotid-jugular anastomosis assessed by angiography. *Arch Neurol* 1950; 64:847-860.
9. Beck CS: Revascularization of the heart. *Ann Surg* 1948;128:854-864.
10. Gordon HE: Historical development of vascular access procedures, in Wilson SE, Owens ML (eds): *Vascular Access Surgery*. Chicago, Year Book Medical Publishers Inc, 1980, chap 1.
11. Rich NM, Hobson RW, Collins GJ: Traumatic arteriovenous fistulas and false aneurysms: A review of 558 lesions. *Surgery* 1975;78:817-828.
12. Holman E: The physiology of an arteriovenous fistula. *Arch Surg* 1923;7:64-82.
13. Holmes TW: Circulatory dynamics in the presence of carotid-jugular fistula: Effects of repair after 12 years' patency. *Circulation* 1964;29:905-910.